Atlas of Renal Lesions in Proteinuric Dogs

Atlas of Renal Lesions in Proteinuric Dogs

Cianciolo Rachel, Cathy Brown, Charles Mohr, Mary Nabity, Jaco Van der Lugt, Shannon McLeland, Luca Aresu, Silvia Benali, Bill Spangler, Hayley Amerman, and George Lees

Claudio Brovida, Larry Cowgill, JD Foster, Reidun Heiene, George Lees, David Polzin, Harriet Syme, Shelly Vaden, and Astrid van Dongen

THE OHIO STATE UNIVERSITY

Atlas of Renal Lesions in Proteinuric Dogs by Rachel Cianciolo is licensed under a Creative Commons Attribution-NonCommercial-NoDerivatives 4.0 International License, except where otherwise noted.

Contents

Authors vii

Contributors and Acknowledgements ix

Preface xi

How to Use this Atlas xv

Introduction 1

Membranous Glomerulonephropathy 13

Membranoproliferative Glomerulonephritis 43

Focal Segmental Glomerulosclerosis 75

Amyloidosis 113

Juvenile Onset Chronic Kidney Disease (Juvenile Nephropathy) 159

Miscellaneous Glomerular Diseases 211

Tubular, Interstitial and Vascular Pathology seen with Glomerular Diseases 247

List of Terms 315

Publication Version 321

Authors

Rachel Cianciolo, The International Veterinary Renal Pathology Service and the Department of Veterinary Biosciences, The Ohio State University, Columbus, OH, USA

Cathy Brown, The Athens Veterinary Diagnostic Laboratory, College of Veterinary Medicine, University of Georgia, Athens, GA, USA

Charles Mohr, the Department of Pathology, Microbiology and Immunology, School of Veterinary Medicine, University of California, Davis, CA, USA

Mary Nabity, The International Veterinary Renal Pathology Service and the Department of Veterinary Pathobiology, College of Veterinary Medicine and Biomedical Sciences, Texas A&M University, College Station, TX, USA

Jaco van der Lugt, IDEXX Europe, BV, Hoofddorp, The Netherlands

Shannon McLeland, The International Veterinary Renal Pathology Service, MN, USA

Luca Aresu, The European Veterinary Renal Pathology Service and the Dipartimento di Scienze Veterinarie, Università degli Studi di Torino (TO), Italy

Silvia L. Benali, The European Veterinary Renal Pathology Service and the Laboratorio MYLAV, La Vallonea, Passirana di Rho (MI) Italy

Bill Spangler, Necropsy Services Group, Davis, CA, USA

Hayley Amerman, The Ohio State University, Columbus, OH, USA

George Lees, The International Veterinary Renal Pathology Service and the Department of Small Animal Clinical Sciences, College of Veterinary Medicine and Biomedical Sciences, Texas A&M University, College Station, TX USA

For questions and comments regarding this ebook please contact Dr Cianciolo: cianciolo.14@osu.edu

Contributors and Acknowledgements

Contributors:

This atlas would not have been possible without the efforts of veterinary internists and pet owners. In particular, we would especially like to thank our Contributors who participated in the creation of the International Veterinary Renal Pathology Initiative (IVRPI), under the auspices of the World Small Animal Veterinary Association – Renal Standardization Study Group (WSAVA-RSSG).

The following clinicians have been involved in case recruitment, sample collection and analysis of clinical data:

Claudio Brovida, ANUBI Ospedale per Animali da Compagnia, Moncalieri, Italy

Larry Cowgill, Department of Medicine and Epidemiology, School of Veterinary Medicine, University of California Davis, CA, USA

JD Foster, Friendship Animal Hospital for Animals, Washington DC, USA

Reidun Heiene, Ghent University, Faculty of Veterinary Medicine, Small Animal Department, Ghent, Belgium

George Lees, Department of Small Animal Clinical Sciences, College of Veterinary Medicine and Biomedical Sciences, Texas A&M University, College Station, TX USA

David Polzin, Department of Veterinary Clinical Sciences, College of Veterinary Medicine, University of Minnesota, St Paul, MN, USA

Harriet (Hattie) Syme, Department of Clinical Sciences, Royal Veterinary College, London, UK

Shelly Vaden, Department of Clinical Sciences, College of Veterinary Medicine, North Carolina State University, Raleigh, NC, USA

Astrid van Dongen, Department of Clinical Sciences of Companion Animals, Faculty of Veterinary Medicine, Utrecht University, Utrecht, The Netherlands

Acknowledgements:

All progress is made by people who are—in one way or another – standing on the shoulders of people who came before them and building on their prior accomplishments. This adage certainly applies to creation of this atlas, which is a product of the ongoing IVRPI. This initiative, which began in 2005, owes its existence to several groups of individuals, organizations, and institutions that we gratefully acknowledge for their substantial contributions to all of the IVRPI's achievements. The IVRPI Organizing Committee included Claudio Brovida, Cathy Brown, Larry Cowgill, Jonathan Elliott, Roel Goldschmeding, Reidun Heiene, George Lees, Johan Jansen, David Polzin, Kinji Shirota, Bill Spangler, Shelly Vaden, and Astrid van Dongen.

From 2008 through 2013, the IVRPI was largely supported by **Hills Pet Nutrition** and **Bayer Animal Health** under auspices of the **World Small Animal Veterinary Association (WSAVA)**, which funded the WSAVA-Renal Standardization Study Group (WSAVA-RSSG) project. The WSAVA-RSSG, co-chaired by Larry Cowgill and David Polzin, was divided into two working groups to pursue its goals. The *Clinical Working Group* included Claudio Brovida, Larry Cowgill, Jonathan Elliott, Reidun Heiene, George Lees, David Polzin, Harriet Syme, Shelly Vaden, and Astrid van Dongen. The *Pathology Working Group* included Luca Aresu, Cathy Brown, Rachel Cianciolo, Johan Jansen, George Lees, Charles Mohr, Bill Spangler, and Jaco van der Lugt, plus 3 individuals (Brian Berridge, Fred Clubb, Jr., and Clare James) who made valuable contributions early on but later withdrew due to the demands of their other commitments.

We would also like to gratefully acknowledge those who have helped process and create the materials that are shown in this Atlas: Fred J Clubb (Department of Veterinary Pathobiology, Texas A&M University, College Station, TX, USA); Ralph Nichols (Texas Heart Institute, Houston, TX, USA); Mary Sanders (Department of Small Animal Clinical Sciences, College of Veterinary Medicine and Biomedical Sciences, Texas A&M University, College Station, TX USA); Alan Fletchner, Anne Saulsberry and Florinda Jaynes (the Comparative Pathology and Mouse Phenotyping Shared Resource, The Ohio State University, Columbus, OH, USA); Mary Ard (Georgia Electron Microscopy Center); and Histopathology staff at Texas A&M University. Their expertise have helped immensely in the evaluation, diagnosis and characterization of renal disease in small animals. Two veterinary students from the Ohio State University, Natalia Jurcak and Hillary Sullivan, helped prepare images, text and clinical synopses. Will McAbee (Educational Resources, College of Veterinary Medicine, University of Georgia) helped create many of the colored transmission electron micrographs. Lastly, we appreciate the guidance and experience in digital publishing that were provided by Michael Shiflet at the Ohio State University Office of Distance Education and eLearning.

Preface

This *Atlas of Renal Lesions in Proteinuric Dogs* is a seminal work that is the product of a huge amount of effort by a dedicated cadre of veterinary pathologists and nephrologists. However, it is noteworthy that it has only recently become possible to prepare such an atlas because during the last decade veterinary pathologists have had the opportunity to routinely evaluate appropriate specimens from proteinuric dogs using adequate methods of examination. This opportunity occurred because of the confluence of 3 important trends: (1) increased availability of informative specimens, (2) greater ability to perform adequately revealing tissue examinations, and (3) improved integration of the clinical and pathologic findings to better support clinical decision-making.

Several key factors contributed to the increased availability of informative specimens. One of these was the emergence of a heightened clinical awareness of the potential value of detecting and managing proteinuria and hypertension, which are common clinical manifestations of canine glomerular diseases. Publication of ACVIM Forum Consensus Statements regarding proteinuria (in 2004) and hypertension (in 2007) both reflected this heightened awareness and armed clinicians with specific guidelines for diagnosis and treatment of these problems. Another key factor contributing to greater availability of informative specimens was increased use of renal biopsy to obtain an antemortem diagnosis and guide therapeutic decisions. Increased emphasis on detecting proteinuria no doubt led to more frequent identification of appropriate indications for renal biopsy. In addition, renal specimens obtained by biopsy are diagnostically more informative than postmortem samples. The first of these is that biopsy specimens frequently exhibit earlier stages in the pathogenesis of the animal's nephropathy, which makes it easier for the pathologist to discern the fundamental nature of the initial abnormality. Second, biopsy specimens typically are relatively small pieces of tissue that are, when handled properly and promptly placed in appropriate fixatives / preservatives, devoid of artifacts, which makes it possible for the pathologist to confidently identify even very subtle lesions that might otherwise be obscured by or confused with postmortem changes.

A pivotal event that enabled veterinary renal pathology to evolve to its present state of maturation was the development of veterinary Diagnostic Renal Pathology Centers (DRPCs), which provided the ability to routinely perform adequately revealing tissue examinations. From a laboratory perspective, processing renal specimens for the kinds of examinations that are required for excellent diagnostic evaluation are highly specialized and demanding tasks. Moreover, developing and maintaining a high degree of technical competence in performing these tasks requires a fairly steady supply of cases to maintain proficiency. Beginning in 2005, DRPCs were established first at Texas A&M University in the USA and subsequently (in 2008) also at Utrecht University in the Netherlands. Each of these DRPCs functioned to:

1. Provide guidance and support for clinicians seeking to submit renal specimens and providing, upon request, Renal Biopsy Kits that contain the materials and instructions needed to properly submit optimum specimens.
2. Routinely perform specialized tissue examinations, including:
    1. Light microscopy with tissue sections cut at 3 micron thickness and routine use of a panel of histochemical stains.

2. Immunostaining of cryosections cut at 3 to 5 micron thickness with routine use of fluorescent antibody probes for immunoglobulins and complement components.
3. Transmission electron microscopy

3. Utilize digital pathology technologies to capture digital images of all microscopic specimens in formats that were suitable for viewing with sufficient magnification and clarity to permit astute diagnostic evaluation.
4. Accumulate all evaluated cases in a searchable, web-based archive that includes:
    1. The clinical information provided when the samples were submitted
    2. Digital images of the microscopic specimens
    3. Descriptions of all microscopic findings
    4. Interpretive comments offered by the pathologists
    5. Any follow-up clinical information that is made available

The searchable, web-based archive created by operations of veterinary DRPCs since their inception now (January, 2018) contains ~2,000 cases, the majority of which are evaluations of biopsy specimens obtained from proteinuric dogs in North America.

The third, and possibly most important, element contributing to the current relevance of renal pathology to contemporary veterinary nephrology practice has been greatly improved processes for integrating the findings and expertise of renal pathologists with the findings and expertise of clinical nephrologists. One of the first uses of the archive (database) was to serve as the substrate for a WSAVA-sponsored project to establish appropriate diagnostic criteria for canine glomerular diseases. Prior to this initiative, canine glomerular diseases were most often classified according to criteria for human diseases, which was tantamount to making diagnoses of human diseases in dogs. The objective of this project was to establish standardized, objective species-specific criteria for classifying canine glomerular diseases. The project, the results of which have been published (Vet Pathol 2016:53:113-135), was accomplished in a highly collaborative fashion using a digital pathology platform to review cases in the web-based archive during online meetings. These meetings fostered a culture of clinician-pathologist collaboration that is essential for optimum use of renal biopsy findings to support clinical decision-making for the benefit of patients. The nature and importance of this clinician-pathologist relationship is aptly conveyed by the following statements:

“The correct diagnosis requires a well-trained renal pathologist with thorough knowledge not only of renal pathology but also renal medicine in order to correlate intricate tissue derived information with detailed and sometimes subtle clinical data to provide the best possible clinicopathologic diagnosis.”

Walker PD, et al: Practice guidelines for the renal biopsy.
Mod Pathol 2004;17:1555-1563.

“Getting high value from a renal biopsy requires a well-trained clinician with thorough knowledge not only of renal medicine but also of renal pathology to correlate detailed and sometimes subtle clinical data with intricate tissue-derived information to obtain the best possible clinicopathologic diagnosis and provide optimum patient care.”

A corollary statement made in a presentation by George Lees
25th ACVIM Forum; June, 2007; Seattle, WA

The accomplishments of the International Renal Pathology Initiative over the last 13 years have constructed a solid foundation for continued progress in veterinary nephrology and renal pathology. Renal biopsy is now well established as a productive diagnostic procedure in large part because of the ready availability of excellent tissue analysis combined with expert, clinically-relevant interpretation of the findings by experienced veterinary renal pathologists. The infrastructure and procedures needed to reliably deliver renal pathology services in a timely manner have been developed and have withstood the test of time. A growing cohort of clinicians and pathologists is being trained to perform and evaluate renal biopsies as a collaborative enterprise focused on optimizing patient care. There is, of course, much that is yet to be learned; however, the necessary resources now exist and the future of veterinary renal pathology is exciting to contemplate.

George E. Lees, DVM, MS
Diplomate, ACVIM (Small Animal Internal Medicine)
Diplomate, ACVP (Honorary)
Emeritus Professor
Department of Small Animal Clinical Sciences
College of Veterinary Medicine and Biomedical Sciences
Texas A&M University

How to Use this Atlas

This work was created by veterinary anatomic and clinical pathologists with interest and expertise in nephropathology and specifically glomerular disease. The Atlas is designed to illustrate the variety and breadth of lesions that can be identified in dogs with proteinuria. The text is geared towards an audience with training and experience in veterinary pathology and nephrology (e.g. pathology residents, board-certified pathologists and veterinary internists with interest in nephrology and urology). There are many features that the eBook format provides which will hopefully enrich the material presented here.

First, the basic signalment and clinicopathologic data are provided before each set of images are displayed. Many of the cases have additional clinical and historical details, which can be viewed by clicking on the arrowhead to the left of the case information. This will provide a dropdown box with the additional relevant information.

Second, the transmission electron micrographs often have a colorized version to allow the reader verify their identification of the structures in the micrograph. Below the colorized versions, there is a bar with the names of the structures present in the micrograph. Clicking on the name or sliding the bar from left to right will highlight the structure in the image. Colorization of these transmission electron micrographs was an arduous task, and many of the authors worked on the images. Although there is some variation in the tinctorial hue and presence or absence of an outline, the overall goal was to color podocytes pink, glomerular basement membrane green, endothelial cells yellow, mesangium blue, and parietal epithelial cells purple.

Third, there are multiple links to published literature throughout the text. They should be active links. If a link has become inactive, please contact us so we can address it within the text.

Finally, the benefit of an eBook format will allow us to periodically update the Atlas with new diseases and with better examples of some of the diseases currently described. Viewing the eBook via the web will ensure that you are reading the most current version. If you prefer to download the book as a pdf, please be aware that there might be changes and updates to the content at a later date. When there is substantiative change in content, we will update the list of Publication Versions at the back of the book. Comparison of the saved pdf to this list will help the reader determine if they are viewing the most recent version.

Thank you in advance for your interest in canine proteinuric kidney disease. Please feel free to contact us with questions, concerns and comments!

Sincerely
Rachel Cianciolo
Co-Director, The International Veterinary Renal Pathology Service
Department of Veterinary Biosciences
The Ohio State University, Columbus, OH

For questions and comments regarding this eBook,please contact Dr Cianciolo:
cianciolo.14@osu.edu

xvi Cianciolo Rachel, Cathy Brown, Charles Mohr, Mary Nabity, Jaco Van der Lugt, Shannon McLeland, Luca Aresu, Silvia Benali, Bill Spangler, Hayley Amerman, and George Lees

Introduction

This *Atlas of Renal Lesions in Proteinuric Dogs* describes and illustrates the tissue abnormalities that are observed in, and therefore characterize, kidney diseases in dogs with renal proteinuria. These lesions can be identified when appropriate tissue specimens are adequately examined by experienced veterinary pathologists. Preparation of this atlas is another outcome of the World Small Animal Veterinary Association Renal Pathology Initiative. The WSAVA Renal Pathology Initiative developed a standardized objective species-specific approach for the diagnosis of canine glomerular disease, and was published in 2016 (Cianciolo 2016).

The published approach, which is also conveyed in this atlas, is based on routinely using standardized methods of tissue evaluation, including (1) examination of thin (3 µm) light microscopic (LM) sections viewed with a specific panel of histochemical stains, (2) immunofluorescence (IF) to detect the presence of immunoglobulins and complement components, and (3) transmission electron microscopy (TEM). These specialized evaluations have been performed at two veterinary diagnostic renal pathology centers, one in the United States and one in Europe, that were established for this purpose. These centers have now clearly demonstrated that canine renal biopsies can be evaluated with LM, IF, and TEM in a reasonable diagnostic workflow to provide timely and useful information to clinicians. Since their inception (in the US in 2005, and in Europe in 2008) these centers have evaluated more than 2,000 cases, the majority of which have been renal biopsies from proteinuric dogs in North America.

The study that produced the published approach had 3 goals. The first was development of a digital pathology platform that permitted the study pathologists, who were in widely dispersed geographic locations, to communicate and collaborate effectively. Utilizing that platform, digitized LM slides and IF and TEM images were remotely accessed and evaluated by individuals and by the group during online meetings. The second goal was to develop succinct definitions and scoring criteria for glomerular, tubular, interstitial and vascular lesions observed in the specimens examined. The third and final goal was to use hierarchical cluster analysis to objectively identify common patterns of glomerular injury in dogs to create a simplified, reproducible, and accurate guide for veterinary pathologists to use when evaluating renal biopsies from proteinuric dogs. The results of that study are further promulgated by this atlas, which defines and illustrates the lesions that were identified and illustrates the spectrum of lesion severity exhibited by each of the common patterns of glomerular injury that occur in dogs.

THE HISTOLOGIC AND ULTRASTRUCTURAL ANATOMY OF NORMAL GLOMERULI

The glomerulus is composed of a network of capillaries supported by a central scaffolding of mesangium. Afferent and efferent arterioles that supply individual glomeruli are located at the vascular pole, which may not be present in every cross-section. Three cell types are present in glomeruli: mesangial cells, epithelial cells, and endothelial cells. Mesangial cells are located centrally within the tuft and there should be no more than 3 cells within the mesangium adjacent to a peripheral capillary loop. Endothelial cells line capillary lumens and have a thin rim of cytoplasm and oval nucleus. Glomerular epithelial cells are divided into parietal and visceral epithelium. Podocytes (also called visceral epithelial cells) are present on the abluminal surface of capillary loops and have specialized foot processes that are in contact with the glomerular basement membrane (GBM). The GBM is the matrix component of capillary loops that lies between the endothelial and epithelial layers. Parietal epithelial cells line the internal surface of the Bowman's capsule, which encloses the glomerular tuft, and is squamous in appearance. Opposite of the vascular pole is the urinary pole where parietal epithelial

cells transition from squamous to columnar epithelial cells of the proximal tubular epithelium. Cortical tubules are closely apposed with scant interstitium and peritubular capillaries.

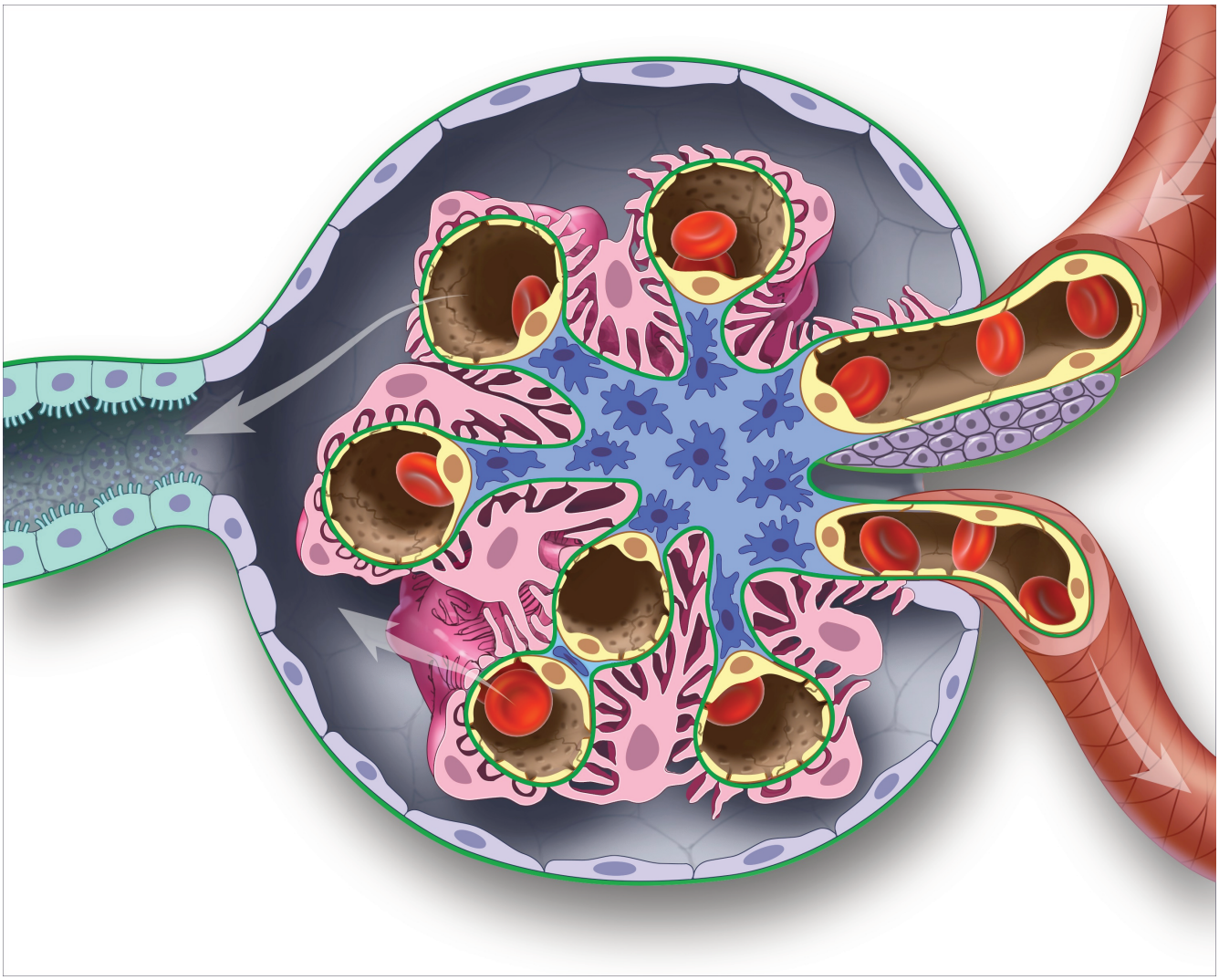

FIG 1. Schematic diagram of a normal glomerulus with colorized components. Podocytes are pink; Glomerular basement membrane is green; Endothelial cells are yellow; Mesangium is blue; Parietal epithelial cells are purple. Arterioles are brown structures at the right of the image. Proximal tubules are the teal stuctures to the left of the image. Contributed by Educational Resources, College of Veterinary Medicine, University of Georgia.

INTEGRATION OF LIGHT MICROSCOPY, IMMUNOFLUORESCENCE, TRANSMISSION ELECTRON MICROSCOPY AND CLINICAL ASSESSMENT ARE IMPERATIVE FOR THE ADEQUATE EVALUATION OF RENAL BIOPSIES.

LIGHT MICROSCOPY

- Comprehensive histologic evaluation includes standard hematoxylin-and-eosin (HE) and special stains performed at ≤ 3 µm thick sections. Congo Red stain is an exception and is performed on tissues sectioned 8-10 µm. Special stains include Periodic-Acid Schiff hematoxylin (PAS[H]), Masson's trichrome (TRI), and Jones methenamine silver stain (JMS). All glomeruli should be examined in core biopsies and no less than 50 glomeruli with wedge specimens so that focal lesions are not missed. Glomerular features to be assessed by light microscopy include hypercellularity specifically the location, cell type, and severity; presence of synechiae, crescents, and hyalinosis. Furthermore, the remaining compartments (i.e. interstitium, tubules, vasculature) should be examined for lesions that may include but are not limited to fibrosis, inflammation, tubular atrophy, and arterio- and arteriolosclerosis.
- HE: A good survey stain, helpful for assessing inflammation, cellular and nuclear morphology. Glomerular basement membrane (GBM) may appear falsely thickened due to the lack of differentiation between matrix and cellular components.
- PAS: Helpful in distinguishing between basement membranes (dark pink to magenta) and cells (cytoplasm is pale pink). Highlights (pink) the brush border of proximal tubular epithelial cells
- TRI: Basement membranes and extracellular collagenous matrix stain blue while cytoplasm is red. Glomerular immune deposits can appear as regular, small fuchsinophilic (red) nodules that typically reside on the abluminal surface of capillary loops.
- JMS: Excellent stain to evaluate for GBM remodeling (i.e. spikes, holes, double contours, and/or irregular outer contours). Normal GBM should have smooth outer contours. Tinctorial density of GBM depends on how the capillary loop is cut (perpendicular vs en face).

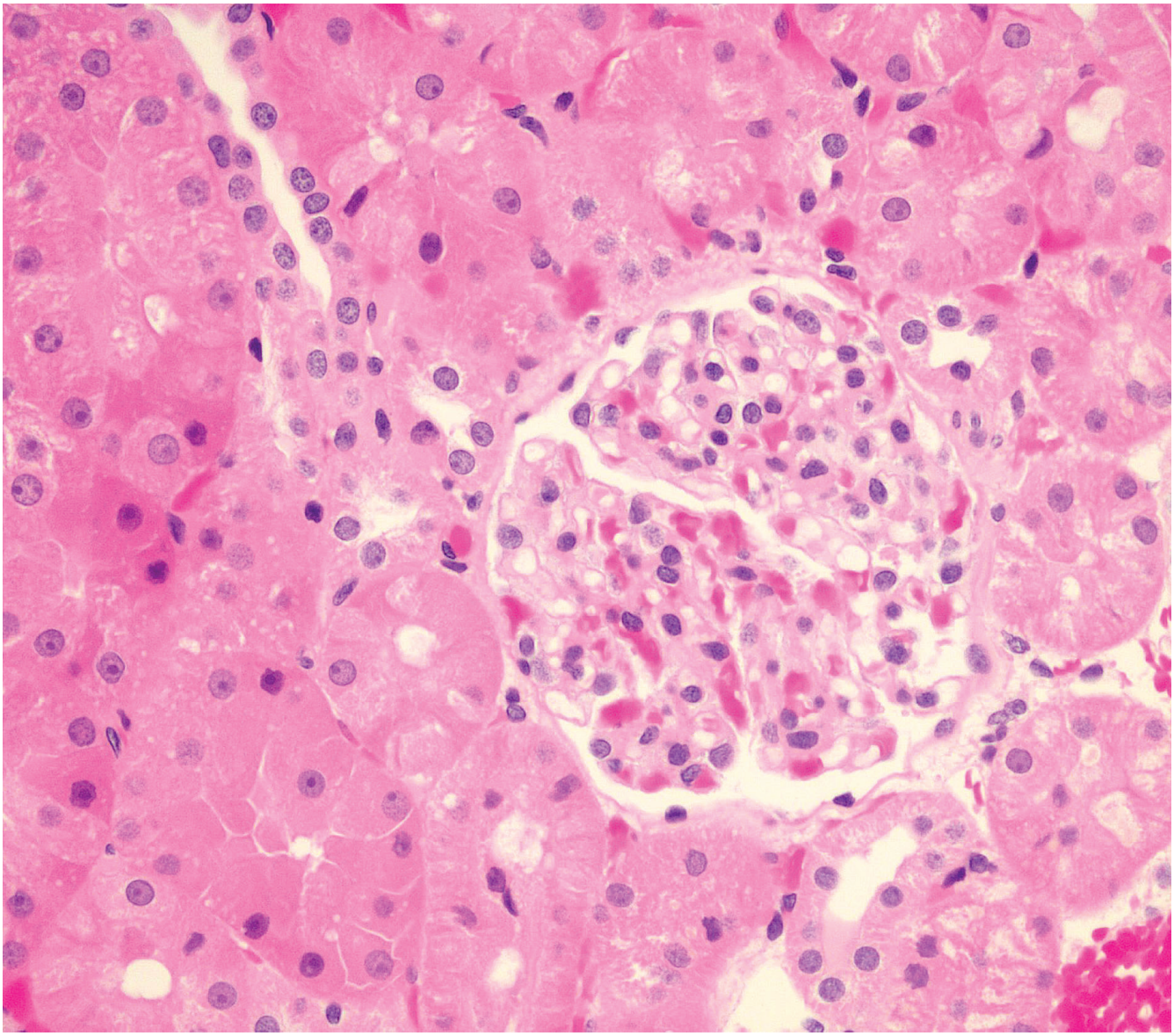

FIG 2A. Hematoxylin-and-eosin (HE) of a normal glomerulus. Staining of cytoplasm and GBM are similar and difficult to differentiate, which might give the false appearance of thickened capillary loops. It is also useful in assessing inflammation (degree and cell type).

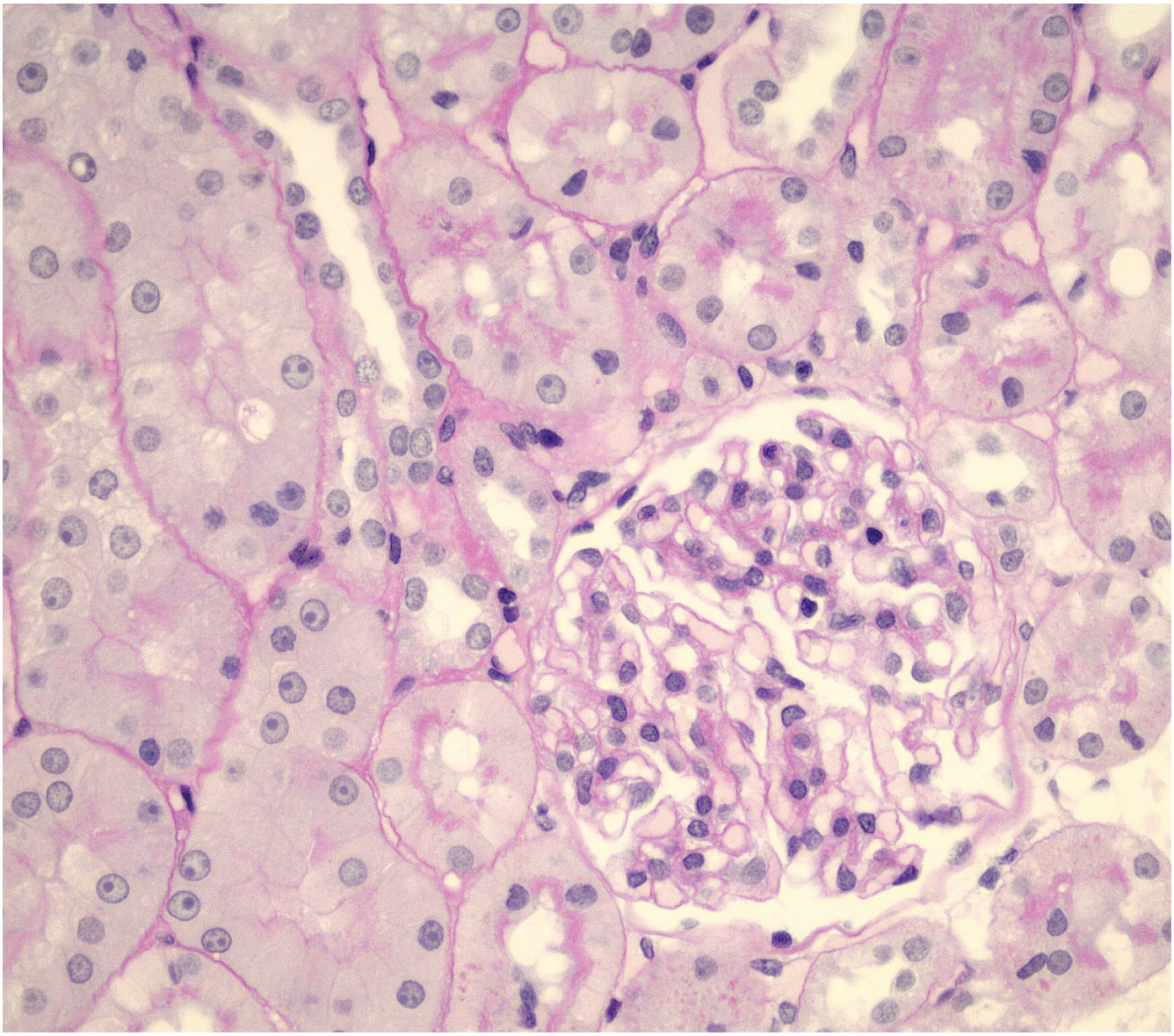

FIG 2B. Periodic-Acid Schiff hematoxylin (PAS) of a normal glomerulus. Basement membranes are bright pink or magenta and of equal thickness. Nuclei are blue due to the hematoxylin counterstain. RBCs are pale peach while the cytoplasm of other cells (e.g. proximal tubular epithelial cell to the right of the glomerulus) are light pink. The apical brush borders of proximal epithelial cells are pink and easy to discern.

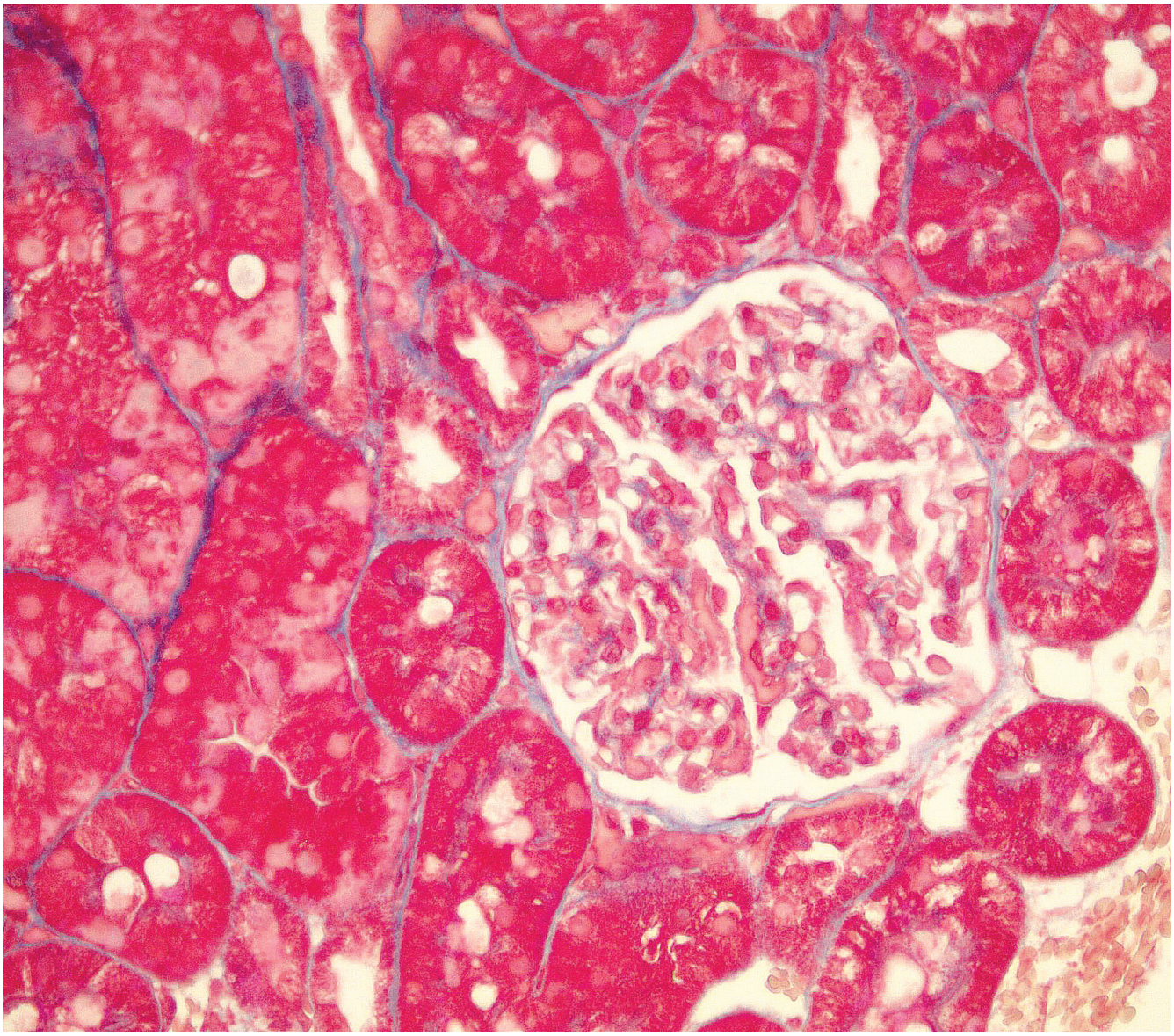

FIG 2C. Masson's trichrome (MT) of a normal glomerulus. Collagen (e.g.extracellular matrix and basement membranes) is blue with this stain. Cytoplasm stains red and RBCs are dark red.

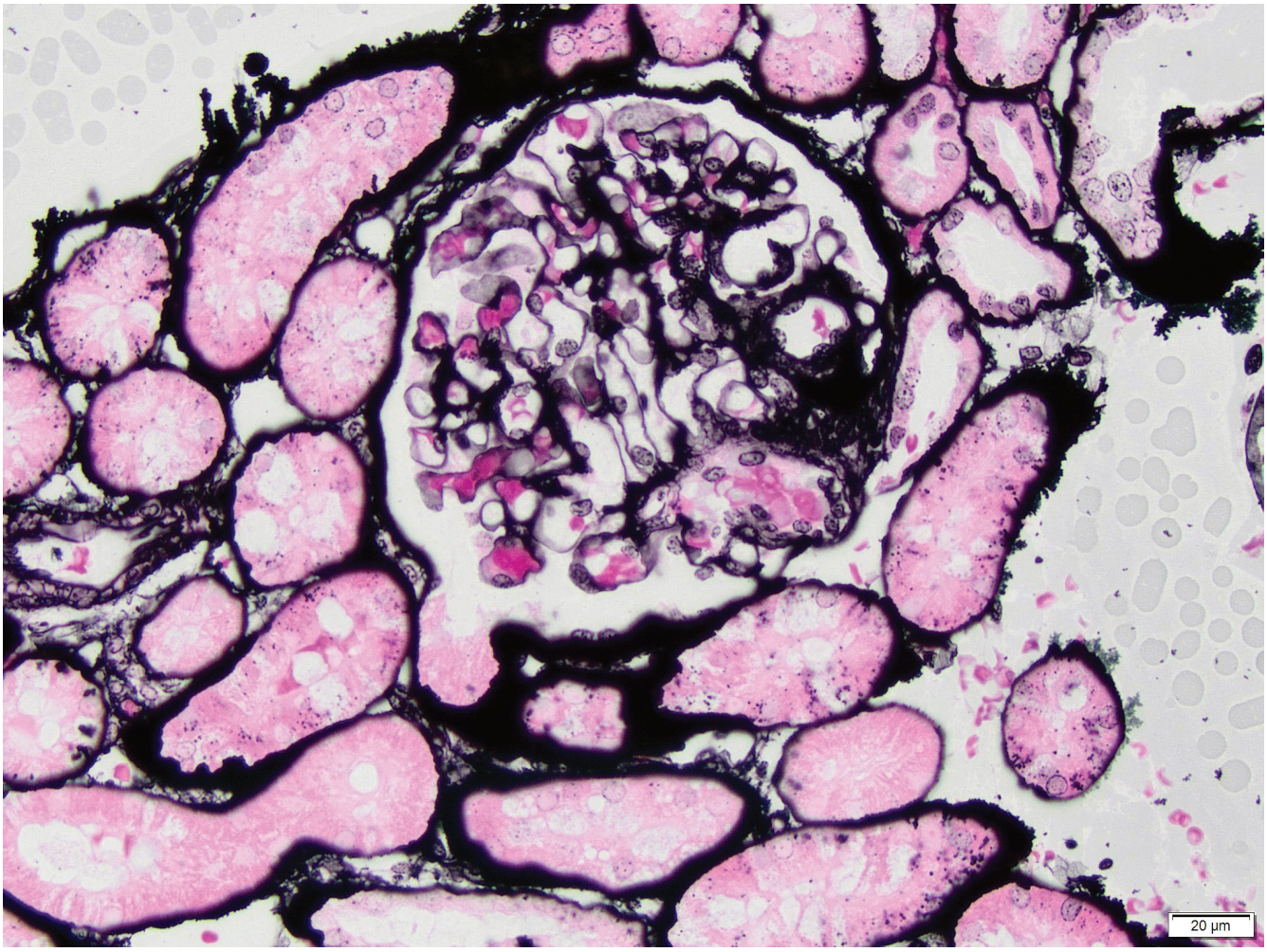

FIG 2D. Jones methenamine silver (JMS) stain of a normal glomerulus. The capillary walls and mesangium are black, but the tinctorial density of GBM depends on how the capillary loop is cut (perpendicular vs *en face*). The outer contours of capillary loops are smooth and have an equal thickness compared to adjacent tubular basement membranes. RBCs within capillary lumens stain pink while other cell cytoplasm is pale pink with black nuclei.

IMMUNOFLUORESCENCE

Because the immunofluorescence antibodies used target components of immunoglobulins (heavy chains and light chains), there should be minimal to no labeling of the healthy glomerulus. One of the immunoreactants, IgM, might label the glomerulus non-specifically. Normal tubules also often have various degrees of non-specific labeling.

TRANSMISSION ELECTRON MICROSCOPY

This method is used almost exclusively for evaluation of the glomerulus. Identification of the podocytes and their regularly-spaced foot processes that are oriented perpendicular to the glomerular capillary walls is usually a first step in orienting the pathologist as to the location of capillary lumens and the abluminal Bowman's space. Nuclei within the urinary space are either podocyte or parietal epithelial cell nuclei. The glomerular capillary walls should have a smooth contour. In some preparations, the trilaminar nature of the glomerular basement membrane can be identified: lamina rara interna, lamina densa, lamina rara externa. Along the luminal aspect of the capillaries, there is a thin fenestrated endothelium with a single nucleus. Circulating red and white blood cells are occasionally observed.

The mesangial matrix is usually more electron dense and has a fibrillar to granular appearance. The number of nuclei in the mesangium should be 1 to 2 per segment.

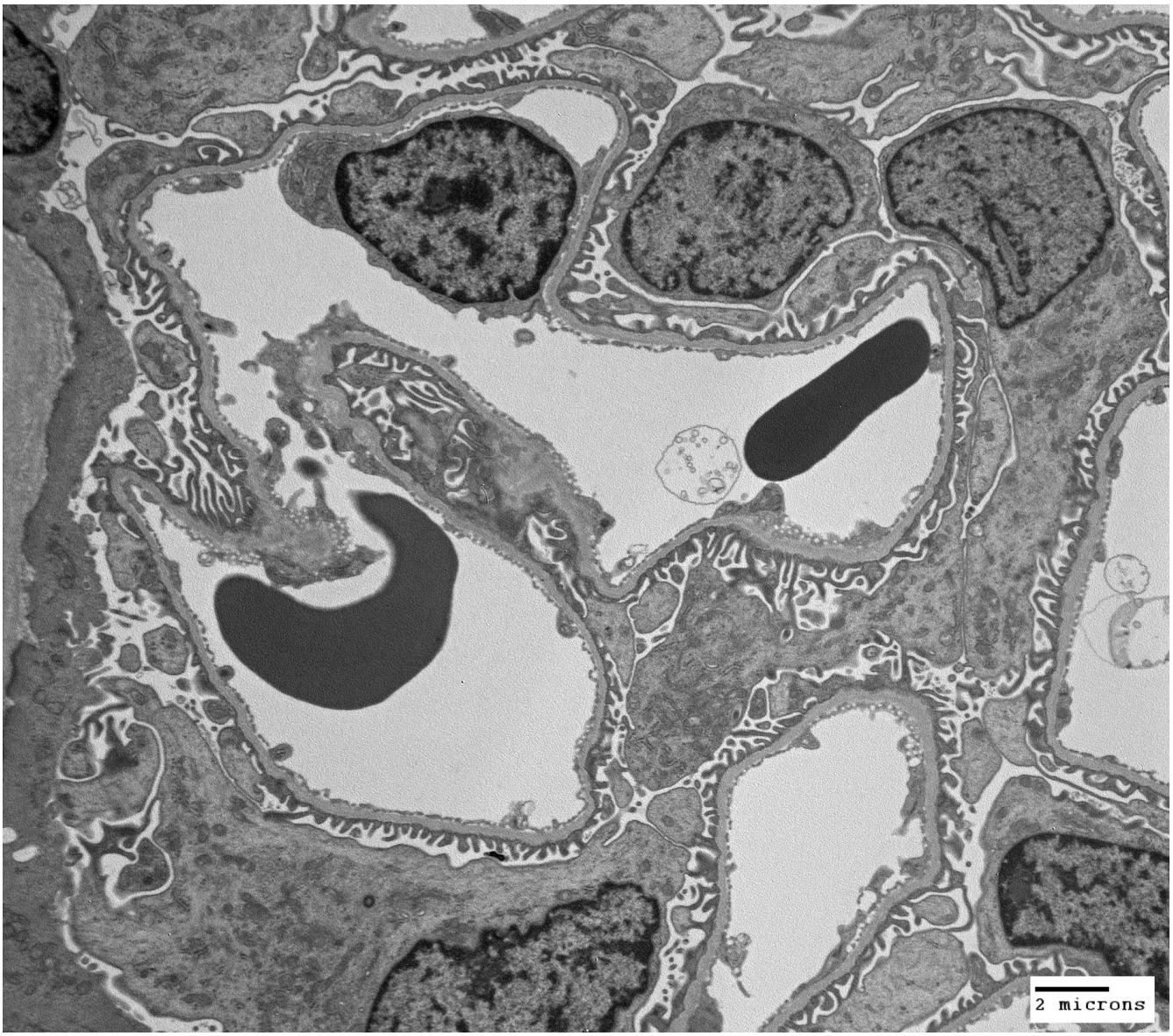

FIG 3A. Ultrastructural transmission electron microscopy (TEM) image of a normal glomerulus. Several capillary loops are present. Endothelium lines the internal surface of the capillary walls. There is an endothelial nucleus present in the upper right capillary. On the external surface of each loop are numerous foot processes and a podocyte nucleus and cell body in the lower right between capillary loops.

An interactive or media element has been excluded from this version of the text. You can view it online here:
https://ohiostate.pressbooks.pub/vetrenalpathatlas/?p=791

FIG 3B. Colorized version of above TEM. Endothelium is yellow, glomerular basement membrane is green, and podocytes are pink.

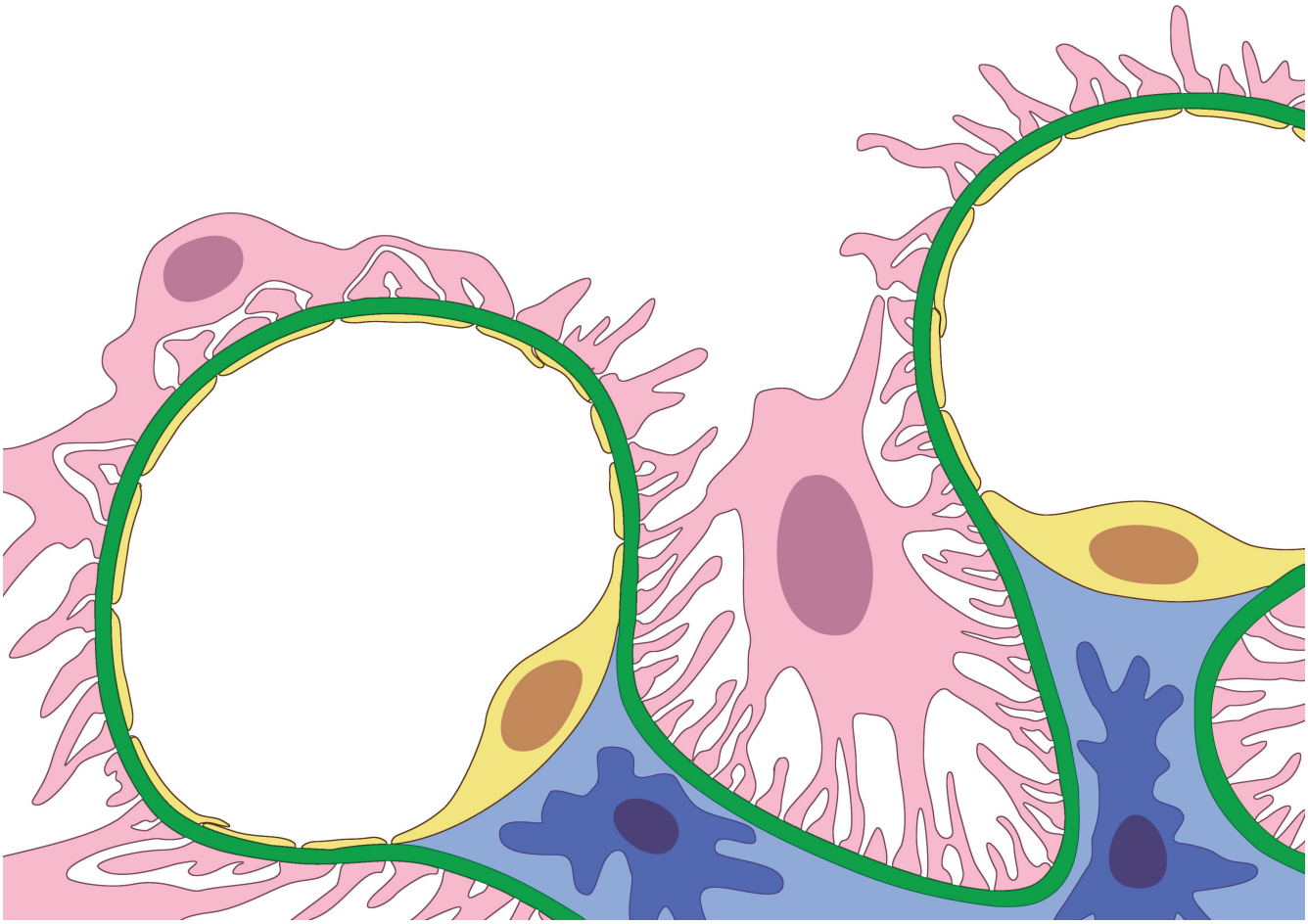

FIG 3C. Diagram of 2 capillary loops from a normal glomerulus, with colorized components. Podocytes are pink; Glomerular basement membrane is green; Endothelial cells are yellow; Mesangium is blue. Contributed by Educational Resources, College of Veterinary Medicine, University of Georgia.

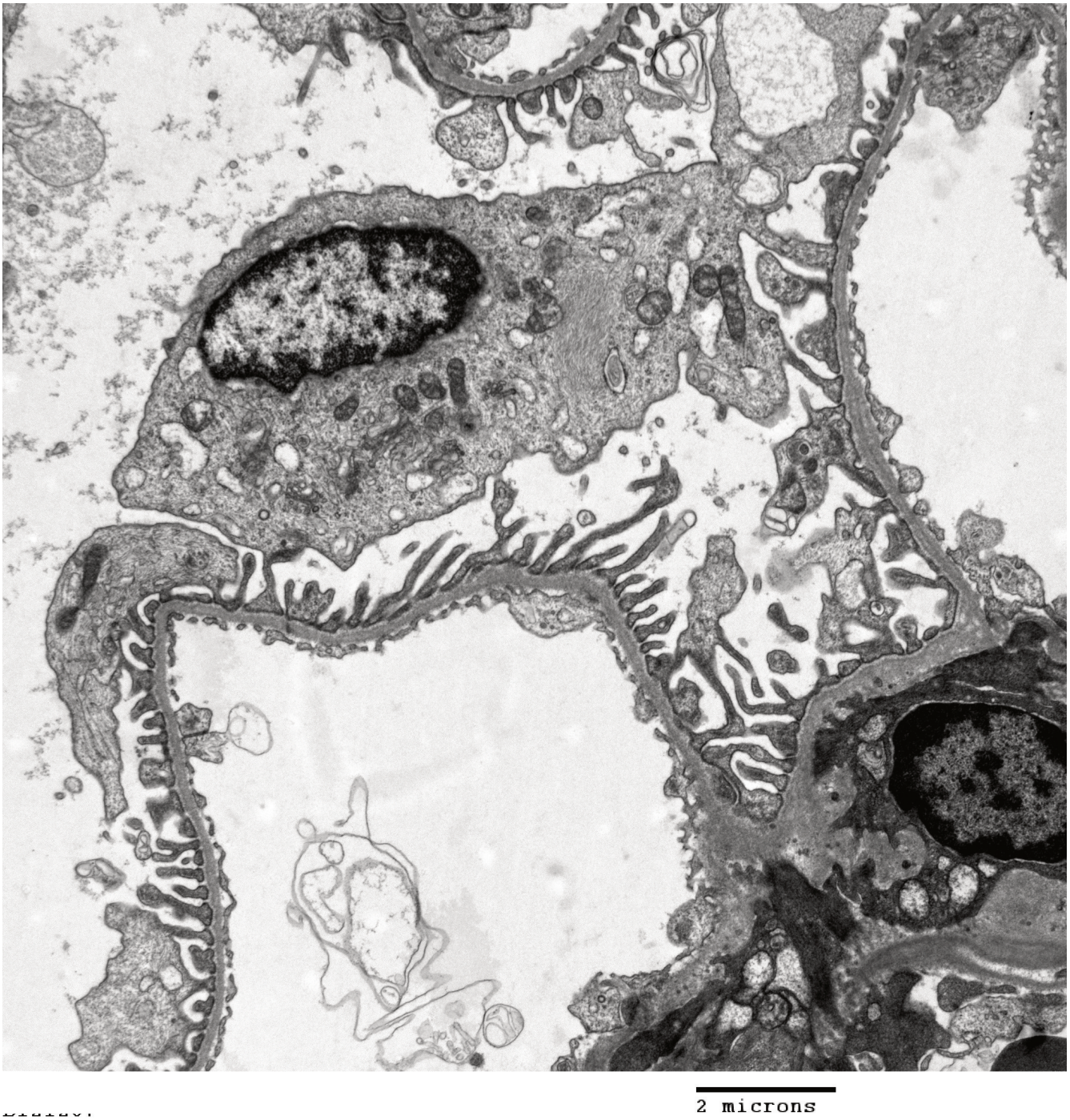

FIG 3D. Ultrastructural transmission electron microscopy (TEM) image of a normal glomerulus. One entire capillary loop and one partial loop are available for examination. Endothelial fenestrations are easier to appreciate but an endothelial nucleus is not present in this section. On the abluminal surface of each loop are numerous foot processes that are perpendicular to the glomerular basement membrane. A podocyte nucleus and cell body is near the center of the transmission electron micrograph.

An interactive or media element has been excluded from this version of the text. You can view it online here:
https://ohiostate.pressbooks.pub/vetrenalpathatlas/?p=791

FIG 3E. Colorized version of above TEM. Endothelium is yellow, glomerular basement membrane is green, and podocytes are pink.

Membranous Glomerulonephropathy

- Membranous glomerulonephropathy (MGN) is an immune-complex mediated disease wherein immune complexes are deposited on the abluminal (subepithelial) side of the glomerular basement membrane (GBM).
    - Immune complex deposits are composed of immunoglobulin (usually IgG) and antigen. The source of the antigen is often unknown and could be native or exogenous.
    - Immune complex deposits activate the complement system. Complement components (e.g. C3) can be identified with IF.
- Histologic appearance – Glomeruli are usually normocellular. In early stages, the capillary walls are histologically normal. In later stages, GBM remodeling occurs, demonstrated by the presence of spikes on the abluminal surface and / or holes within a thickened capillary wall.
    - With LM, the GBM remodeling is best visualized with JMS.
    - Regularly spaced subepithelial red (fuchsinophilic) nodular deposits are suggestive of immune complex deposits with MT.
    - Mesangial hypercellularity is minimal to mild while endocapillary hypercellularity should be absent to minimal.
    - All glomeruli are affected.
- TEM and IF are used to identify the presence of immune complex deposits and are invaluable in identifying early cases of MGN when GBM remodeling is subtle or absent on LM. Foot process effacement and other non-specific lesions of podocyte injury are also usually present.
- MGN can be staged based on the following features. The duration of each stage is unknown and some cases might have glomeruli at various stages, likely due to episodic immune complex deposition.
    - Early MGN: GBM has a normal contour and thickness on LM; deposits might be visible with MT. TEM reveals deposits but GBM remodeling is absent or minimal (limited to small scattered spikes).
    - Late MGN: GBM thickening and remodeling (spikes and holes) can be seen with LM. Red nodular deposits might be visible with MT. On TEM, prominent spikes of GBM are in between electron dense deposits, and some deposits are completely encircled by GBM.
    - Advanced MGN: LM evidence of marked GBM remodeling, with holes present in severely thickened capillary walls. There is also secondary glomerulosclerosis due to podocyte injury and loss. TEM might reveal evidence of dissolution of the deposits.

Clinical Features of Membranous Glomerulonephropathy

- Initial sign is typically moderate to marked proteinuria, often with hypoalbuminemia. *Dogs with membranous GN nearly always present with UPC >2.*
- Azotemia develops with sclerosis and nephron loss due to persistence/ progression of disease. With extensive advanced lesions, severity of proteinuria and hypoalbuminemia might decrease.
- Other common clinical findings include low antithrombin activity, hypertension, hypercholesterolemia, and edema/ascites.
- Dogs with ICGN frequently retain adequate concentrating ability.
- MGN is associated with infections, such as Leishmaniasis and Lyme nephritis.
- *Dogs <1 year of age are unlikely to have MGN.*
- No breed predisposition is currently recognized.

EARLY MEMBRANOUS GLOMERULONEPHROPATHY: The capillary wall appears normal to mildly thickened. GBM remodeling is absent or minimal. Fuchsinophilic deposits might be identified with MT.

An interactive or media element has been excluded from this version of the text. You can view it online here: https://ohiostate.pressbooks.pub/vetrenalpathatlas/?p=190

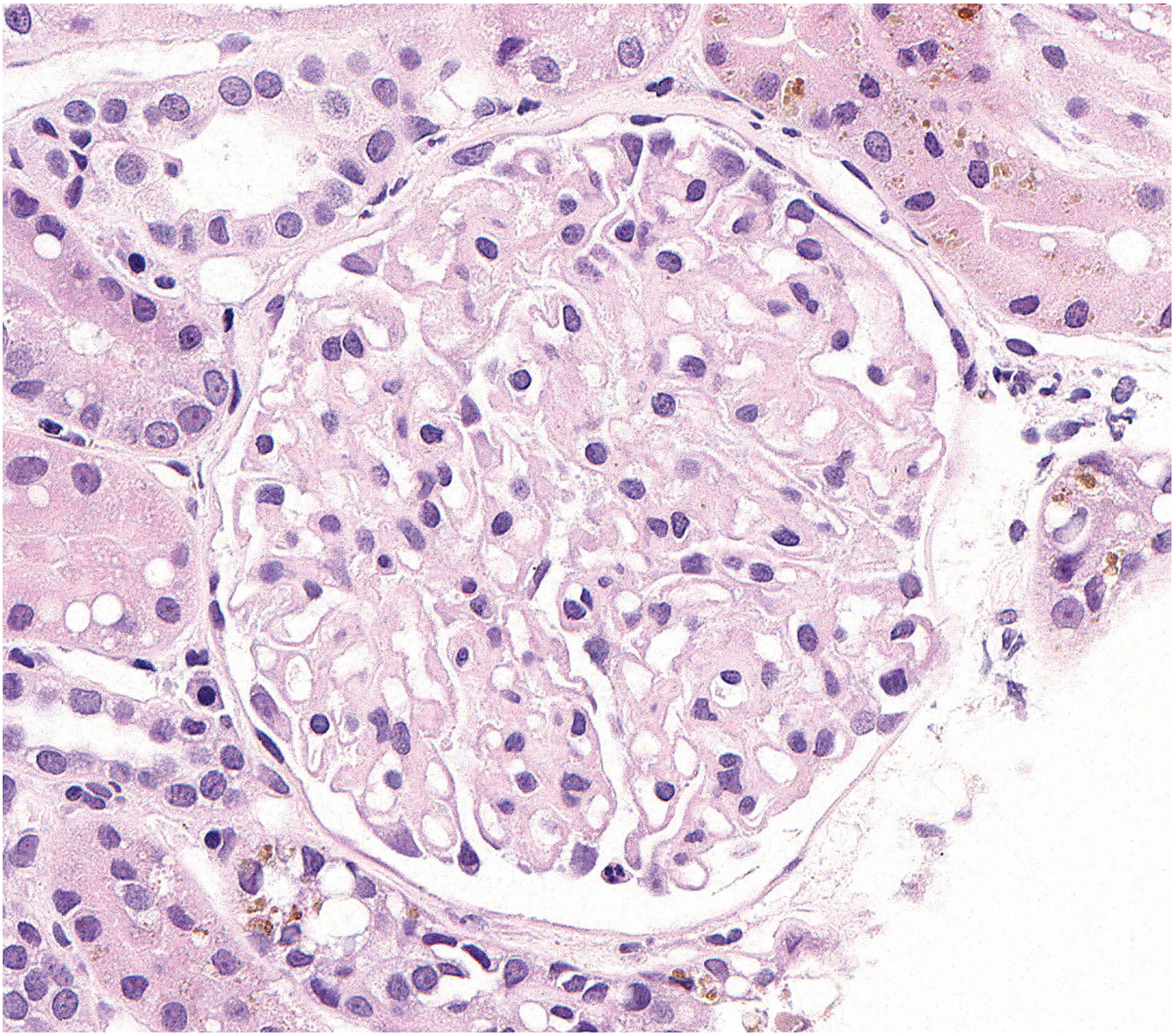

FIG.1A (HE): The glomerulus is normocellular. Some capillary walls appear slightly thickened; however, capillary wall thickness is better evaluated with PAS because the podocyte cytoplasm and GBM stain differently with this method.

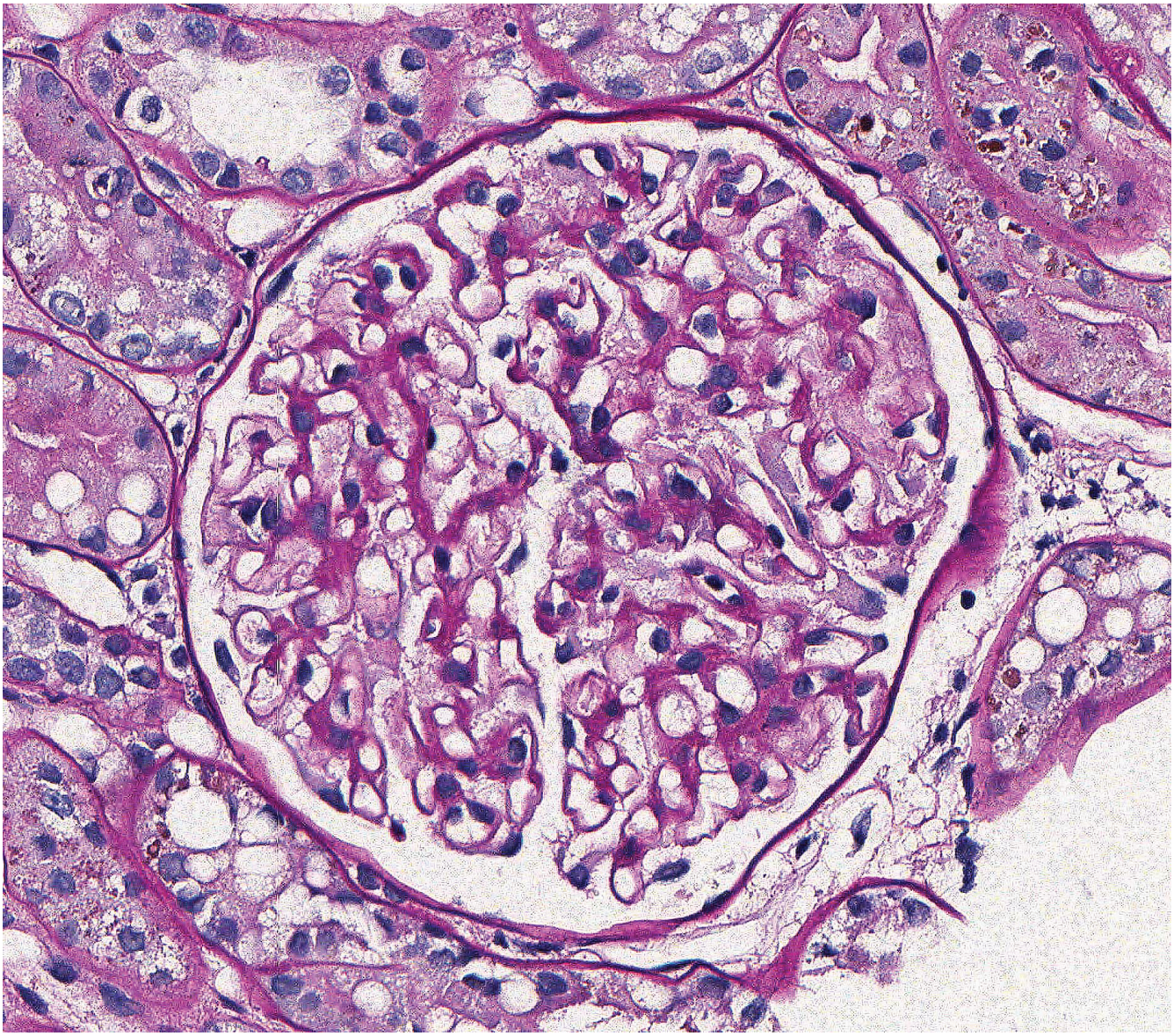

FIG.1B (PAS): The GBM, which is best evaluated in the peripheral capillary loops, is thin and has a smooth contour.

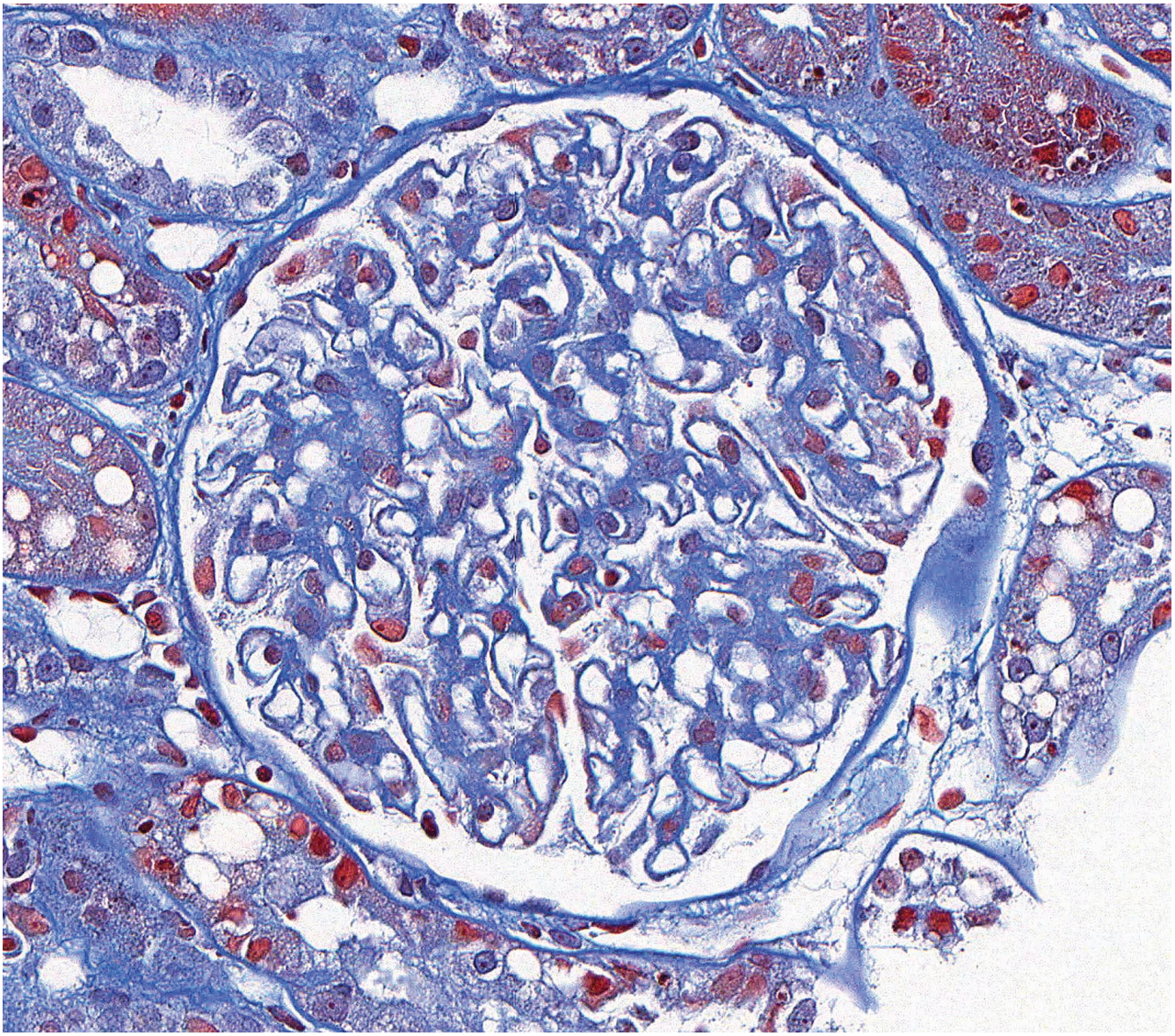

FIG.1C (MT): Fuchsinophilic (red) deposits are not observed.

FIG.1D (JMS): Capillary walls are of normal thickness; remodeling is not observed. There are pinpoint lucent foci on the *en face* surfaces of a few capillary walls (circled).

An interactive or media element has been excluded from this version of the text. You can view it online here:
https://ohiostate.pressbooks.pub/vetrenalpathatlas/?p=190

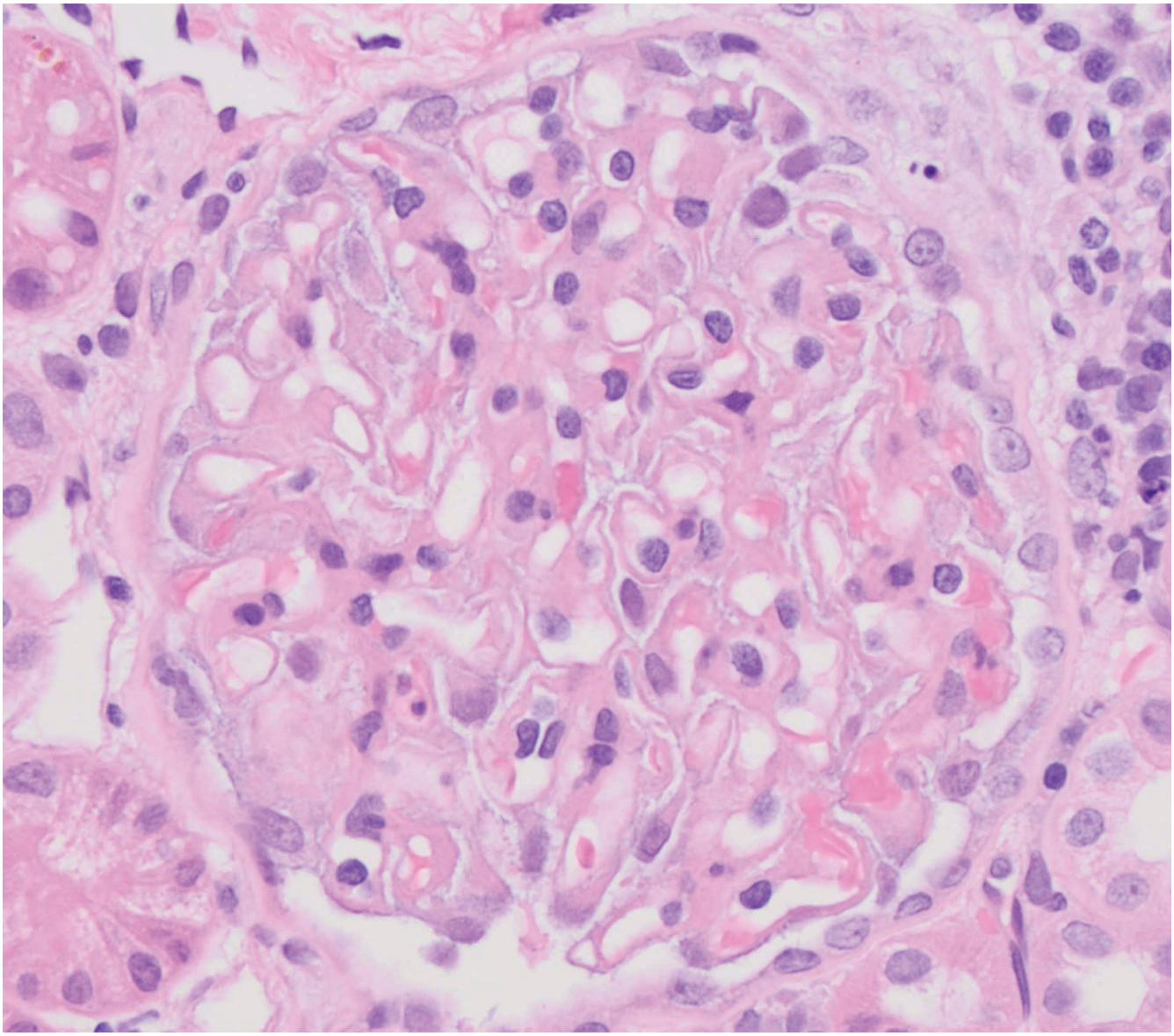

FIG.2A (HE): Podocytes are hypertrophied. The glomerulus is normocellular.

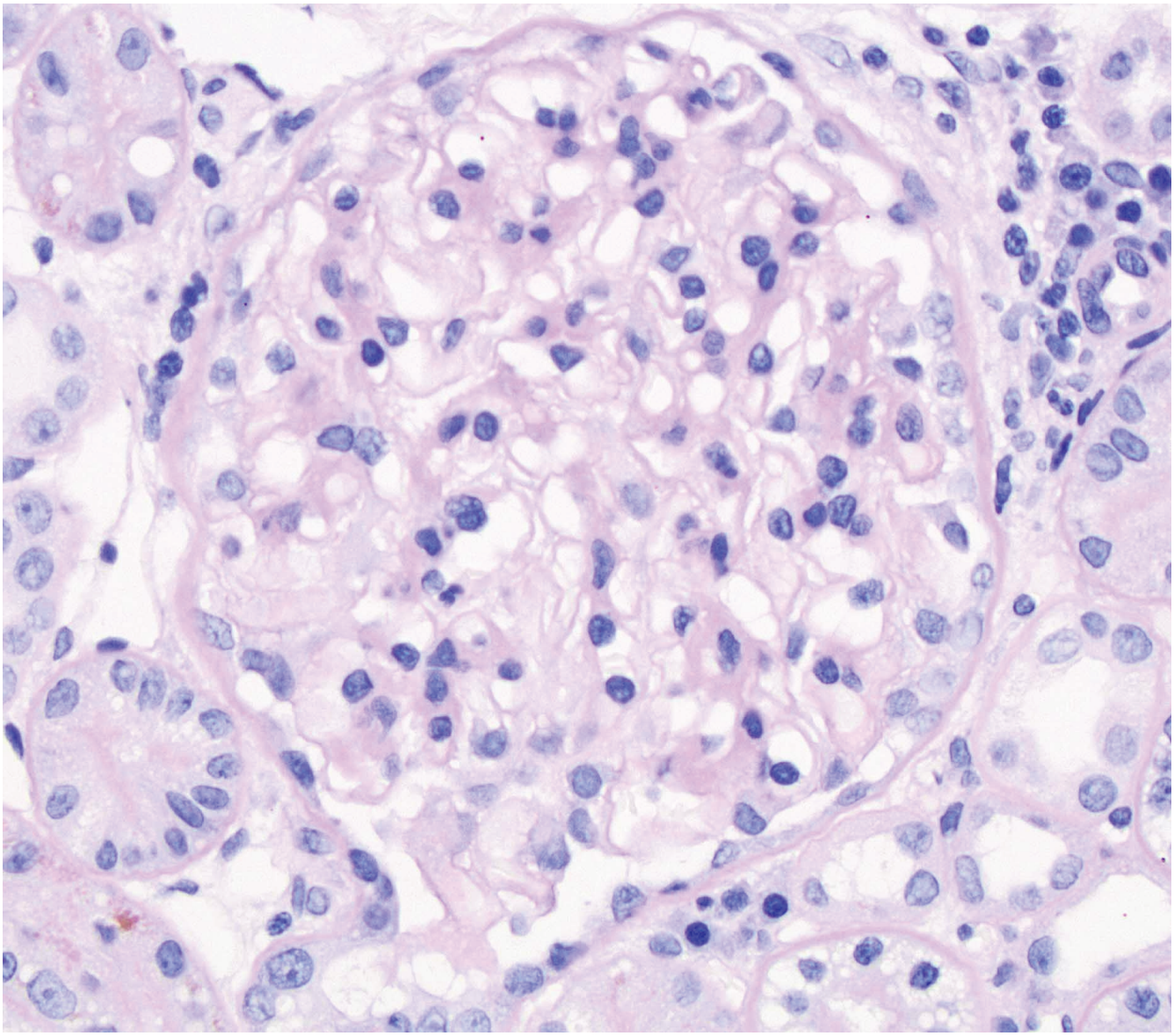

FIG.2B (PAS): GBM are mildly thickened, and the glomerulus is normocellular.

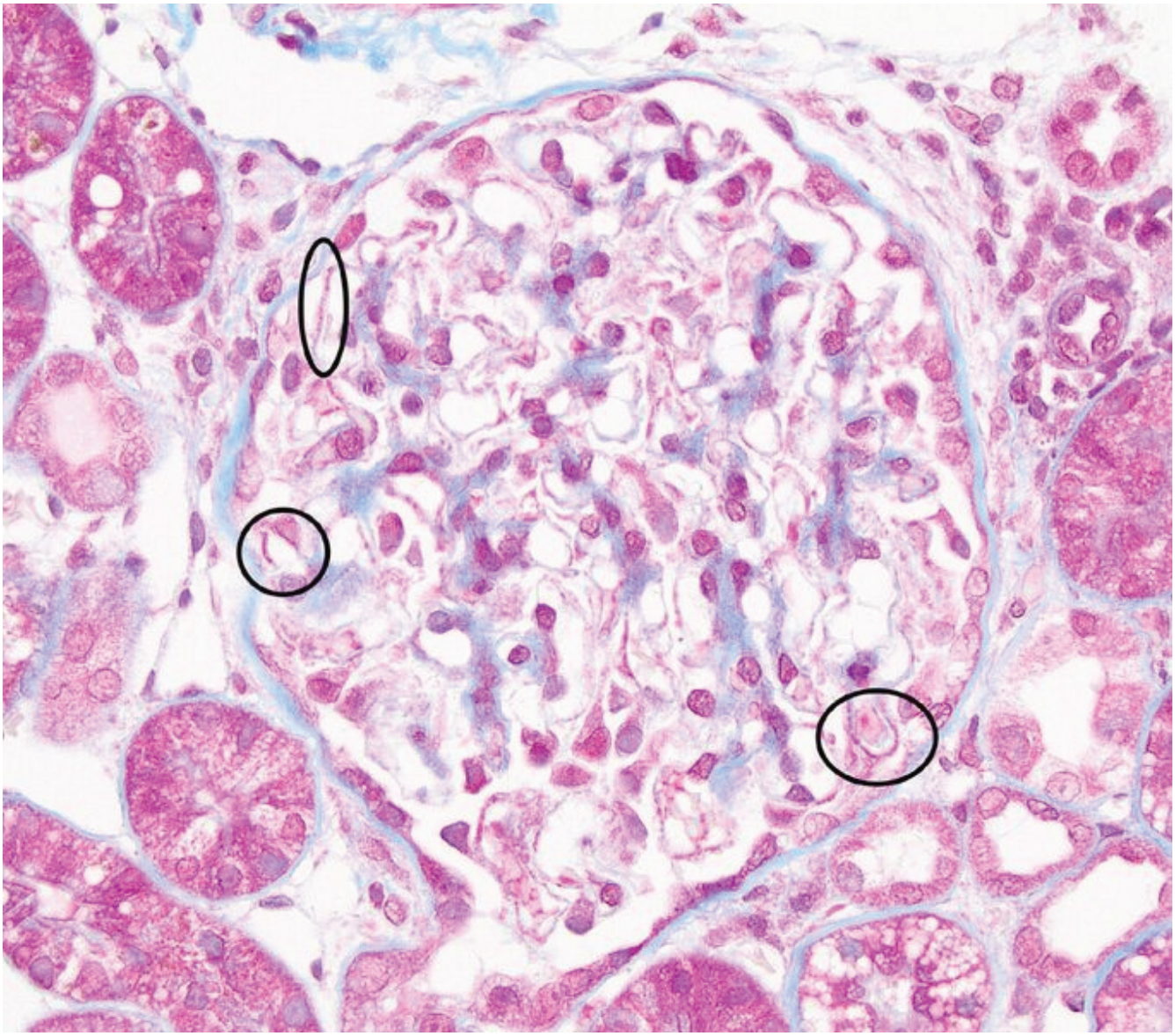

FIG.2C (MT): There are many capillary loops with discrete, small, fuchsinophilic nodules, which are consistent with immune deposits (circled).

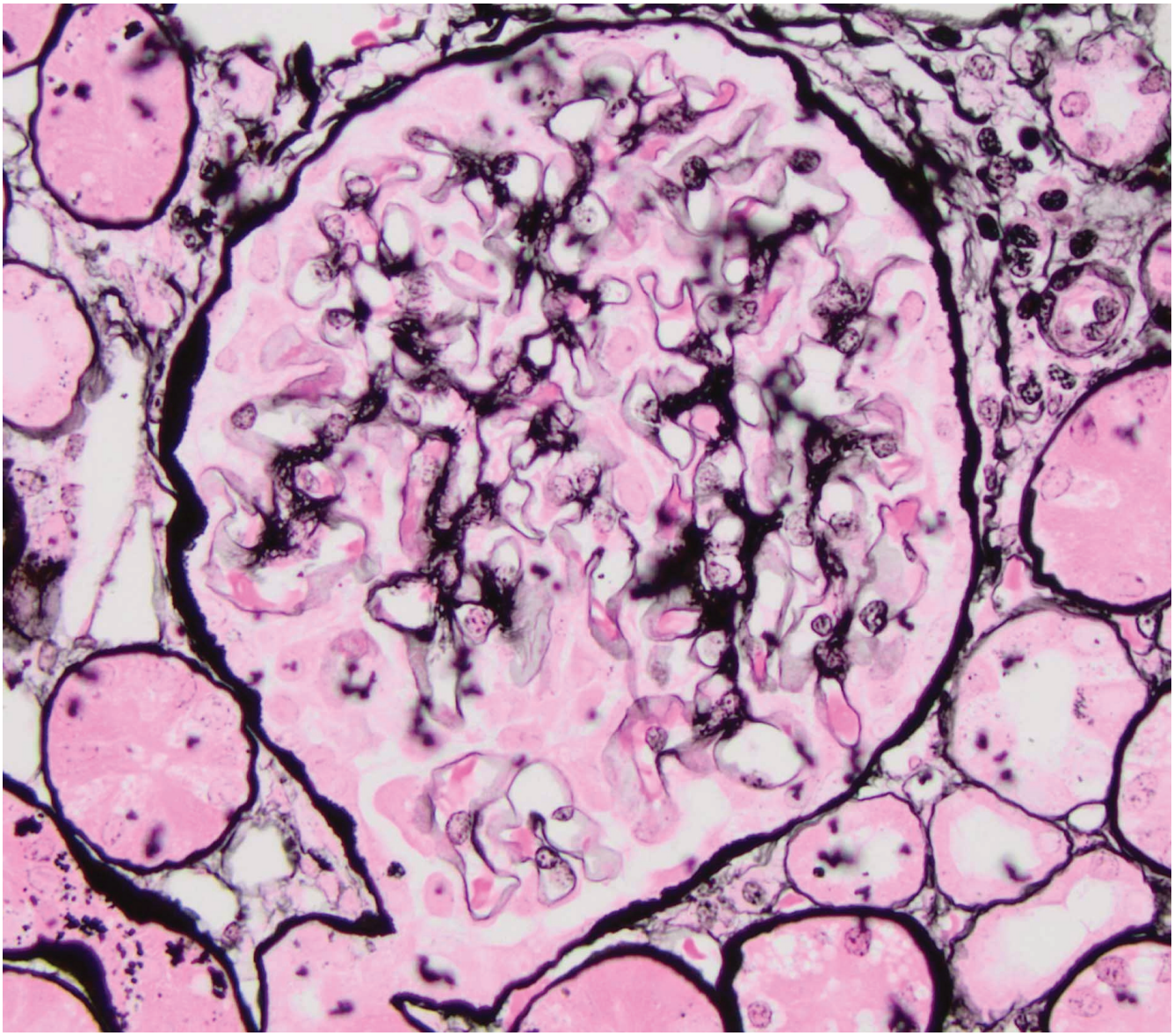

FIG.2D (JMS): The GBM appears normal. There is no evidence of GBM remodeling.

LATE MEMBRANOUS GLOMERULONEPHROPATHY: GBM remodeling is easily observed with LM.

An interactive or media element has been excluded from this version of the text. You can view it online here:
https://ohiostate.pressbooks.pub/vetrenalpathatlas/?p=190

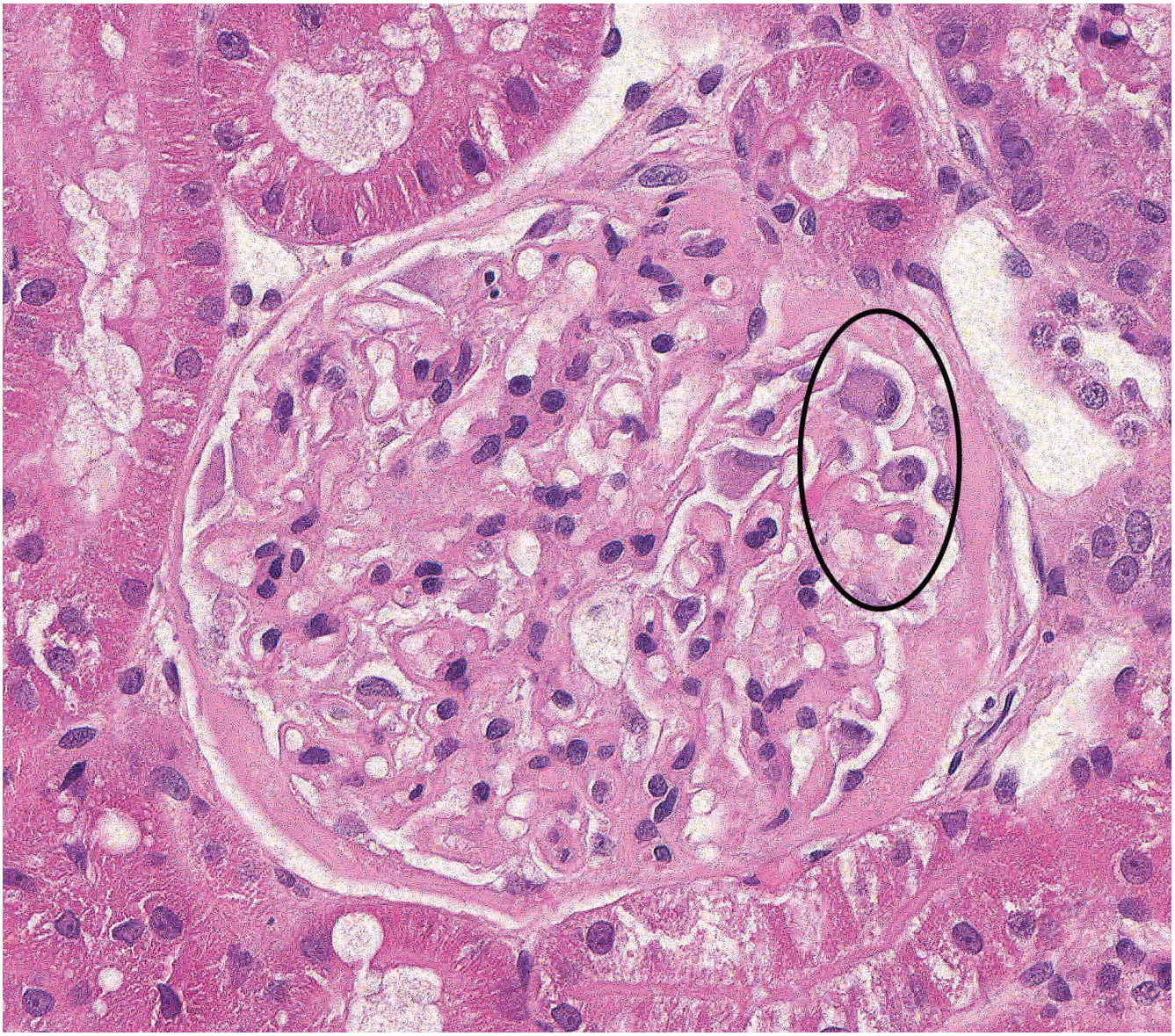

FIG.3A (HE): Most glomeruli have mild to moderately thickened capillary walls. In this glomerulus, there is also evidence of diffuse podocyte hypertrophy (circled) and a thickened Bowman's capsule.

FIG.3B (PAS): Glomeruli have mildly to moderately thickened capillary walls, and podocytes are often hypertrophic (arrow). There is a focal synechia (circled). Bowman's capsule basement membrane is expanded by insudated proteinaceous fluid (hyalinosis). Capillary lumens are open and endocapillary hypercellularity is not a feature.

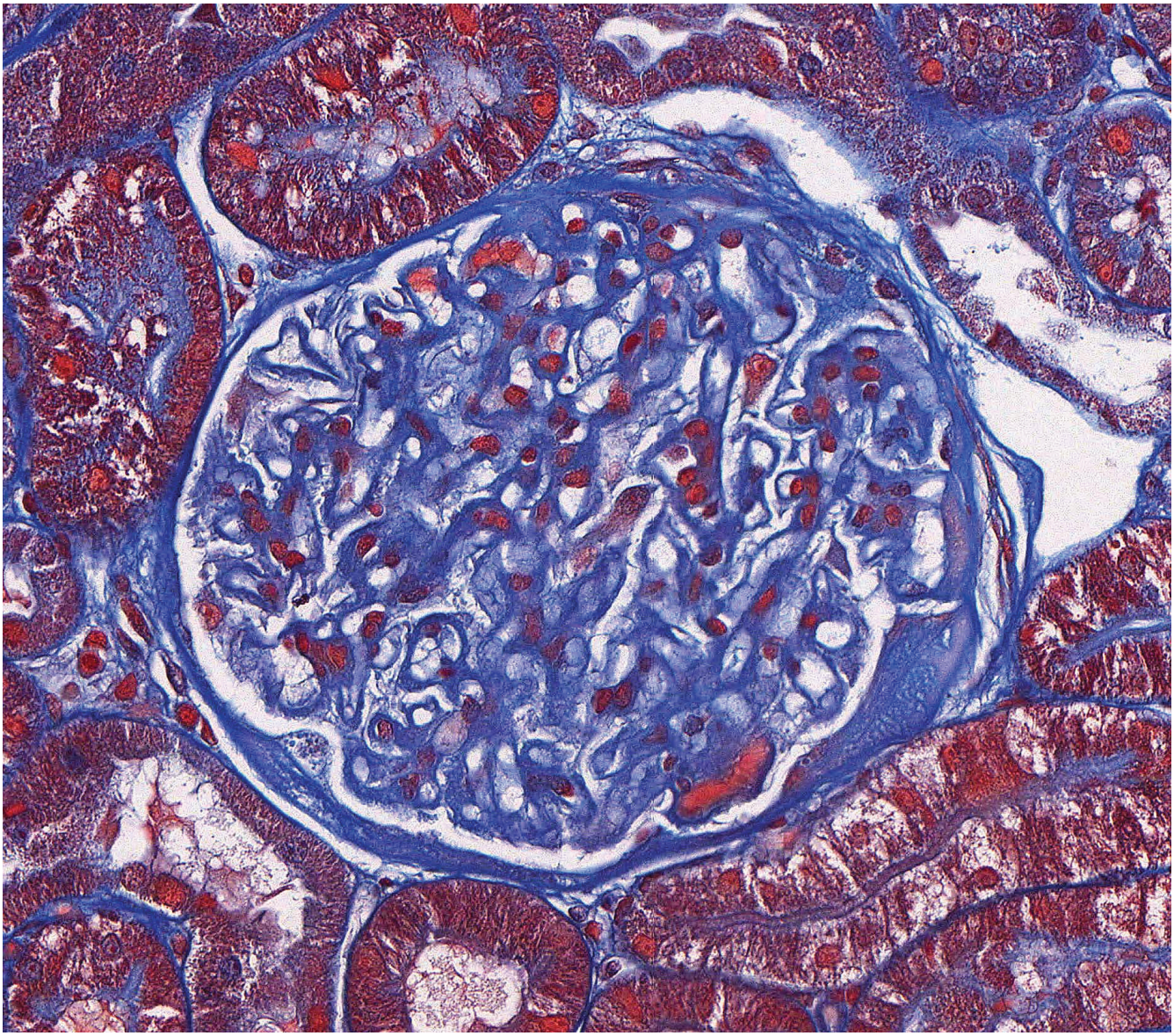

FIG.3C (MT): Glomeruli have mild to moderately thickened capillary walls. Fuchsinophilic deposits are not evident in this glomerulus but they might be present in other cases of late MGN. The thickened Bowman's capsule has a focus of pale peach hyalinosis.

FIG.3D (JMS): In the late stage of MGN, there are frequent spike-like projections and holes, indicative of GBM remodeling (circled).

ADVANCED MEMBRANOUS GLOMERULONEPHROPATHY: Immune complex deposits and/or GBM remodeling are obvious throughout most glomeruli. There is often secondary segmental sclerosis

An interactive or media element has been excluded from this version of the text. You can view it online here:
https://ohiostate.pressbooks.pub/vetrenalpathatlas/?p=190

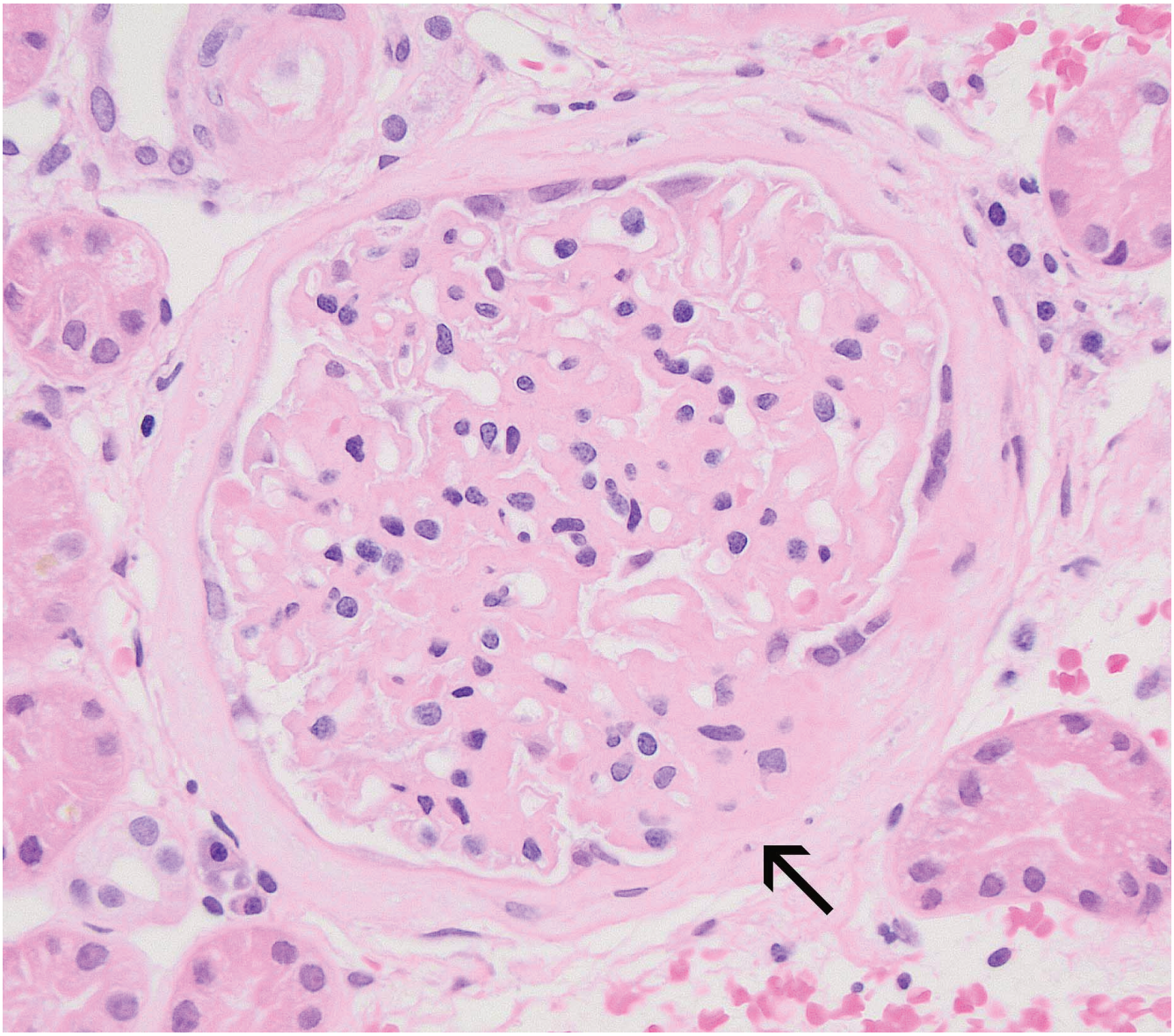

FIG.4A (HE): There is diffuse, marked thickening of the capillary walls. A broad synechia is present (arrow). There is thickening and splitting of Bowman's capsule basement membrane, both of which are non-specific lesions that can be seen with synechiae.

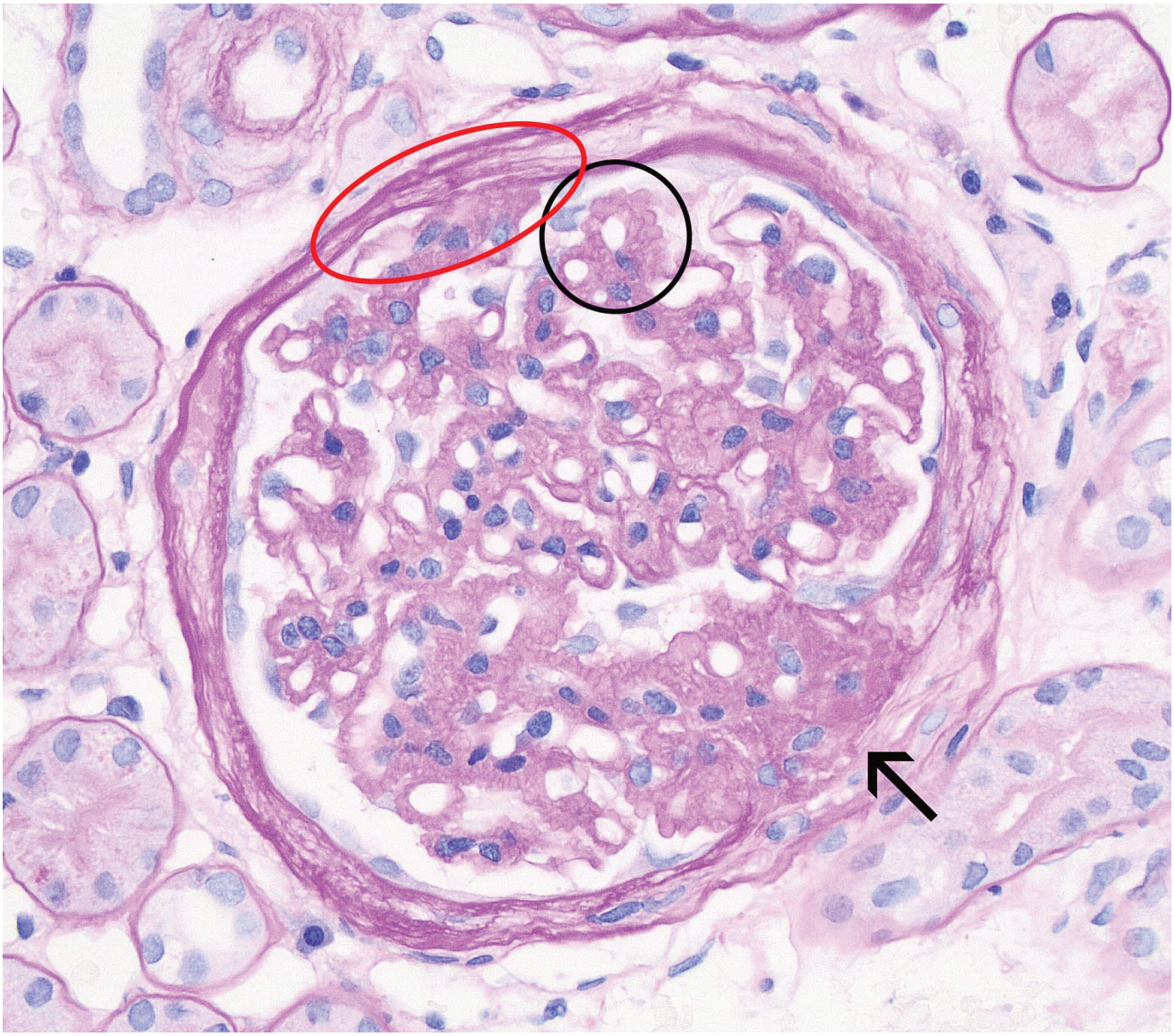

FIG.4B (PAS): There is global remodeling of the GBM (black circle), resulting in marked irregular nodularity of the abluminal (subepithelial surface). Synechia (red circle) and segmental sclerosis with associated synechia (arrow) are frequent at this stage.

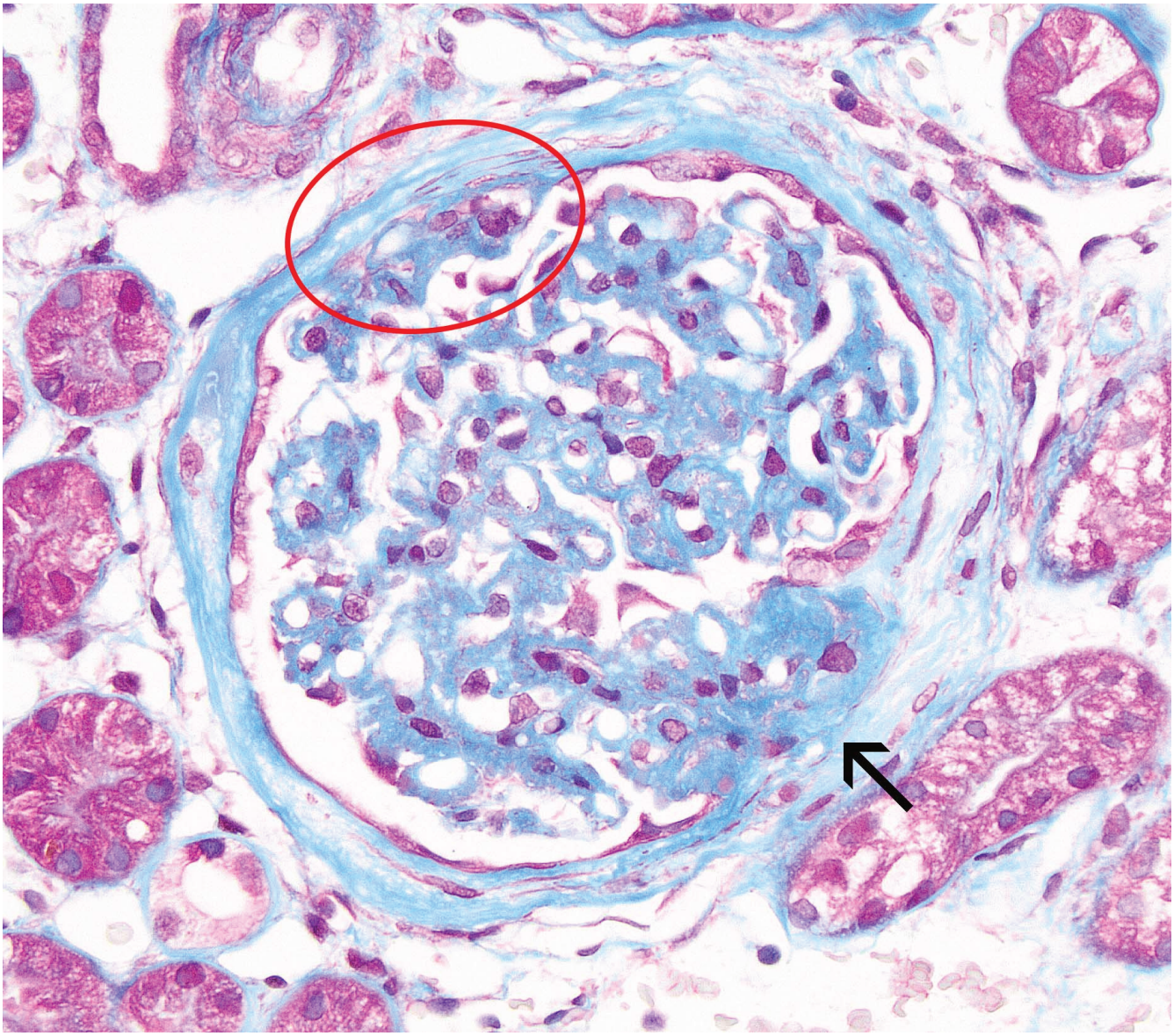

FIG.4C (MT): There is global marked remodeling of the GBM, predominantly affecting the abluminal (subepithelial surface). Synechia (red circle) and segmental sclerosis with associated synechia (arrow) are frequent at this stage. Fuchsinophilic deposits are not evident in this glomerulus but might be seen in other cases of Late MGN.

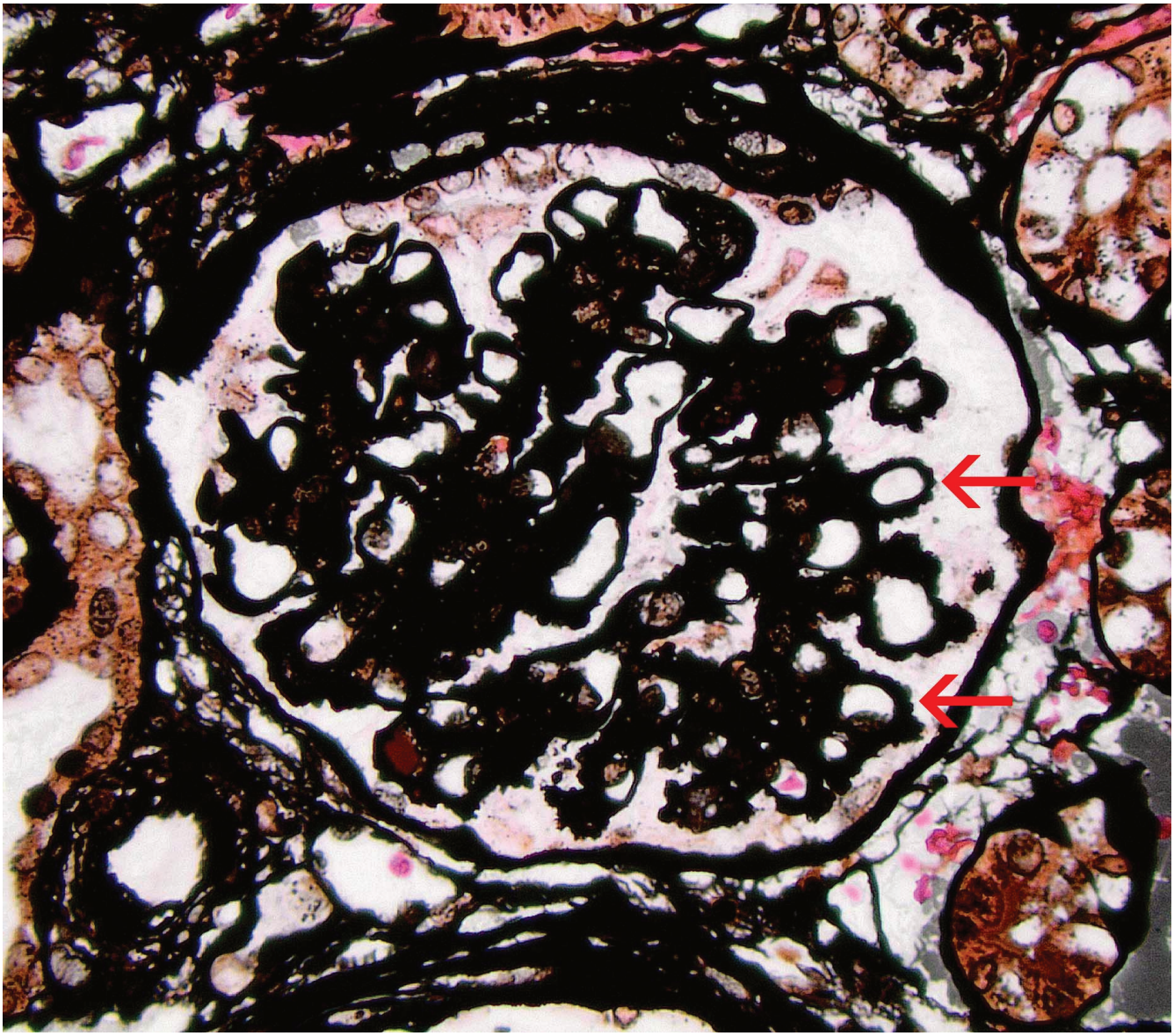

FIG.4D (JMS): The silver stain demonstrates striking knobby to spike-like projections on the subepithelial surface (arrows).

ADDITIONAL DIAGNOSTICS FOR MGN

An interactive or media element has been excluded from this version of the text. You can view it online here:
https://ohiostate.pressbooks.pub/vetrenalpathatlas/?p=190

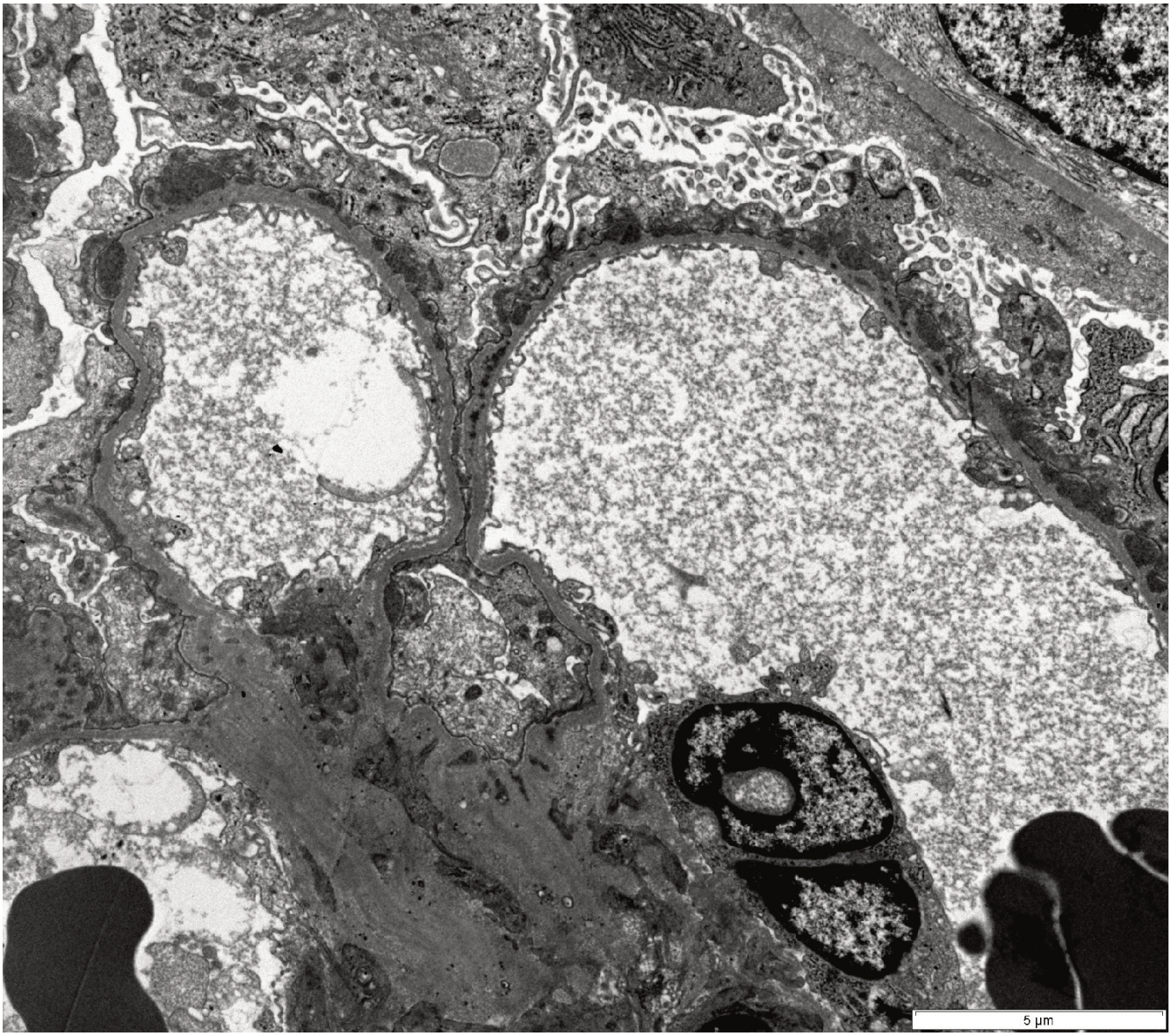

FIG. 5A (TEM): Numerous electron dense deposits are present on the subepithelial surface of the capillary loops.

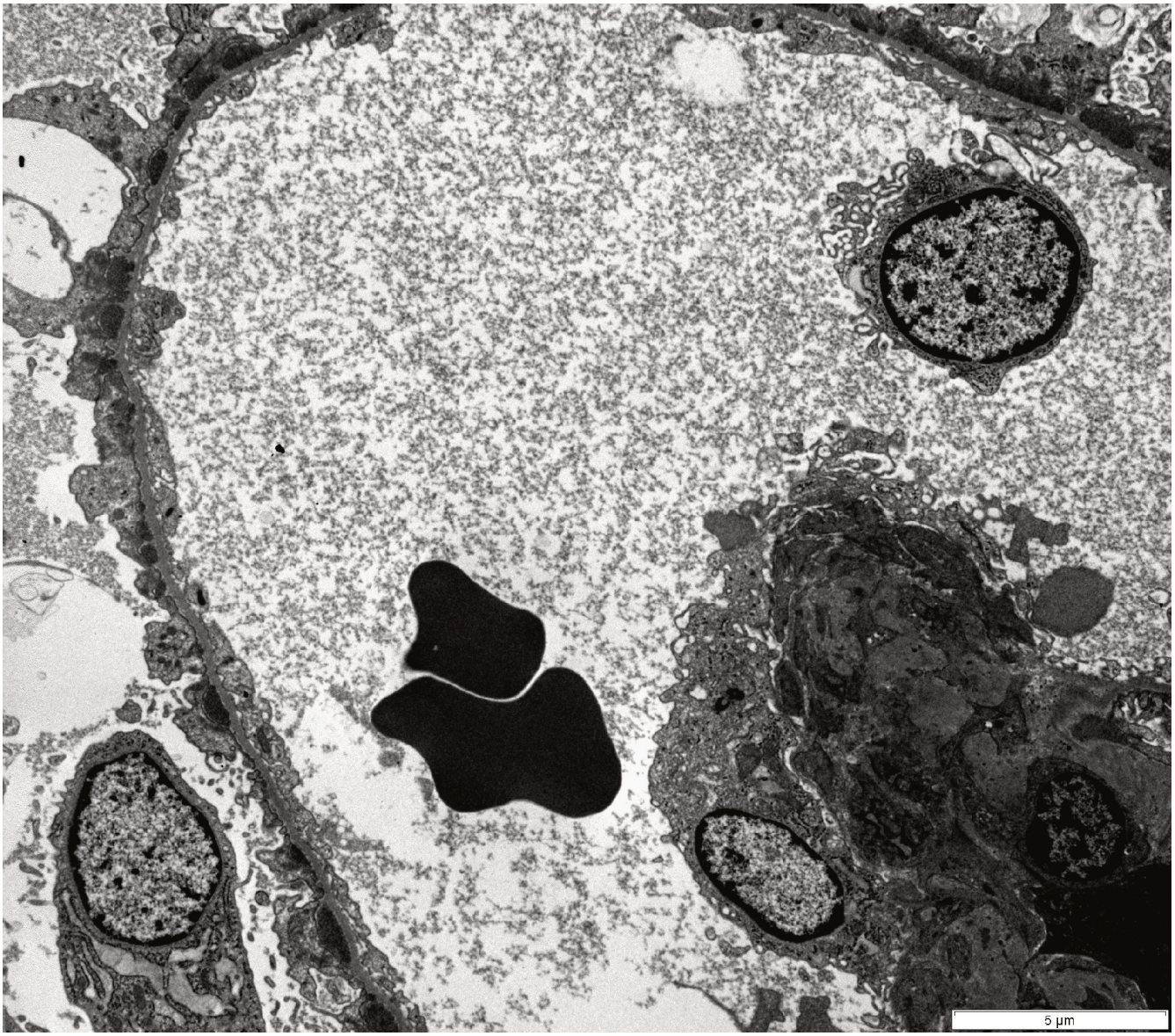

FIG. 5B (TEM): Numerous electron dense deposits are present on the subepithelial surface of the capillary loops and there is minimal remodeling of the GBM.

An interactive or media element has been excluded from this version of the text. You can view it online here:
https://ohiostate.pressbooks.pub/vetrenalpathatlas/?p=190

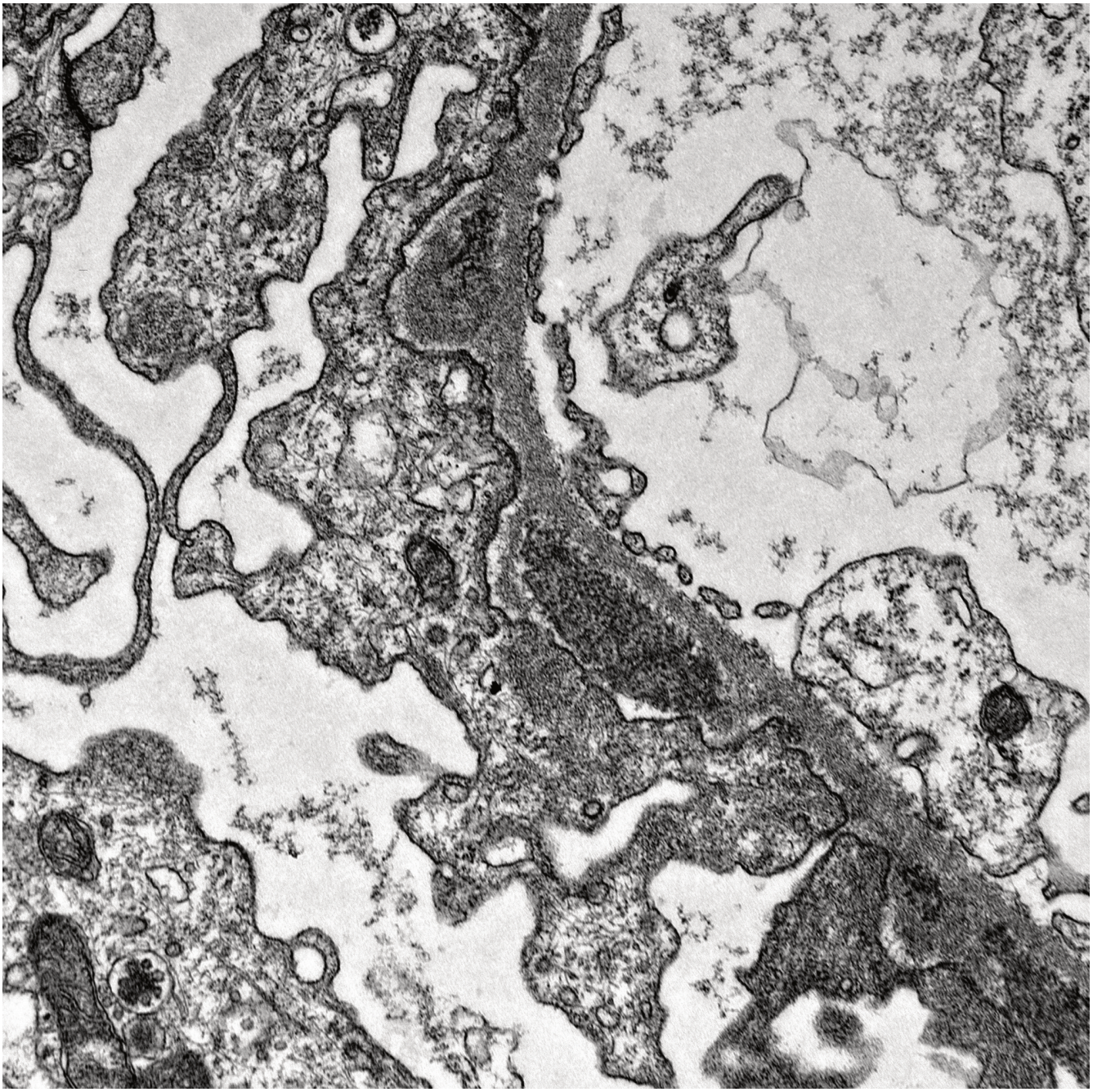

FIG. 5C (TEM): There are small spikes of GBM at each side of the electron dense deposit. Podocyte foot processes are globally effaced.

An interactive or media element has been excluded from this version of the text. You can view it online here:
https://ohiostate.pressbooks.pub/vetrenalpathatlas/?p=190

FIG. 5D (TEM): Colorized version of above TEM image. (Yellow: endothelial cell, Green: GBM, Pink: podocytes, Black: deposits)

An interactive or media element has been excluded from this version of the text. You can view it online here:
https://ohiostate.pressbooks.pub/vetrenalpathatlas/?p=190

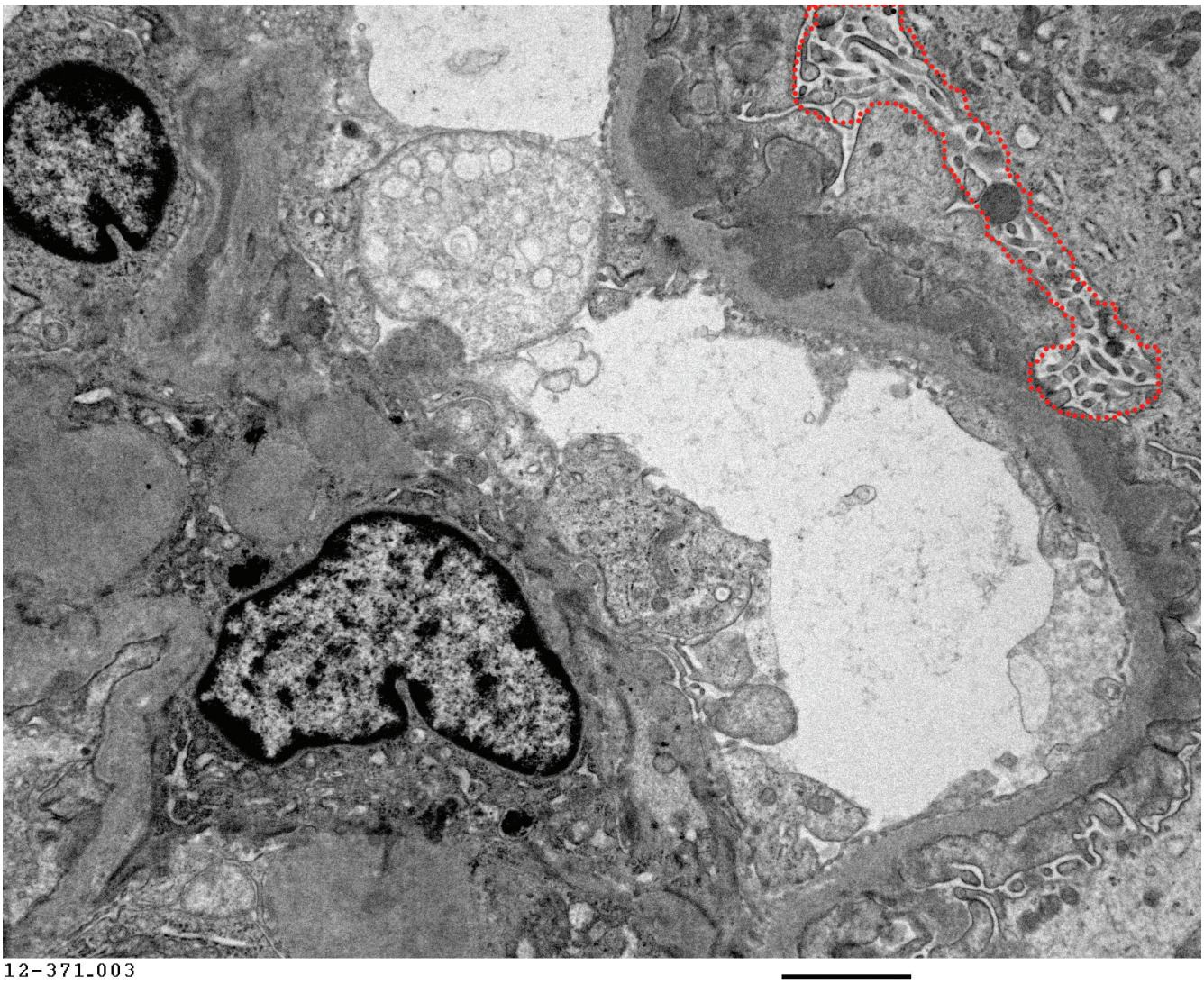

FIG. 5E (TEM): Many large electron dense deposits are along the subepithelial surface of the capillary wall. Podocyte foot processes are globally effaced and there is microvillus transformation of the cytoplasm (outlined with red dotted line).

An interactive or media element has been excluded from this version of the text. You can view it online here:
https://ohiostate.pressbooks.pub/vetrenalpathatlas/?p=190

FIG. 5F (TEM): Colorized version of above TEM image. (Yellow: endothelial cell, Green: GBM, Pink: podocyte, deposits are uncolored).

An interactive or media element has been excluded from this version of the text. You can view it online here:
https://ohiostate.pressbooks.pub/vetrenalpathatlas/?p=190

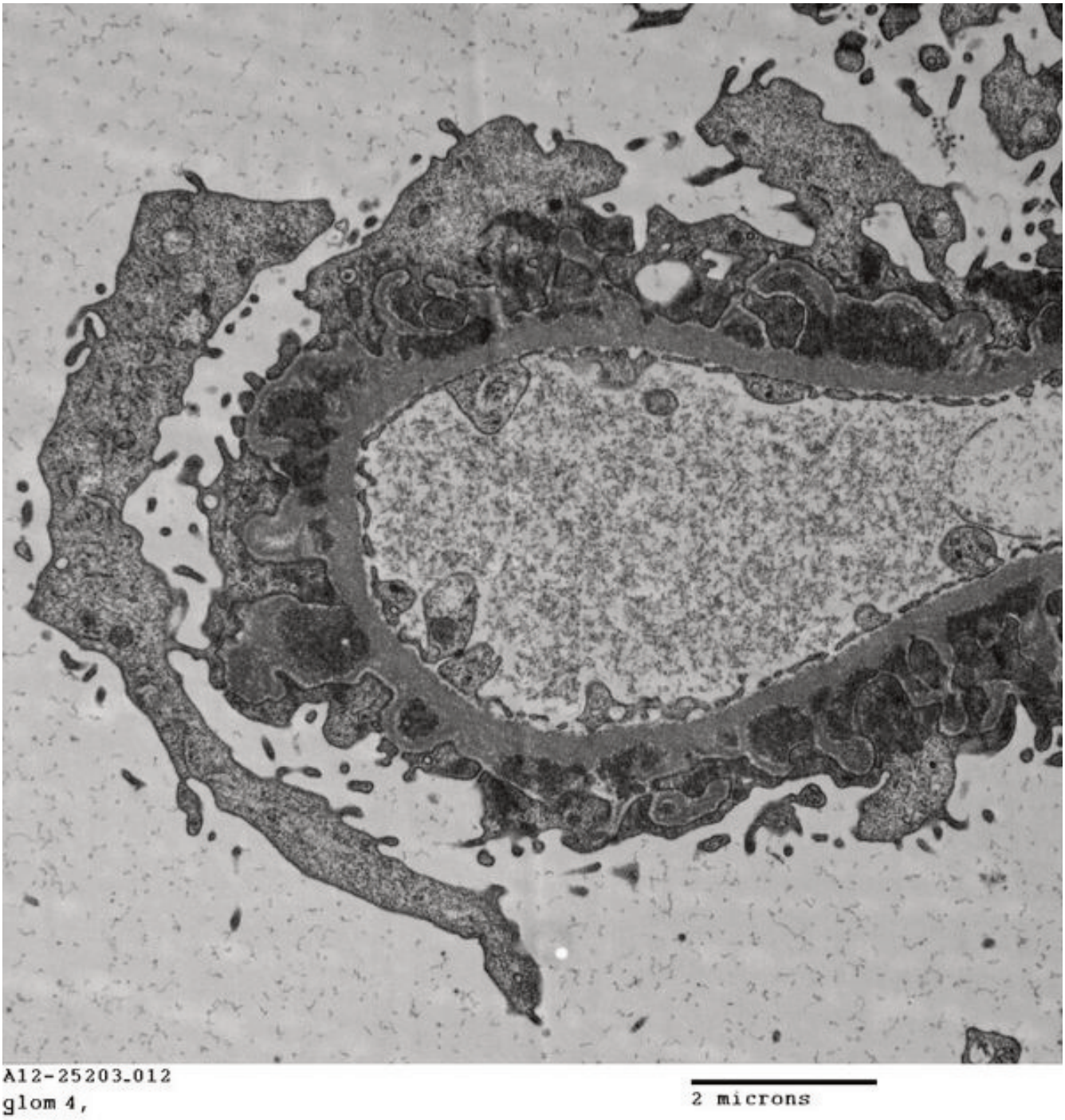

FIG. 5G (TEM): Late stage MGN with numerous encircled electron dense deposits. Podocyte foot processes are globally effaced. The capillary lumen is open and the endothelial cell maintains its fenestrations.

An interactive or media element has been excluded from this version of the text. You can view it online here:
https://ohiostate.pressbooks.pub/vetrenalpathatlas/?p=190

FIG.5H (TEM) Colorized version of above TEM image. (Yellow: endothelial cell, Green: GBM, Pink: podocyte, deposits are uncolored).

An interactive or media element has been excluded from this version of the text. You can view it online here:
https://ohiostate.pressbooks.pub/vetrenalpathatlas/?p=190

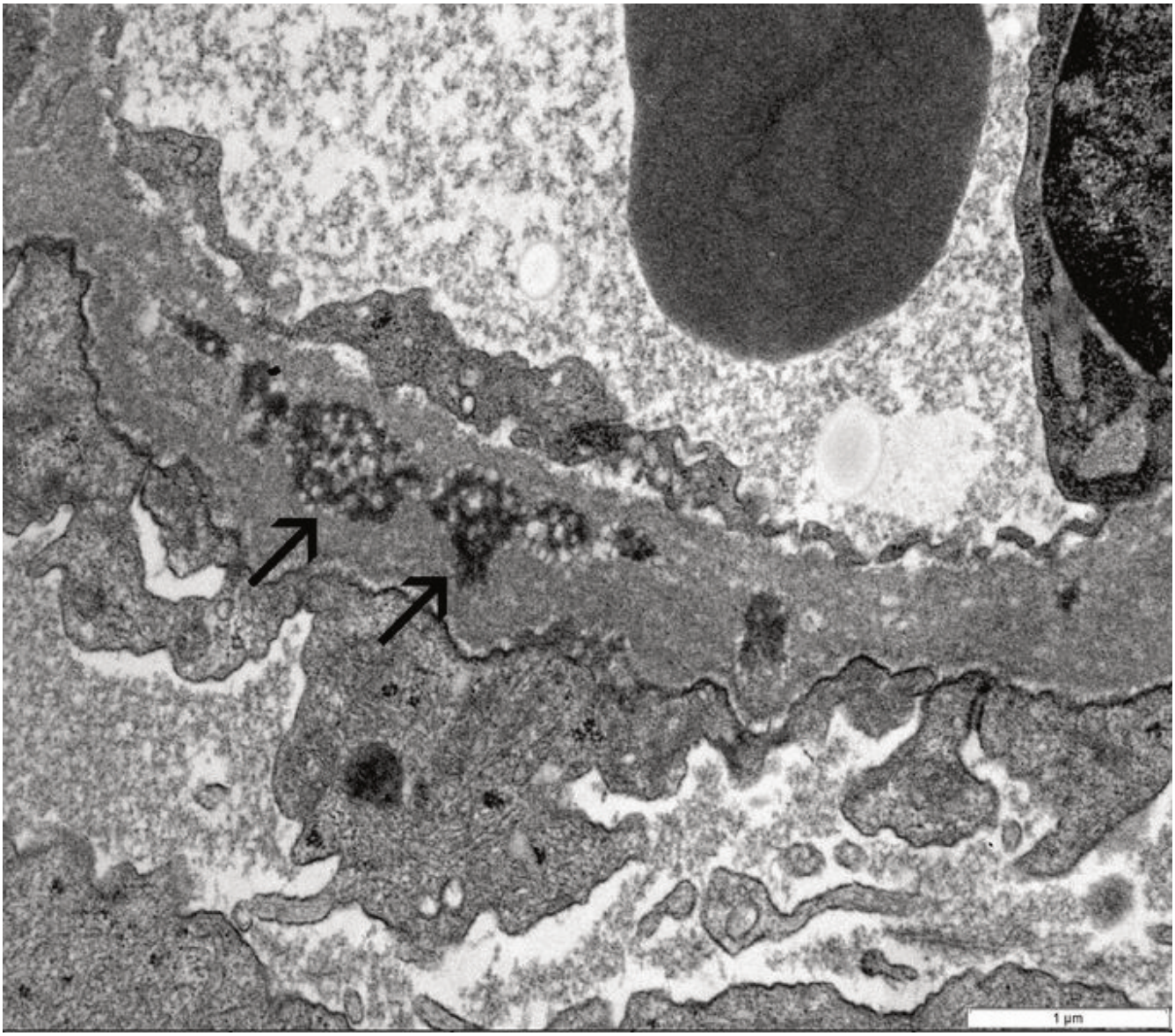

FIG.5I (TEM) Electron dense deposits are encircled by new GBM material and most deposits have a mottled appearance, indicative of resorption (arrows).

An interactive or media element has been excluded from this version of the text. You can view it online here:
https://ohiostate.pressbooks.pub/vetrenalpathatlas/?p=190

An interactive or media element has been excluded from this version of the text. You can view it online here:
https://ohiostate.pressbooks.pub/vetrenalpathatlas/?p=190

FIG.5K (TEM) Colorized version of above TEM image. (Yellow: endothelial cell, Green: GBM, Pink: podocyte, reabsorbed deposits are uncolored).

An interactive or media element has been excluded from this version of the text. You can view it online here:
https://ohiostate.pressbooks.pub/vetrenalpathatlas/?p=190

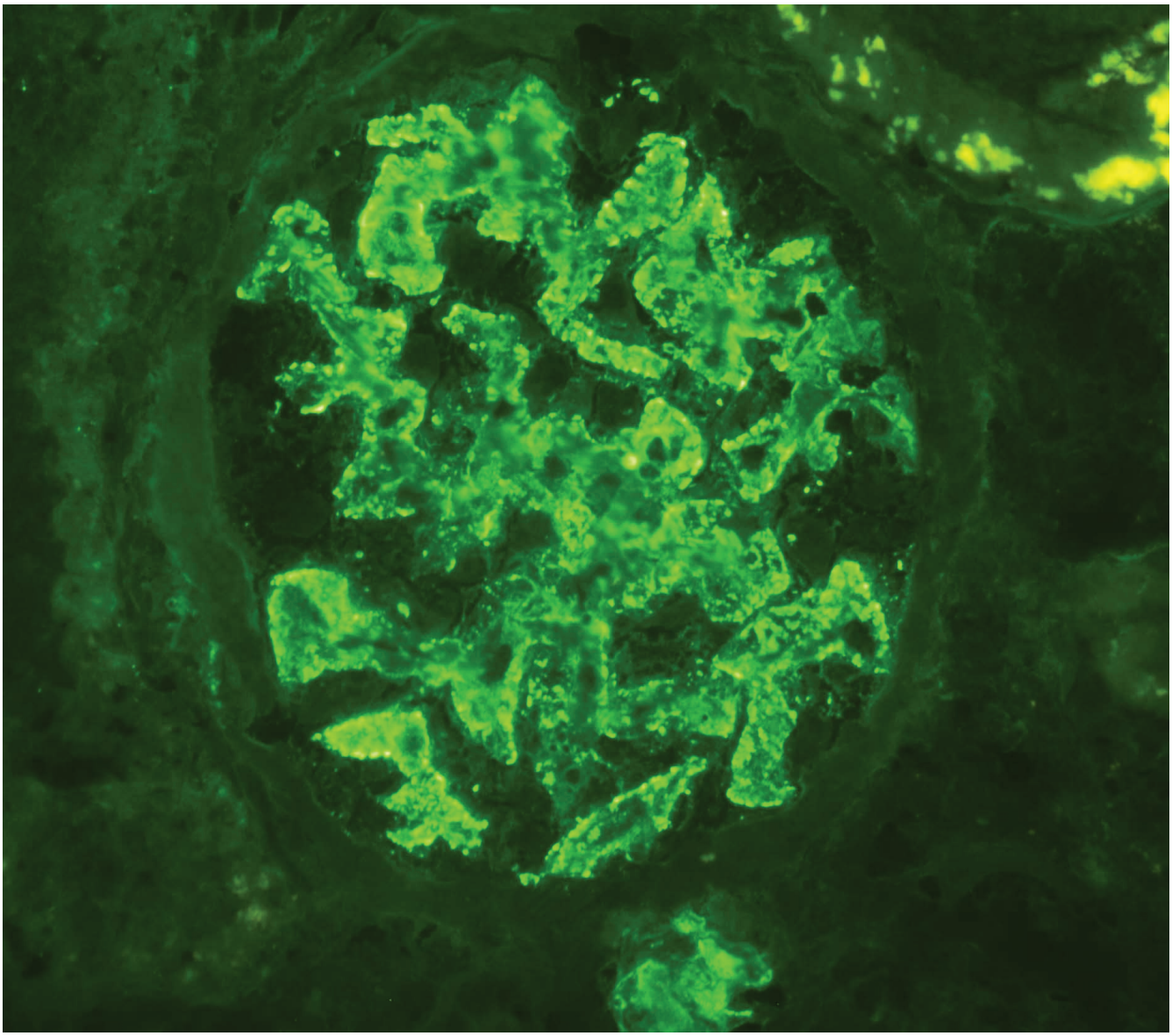

FIG.5L (IF for IgG): There is strong granular labeling along capillary loops.

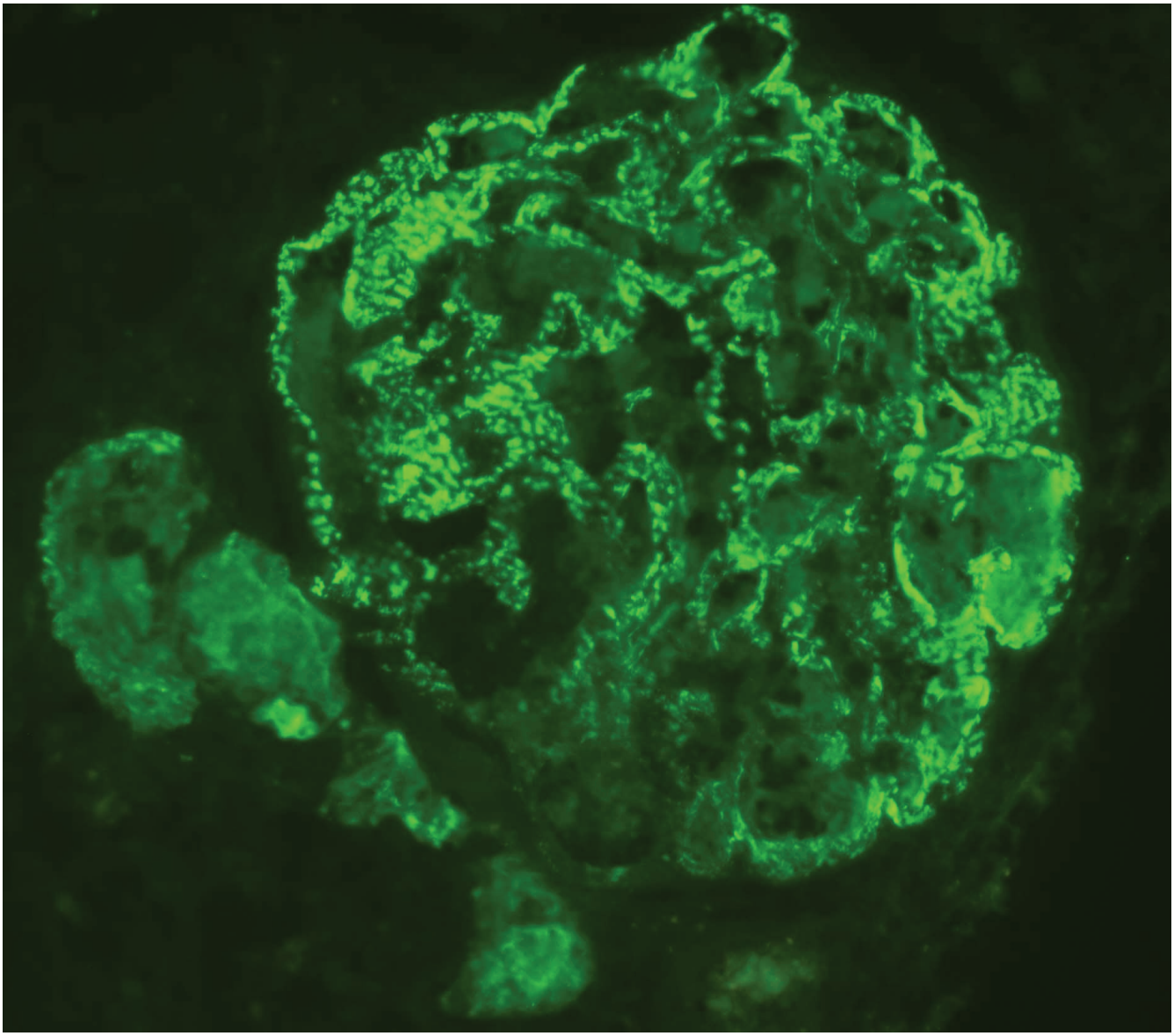

FIG.5M (IF for LLC): There is strong granular labeling along capillary loops.

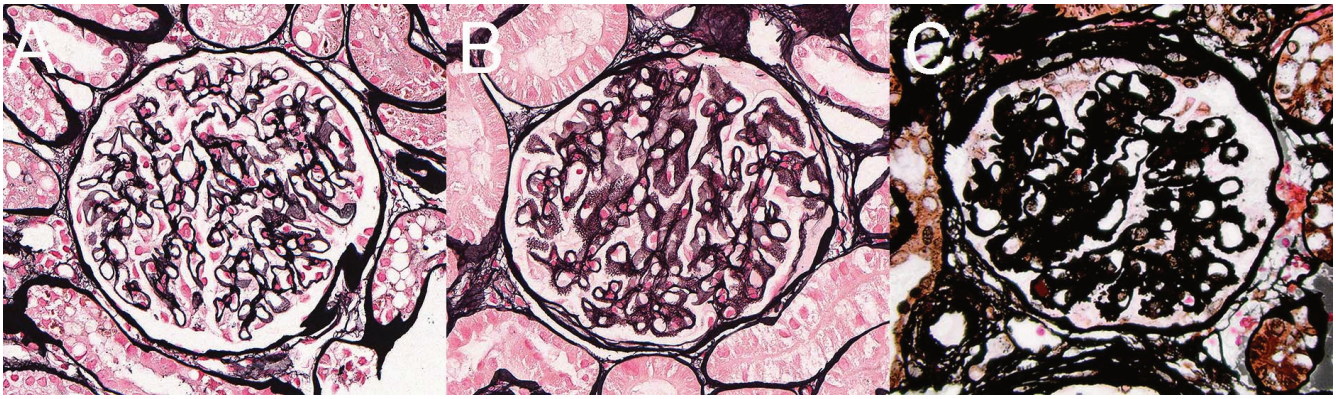

FIG.6 (Comparison panel of JMS): Glomeruli with early (A), late (B), and advanced (C) GBM

remodeling demonstrated by subepithelial spikes and holes on silver stain. These JMS stains are the same images as above (Figures 2D, 3D and 4D).

Differential Diagnoses for Early Membranous Glomerulonephropathy

Disease	Defining Histologic Features	Defining Ultrastructural Features
Early amyloidosis	Small deposits of amyloid are often missed by LM	7 – 11um fibrils
Podocytopathy	Might see podocyte hypertrophy and vacuolization	Diffuse podocyte injury which could include foot process effacement, microvillus transformation, and cytoplasmic vacuolar degeneration, no dense deposits
Unsampled FSGS	No GBM remodeling or thickening	Podocyte injury as above, occasional preservation of foot processes, no dense deposits

Differential Diagnoses for Late Membranous Glomerulonephropathy

Disease	Defining Histologic Features	Defining Ultrastructural Features
GBM disease	Thickened, irregular GBM	Irregular contours of GBM but no electron dense deposits
Focal Segmental Glomerulosclerosis	Segmental effacement of peripheral capillary loops by extracellular matrix	Podocyte foot process effacement; electron dense deposits are absent

Key Diagnostic Features of Immune complex-mediated membranous glomerulonephropathy

- GBM remodeling such as subepithelial spikes and holes (best visualized with silver stain) with or without fuchsinophilic deposits.
- Presence of subepithelial immune complex deposits with MT (fuchsinophilic nodules).
- Requires silver stain, PAS, MT, IF and/or EM for diagnosis
- Early MGN can have minimal lesions on LM.

Membranoproliferative Glomerulonephritis

- Membranoproliferative glomerulonephritis (MPGN) is a type of glomerular injury caused by immune-complex deposition on the luminal (subendothelial) surfaces of capillary walls and the resultant inflammatory response.
    - Immune complex deposits are composed of mainly IgG and antigen. The source of the antigen is often suspected to be exogenous (associated with an infection). In some cases, the antigen might be endogenous.
    - Immune complex deposits activate the complement system, which attracts inflammatory cells resulting in a hypercellular appearance of the glomerular tuft.
- Histologic appearance – Endocapillary hypercellularity (within capillary lumens) and thickening of glomerular capillaries by the immune complex deposits or by GBM remodeling.
    - Endocapillary hypercellularity can be due to circulating leukocytes, endothelial cell hypertrophy, and / or interposed mesangial cells within the capillary that encroach upon or obliterate the lumen. Increased cellularity is most often diffuse, but can be segmental or global.
    - Capillary wall remodeling is characterized by double contours of the GBM, best visualized with JMS.
    - Other lesions that might accompany MPGN include glomerular synechiae, hyalinosis, crescents, presence of pyknotic debris, as well as periglomerular inflammation and fibrosis.

TEM and IF are needed to identify the presence of immune complex deposits and are needed to differentiate MPGN from other types of membranoproliferative *patterns* of glomerular injury. These patterns have similar histologic appearances but lack definitive evidence of immune complex deposition.

Clinical Features of Membranoproliferative Glomerulonephritis (MPGN)

The most consistent initial clinical feature of MPGN is the presence of moderate to marked proteinuria (typically UPC > 2); however, the constellation of clinical findings is often more severe in dogs with MPGN vs. other categories of glomerular disease, with azotemia and hypertension often being present. Rare cases can have a UPC as low as 0.5.

Other common clinical findings include low antithrombin activity, hypercholesterolemia, and edema/ ascites.

Dogs with ICGN frequently retain adequate concentrating ability.

MPGN may be associated with infections, such as Leishmaniasis and Lyme nephritis.

Dogs <1 year of age are unlikely to have MPGN.

Beagles have been reported to have familial MPGN.

COMMENTS REGARDING THE MEMBRANOPROLIFERATIVE PATTERN

- One element of evaluating (and reporting) the pathologic findings for glomerular disease is assessing (and describing) the severity and / or "stage" of the disease process within the glomerulus.
- For some patterns of glomerular injury, the severity of the glomerular lesions is largely a function of the features exhibited along a temporally linear dimension of pathologic changes. In amyloidosis for example, severity is mainly a function of the amount of amyloid deposition within the glomeruli and the degree to which glomerular capillary lumens are occluded. In membranous GN, as another example, severity is mainly assessed by the degree of GBM remodeling induced by the presence of immune-complex deposits.
- In contrast, in the MPGN pattern, lesion progression is not straightforward. The lesions are dependent on the duration/magnitude of immune complex deposition and the severity of the resultant inflammatory response (inflammatory cells and inflammatory mediators). Features that should be assessed include:
    - Hypercellularity – this dimension involves the number, location, and types of cells that are present in the glomeruli in excess of what is expected in normal glomeruli, as well as evidence of cellular injury (eg, pyknotic debris).
    - Capillary wall remodeling – this dimension involves the degree and extensiveness of changes in the structures that compose the peripheral capillary wall; namely wall thickening, double contours of the GBM, cellular interpositioning.
    - Sclerosis – this dimension involves the degree and extent of changes that are thought to be irreversible, namely synechia, and segmental or global sclerosis.

An interactive or media element has been excluded from this version of the text. You can view it online here:
https://ohiostate.pressbooks.pub/vetrenalpathatlas/?p=296

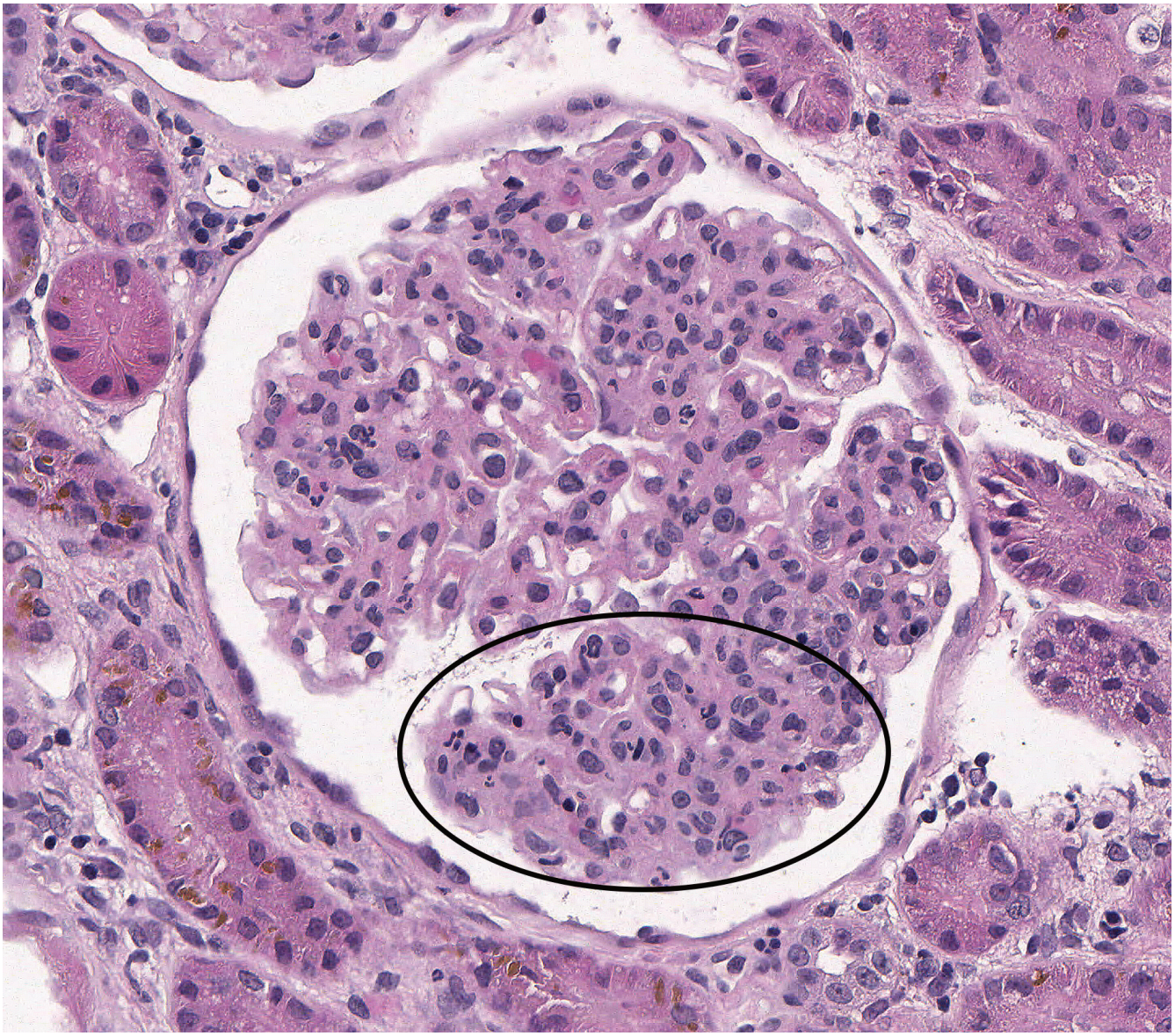

FIG.1A (HE): Active MPGN: Capillary lumens are frequently narrow or indistinct due to increased cellularity which includes endothelial hypertrophy as well as many circulating neutrophils (circled).

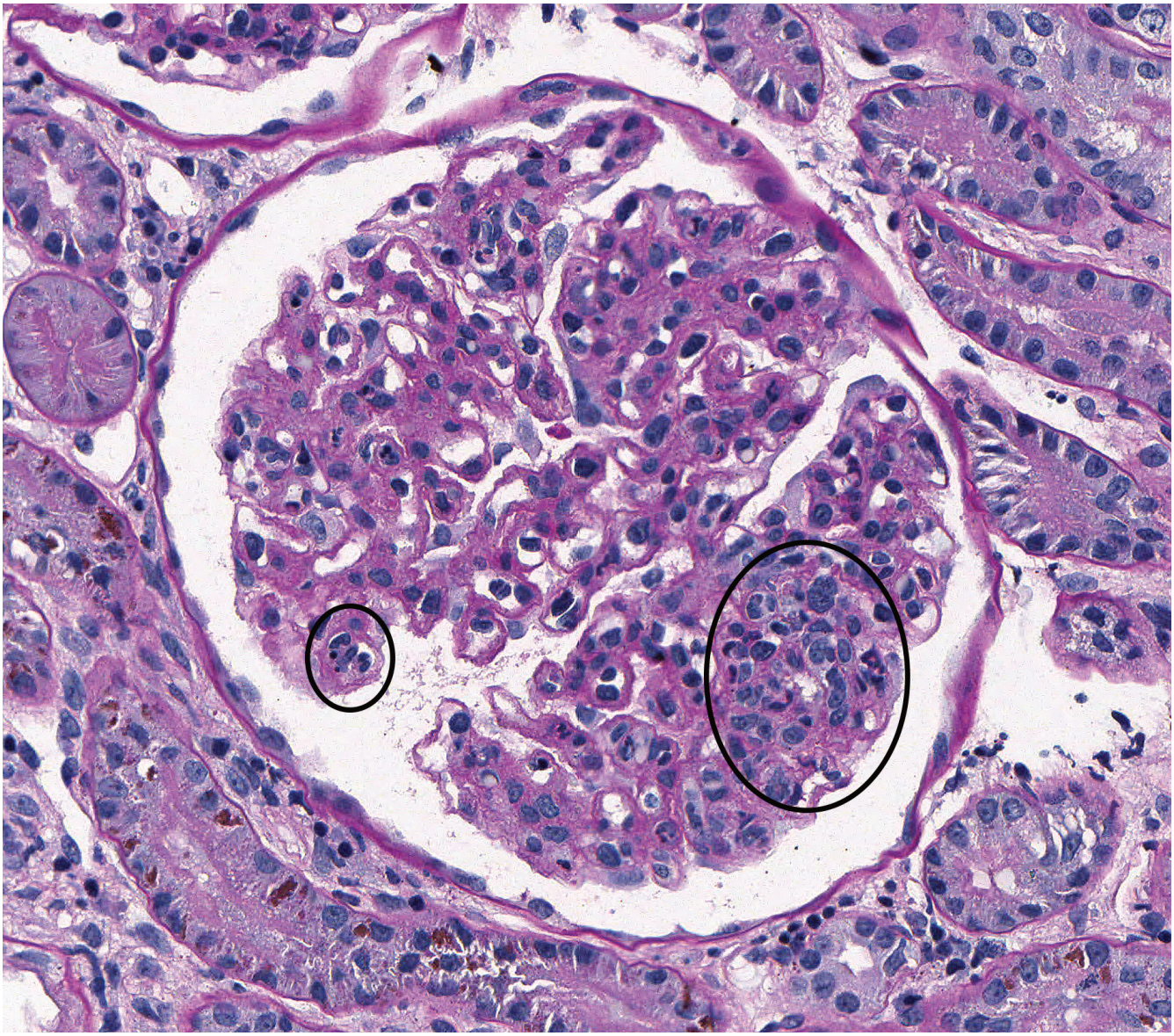

FIG.1B (PAS): Active MPGN: Segmentally, capillary lumens are obscured by increased cellularity. Contributors to hypercellularity include circulating leukocytes [neutrophils (small circle) and mononuclear cells], hypertrophied endothelium and increased numbers of mesangial cells (large circle).

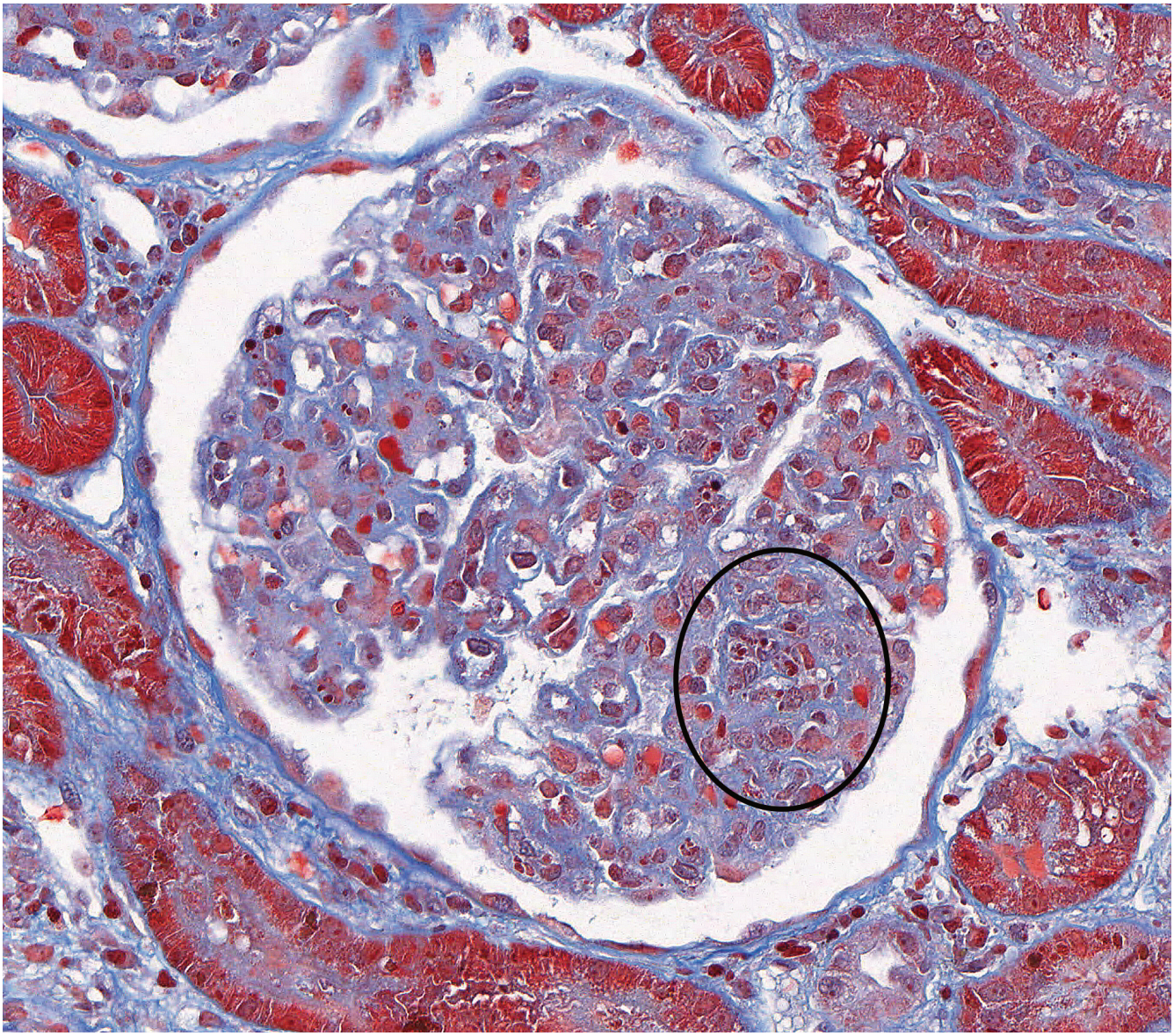

FIG.1C (MT): Active MPGN: Segmental hypercellularity (circled) with absence of periglomerular fibrosis and glomerulosclerosis are observed.

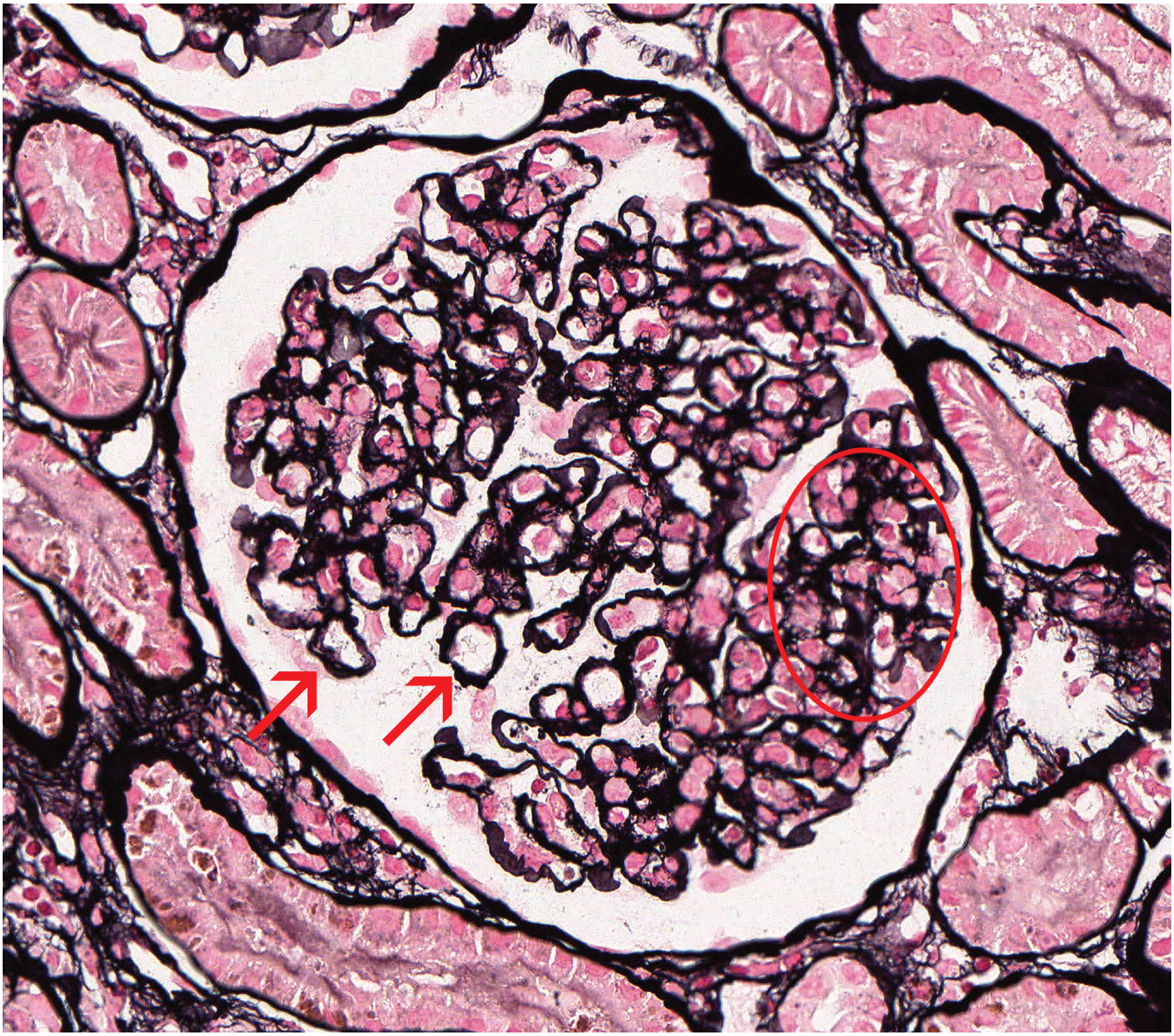

FIG.1D (JMS): Active MPGN: In addition to hypercellularity (circled), the JMS stain shows segmental GBM remodeling which is characterized by uneven inner and outer contours of the GBM (arrows).

An interactive or media element has been excluded from this version of the text. You can view it online here:
https://ohiostate.pressbooks.pub/vetrenalpathatlas/?p=296

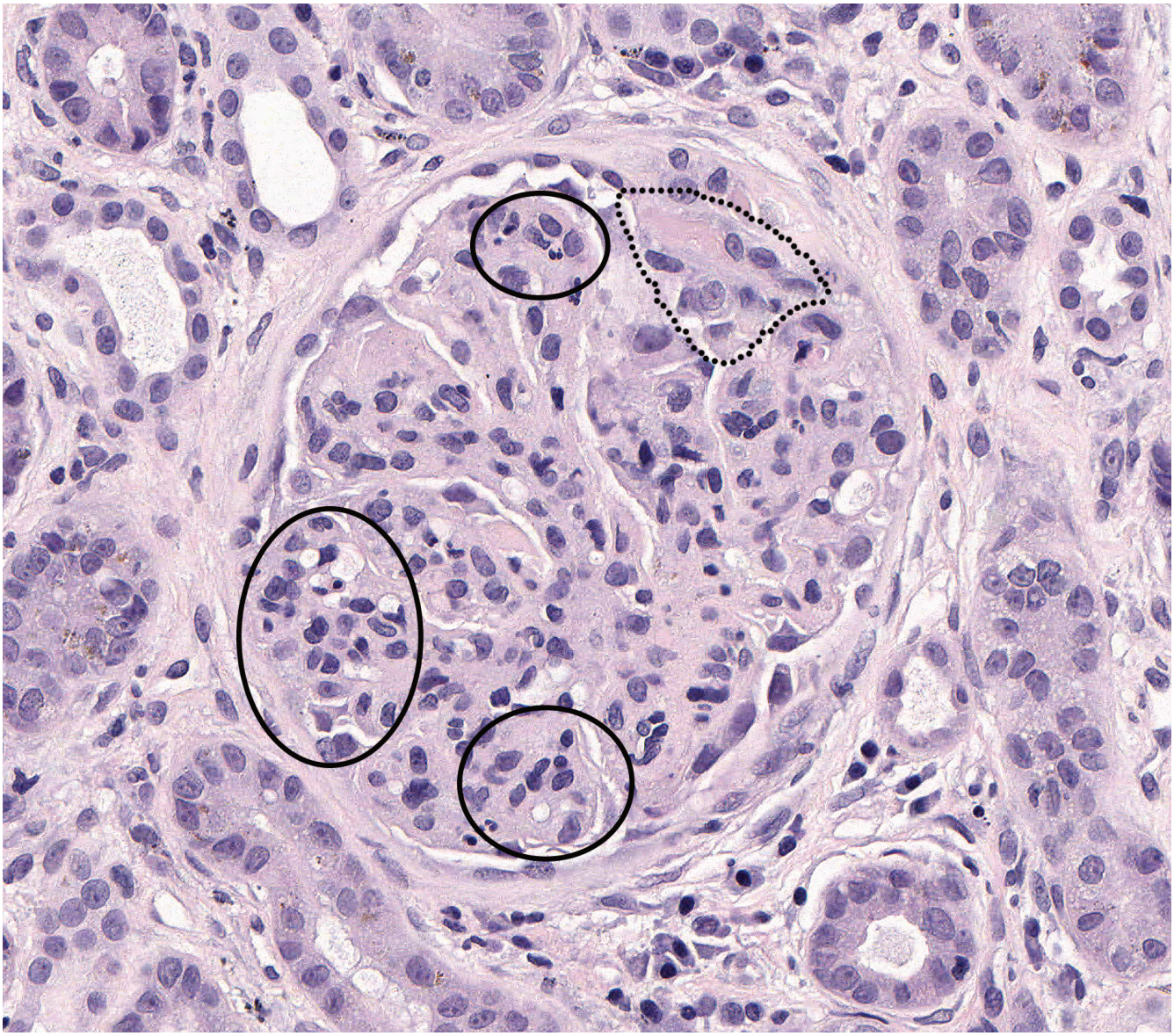

FIG.2A (HE): Chronic-active MPGN: There is global hypercellularity (circled), thickening of the GBM, a crescent within Bowman's space (outlined) and synechiae.

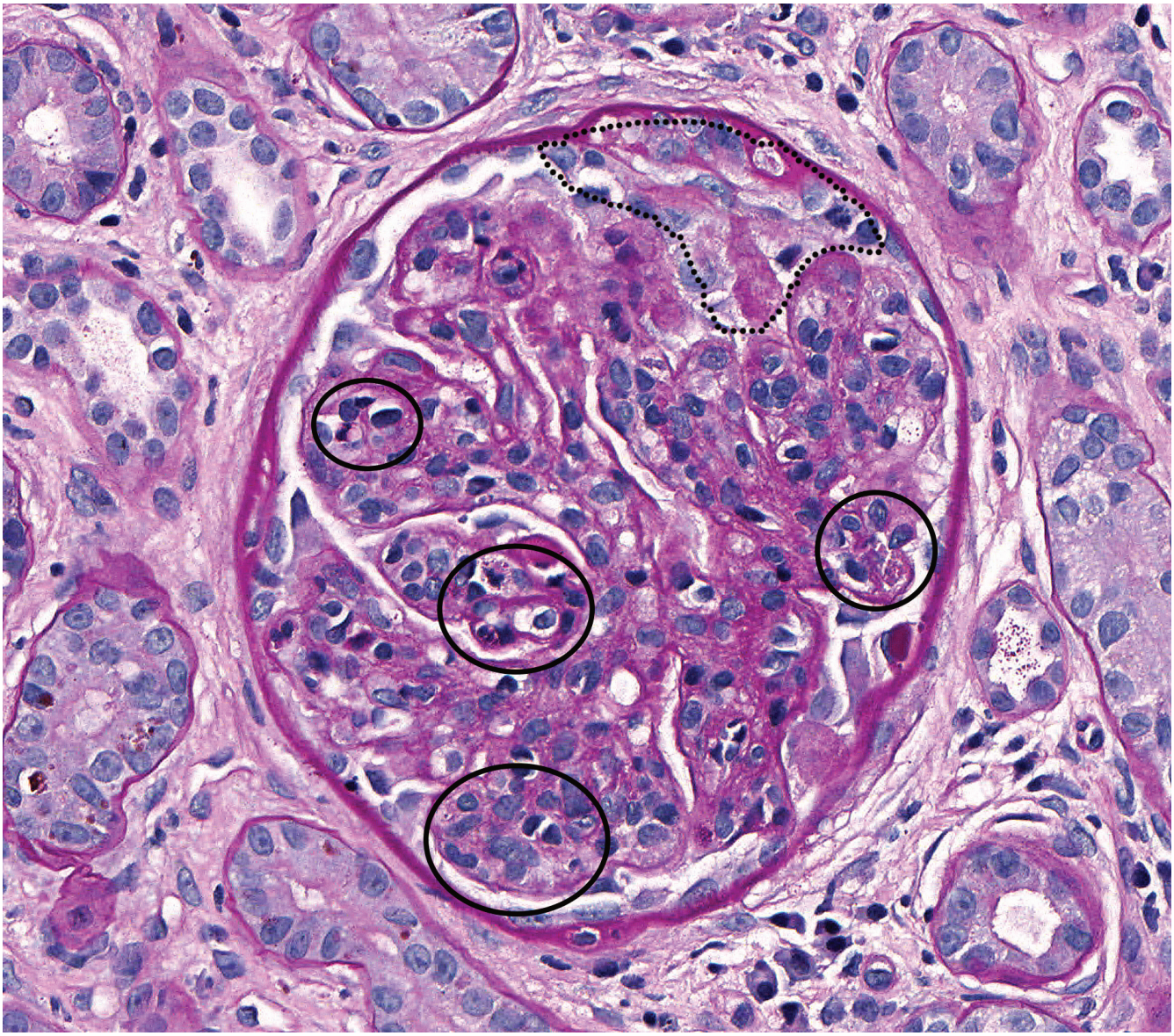

FIG.2B (PAS): Chronic-active MPGN: Global hypercellularity (circled), in both the endocapillary and mesangial compartments, accentuates the lobules of this glomerulus (i.e. glomerular lobulation) resulting in a clover-leafed appearance. Additionally there is a crescent characterized by segmental epithelial hypertrophy and mononuclear inflammatory infiltrates within Bowman's space (outlined).

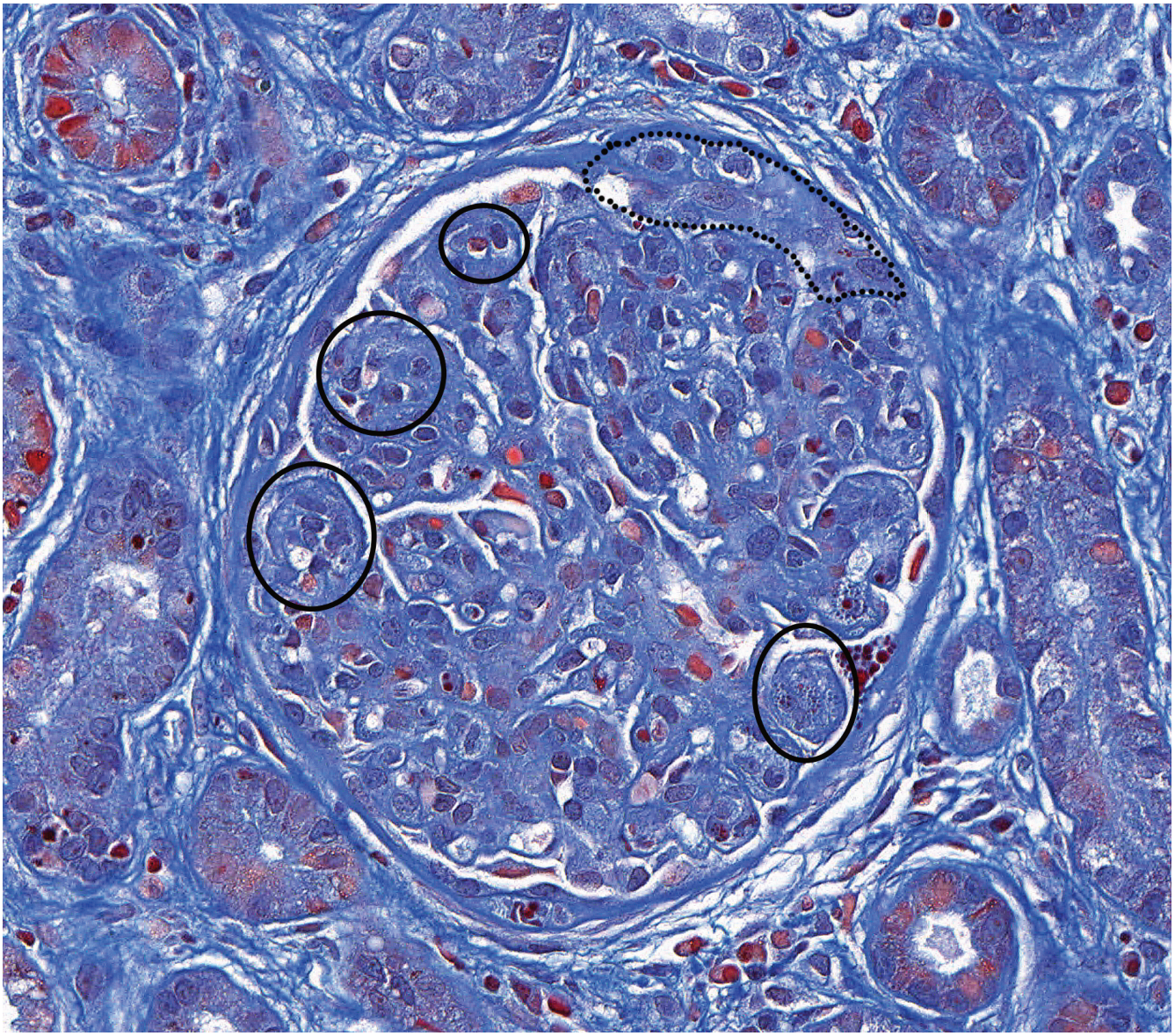

FIG.2C (MT): Chronic-active MPGN: The trichrome stain highlights the hypercellularity (circled) resulting in a lobular appearance of the glomerulus. The crescent is outlined. There is also periglomerular fibrosis, indicative of chronic injury. The generalized blue color in this particular case is likely a result of variability of the staining technique.

FIG.2D (JMS): Chronic-active MPGN: In addition to endocapillary hypercellularity the JMS stain shows evidence of capillary wall remodeling which is termed double contours (circled). Double contours occur when there is subendothelial cellular interpositioning, typically mesangial cells, as well as new subendothelial basement membrane deposition.

An interactive or media element has been excluded from this version of the text. You can view it online here:
https://ohiostate.pressbooks.pub/vetrenalpathatlas/?p=296

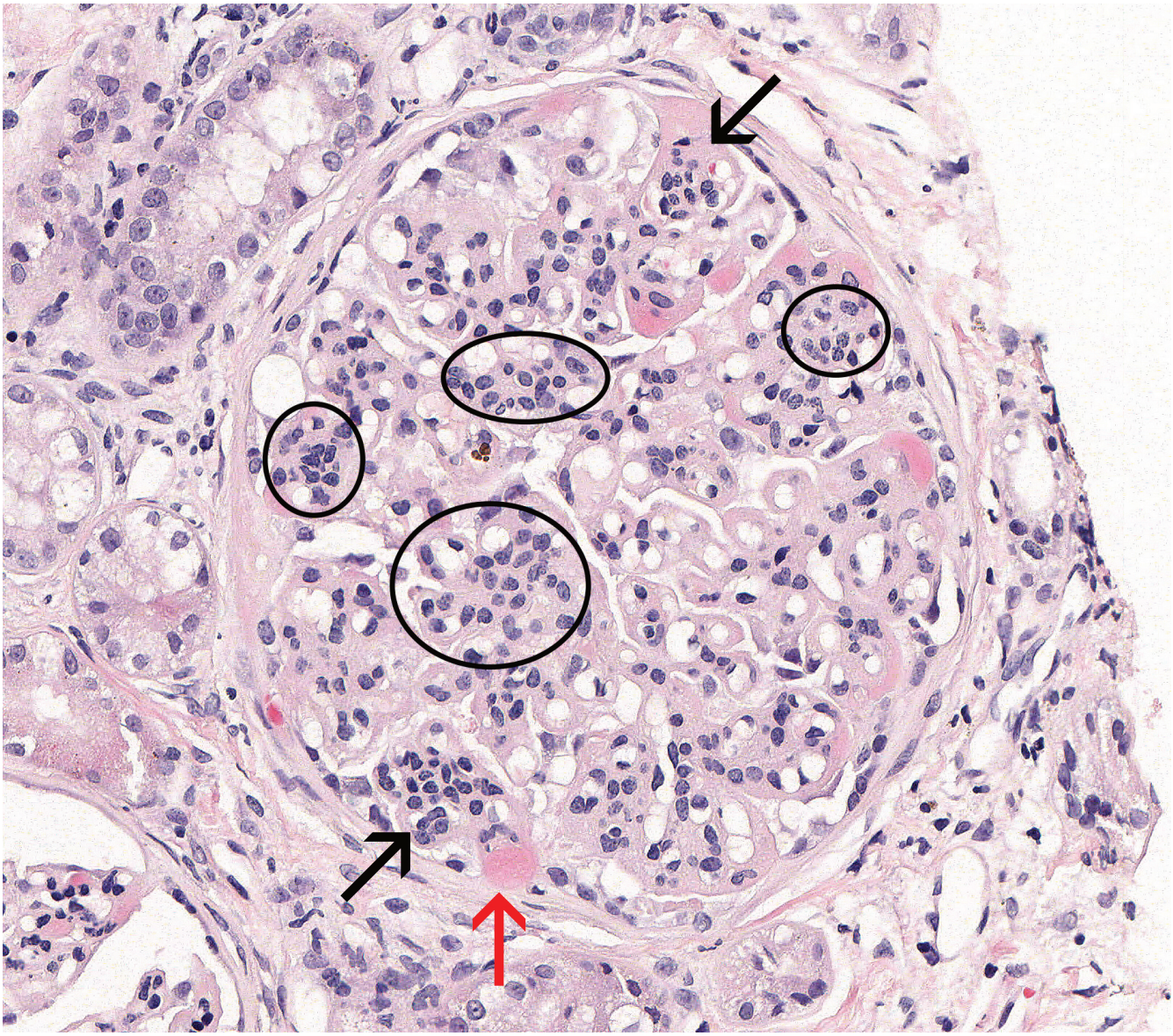

FIG.3A (HE): Chronic MPGN: This glomerulus demonstrates an accentuated lobular pattern, resulting in a clover-leaf morphology due to mesangial (circled) and endocapillary hypercellularity (black arrows). Mesangial hypercellularity is diffuse while endocapillary hypercellularity is segmental. Multifocally peripheral capillary loops are expanded by plasma (hyalinosis) (red arrow).

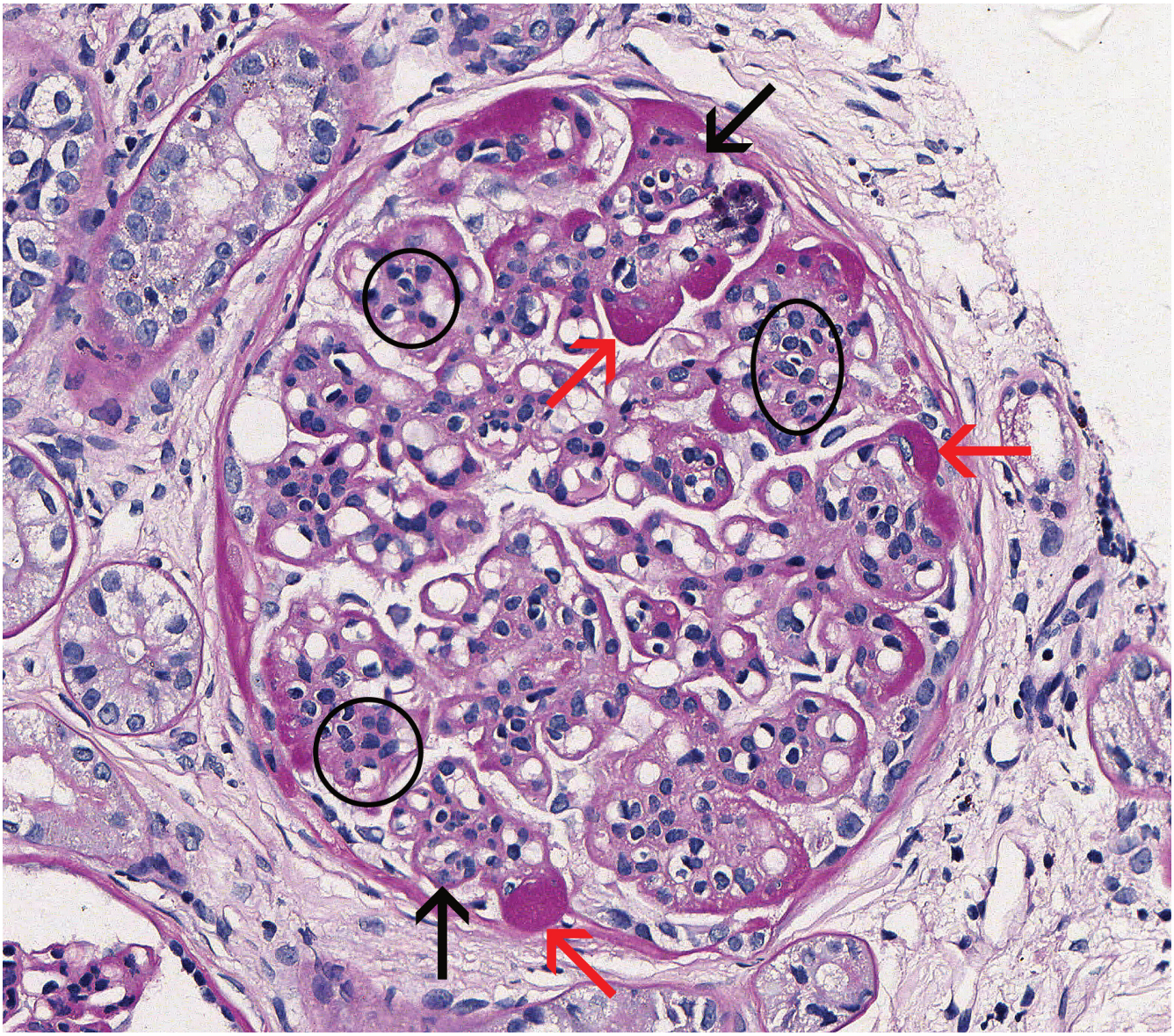

FIG.3B (PAS): Chronic MPGN: This glomerulus demonstrates mesangial hypercellularity (circled), endocapillary hypercellularity (black arrows), and a globally thickened GBM. Hyaline material in peripheral capillary loops is PAS positive (red arrows).

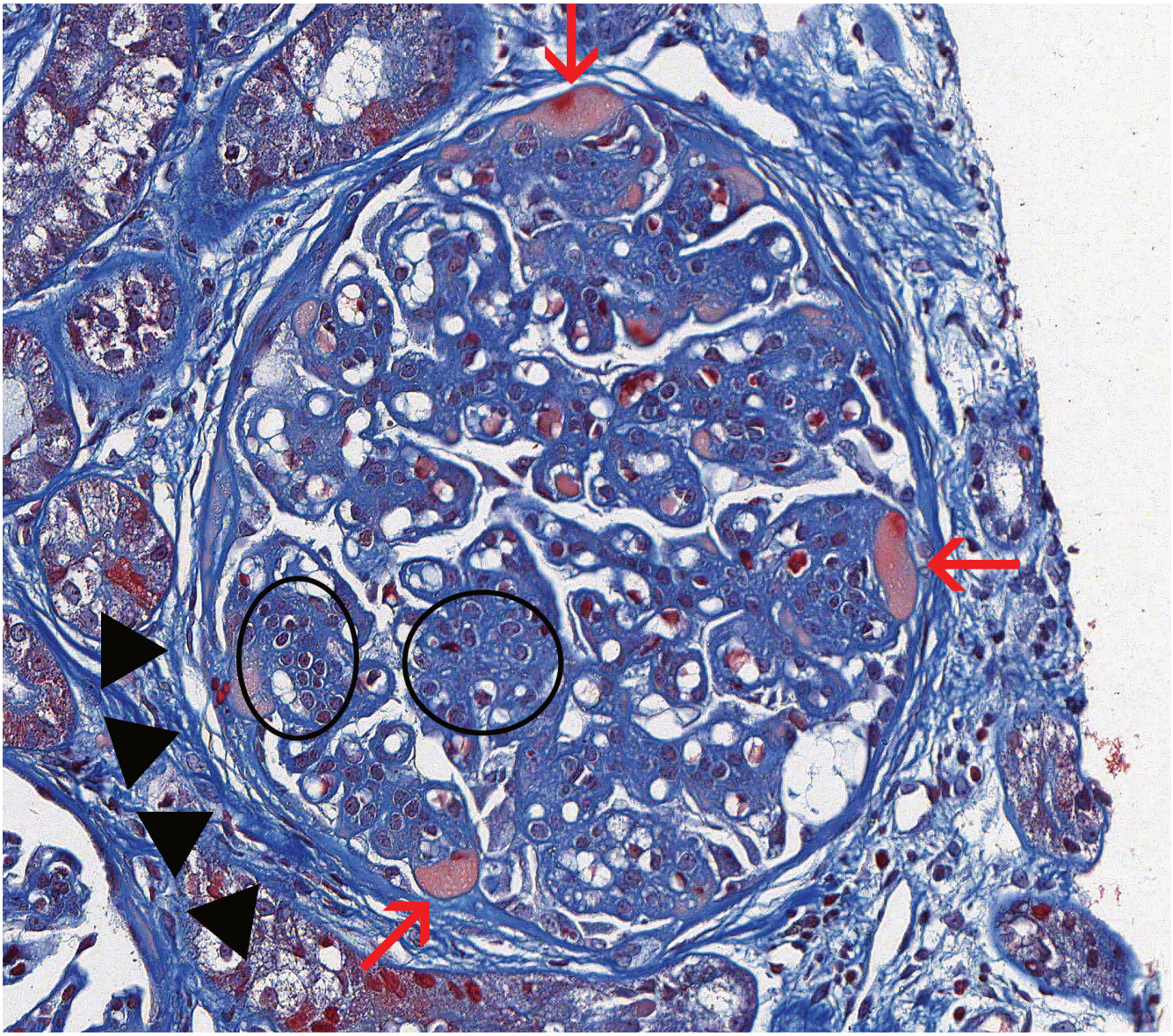

FIG.3C (MT): Chronic MPGN: This stain highlights the accentuated lobular pattern, moderate global thickening of the GBM, and hyalinosis of peripheral capillary loops (red arrows). There is moderate mesangial hypercellularity (circled). Hyaline material accumulates between the endothelial cells and GBM and appears orange to peach with MT. Additionally there is moderate circumferential fibrosis of Bowman's capsule (periglomerular fibrosis).

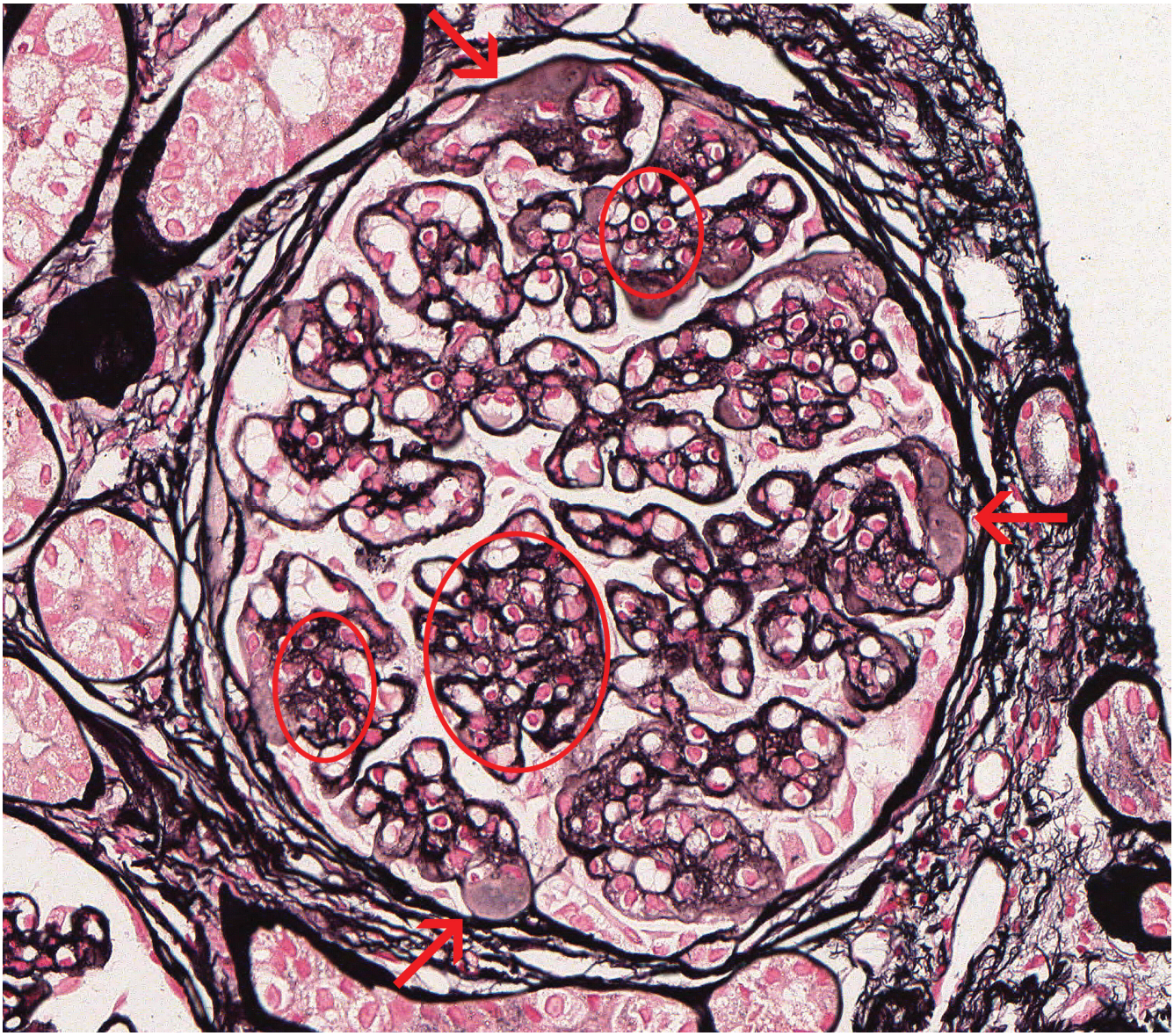

FIG.3D (JMS): Chronic MPGN: There is moderate mesangial hypercellularity (circles). This stain highlights the presence of double contours and thickening of the GBM (arrows). The double contours can be due to the presence of immune complexes, hyaline and cellular interpositioning within the GBM.

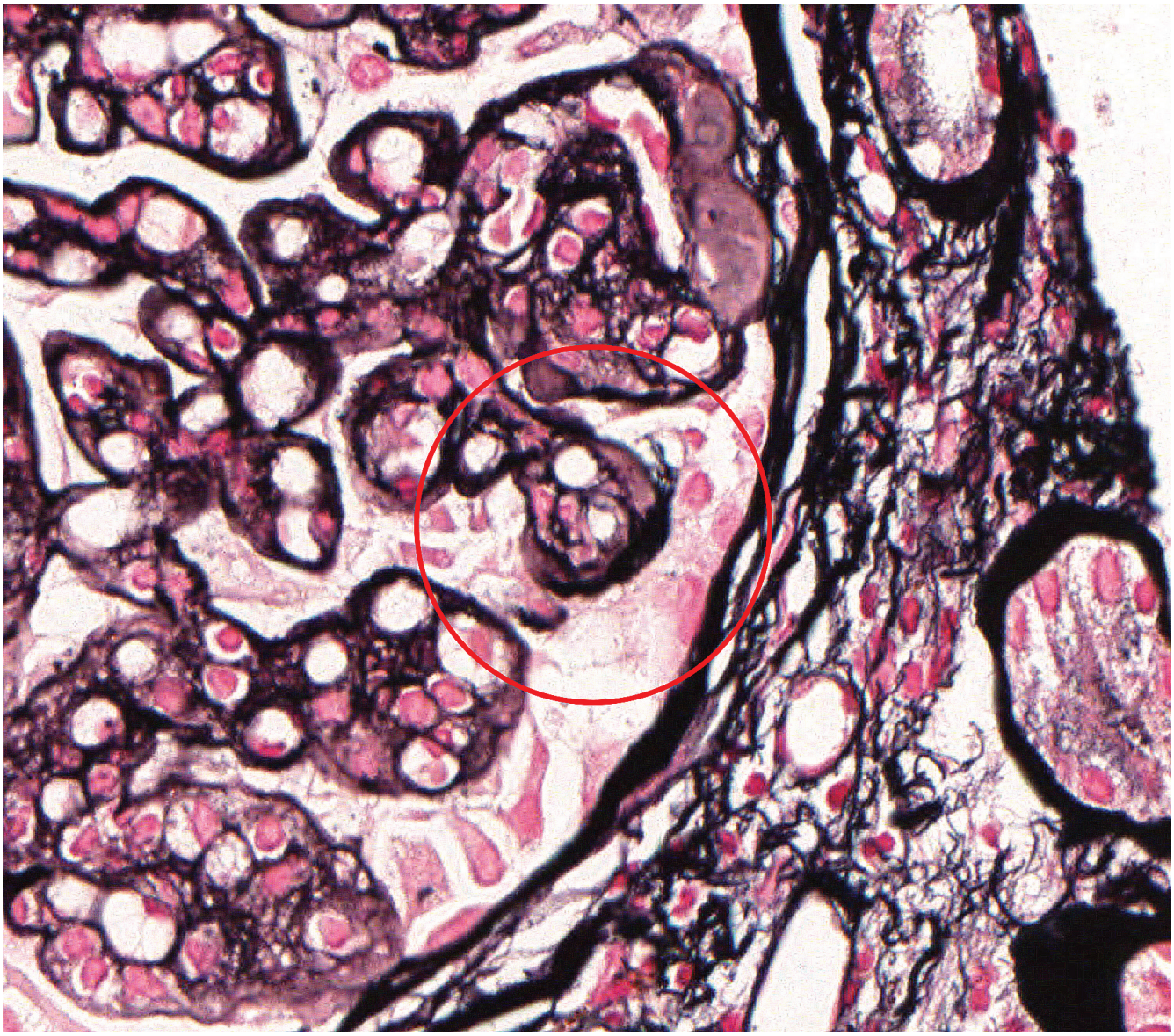

FIG.3E (JMS): Chronic MPGN: Increased magnification of previous photomicrograph, demonstrating double contours of the GBM (circled).

An interactive or media element has been excluded from this version of the text. You can view it online here:
https://ohiostate.pressbooks.pub/vetrenalpathatlas/?p=296

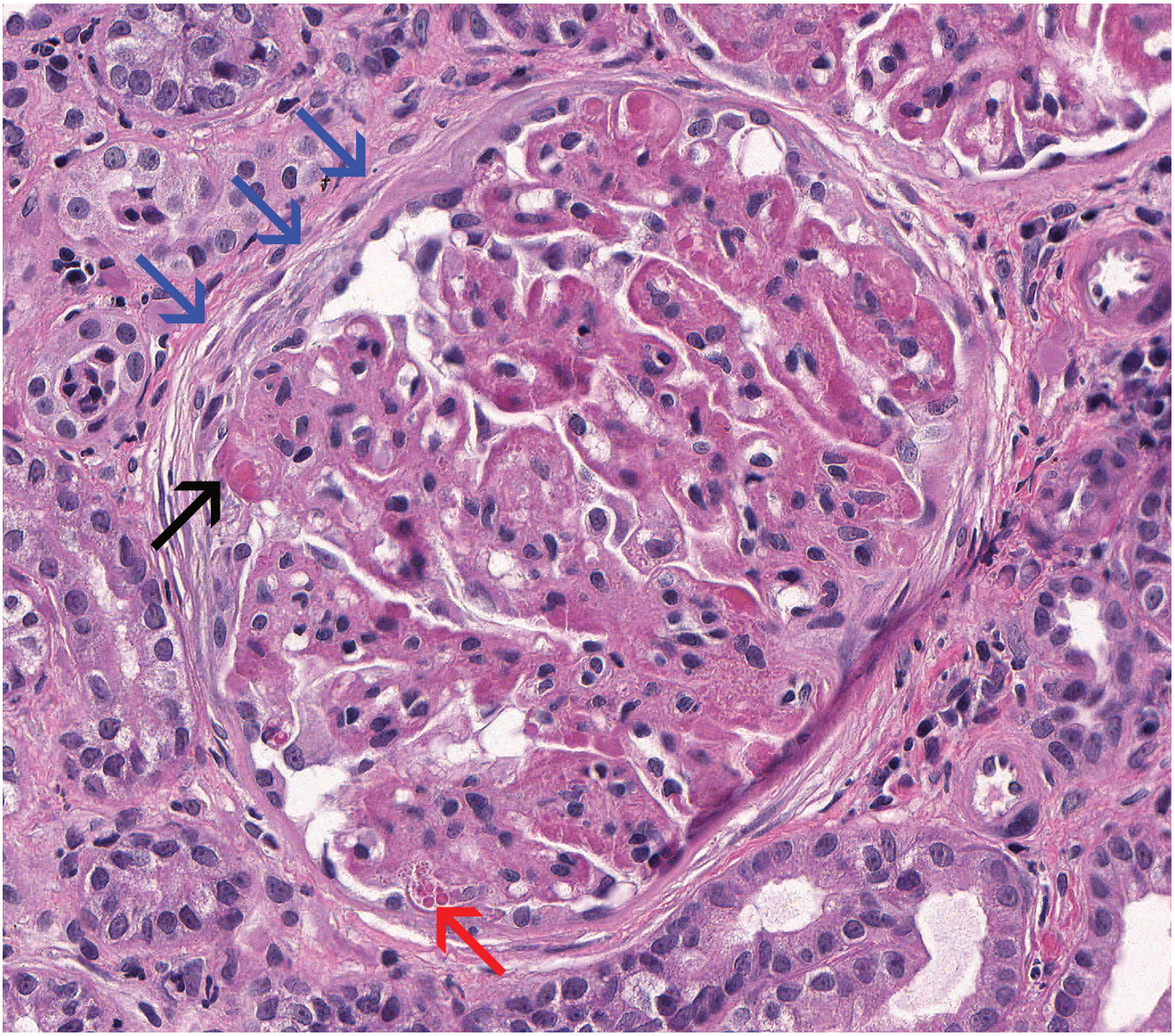

FIG.4A (HE): Severe, chronic MPGN: This glomerulus demonstrates thickening of the GBM, synechiae (black arrow), podocyte protein droplets (red arrow), a split Bowman's capsule (blue arrows), and periglomerular fibrosis.

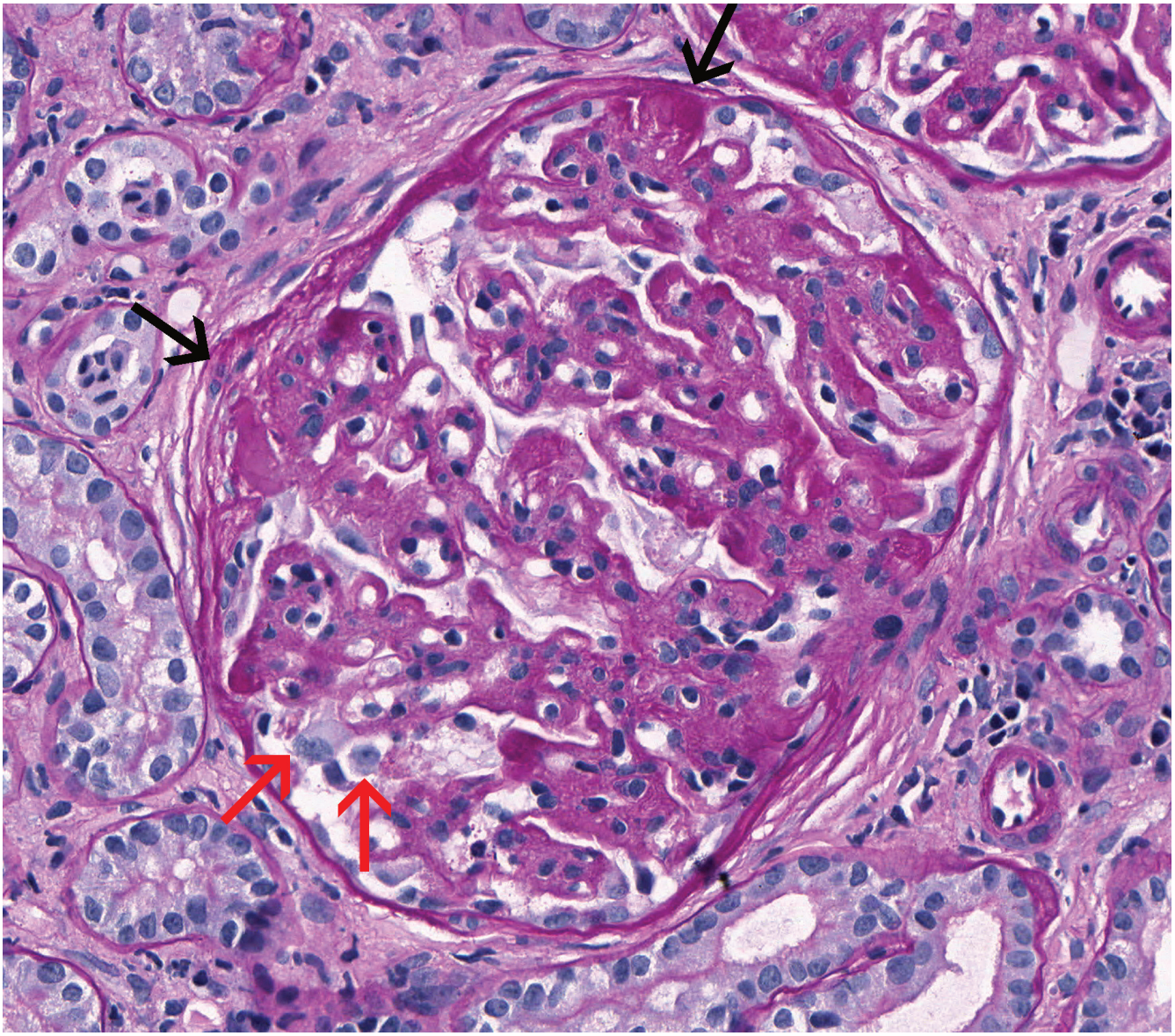

FIG.4B (PAS): Severe, chronic MPGN: This stain highlights the globally thickened GBM, multiple synechiae (black arrows), and marked podocyte hypertrophy (red arrows).

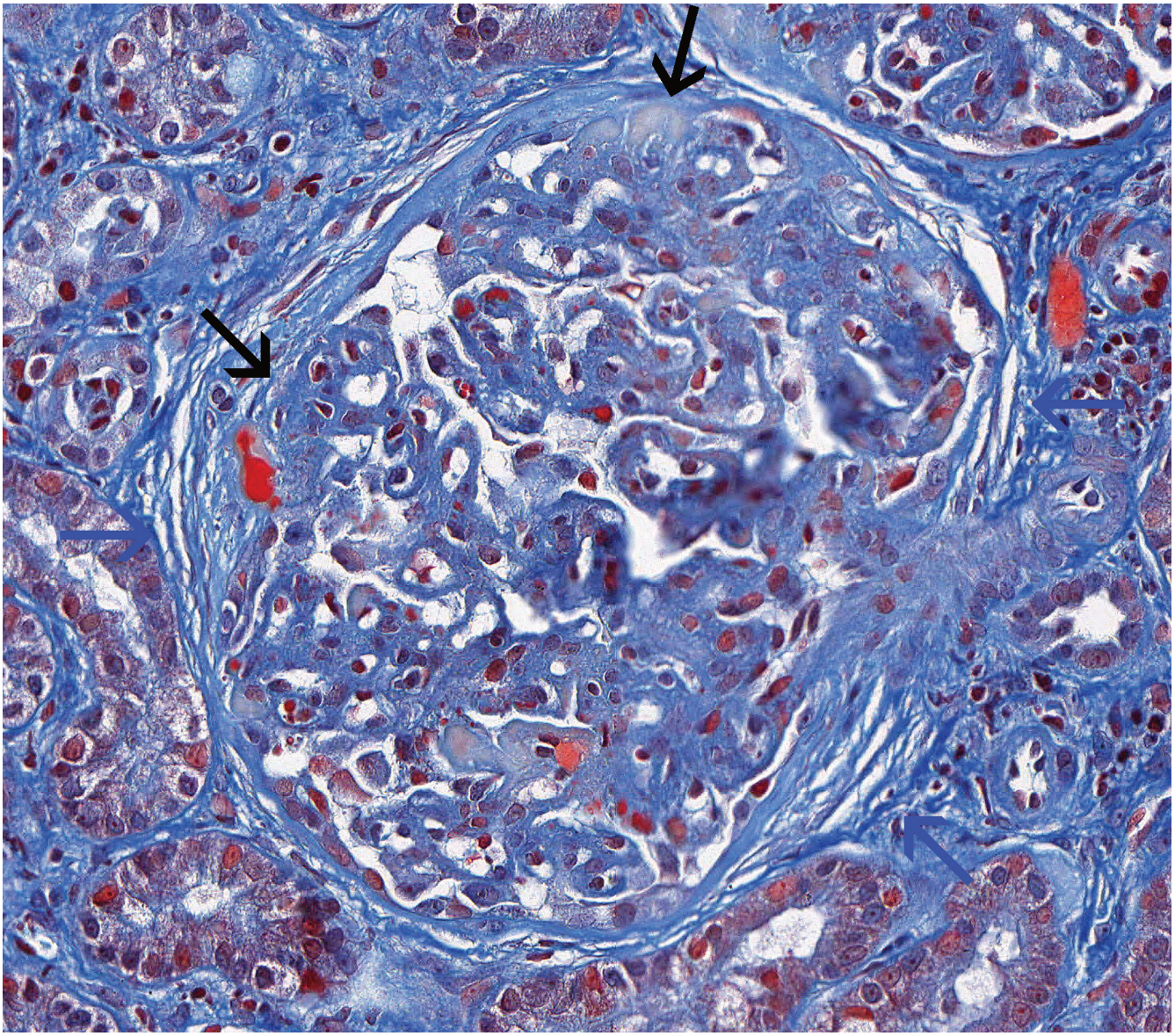

FIG.4C (MT): Severe, chronic MPGN: This stain highlights the presence of a split Bowman's capsule and periglomerular fibrosis (blue arrows). There are multiple synechiae (black arrows).

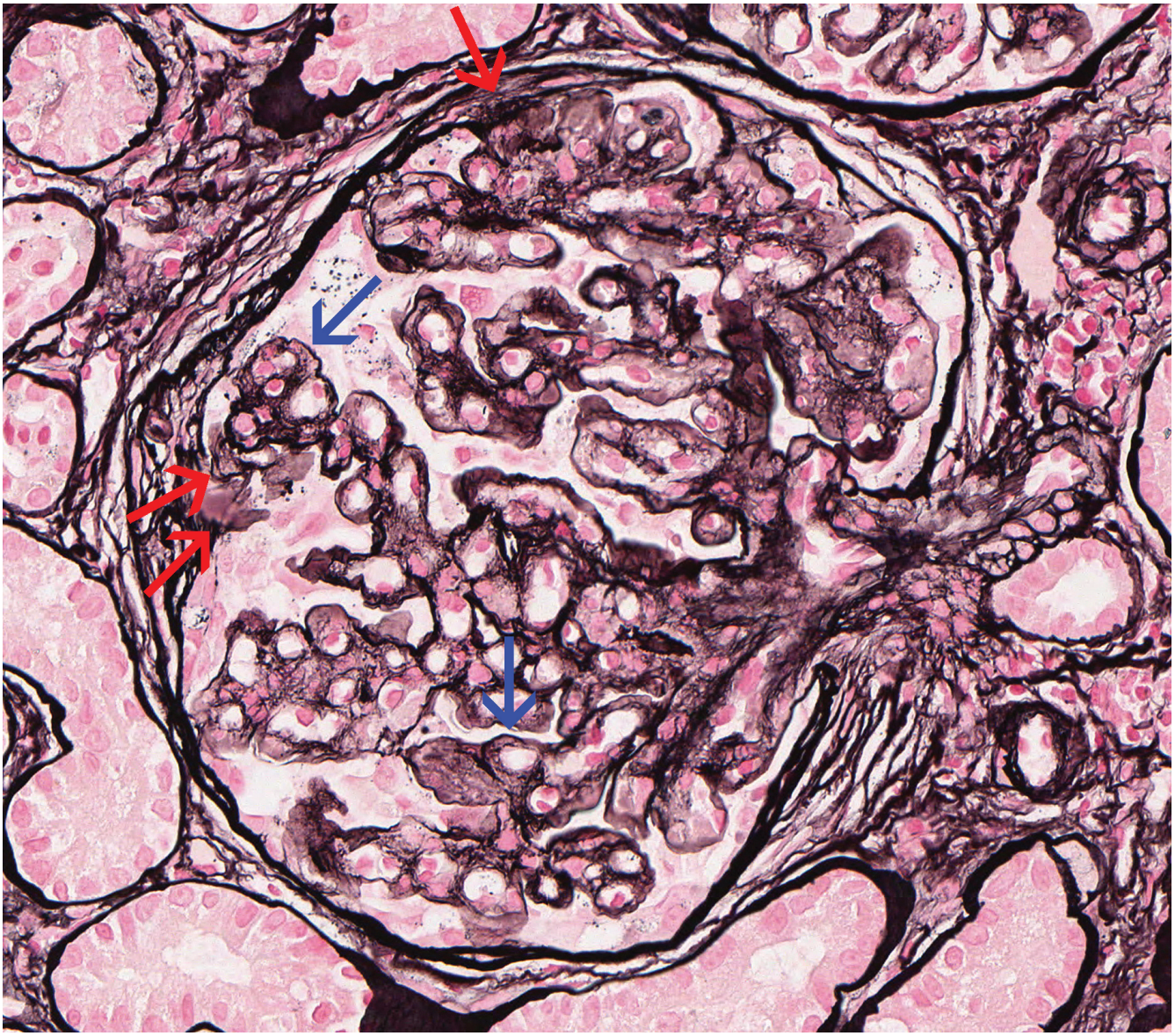

FIG.4D (JMS): Severe, chronic MPGN: The JMS method highlights the presence of multiple synechiae, a split Bowman's capsule (red arrow), periglomerular fibrosis, and GBM duplication with mesangial interpositioning (blue arrows).

Please note the glomerulus below is from the same dog presented in FIGURES 4A – 4D.

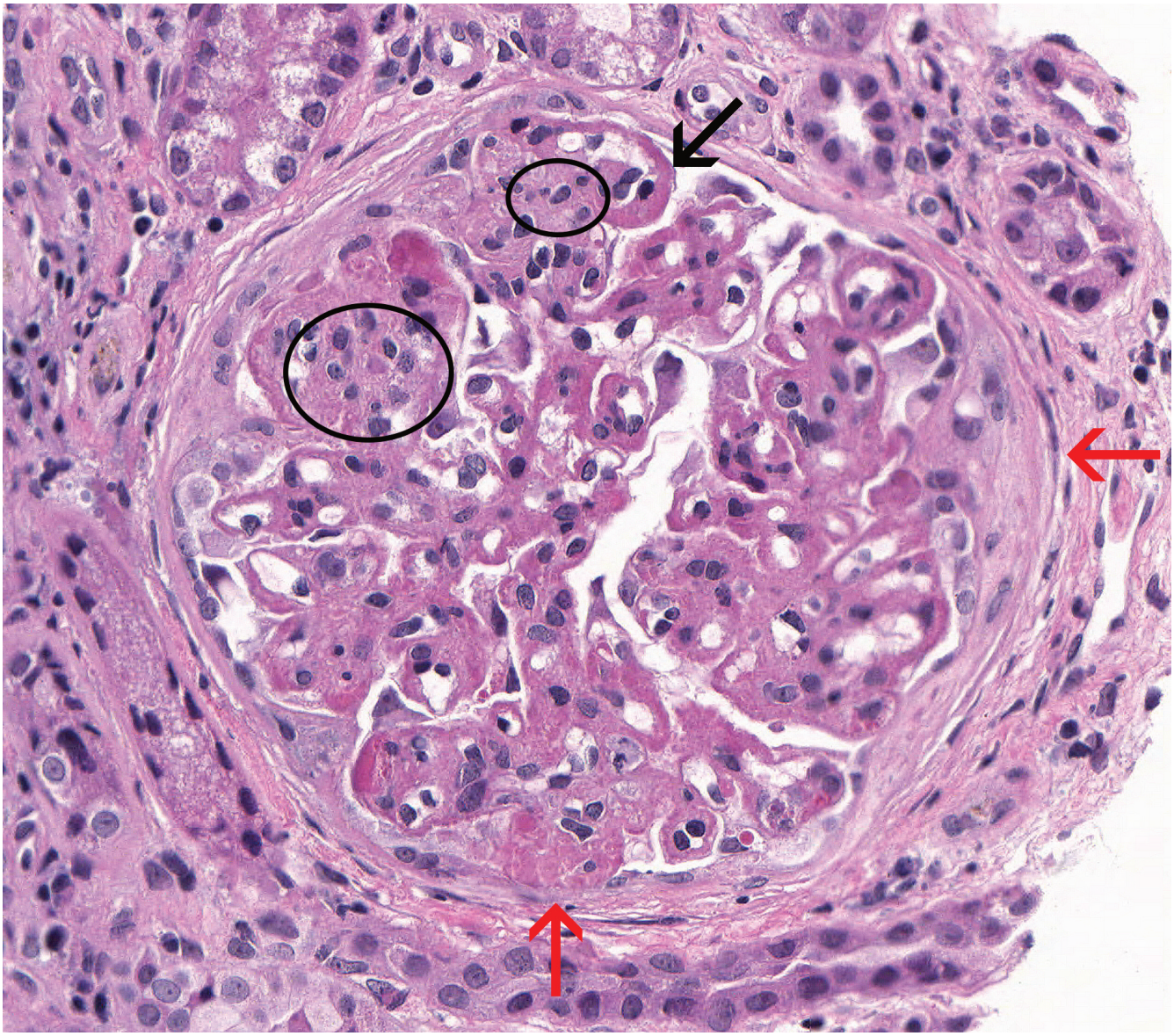

FIG.4E (HE): Severe, chronic MPGN: This glomerulus demonstrates multifocal mesangial hypercellularity (circles), a thickened GBM (black arrow), and multiple synechiae (red arrows).

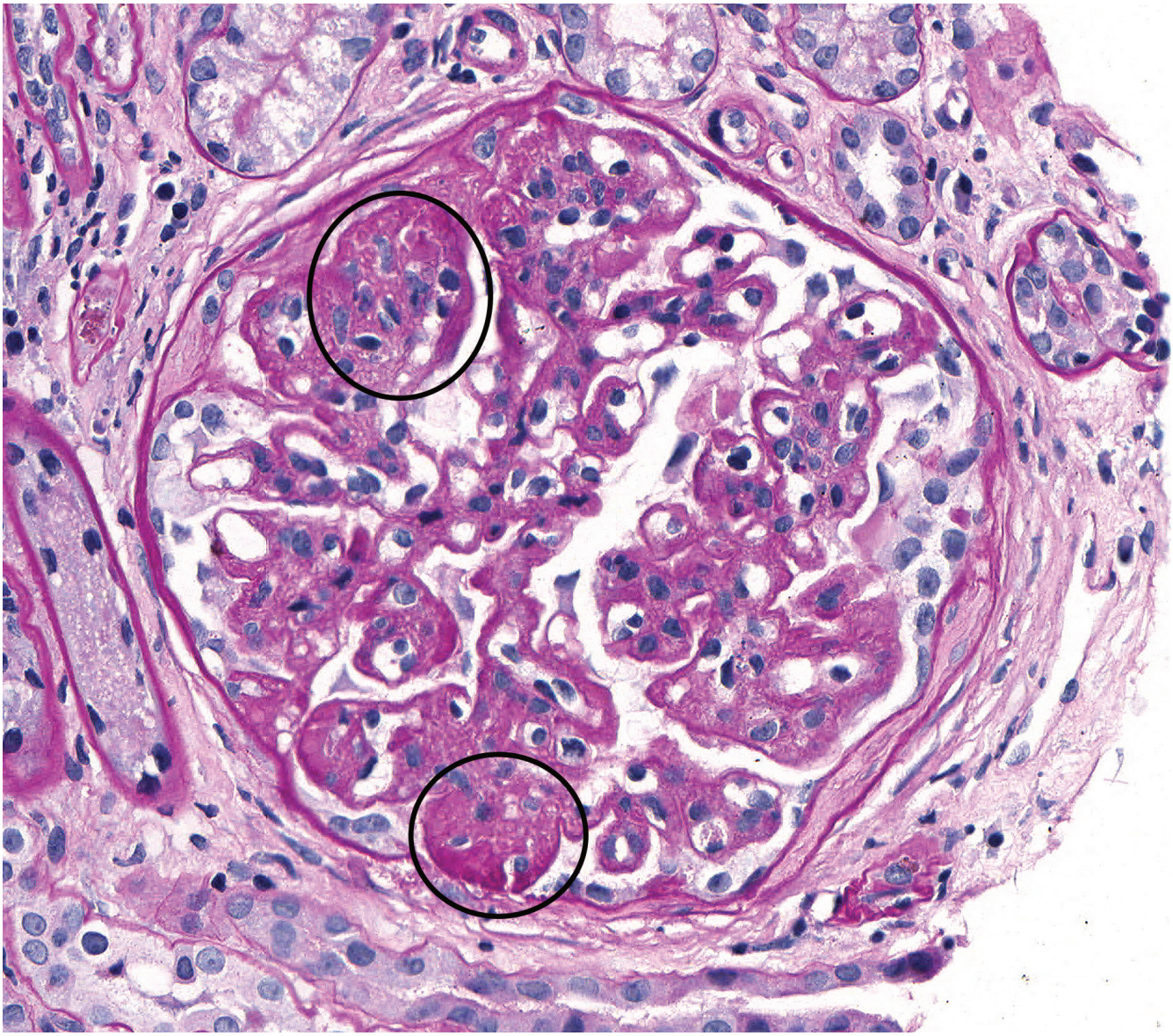

FIG.4F (PAS): Severe, chronic MPGN: There is GBM thickening and the mesangial matrix is segmentally expanded indicating irreversible sclerosis (circled). The hypercellularity is less prominent in this glomerulus.

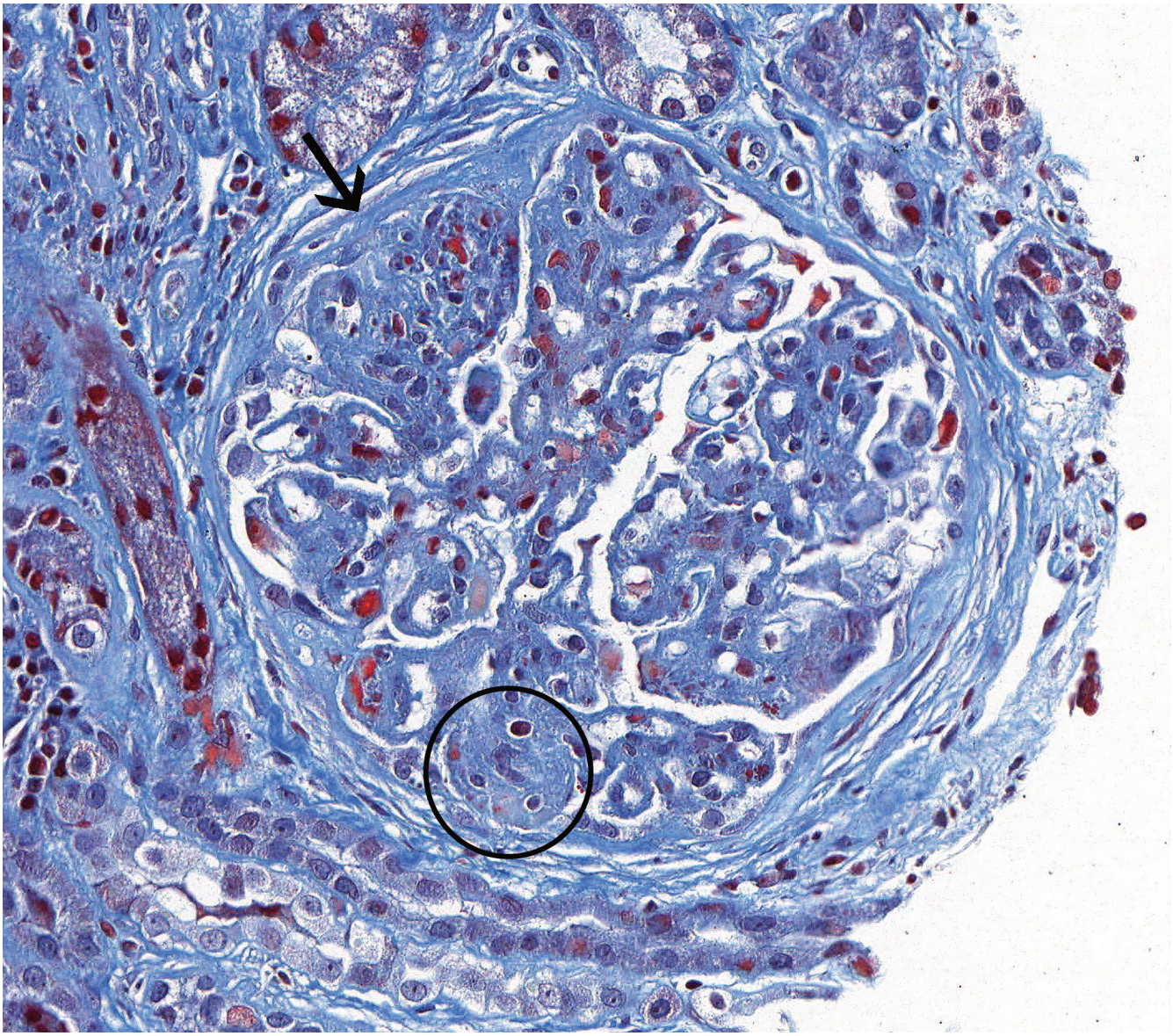

FIG.4G (MT): Severe, chronic MPGN: This glomerulus demonstrates synechia (arrow) and segmental sclerosis (black circle).

FIG.4H (JMS): Severe, chronic MPGN: This glomerulus demonstrates severe GBM duplication with double contouration (arrows).

An interactive or media element has been excluded from this version of the text. You can view it online here:
https://ohiostate.pressbooks.pub/vetrenalpathatlas/?p=296

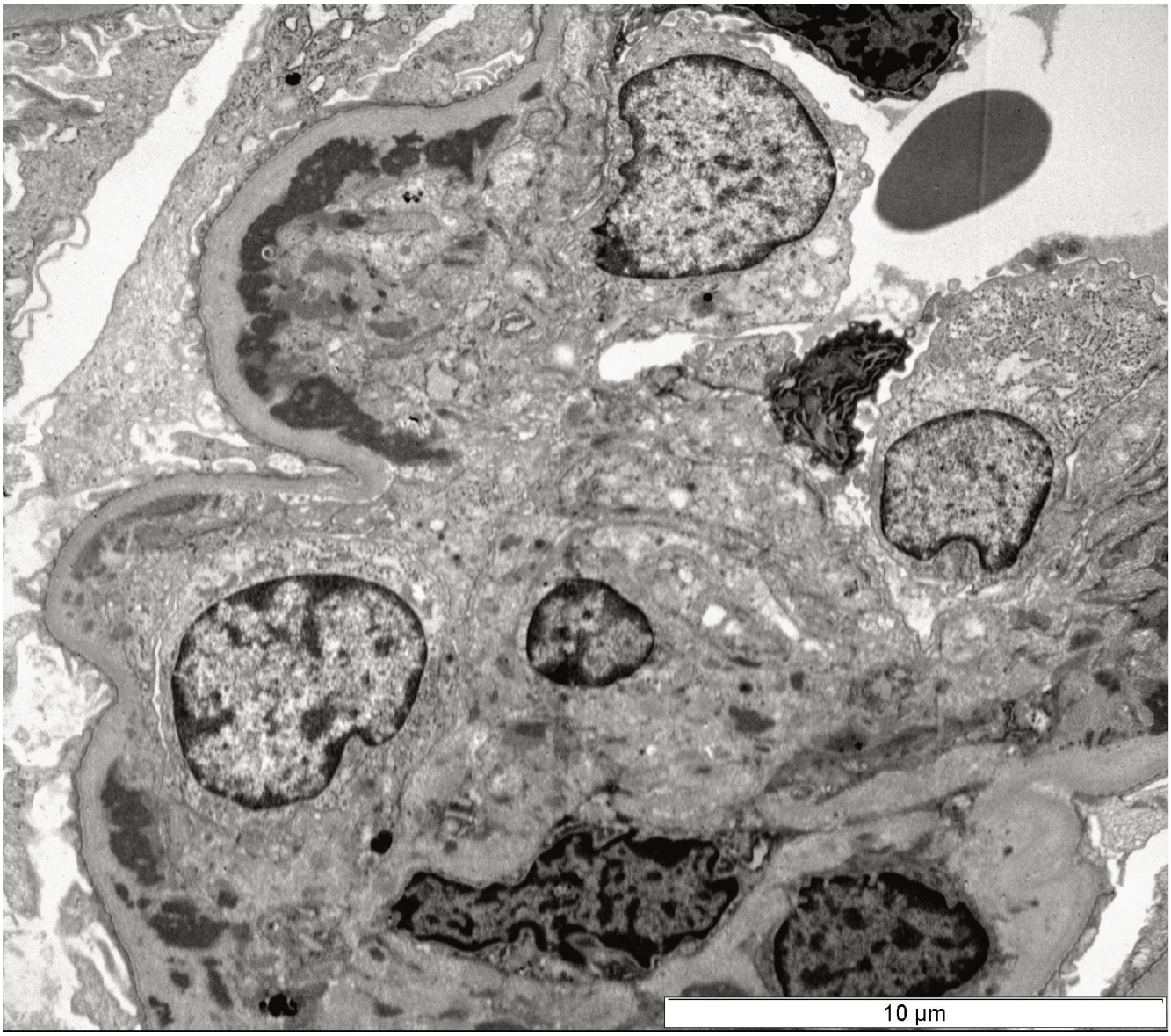

FIG.5A (TEM): Acute MPGN: There are subendothelial and mesangial electron dense deposits. This segment of the glomerular tuft is hypercellular.

An interactive or media element has been excluded from this version of the text. You can view it online here:
https://ohiostate.pressbooks.pub/vetrenalpathatlas/?p=296

FIG.5B (TEM): Colorized version of above TEM image with subendothelial electron-dense deposits and variable electron-dense mesangial deposits (grey black). The mesangium (blue) is expanded compressing and invading the capillary. Endothelial cells (yellow) are swollen and obstruct the capillary lumen. Lastly, there is global fusion of podocyte foot processes (pink).

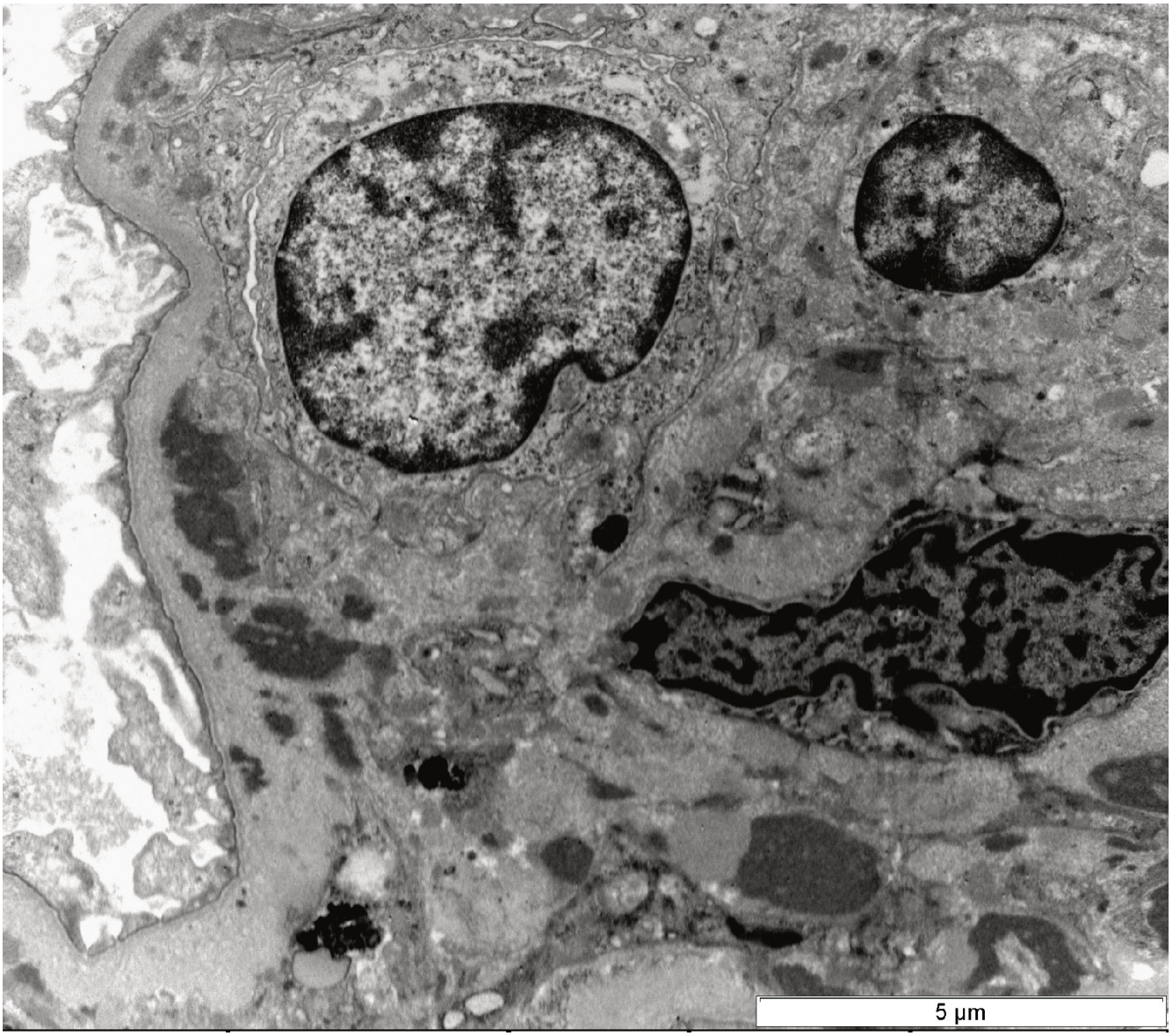

FIG.5C (TEM): Acute MPGN: Higher magnification of Figure 5A showing subendothelial and mesangial deposits, mesangial and endothelial proliferation.

An interactive or media element has been excluded from this version of the text. You can view it online here:
https://ohiostate.pressbooks.pub/vetrenalpathatlas/?p=296

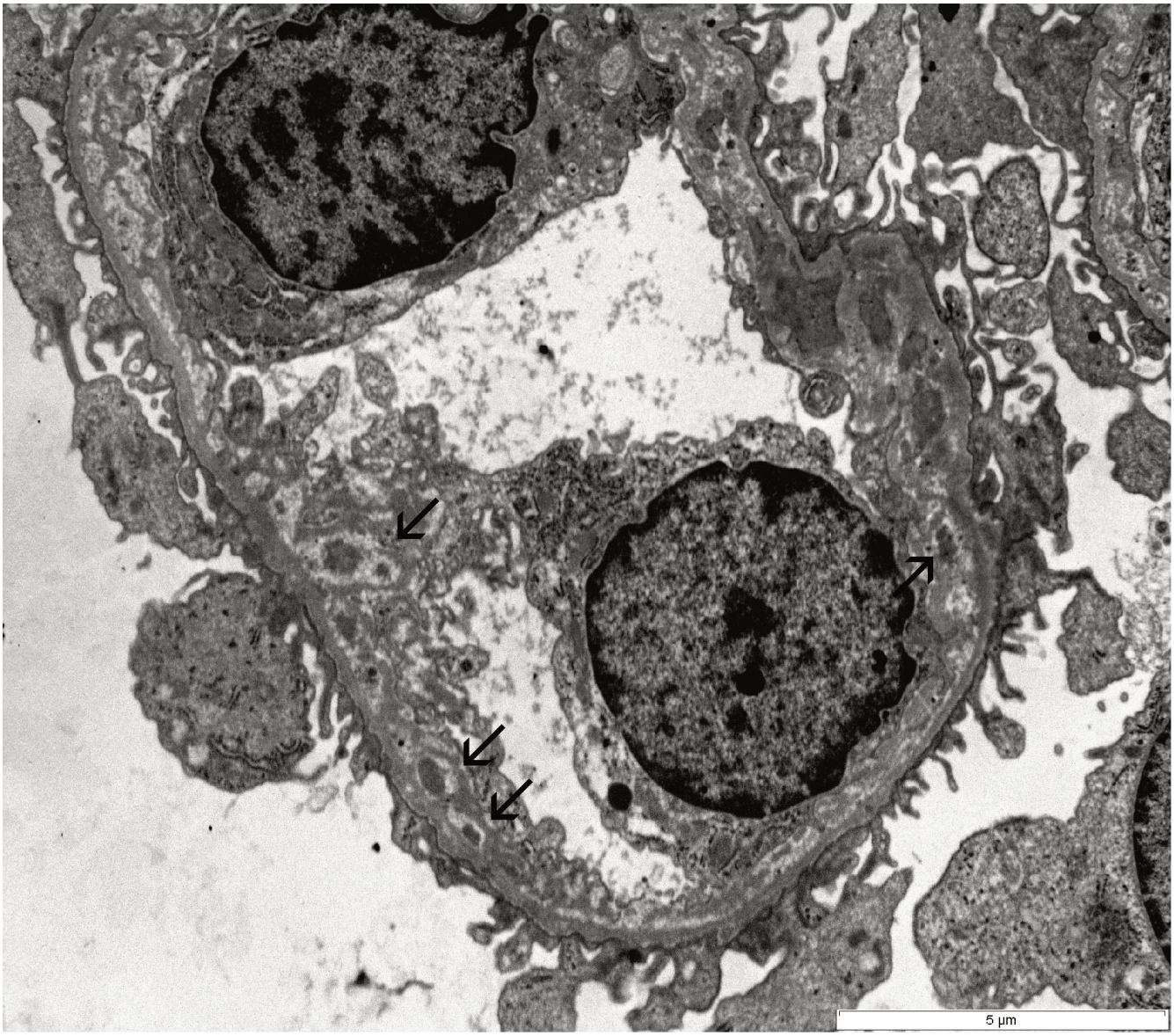

FIG.6A (**TEM):** This glomerular capillary loop demonstrates scattered subendothelial granular electron-dense deposits and synthesis of new GBM material by the endothelial cells (arrows).

An interactive or media element has been excluded from this version of the text. You can view it online here:
https://ohiostate.pressbooks.pub/vetrenalpathatlas/?p=296

FIG.6B (TEM): Colorized version of above TEM image This glomerular capillary loop demonstrates scattered subendothelial granular electron-dense deposits with remodeling of the basement membrane (green). Remodeling consists of lamina densa encasing deposits and a circumferential lucency indicating dissolution of immune deposits.

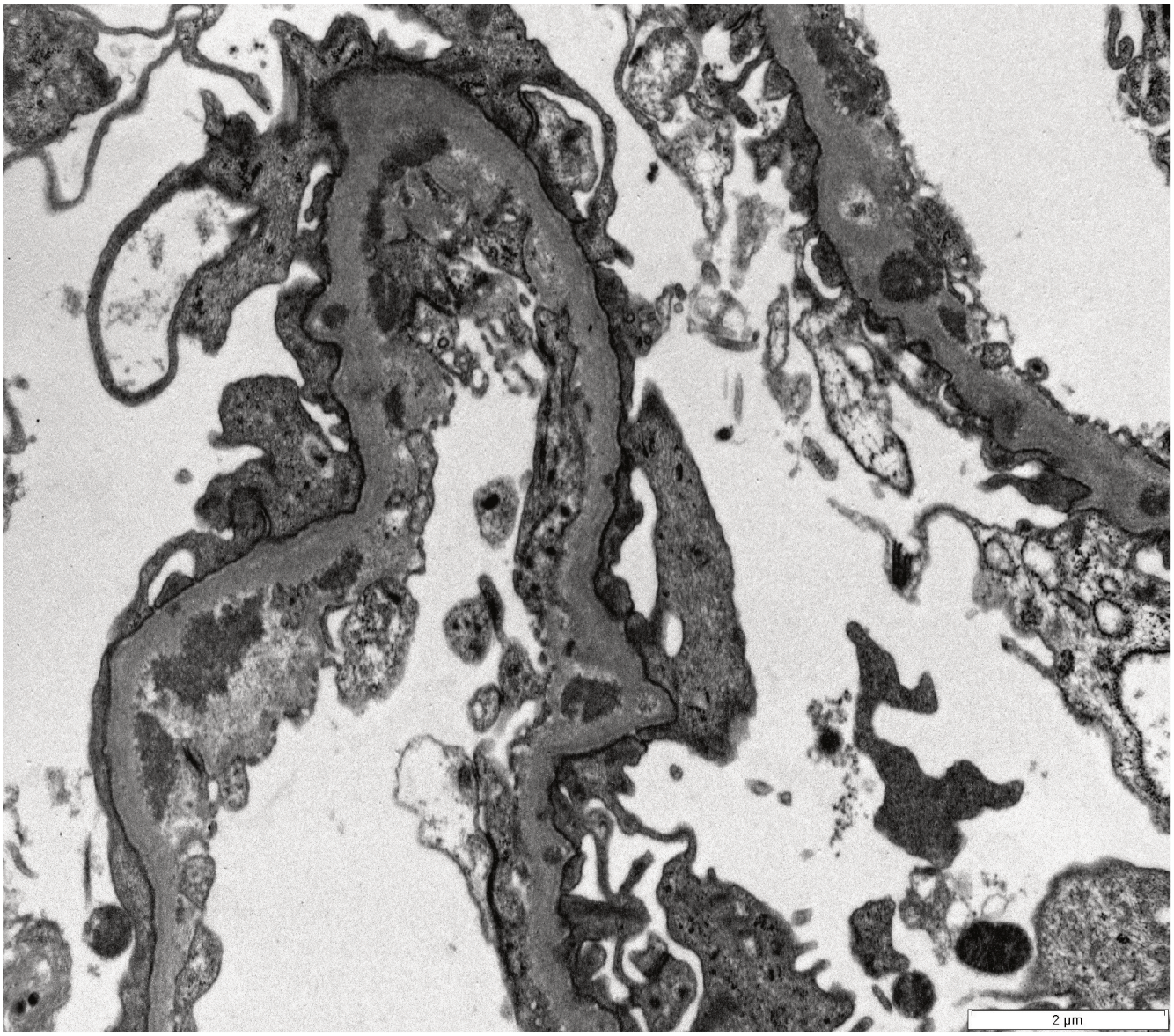

FIG.6C (TEM): These capillaries have many irregular electron dense deposits in a subendothelial location and global effacement of podocyte foot processes.

An interactive or media element has been excluded from this version of the text. You can view it online here:
https://ohiostate.pressbooks.pub/vetrenalpathatlas/?p=296

FIG.6D (TEM): Colorized version of above TEM image. These capillaries have many irregular electron dense deposits. They are on the subendothelial aspect of the GBM (green). There is global effacement of podocyte foot processes (pink). Endothelial cells have lost their fenestrae (yellow).

An interactive or media element has been excluded from this version of the text. You can view it online here:
https://ohiostate.pressbooks.pub/vetrenalpathatlas/?p=296

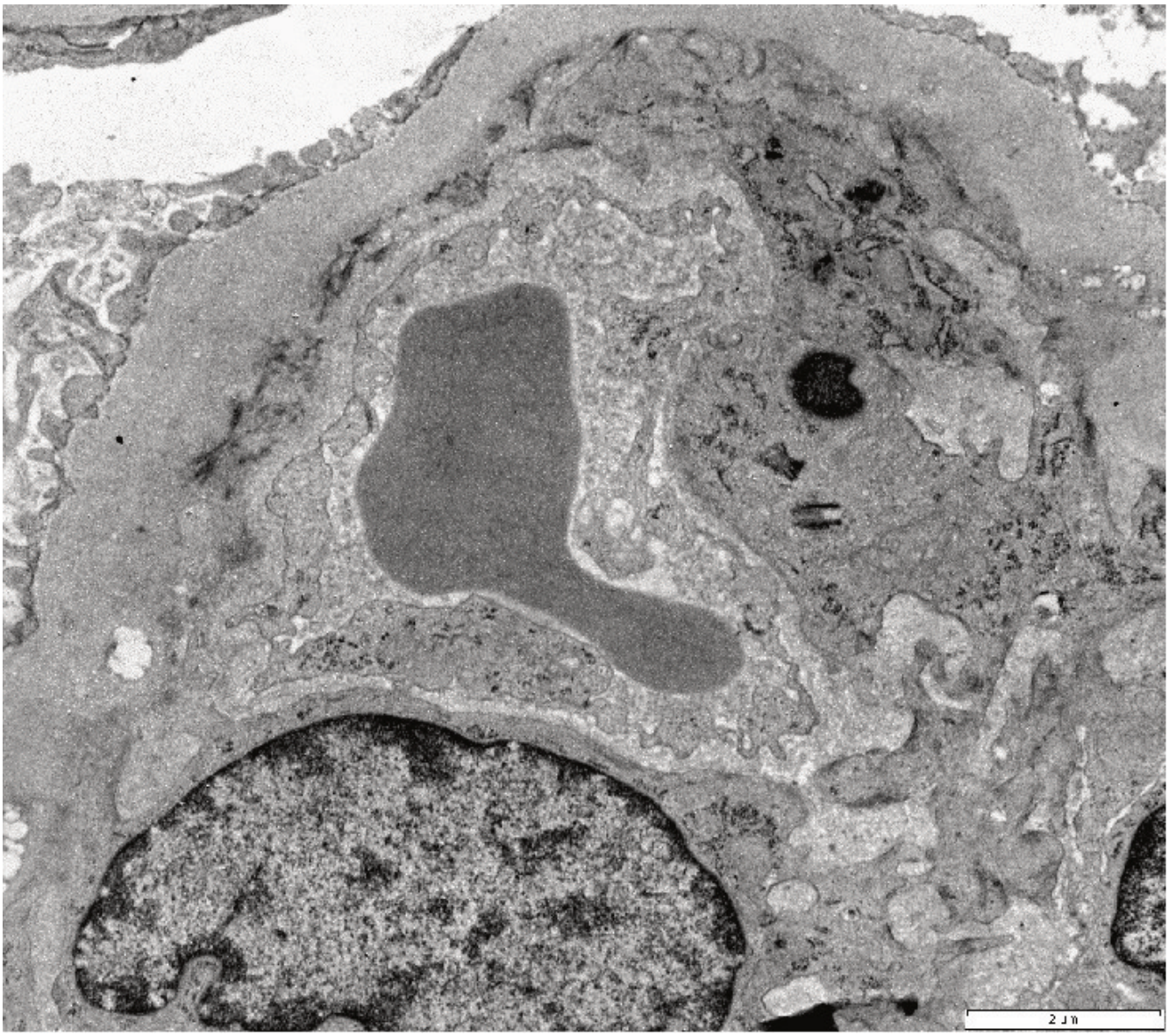

FIG.7A (TEM): MPGN: Membranoproliferative pattern of injury due to chronic MPGN with circumferential interpositioning of mesangial cell cytoplasmic processes.

An interactive or media element has been excluded from this version of the text. You can view it online here:
https://ohiostate.pressbooks.pub/vetrenalpathatlas/?p=296

FIG.7B (TEM): MPGN: The GBM (green) is thickened due to remodeling and subendothelial electron-dense deposits. Additionally there is marked podocyte foot process effacement (pink) and microvillus transformation.

An interactive or media element has been excluded from this version of the text. You can view it online here:
https://ohiostate.pressbooks.pub/vetrenalpathatlas/?p=296

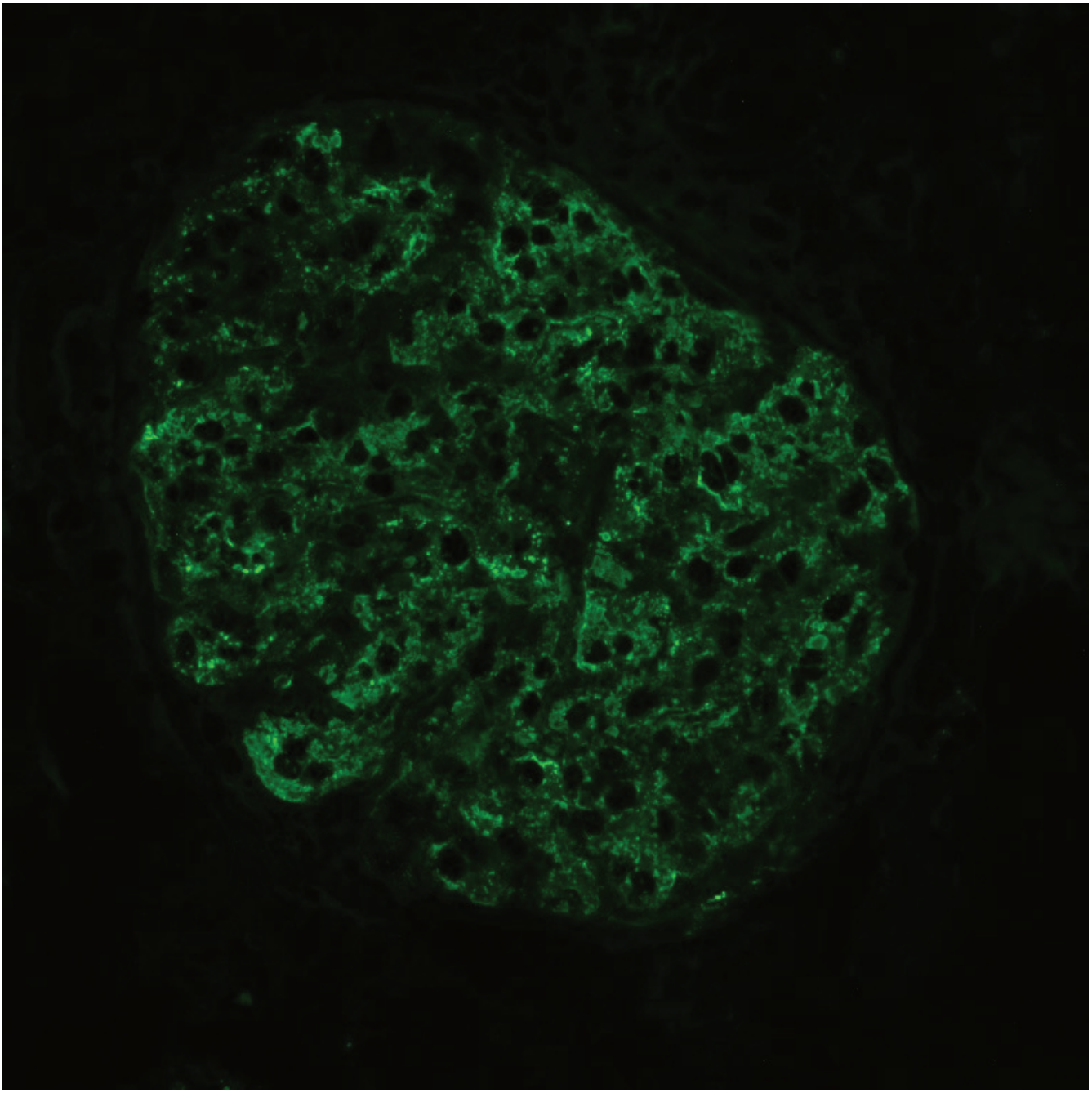

FIG.8A (IF for C3): There is strong granular labeling along capillary loops and in mesangial zones.

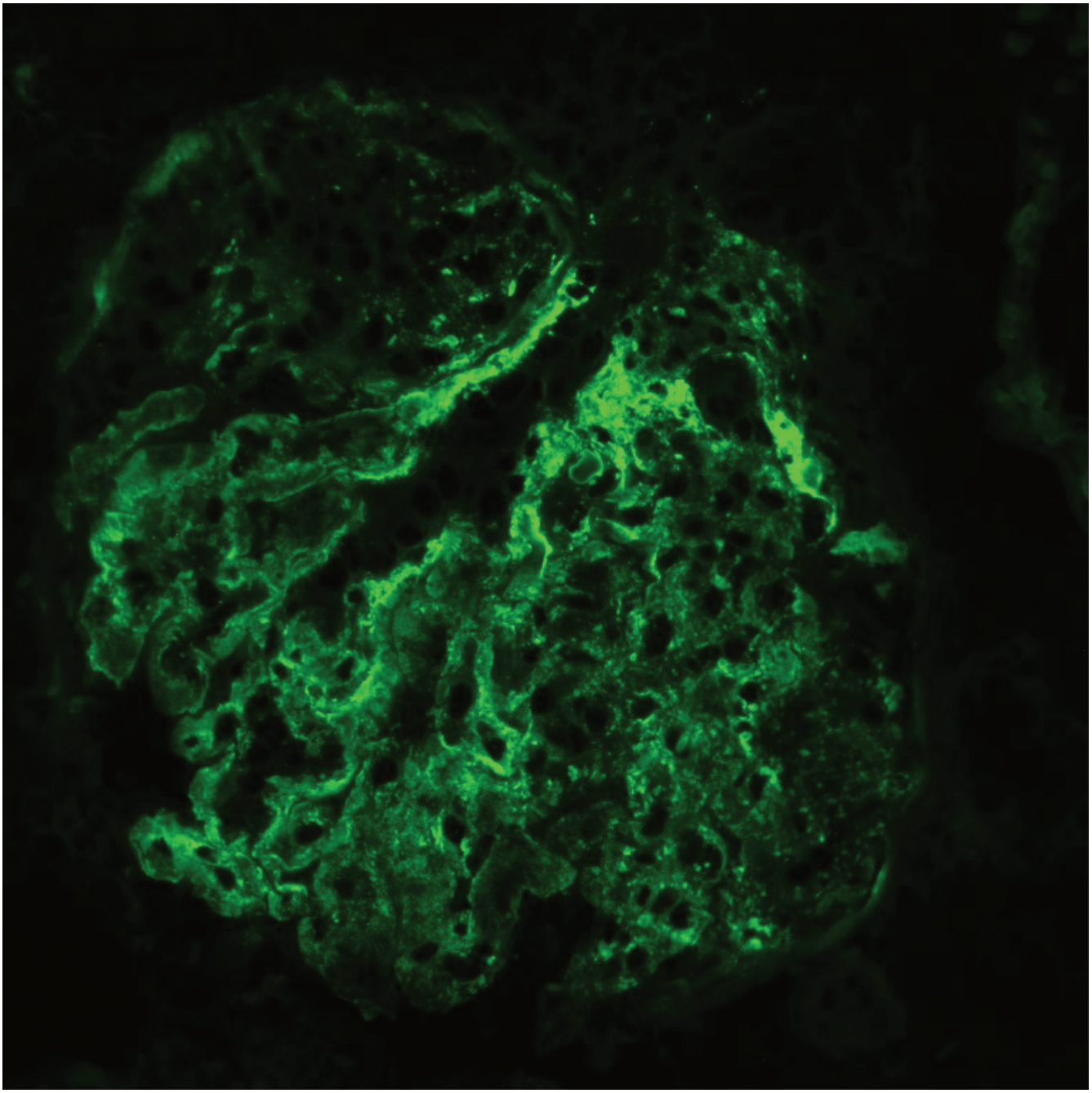

FIG.8B (IF for LLC): There is strong granular labeling along capillary loops and in mesangial zones.

Differential Diagnoses for Membranoproliferative Glomerulonephritis

Disease	Defining Histologic Features	Defining Ultrastructural Features
Proliferative pattern	Increased cellularity without GBM remodeling	GBM is not remodeled and immune deposits usually not identified
Glomerular basement membrane disease (e.g. Alport syndrome)	Irregular GBM, usually segmental sclerosis	No immune deposits, multi-laminated GBM
Collagenofibrotic glomerulonephropathy	Mesangial hypercellularity with infrequent endocapillary hypercellularity	Mesangial expansion by fibrillar collagen with cross striations
Mixed GN	Mesangial/endocapillary hypercellularity	Immune complexes present in multiple locations within the glomerulus
Mesangioproliferative GN	Hypercellularity is confined to the mesangium	Immune complexes present within the mesangium and are not present in capillary walls

Key Diagnostic Features of Membranoproliferative Glomerulonephritis

- Thickening of glomerular capillary walls by immune complex deposits or GBM remodeling (double contours), as visualized by JMS
- Endocapillary hypercellularity
- Subendothelial and mesangial deposits, confirmed by IF and / or EM
- Requires silver stain, PAS, trichrome, IF and/or EM for diagnosis

Focal Segmental Glomerulosclerosis

- Focal segmental glomerulosclerosis (FSGS) describes both a disease entity characterized by primary injury to podocytes as well as a lesion that can occur secondarily in many types of chronic glomerular disease. As a disease entity, serial biopsies from FSGS patients (humans, dogs and cats) demonstrate disease progression with involvement of more and more glomeruli. Many physician nephropathologists use the term “advanced FSGS” instead of the more accurate morphologic term of “diffuse segmental to global glomerulosclerosis”. This preference is based on the desire to communicate to the clinician that the pathogenesis was primary podocyte injury.
- Histologic appearance – there is a focal and segmental pattern of sclerosis (scarring), which is defined as increased extracellular matrix leading to obliteration of capillary lumens and consolidation of part of the tuft.
    - With LM, the sclerosis involves some but not all glomeruli (focal as opposed to diffuse) and affects only a portion of the glomerular tuft (segmental as opposed to global).
    - Even though it is a focal lesion on light microscopy, there can be ultrastructural evidence of podocyte injury in many (or most) glomeruli. Therefore, proteinuric dogs can be diagnosed with FSGS even when only a single glomerulus is segmentally sclerotic on histology.
    - Segments of sclerosis stain pale pink with HE, blue with MT, black (argyrophilic) with JMS and magenta with PAS.
    - Lesions of sclerosis are often associated with synechiae (adhesions of the sclerotic segment to Bowman’s capsule) and may be accompanied by hyalinosis which is characterized by the accumulation of glassy, eosinophilic material due to the entrapment of plasma proteins.
    - In dogs, location of the sclerosis (e.g. hilus or tip) has (to the best of our knowledge) no prognostic implications. This is in contrast to FSGS in people.
- Transmission electron microscopy in cases of FSGS reveals multifocal or extensive effacement of podocyte foot processes.
    - Presence of electron dense deposits or significant alterations in the glomerular basement membrane indicates that the segmental scarring is secondary.
- Immunofluorescence evaluation shows no granular positivity with IgG and C3 but may show some non-specific entrapment of IgM and C3 in sclerotic areas or in the mesangial matrix. The staining pattern is splotchy and not granular.
    - Granular labeling for immunoglobulins and complement indicate that the segmental scarring is secondary.
- The disease of FSGS is considered to be a podocytopathy, and in humans podocyte injury and

loss may be primary or secondary. Primary (or idiopathic) FSGS is assumed to be due to innate defects in podocyte or slit diaphragm genes and proteins. Secondary (or adaptive) FSGS can be due to hyperfiltration which is expected to occur in hypertension (humans and dogs), nephron paucity leading to glomerular compensatory hypertrophy (humans and dogs) and obesity (humans). Direct podocyte toxins or viral infections are also known to be causes in humans but are poorly documented in dogs.

- Causes of FSGS in dogs remain largely unknown. In proteinuric soft-coated Wheaten Terriers, mutations in NPHS1 and KIRREL2, which encode nephrin and filtrin respectively, have been proposed to lead to FSGS. These proteins are part of the glomerular filtration barrier; however the exact pathogenesis of the effects of the mutations has not been elucidated.
- As mentioned above, glomerular scarring in a focal and segmental *pattern* can occur in dogs secondary to immune complex-mediated glomerulonephritis. This should be clearly differentiated from cases of FSGS (in which immune complexes are not part of the pathogenesis).

Clinical Features of Focal Segmental Glomerulosclerosis (FSGS)

- Initial sign is typically moderate to marked proteinuria (UPC > 2), although median UPC is lower than most other categories of glomerular disease, and rare cases can have a UPC < 0.5. Dogs with glomerulosclerosis are more likely to have normal serum albumin concentration compared with many of the other categories of glomerular disease.
- Azotemia develops with progression of sclerosis and nephron loss due to persistence/ progression of disease.
- Moderate hypertension is frequently observed and can be the inciting cause of this disease.
- Dogs <1 year of age are unlikely to have FSGS
- Breeds in which familial glomerulosclerosis has been identified include: Soft-coated wheaten terrier (Littman 2013), Airedale terrier, and Miniature Schnauzer dogs.

EARLY FSGS: One of the earliest events in FSGS is podocyte injury and effacement. This can lead to an adhesion of the glomerular tuft to Bowman's capsule (synechia).

An interactive or media element has been excluded from this version of the text. You can view it online here:
https://ohiostate.pressbooks.pub/vetrenalpathatlas/?p=342

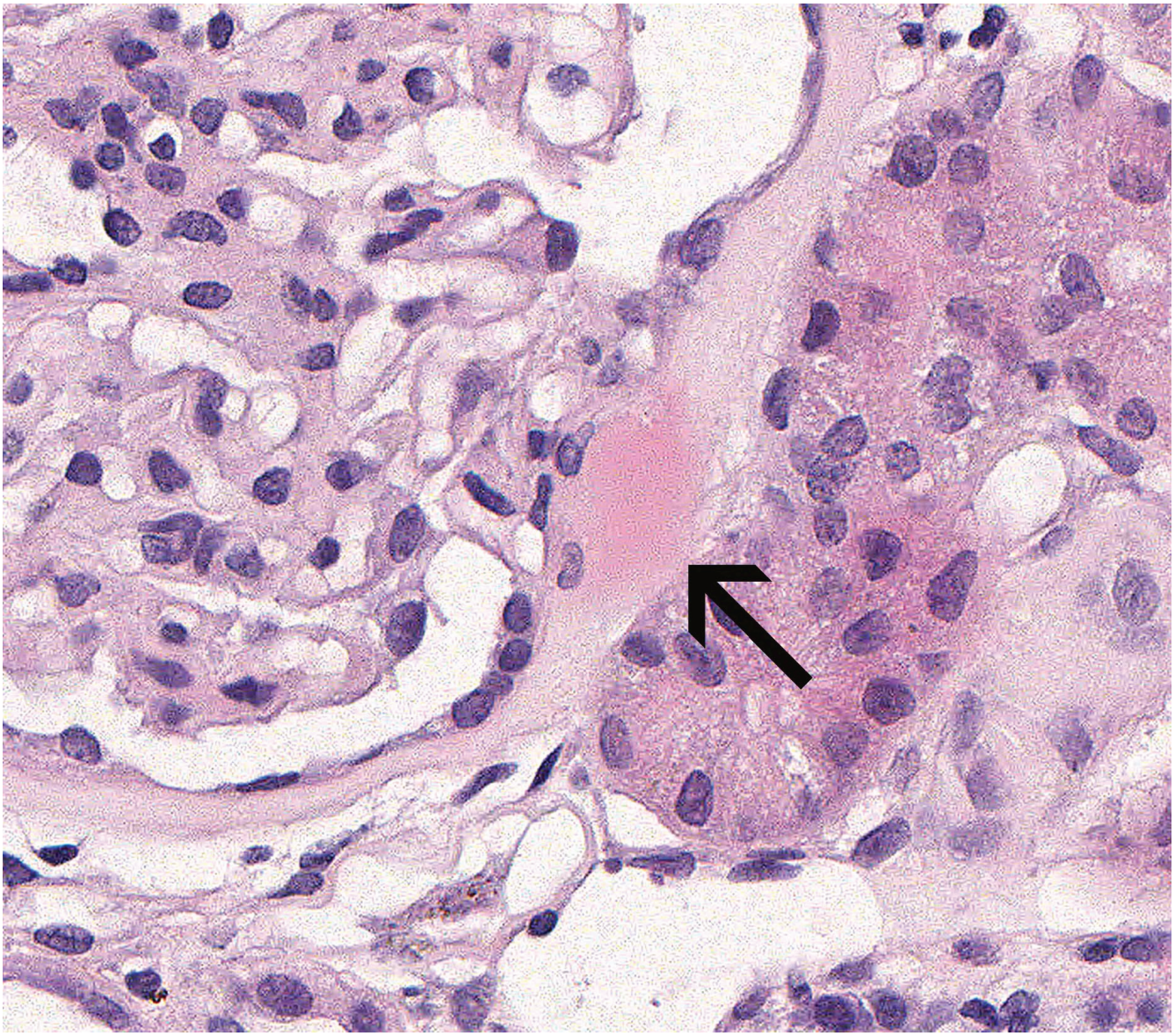

FIG.1A (HE): The glomerulus has a synechia and hyalinosis of Bowman's capsule at the tip of the tuft (arrow).

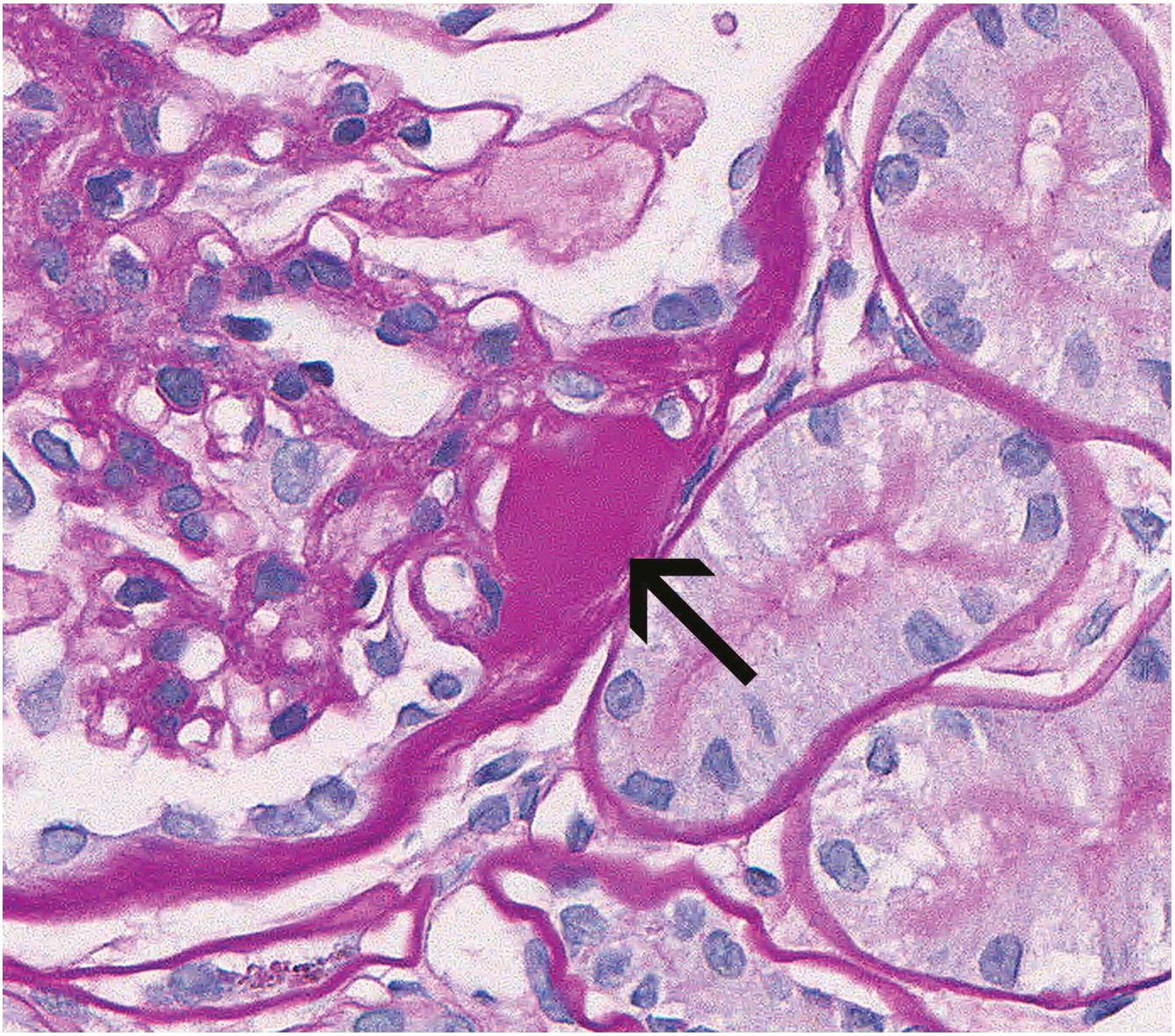

FIG.1B (PAS): The glomerulus has a synechia and hyalinosis at the tip of the tuft (arrow). On the PAS stain, hyalinosis is bright magenta.

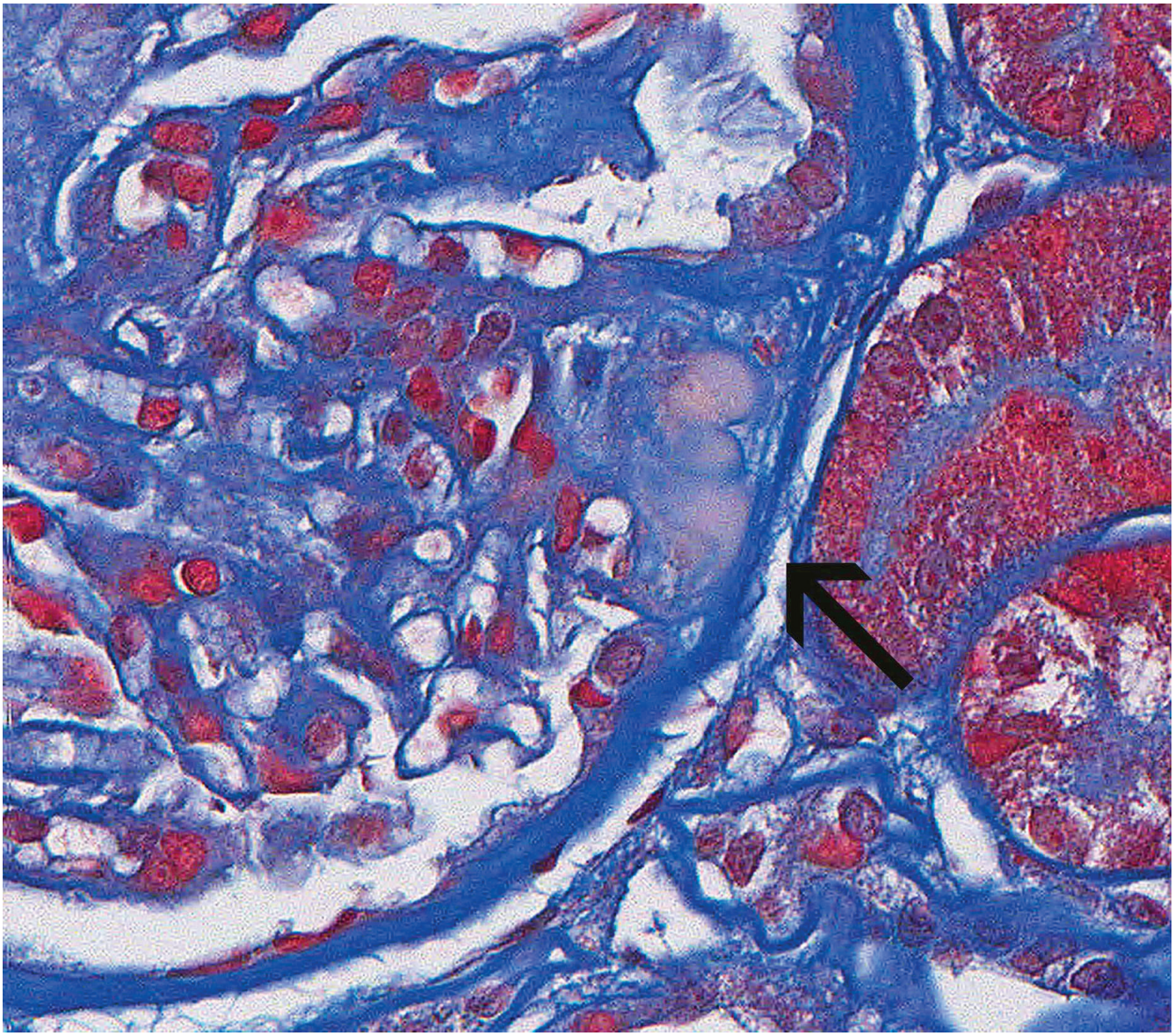

FIG.1C (MT): The glomerulus has a synechia at the tip of the tuft (arrow). On the trichrome stain, hyalinosis is slightly peach to orange.

FIG.1D (JMS): The glomerulus has a synechia at the tip of the tuft (arrow). Hyalinosis does not take up silver and appears pink from the counterstain.

An interactive or media element has been excluded from this version of the text. You can view it online here:
https://ohiostate.pressbooks.pub/vetrenalpathatlas/?p=342

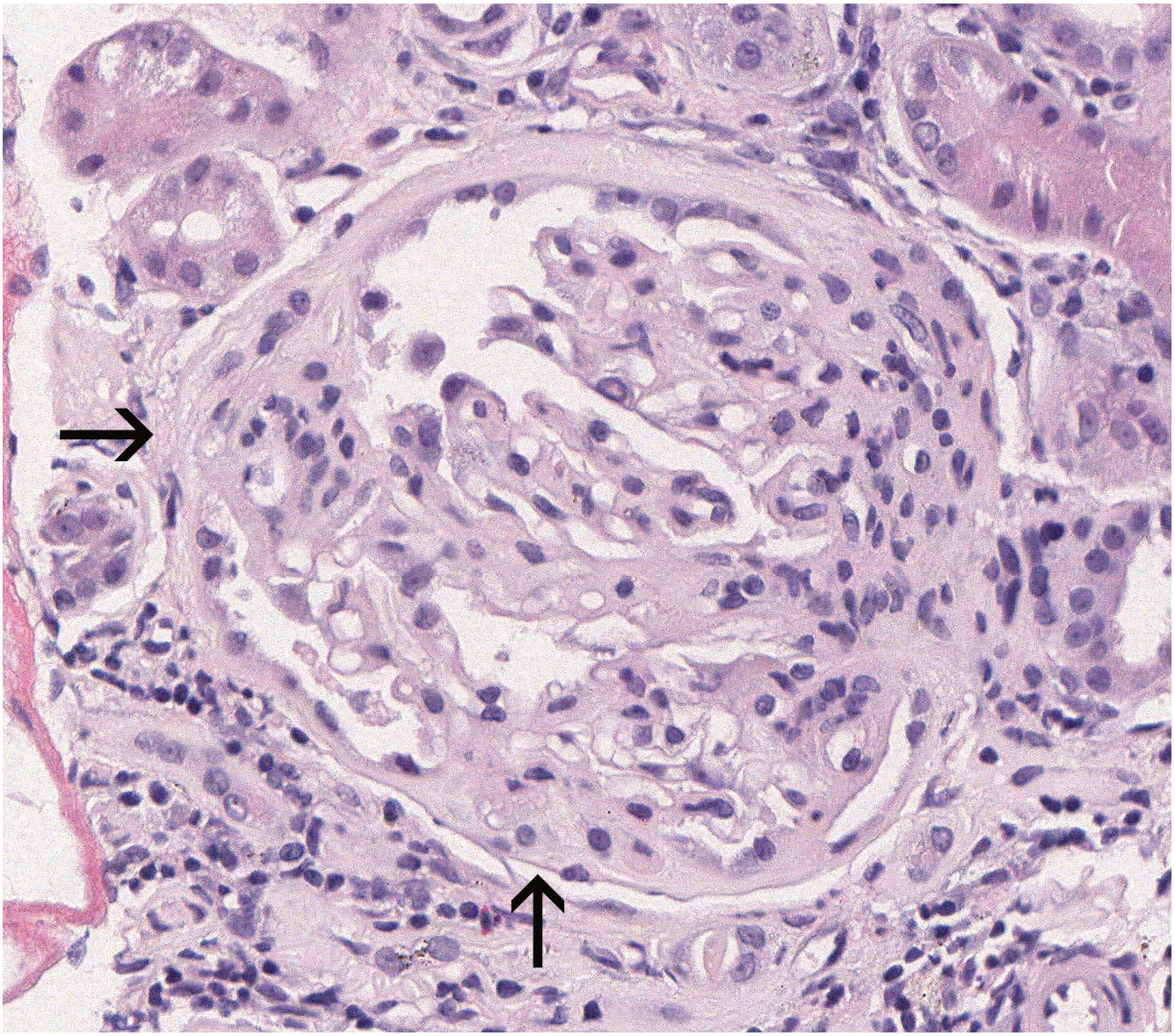

FIG.2A (HE): This glomerulus has two sclerotic regions with synechiae (arrows). Near the location of the lower arrow, Bowman's capsule is artifactually separated from the interstitium.

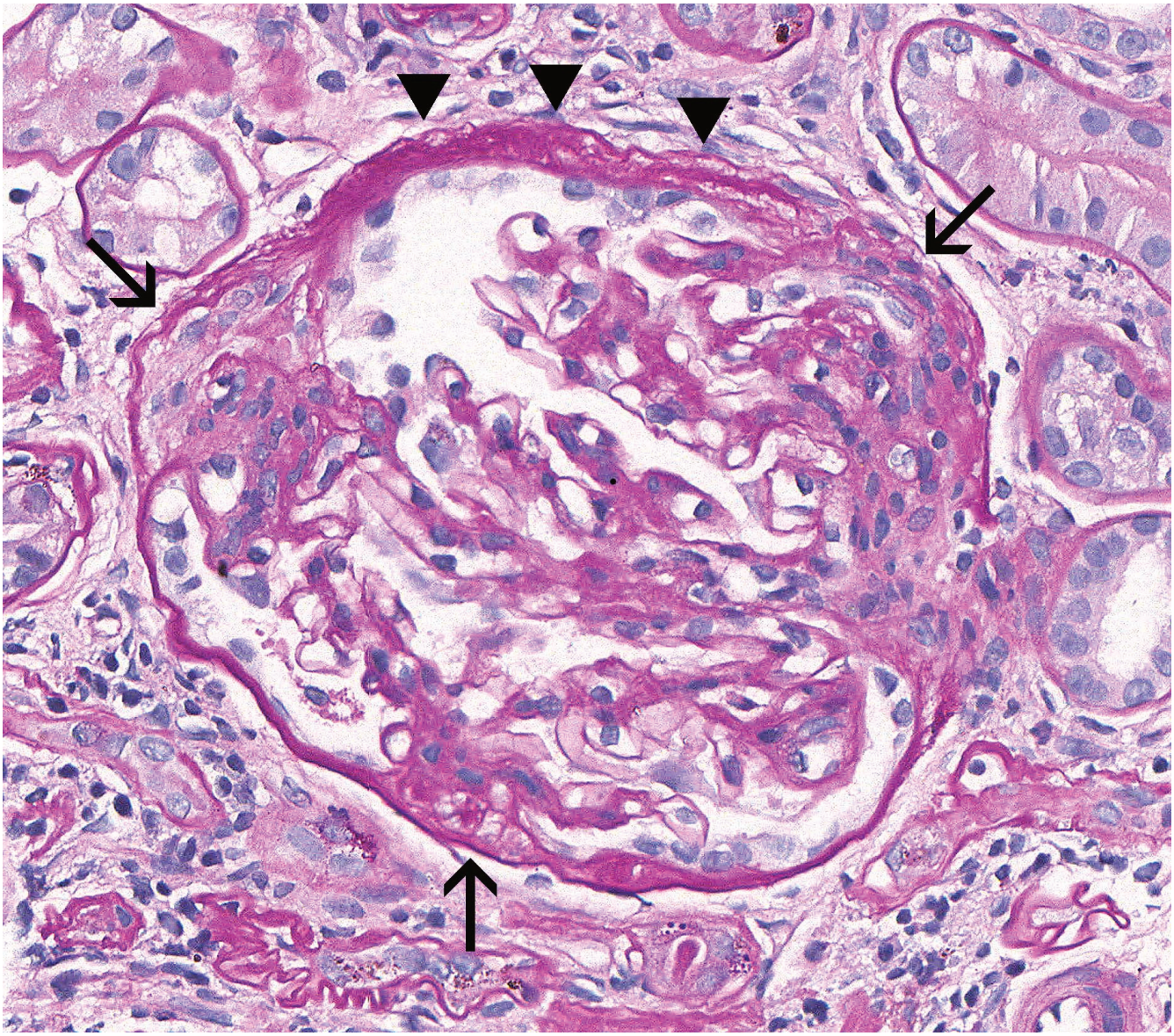

FIG.2B (PAS): This glomerulus demonstrates a wrinkled, multi-laminated Bowman's capsule (arrowheads) and multiple synechiae (arrows).

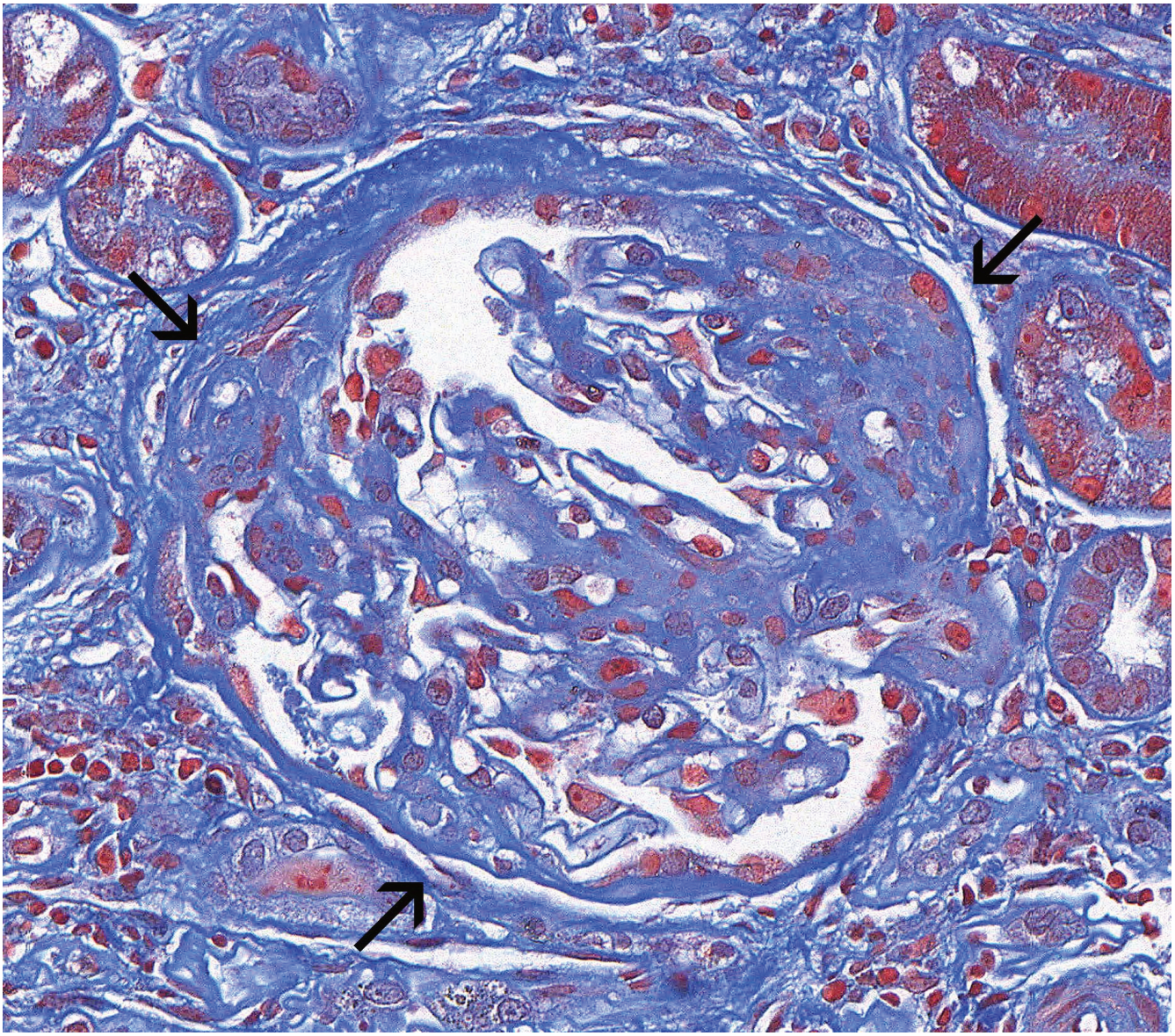

FIG.2C (MT): This glomerulus has multiple synechiae (arrows).

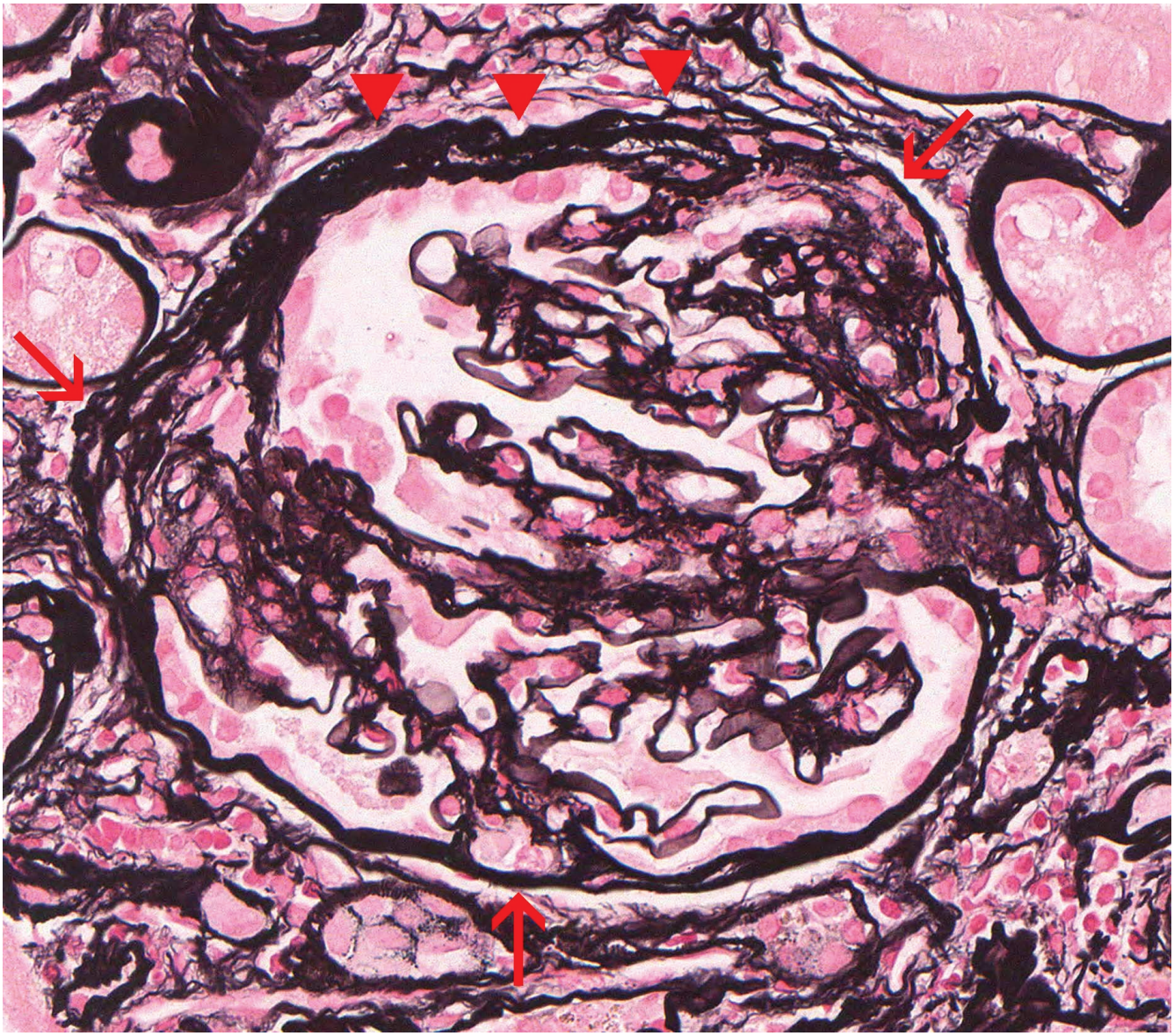

FIG.2D (JMS): This glomerulus demonstrates a wrinkled, multi-laminated Bowman's capsule (arrowheads) and multiple synechiae (arrows).

PODOCYTE INJURY: Evidence of podocyte injury includes hypertrophy and cytoplasmic protein droplets. After the death or detachments of podocytes overlying a segment of a glomerular tuft, the underlying capillary lumens become effaced by extracellular matrix (sclerosis) and insudated plasma (hyalinosis).

An interactive or media element has been excluded from this version of the text. You can view it online here:
https://ohiostate.pressbooks.pub/vetrenalpathatlas/?p=342

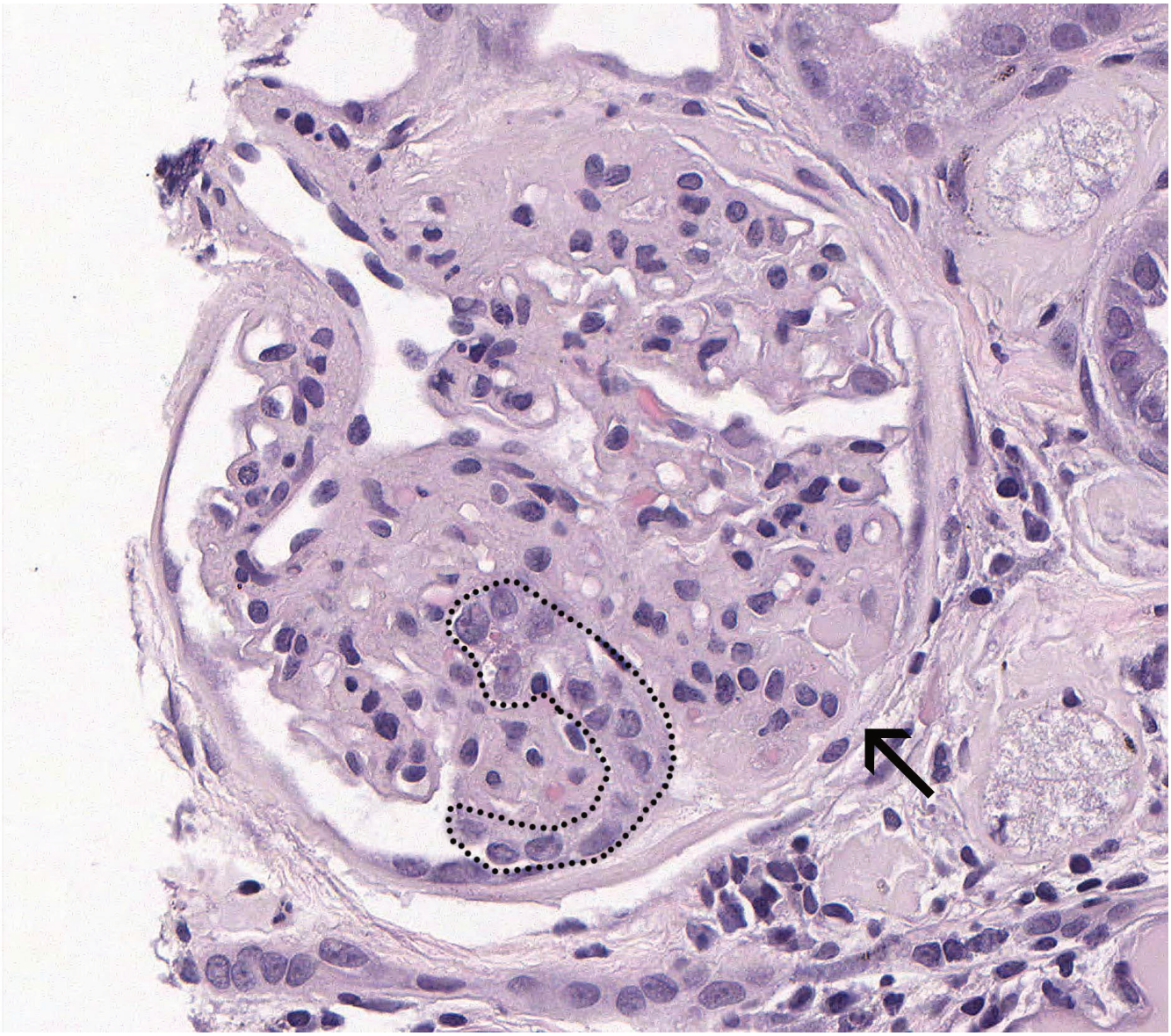

FIG.3A (HE): This glomerulus demonstrates hypertrophied podocytes (outlined) and a synechia between a segment of sclerosis and Bowman's capsule (arrow).

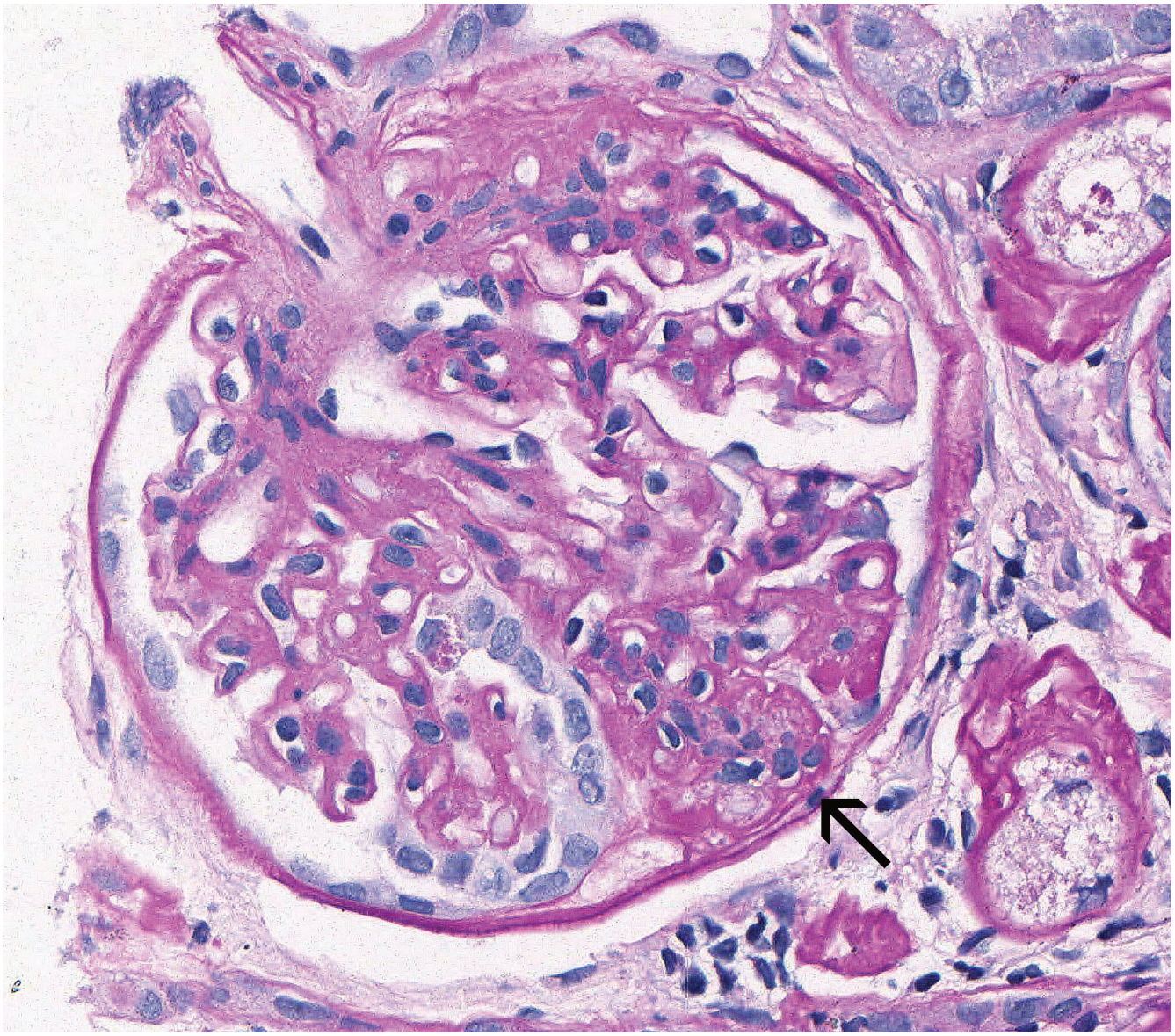

FIG.3B (PAS): This glomerulus demonstrates hypertrophied podocytes. The PAS stain helps differentiate the podocyte cytoplasm from the underlying capillary walls. One of the podocytes has prominent protein droplets in the cytoplasm. The synechia between the sclerotic segment and Bowman's capsule is also present (arrow).

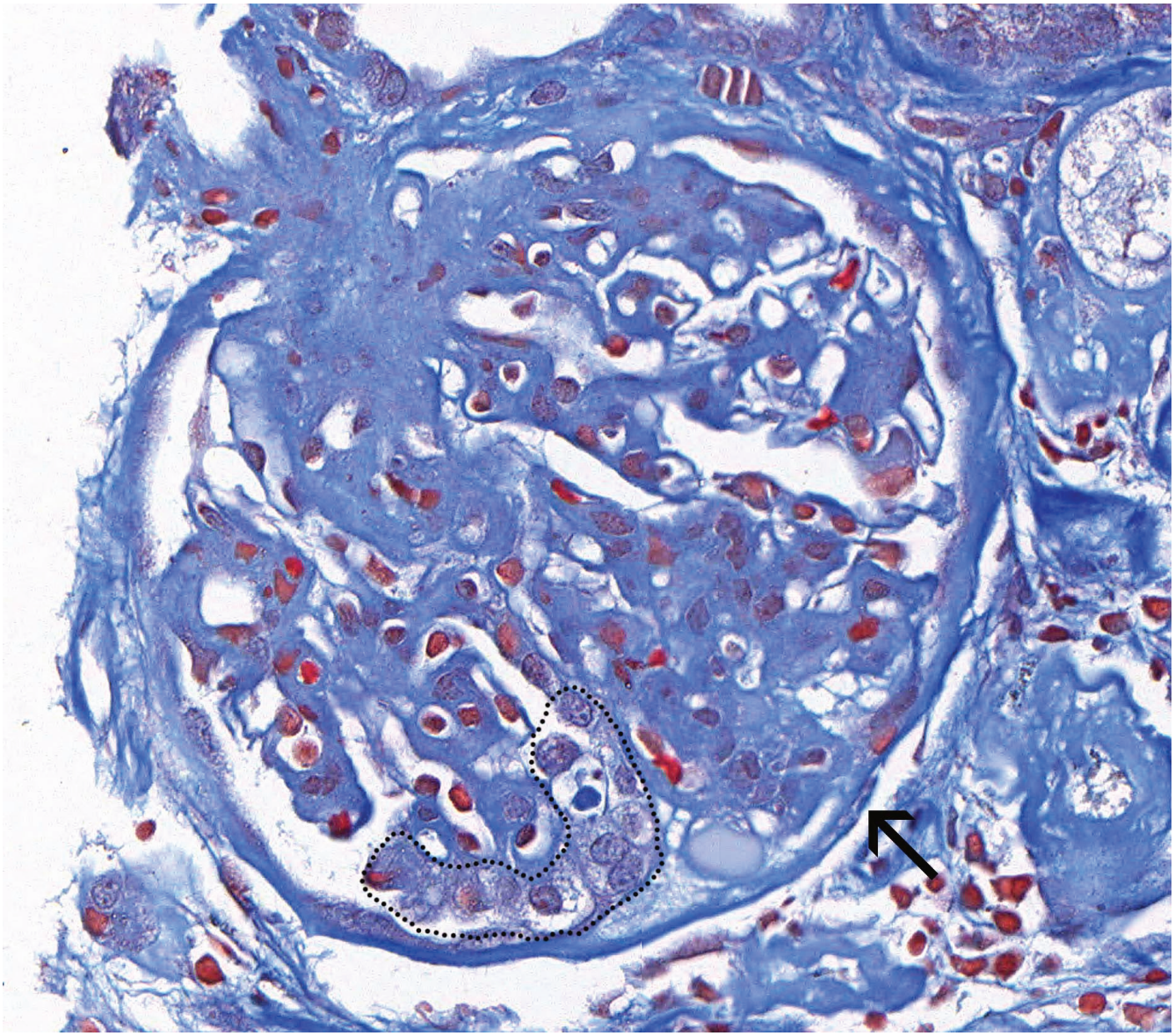

FIG. 3C (MT): This glomerulus demonstrates hypertrophied podocytes (outlined) and a synechia between a segment of sclerosis and Bowman's capsule (arrow).

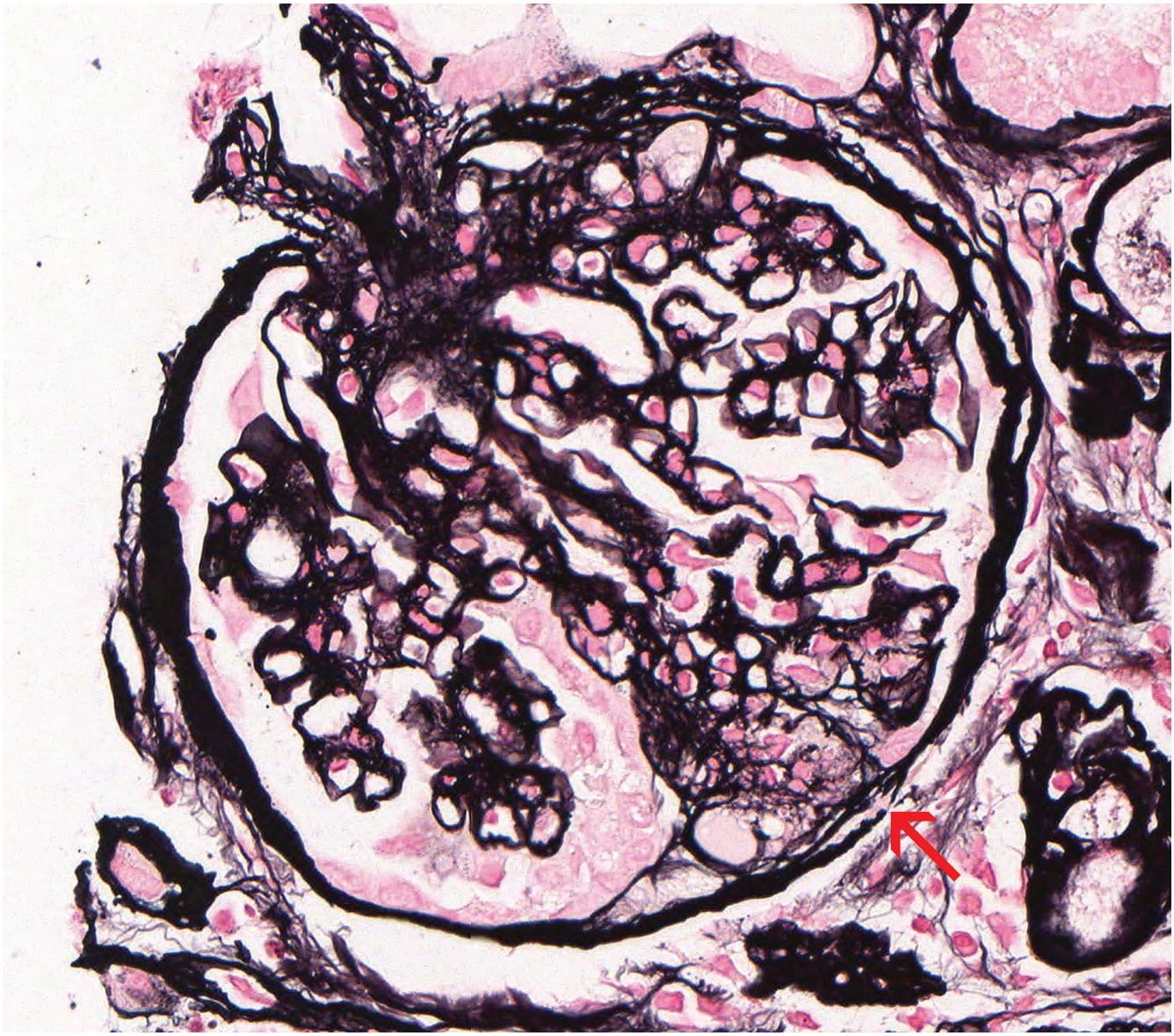

FIG.3D (JMS): This glomerulus demonstrates hypertrophied podocytes and larger synechiae (arrow). The JMS method helps differentiate the podocyte cytoplasm from the underlying capillary walls.

MORE FEATURES OF THE FSGS PATTERN: It is common to see normal glomeruli (which have not yet had podocyte damage) adjacent to segmentally sclerotic glomeruli.

An interactive or media element has been excluded from this version of the text. You can view it online here:
https://ohiostate.pressbooks.pub/vetrenalpathatlas/?p=342

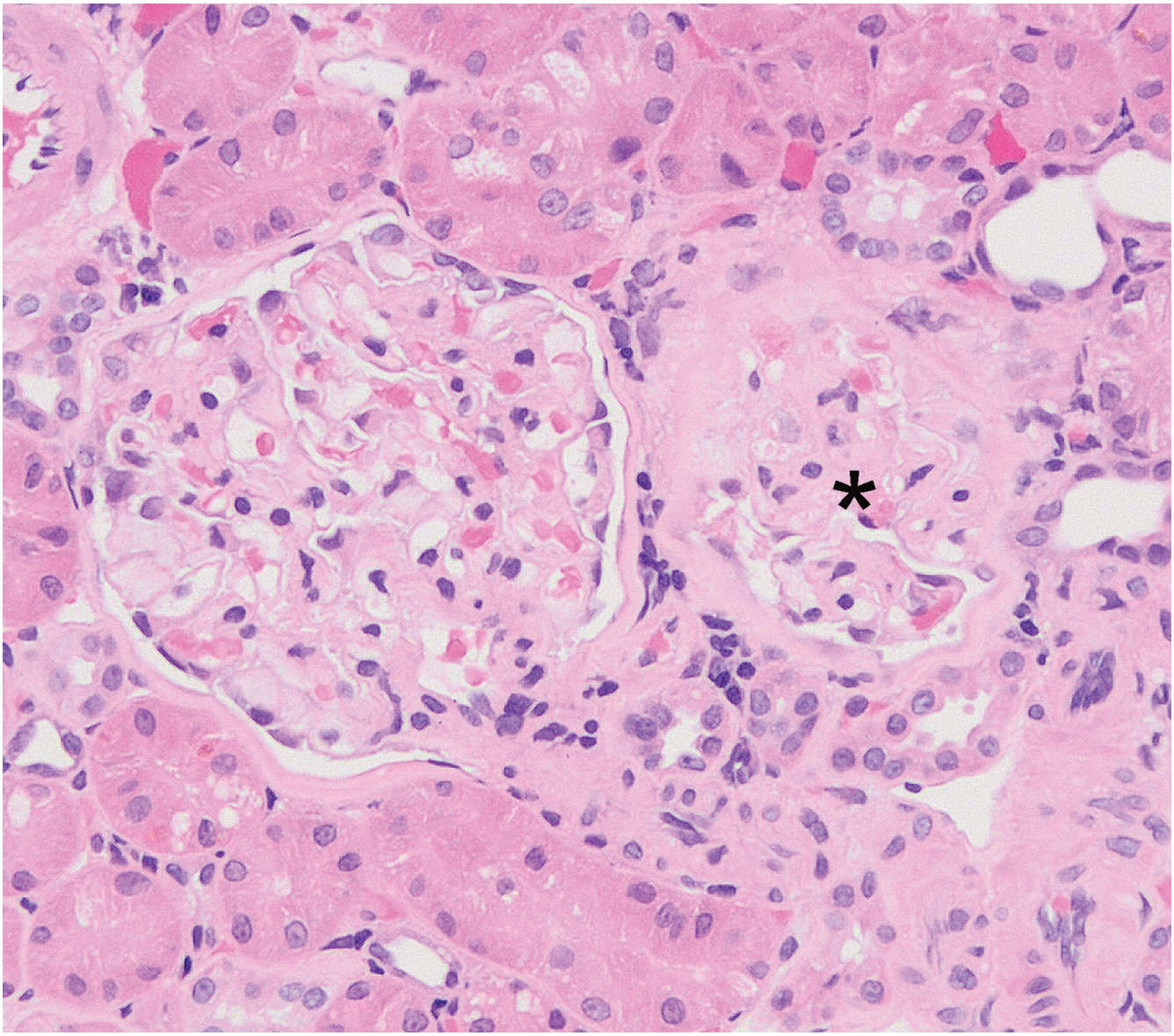

FIG.4A (HE): One glomerulus (left) is normal, and the other glomerulus (asterisk) has segmental sclerosis.

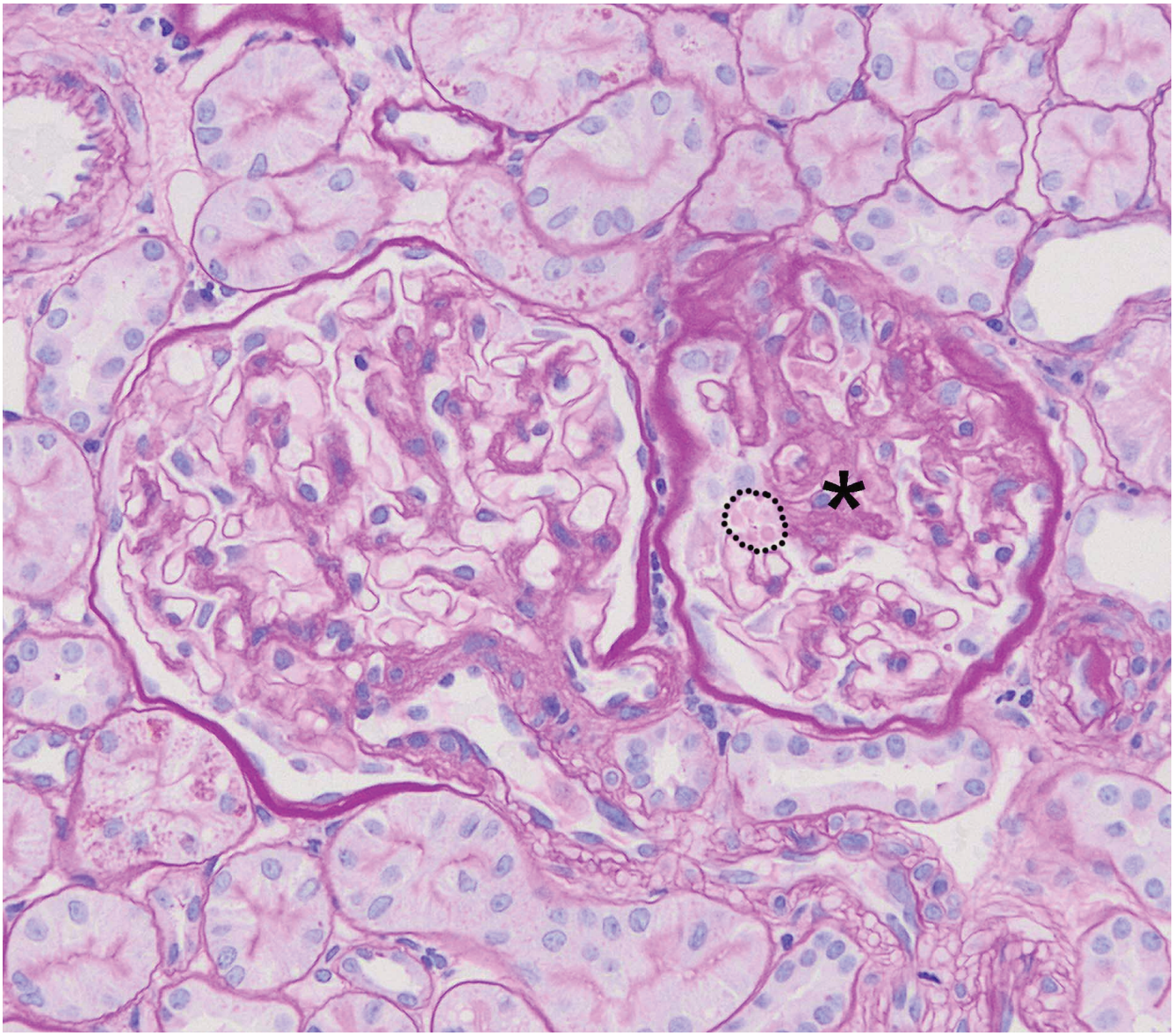

FIG.4B (PAS): One glomerulus (left) is normal, and the other glomerulus (asterisk) has segmental sclerosis. The podocytes overlying the sclerotic portion of the glomerulus have large pale pink protein droplets in the cytoplasm (outlined with dotted line).

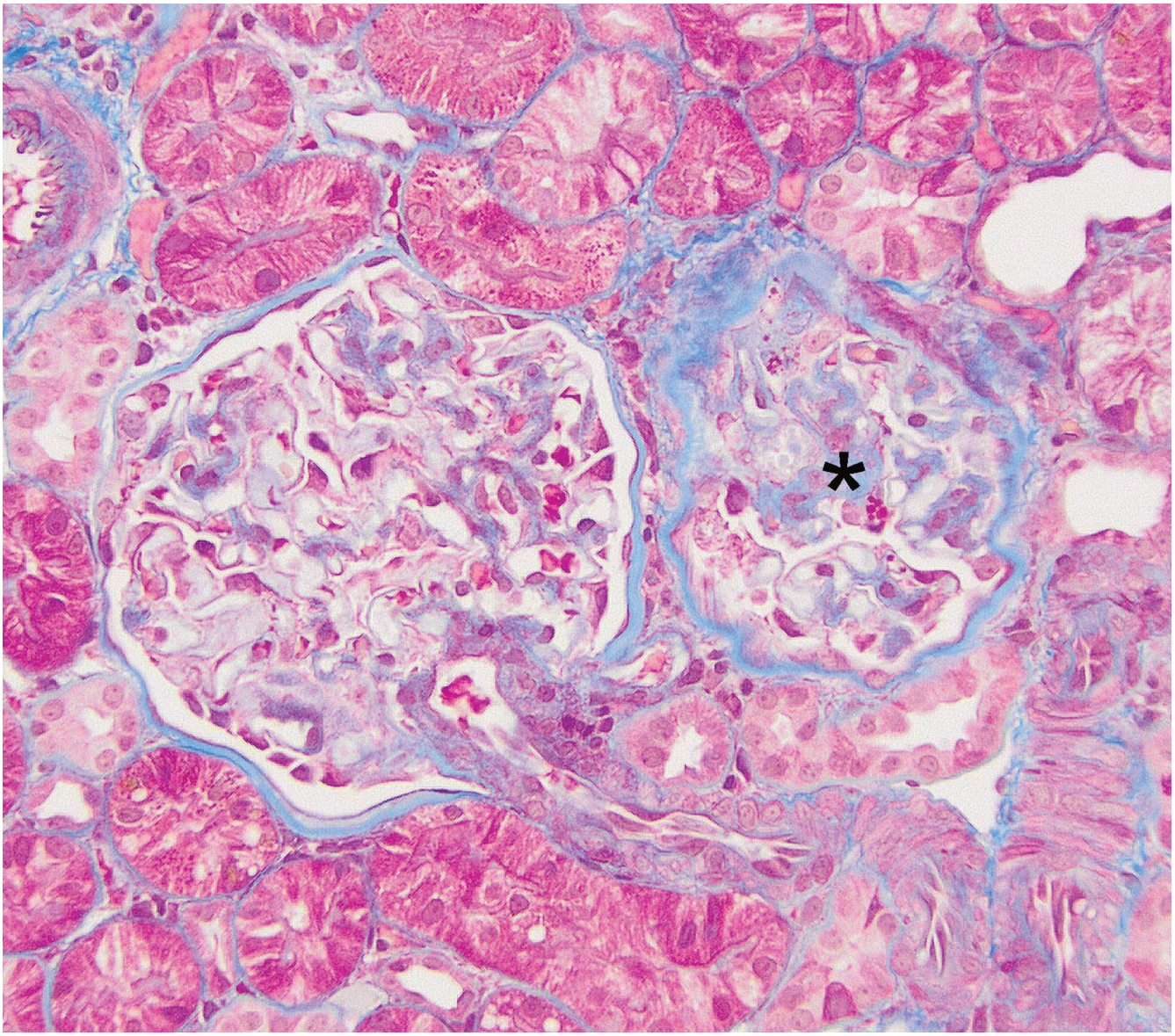

FIG.4C (MT): One glomerulus (left) is normal, and the other glomerulus (asterisk) has segmental sclerosis. The podocytes overlying the sclerotic portion of the glomerulus have large bright red protein droplets in the cytoplasm.

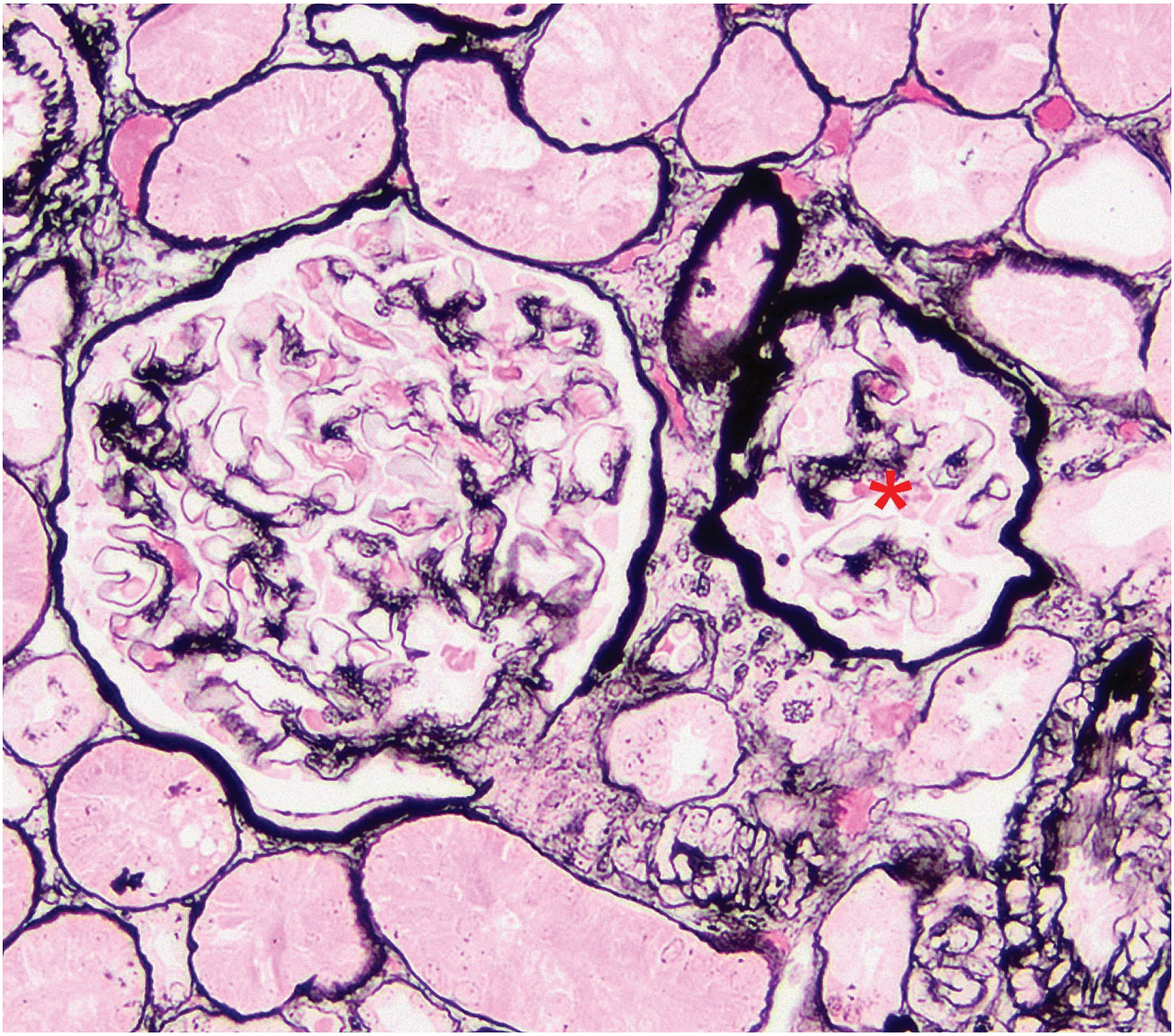

FIG.4D (JMS): One glomerulus (left) is normal, and the other glomerulus (asterisk) has segmental sclerosis.

An interactive or media element has been excluded from this version of the text. You can view it online here:
https://ohiostate.pressbooks.pub/vetrenalpathatlas/?p=342

FIG.5A (HE): There is effacement of capillary lumens by segmental sclerosis near the hilus (circle) of the tuft and hypertrophy of the parietal epithelium and podocytes.

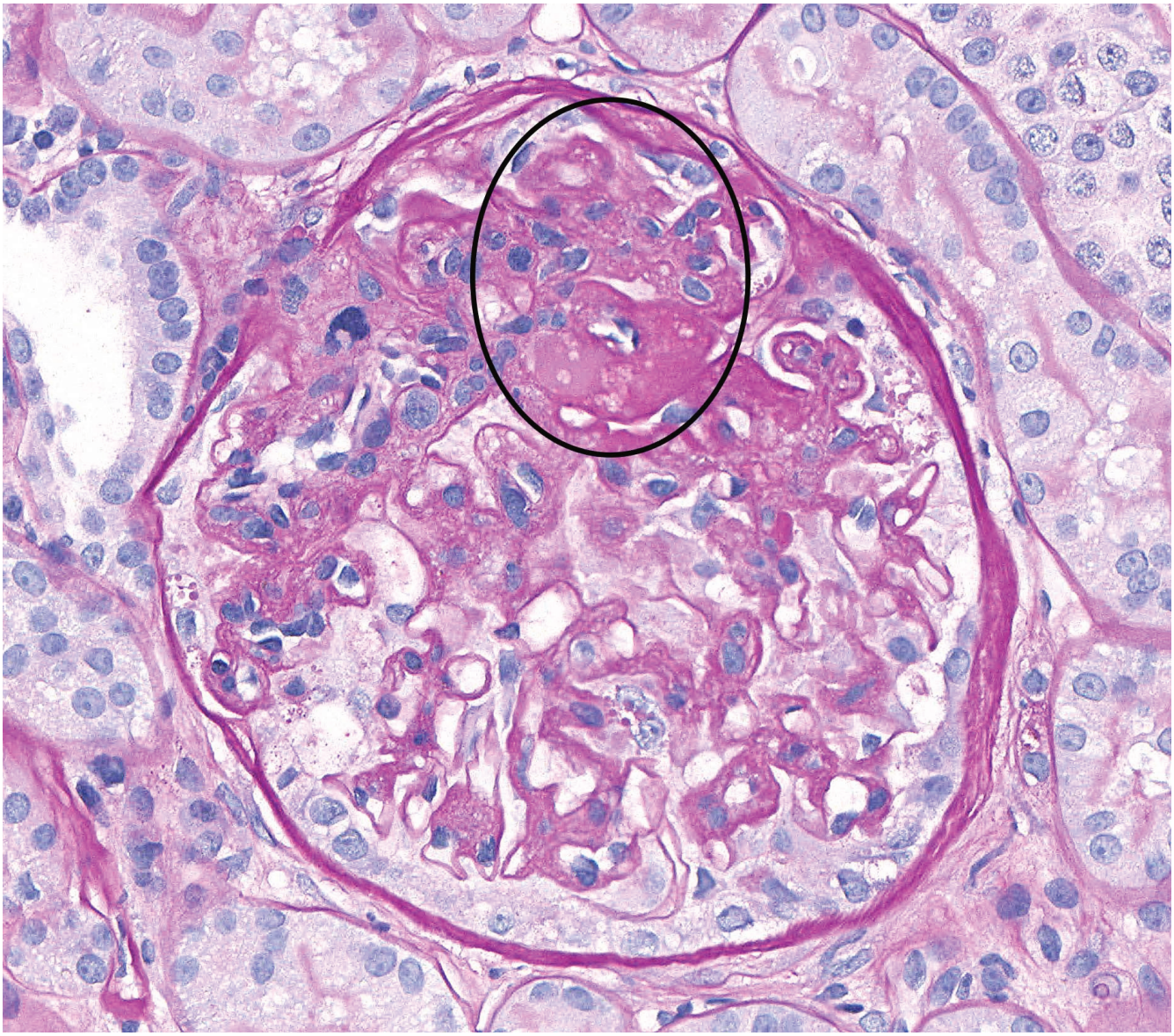

FIG.5B (PAS): There is effacement of capillary lumens by segmental sclerosis and a synechia at the hilus (circled) of the tuft and hypertrophy of the parietal epithelium. The PAS stain clearly delineates the cytoplasm of the podocytes and parietal epithelial cells from the glomerular capillary wall and Bowman's capsule.

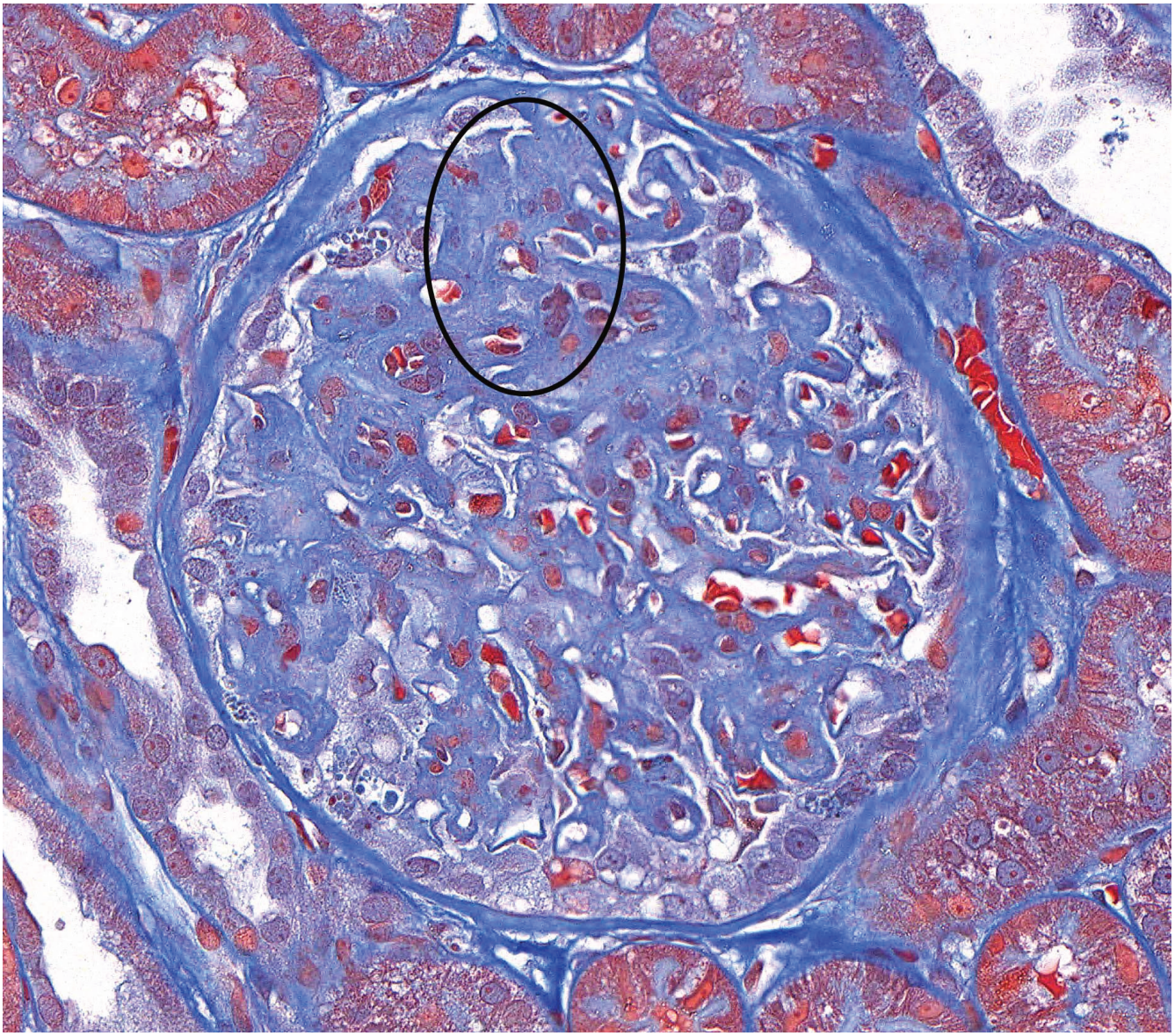

FIG.5C (MT): There is segmental sclerosis and a synechia at the hilus of the tuft (circled) and hypertrophy of the parietal epithelium.

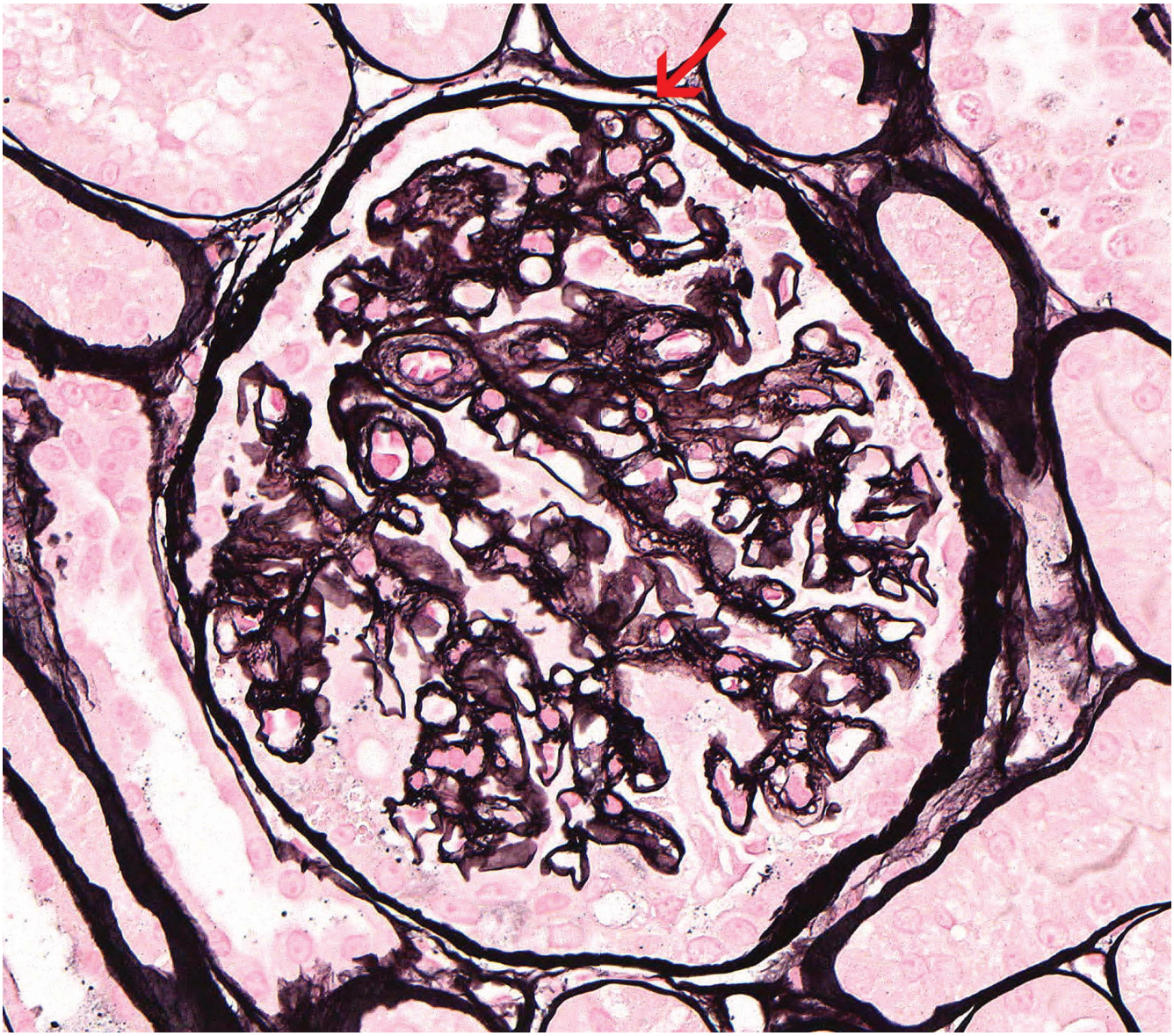

FIG.5D (JMS): A small synechia is at the location of the sclerotic segment (arrow). The JMS method clearly demonstrates the adhesion between the tuft and Bowman's capsule.

LATE STAGES OF FSGS: As glomerular damage progresses, many of the segmentally sclerotic glomeruli become globally sclerotic and non-functional.

An interactive or media element has been excluded from this version of the text. You can view it online here:
https://ohiostate.pressbooks.pub/vetrenalpathatlas/?p=342

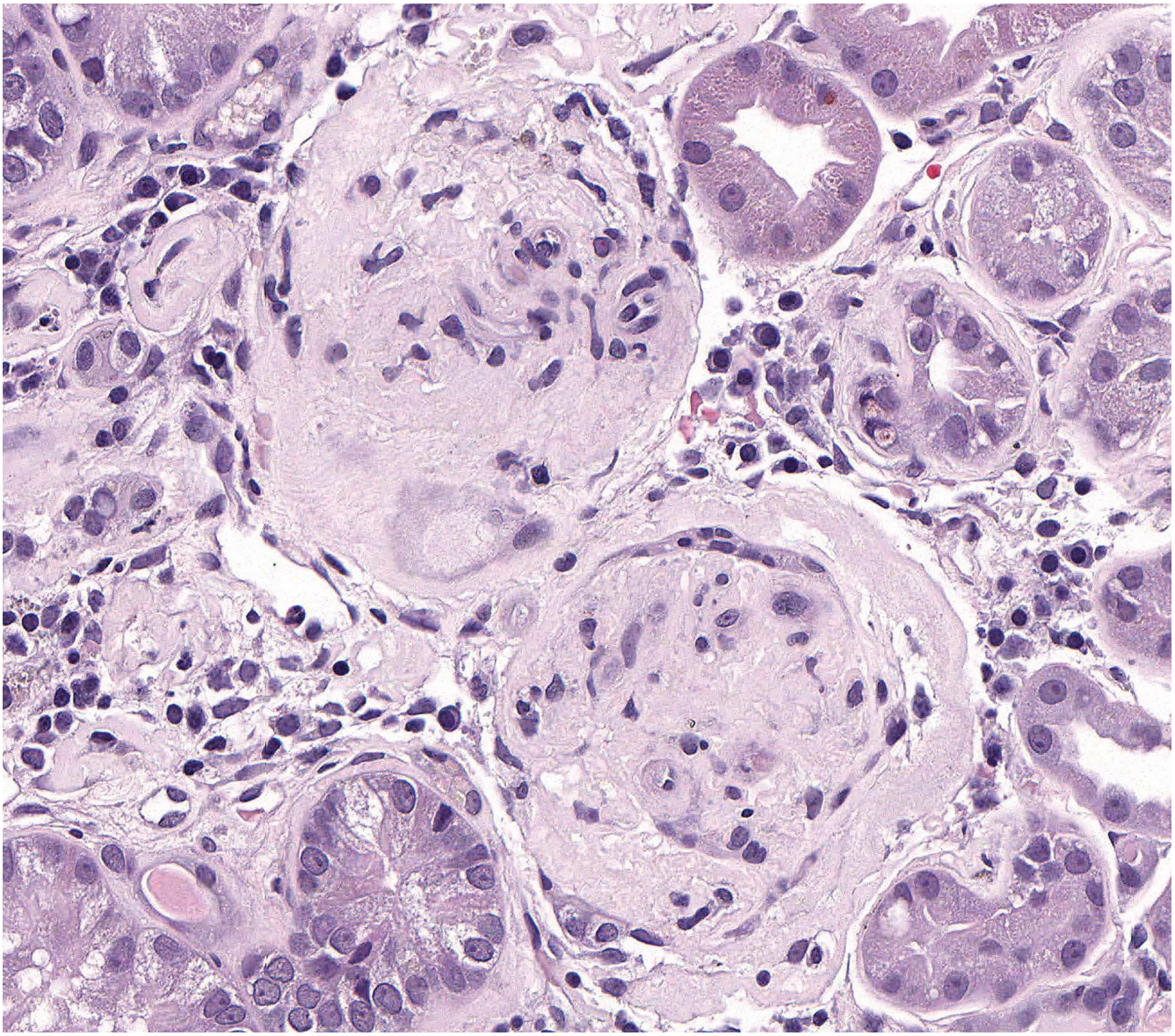

FIG.6A (HE): Both glomeruli in this section are globally sclerotic (obsolescent). Glomerular capillary lumens cannot be identified and glomeruli are small and hypocellular. They also have thickened Bowman's capsules.

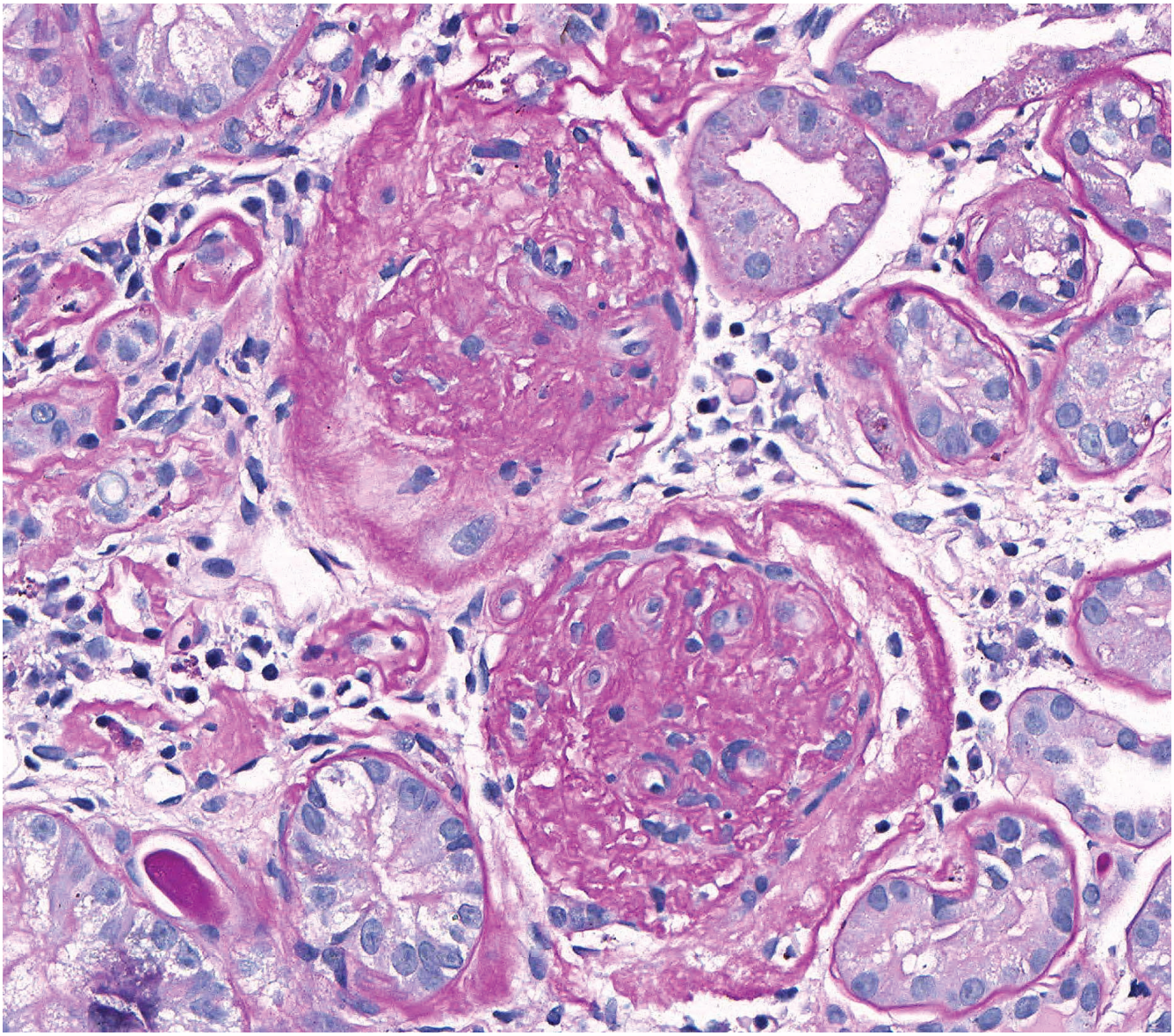

FIG.6B (PAS): Both glomeruli in this section are globally sclerotic. Glomerular capillary lumens cannot be identified and glomeruli are hypocellular. They also have thickened, wrinkled Bowman's capsules.

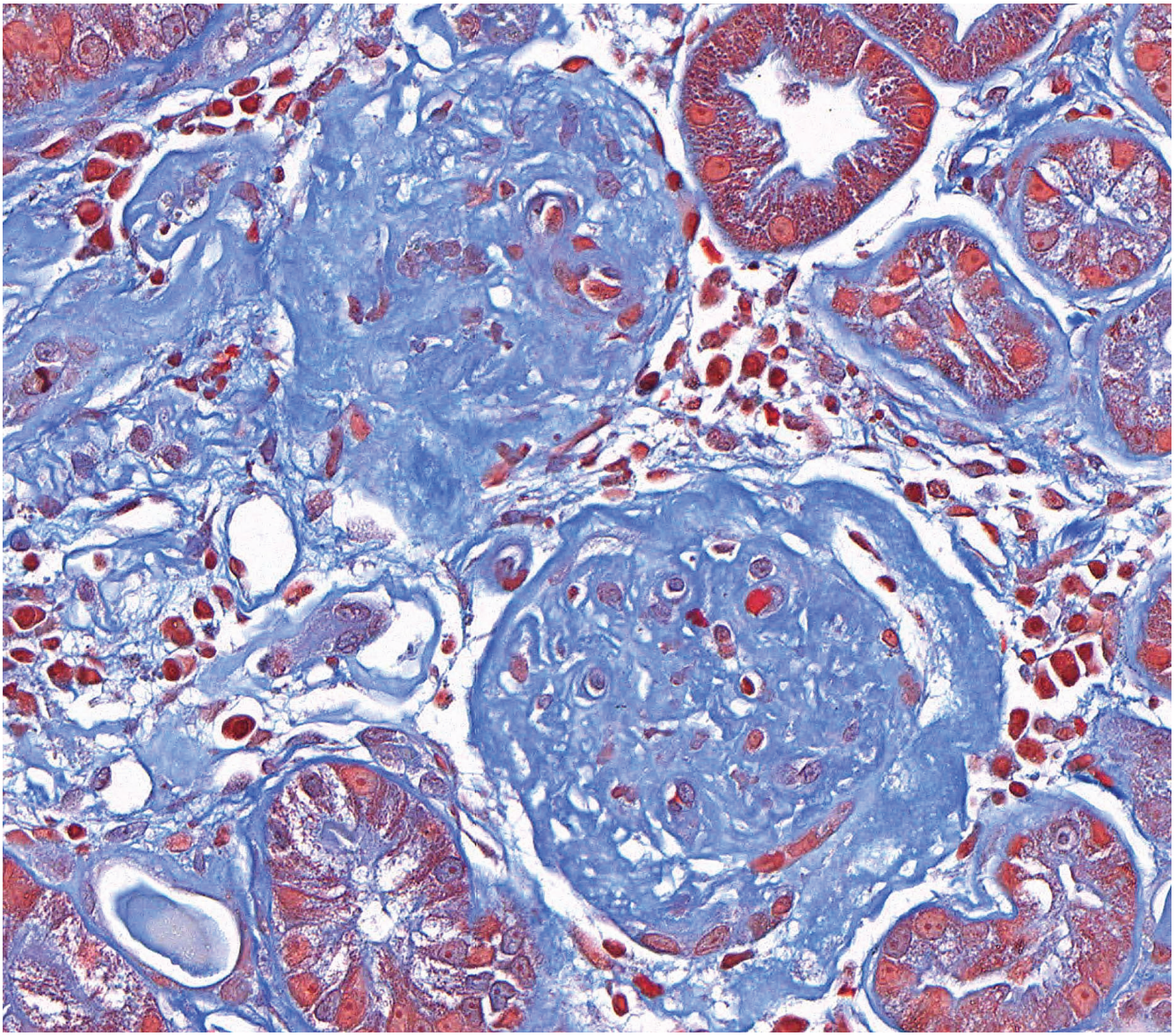

FIG.6C (MT): Both glomeruli in this section are globally sclerotic. Glomerular capillary lumens cannot be identified and glomeruli are hypocellular. They also have thickened, wrinkled Bowman's capsules.

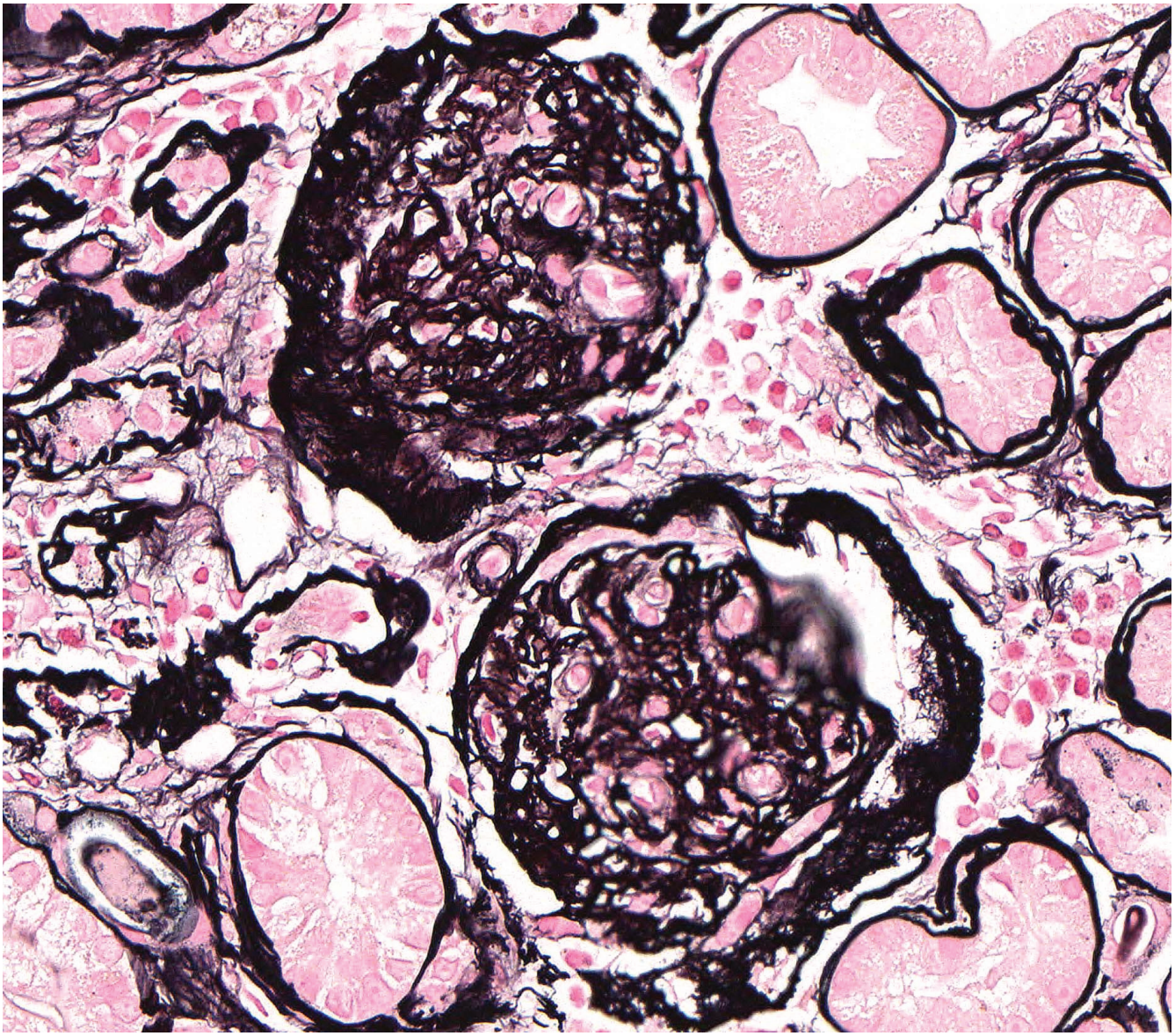

FIG.6D (JMS): Both glomeruli in this section are globally sclerotic and have thickened Bowman's capsules. Glomerular capillary lumens cannot be identified and glomeruli are hypocellular. They also have thickened Bowman's capsules.

An interactive or media element has been excluded from this version of the text. You can view it online here:
https://ohiostate.pressbooks.pub/vetrenalpathatlas/?p=342

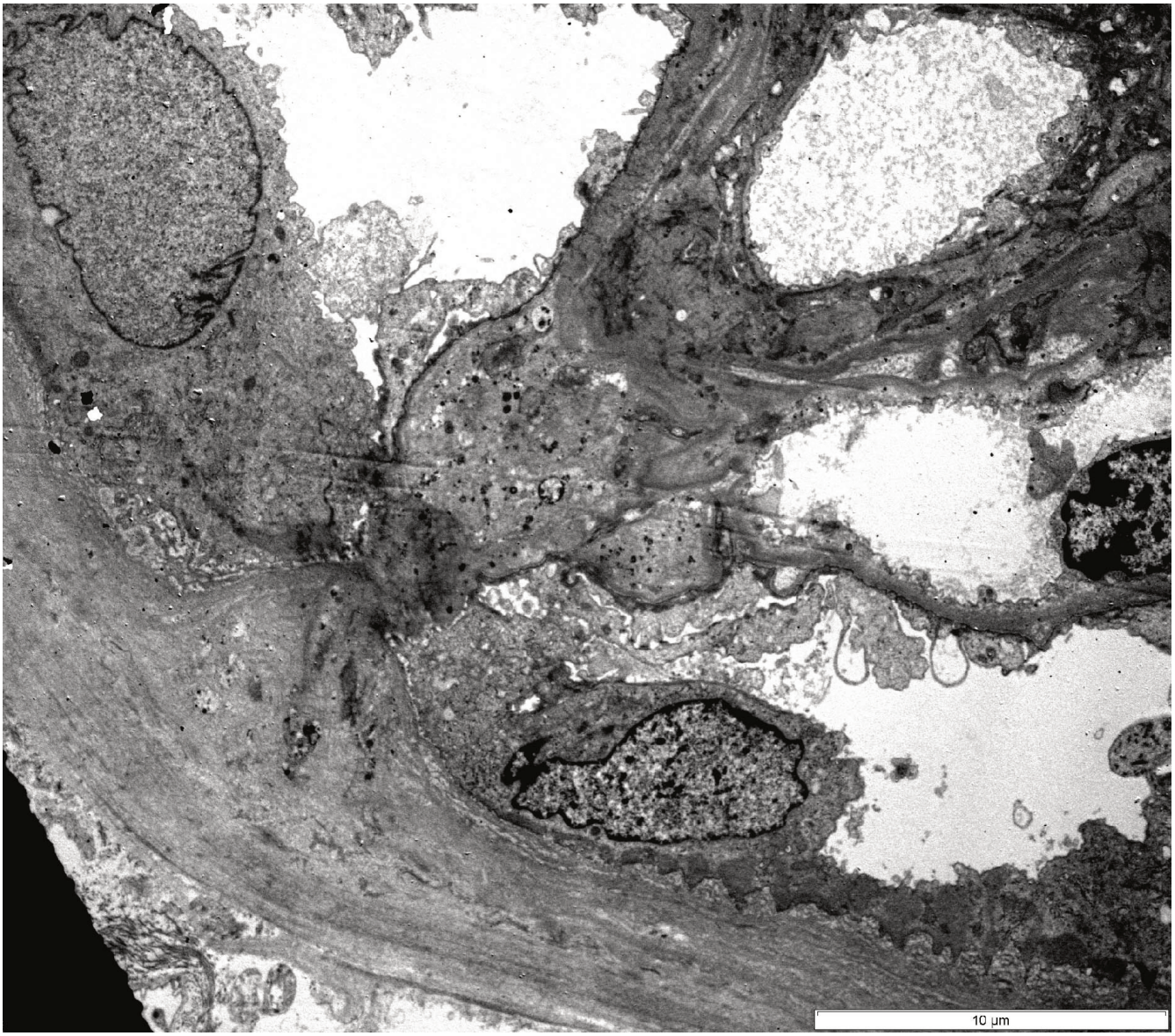

FIG.7A (TEM): Transmission electron micrograph of a synechia.

An interactive or media element has been excluded from this version of the text. You can view it online here:
https://ohiostate.pressbooks.pub/vetrenalpathatlas/?p=342

FIG.7B (TEM): Colorized version of above TEM image. (Yellow: endothelial cell, Green: GBM, Pink: podocyte, Lavender: Bowman's capsule; Purple: parietal epithelial cell).

An interactive or media element has been excluded from this version of the text. You can view it online here:
https://ohiostate.pressbooks.pub/vetrenalpathatlas/?p=342

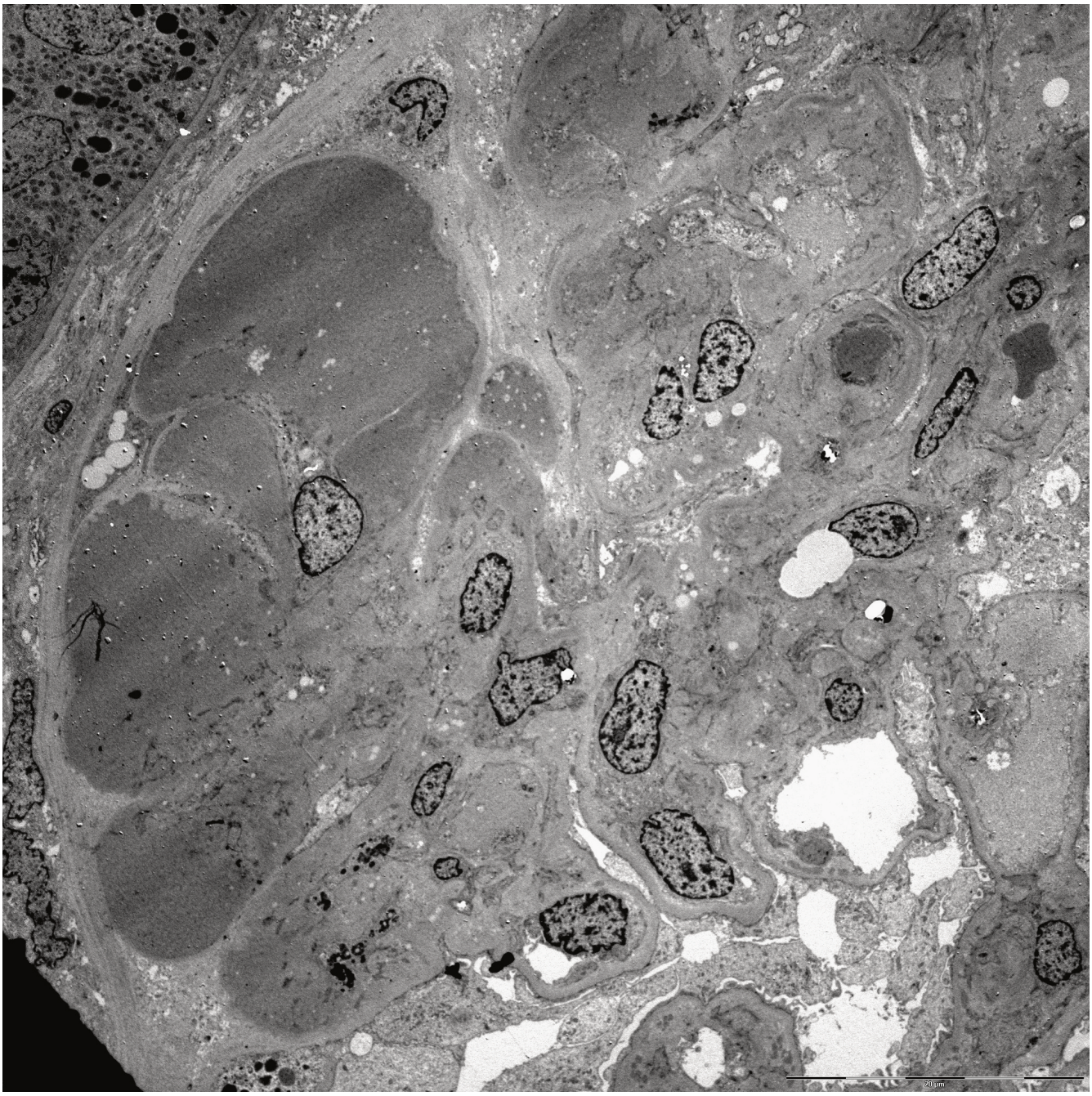

FIG.7C (TEM): One segment of the glomerular tuft is effaced by insudated plasma (hyalinosis) and extracellular matrix. The overlying podocytes have detached and the sclerotic segment is attached to Bowman's capsule (synechia).

An interactive or media element has been excluded from this version of the text. You can view it online here:
https://ohiostate.pressbooks.pub/vetrenalpathatlas/?p=342

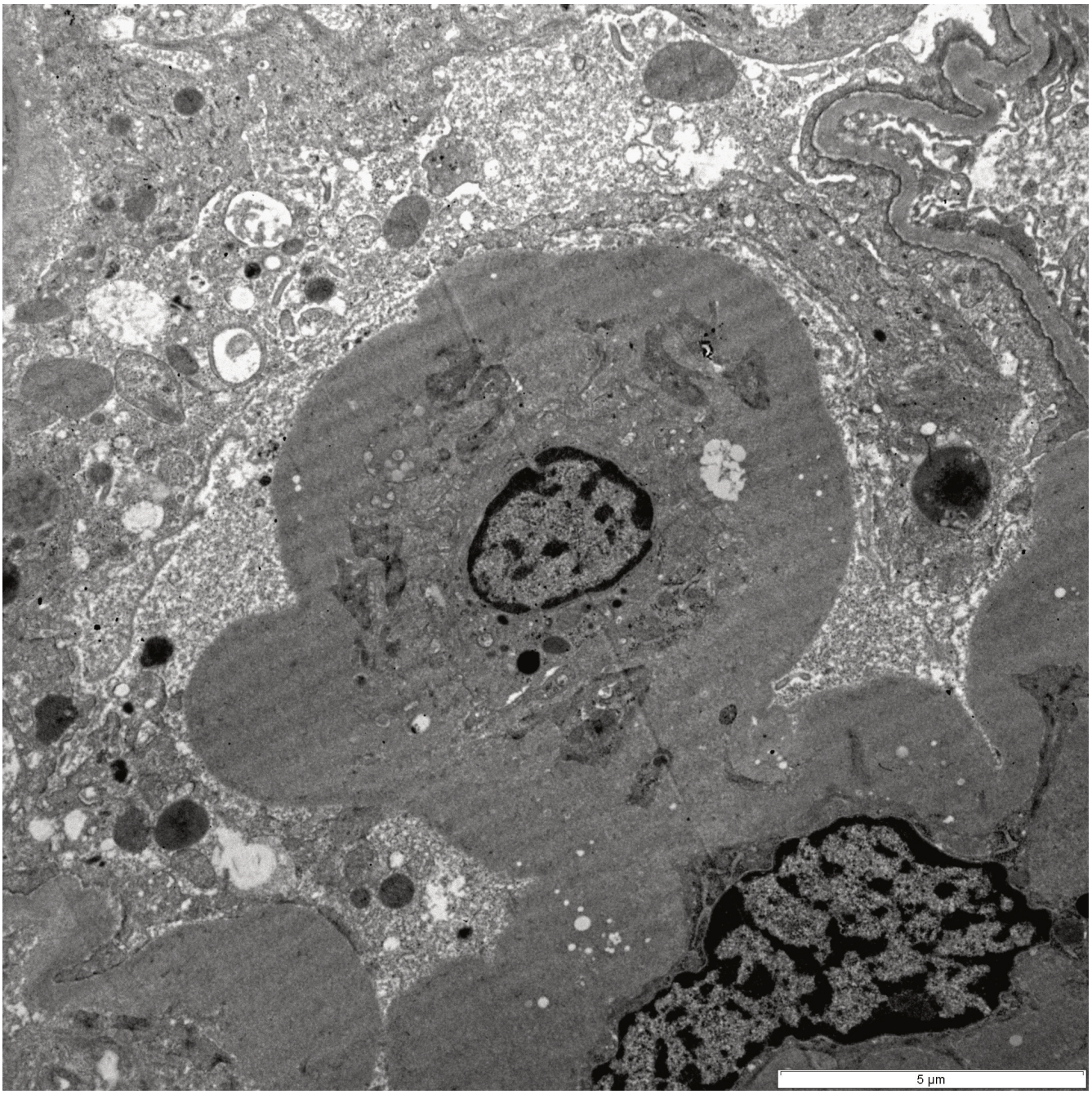

FIG.7D (TEM): The lumen of the capillary loop is effaced by extracellular matrix and the mesangium is expanded. The overlying podocytes have detached and only small cellular blebs are in Bowman's space.

An interactive or media element has been excluded from this version of the text. You can view it online here:
https://ohiostate.pressbooks.pub/vetrenalpathatlas/?p=342

FIG.7E (TEM): Colorized version of above TEM image. (Green: GBM, Blue: Mesangium).

An interactive or media element has been excluded from this version of the text. You can view it online here:
https://ohiostate.pressbooks.pub/vetrenalpathatlas/?p=342

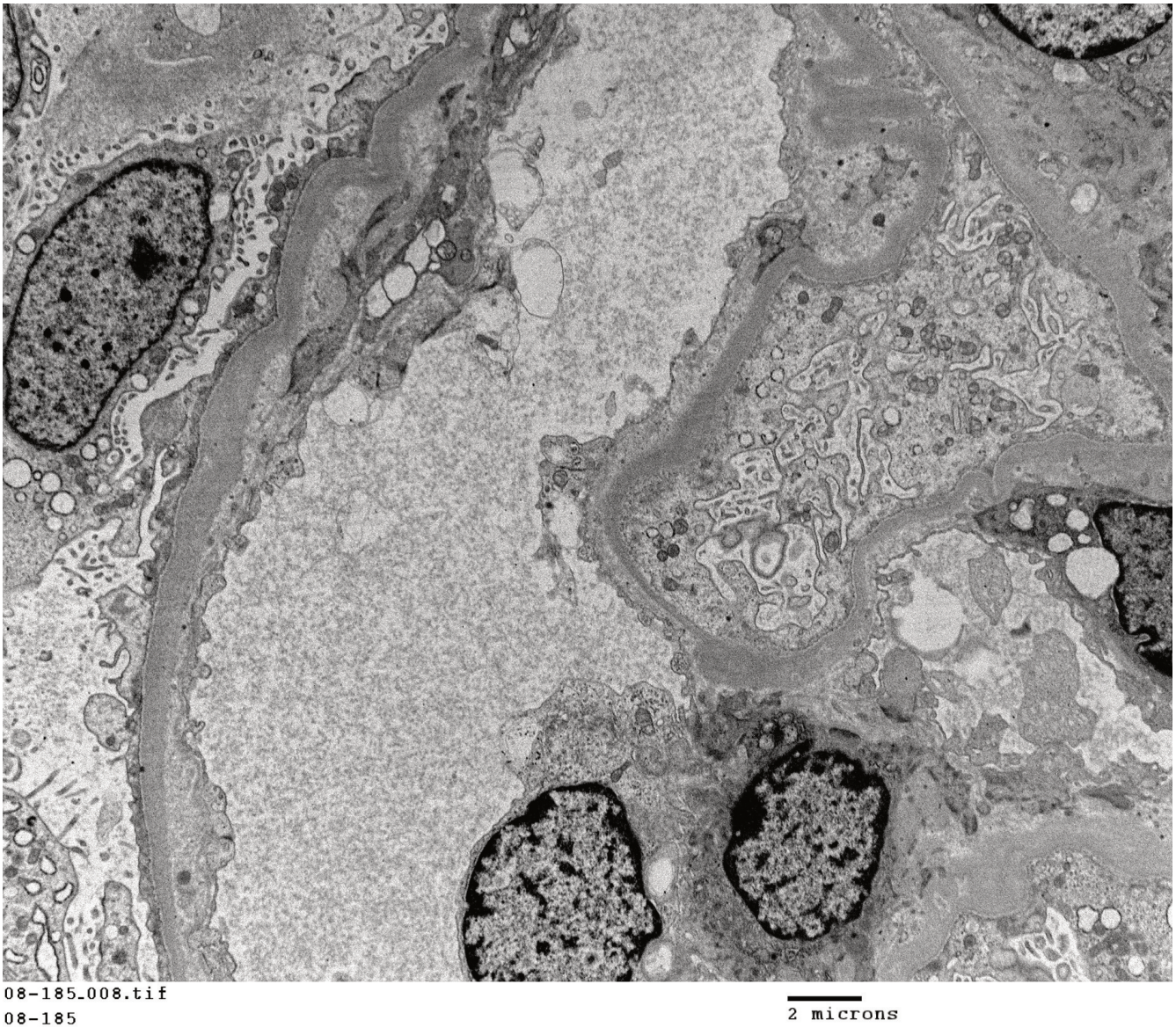

FIG.7F (TEM): Transmission electron microscopy demonstrating podocyte foot process effacement.

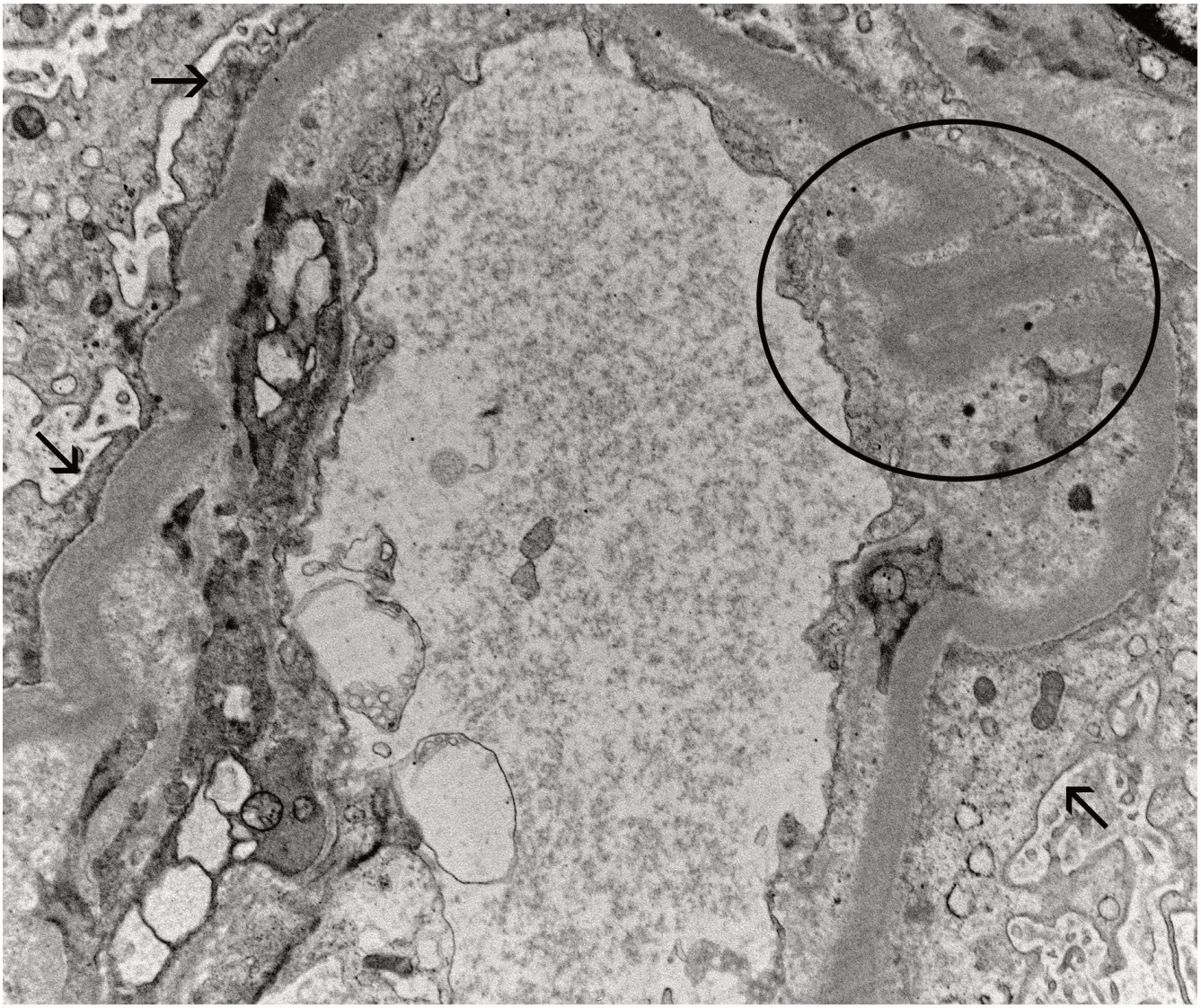

FIG.7G (TEM): Higher magnification of the same capillary loop demonstrating the foot process effacement (arrows) and wrinkling of the capillary wall (cricled).

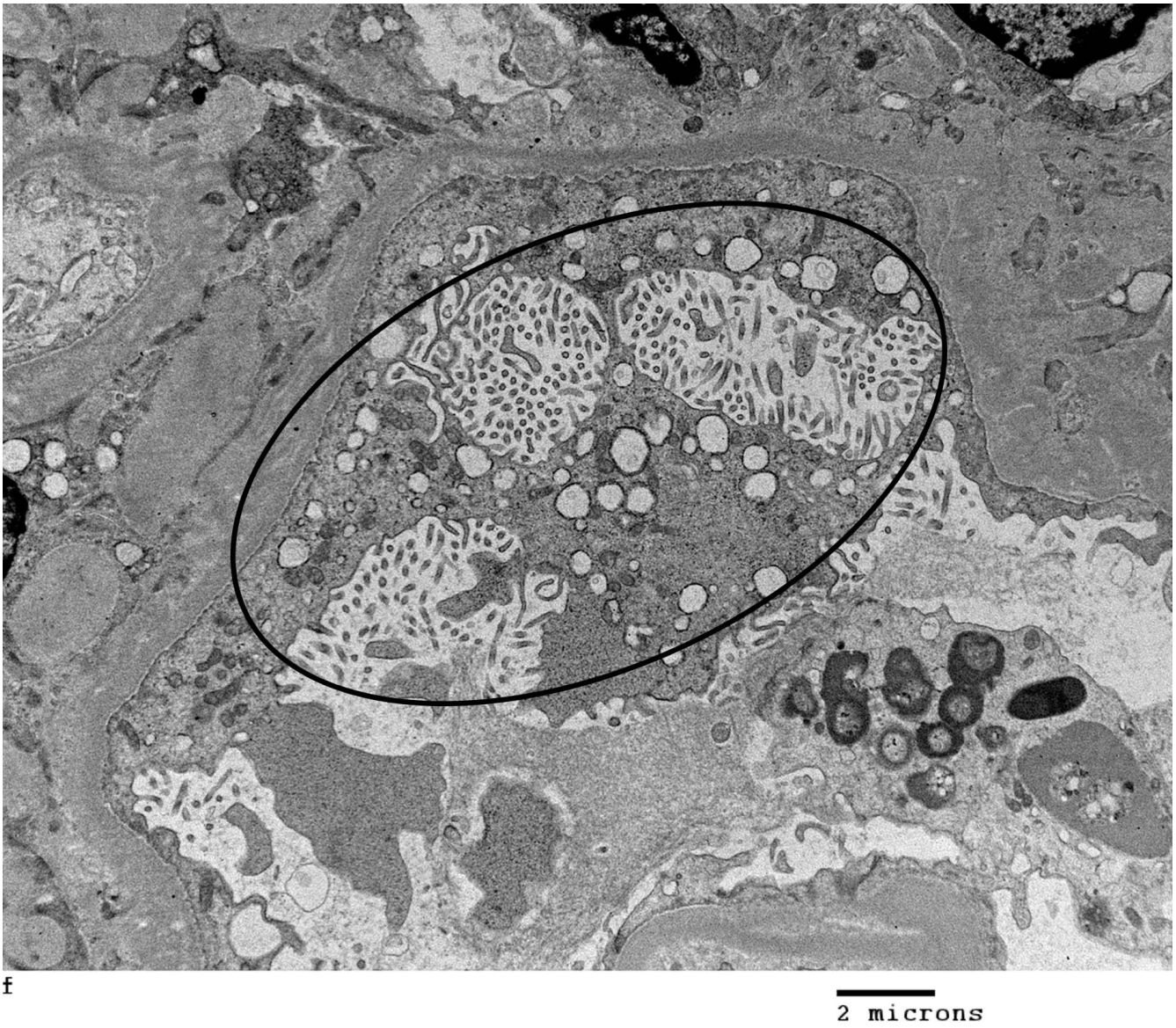

FIG.7H (TEM): Microvillus transformation of podocyte foot processes (circled).

An interactive or media element has been excluded from this version of the text. You can view it online here:
https://ohiostate.pressbooks.pub/vetrenalpathatlas/?p=342

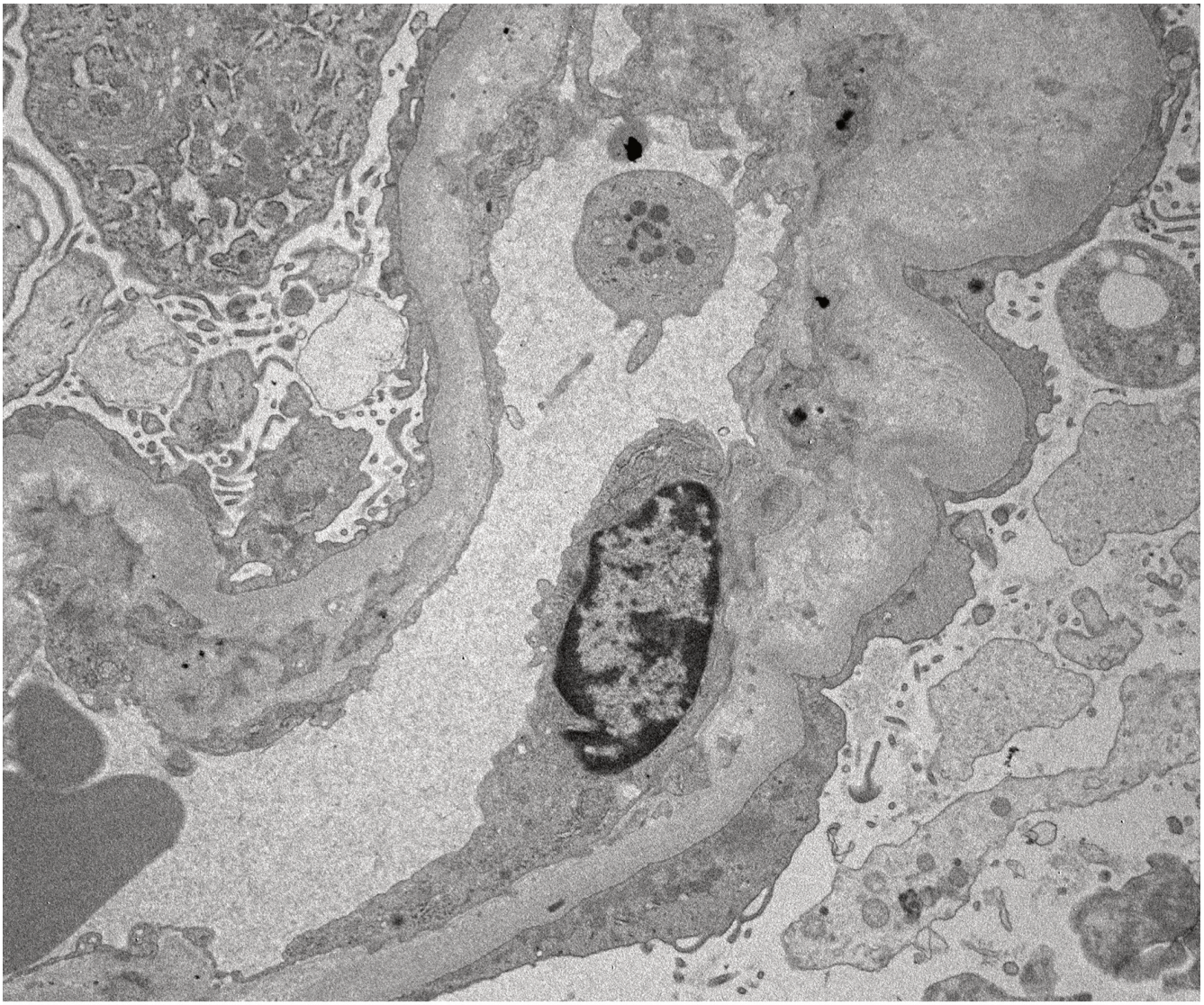

FIG.7I (TEM): The entire capillary loop is lined by effaced podocyte foot processes.

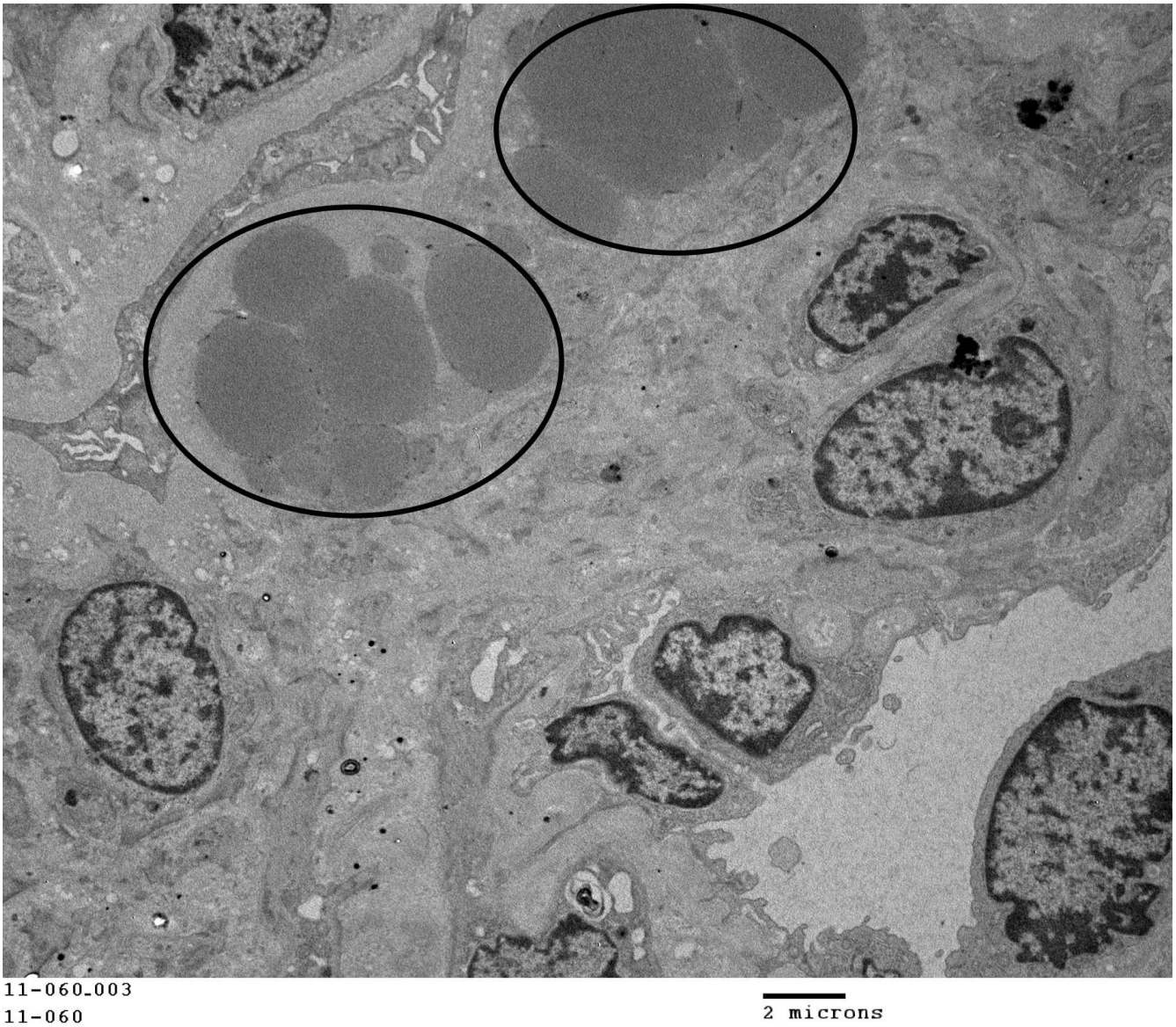

FIG.7J (TEM): Within this sclerotic segments, there are multiple osmophilic globules (circled) which are consistent with lipid.

An interactive or media element has been excluded from this version of the text. You can view it online here:
https://ohiostate.pressbooks.pub/vetrenalpathatlas/?p=342

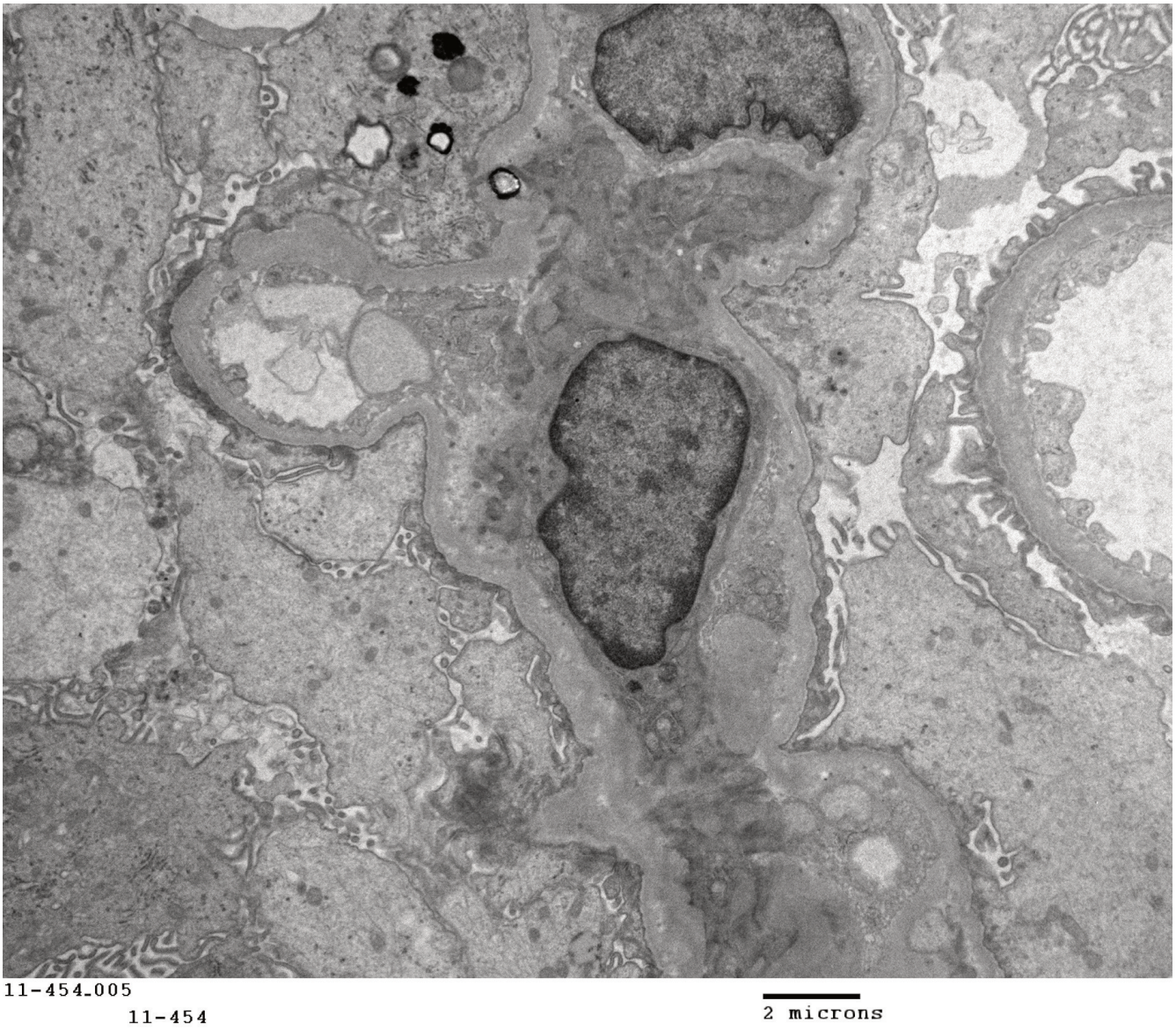

FIG.7K (TEM): All podocytes are severely swollen with effaced foot processes and microvillus transformation of the cytoplasm.

An interactive or media element has been excluded from this version of the text. You can view it online here:
https://ohiostate.pressbooks.pub/vetrenalpathatlas/?p=342

FIG.7L (TEM): Colorized version of above TEM image. (Green: GBM; Pink: Podocyte; Blue: Mesangium).

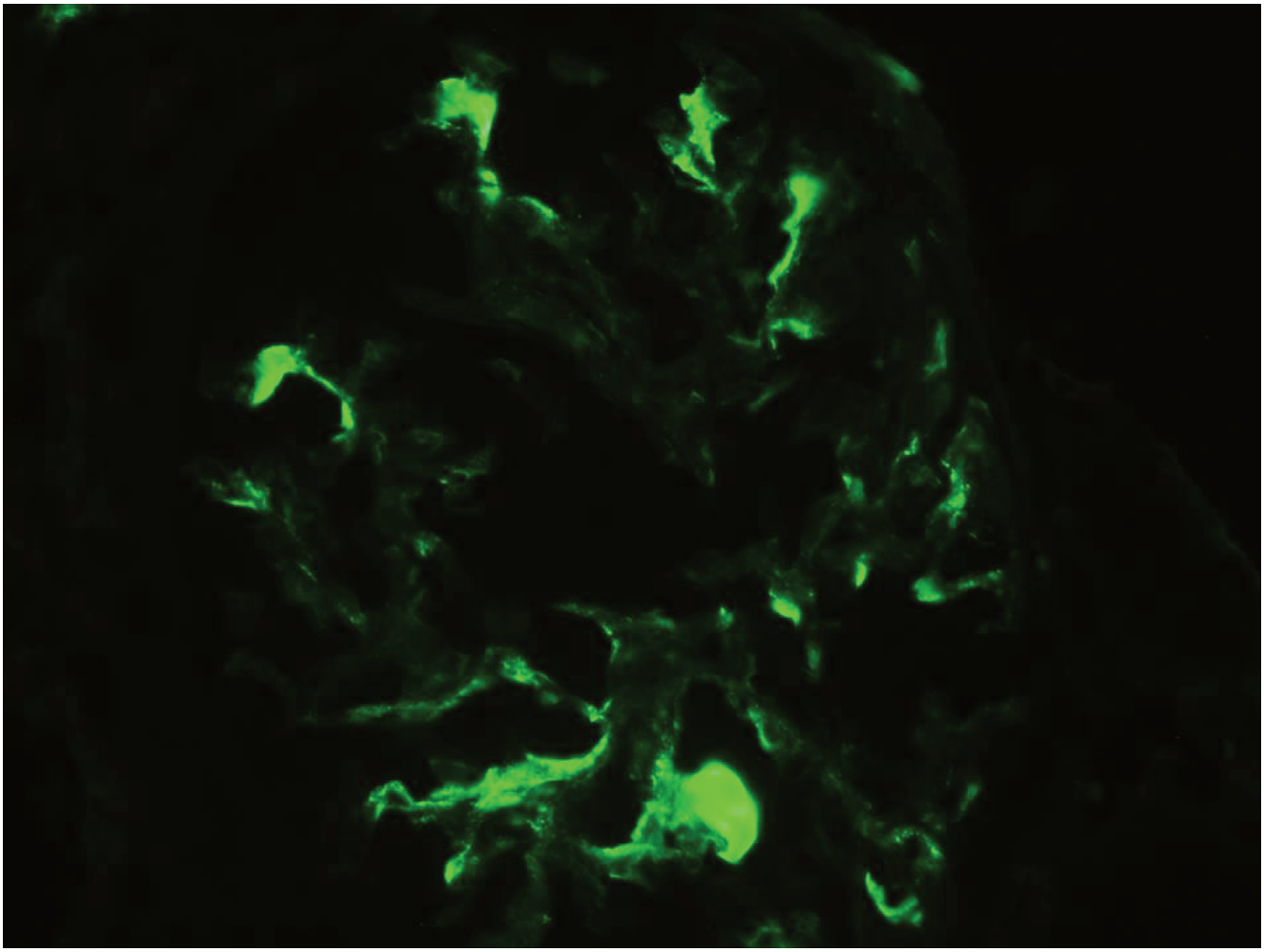

FIG.7M (IF for IgM): There is moderate segmental splotchy labeling in sclerotic segments of the glomerulus.

Differential Diagnoses for Focal Segmental Glomerulosclerosis

Disease	Defining histologic features	Defining ultrastructural features
Segmental sclerosis secondary to underlying immune complex disease	The non-sclerotic portions of the glomeruli might be abnormal (hypercellular or have glomerular basement membrane remodeling)	Electron dense deposits (immune deposits) are identified
Segmental sclerosis secondary to underlying GBM abnormalities	The non-sclerotic portions of the glomeruli will have glomerular basement membrane remodeling	The glomerular basement membrane is abnormal (e.g. thickened, multi-laminated, wrinkled) and electron dense deposits are not identified.

Key Diagnostic Features of Focal Segmental Glomerulosclerosis

- Focal and segmental pattern of sclerosis with light microscopy.
- Adequate numbers of glomeruli in a kidney biopsy is crucial to make a diagnosis of FSGS since focal lesions may be missed with small samples. Multiple levels (step sections) may be needed to identify focal segmental lesions in the submitted kidney cores.
- Multifocal or extensive effacement of podocytes foot processes by transmission electron microscopy.
- With immunofluorescence, no granular staining with antibodies against IgG and C3 although some non–specific entrapment of IgM and C3 in the mesangium may occur.

Amyloidosis

- Amyloid is the general term used for a wide variety of extracellular insoluble protein accumulations made of fibrils that have a β-pleated structure.
    - In the kidney, amyloid is predominantly located in the glomeruli with fewer cases having interstitial or vascular amyloidosis.
- Histologic appearance – Nodular expansion of the mesangium and capillary walls by congophilic material (from Congo red [CR] staining) that is peach to orange. This material exhibits apple-green birefringence when viewed with polarized light.
    - Amyloid appears pale pink and waxy when stained with PAS, mottled blue to orange with MT and does not take up silver with the JMS method.
    - Importantly the HE stain can be unreliable for the diagnosis of amyloidosis because it may exhibit similar characteristics to the eosinophilic material seen in glomerulosclerosis.
    - Minimal amyloidosis might only be detectable by electron microscopy.
    - Non-amyloidotic, non-congophilic fibrillary deposits, with similar tinctorial qualities on PAS, MT, HE, and JMS stains, have been identified in canine glomeruli; therefore, a CR should always be performed for a definitive diagnosis.

Clinical Features of Amyloidosis

- Initial sign is moderate to marked proteinuria (typically UPC > 2), with or without hypoalbuminemia.
- Azotemia develops with nephron loss due to progression of disease.
- In cases where amyloid deposition is consistently located in the medullary interstitium, often with a diffuse and severe distribution (e.g., Chinese Shar Peis), early and more severe development of azotemia with milder proteinuria and hypoalbuminemia would be expected.
- Dogs with glomerular amyloidosis might present with dyspnea due to pulmonary artery thrombosis.
- Markedly proteinuric dogs <2 years old are *unlikely* to have amyloidosis (Segev et al 2012).
- Other common clinical findings include non-regenerative anemia, leukocytosis, low anti-thrombin activity (and associated thromboembolism), and hypertension. In dogs with extra-renal involvement, other clinical findings may be present, particularly hepatobiliary abnormalities with liver involvement.

- Dogs with amyloidosis are less likely to retain robust urine concentrating ability than other categories of glomerular disease.
- Breeds at risk include the Chinese Shar Peis, English Bulldogs, Beagles, Walker Hounds, and possibly Collies (Olsson et al 2013 and Vaden 2011)

MINIMAL AMYLOIDOSIS: Glomeruli might appear histologically normal as very small deposits can be overlooked. Ultrastructural evaluation is required for the diagnosis in these cases.

An interactive or media element has been excluded from this version of the text. You can view it online here:
https://ohiostate.pressbooks.pub/vetrenalpathatlas/?p=5

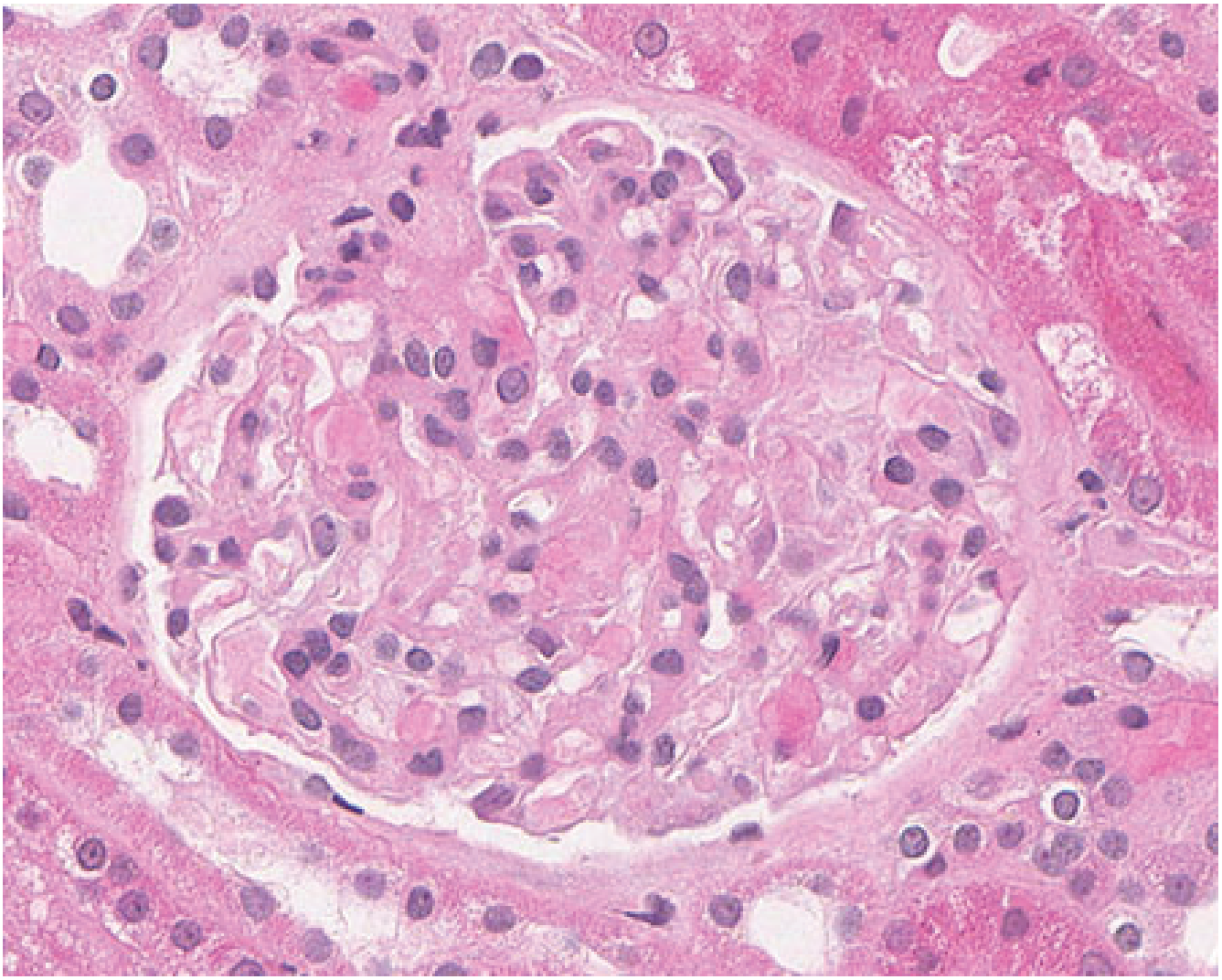

FIG.1A (HE): The glomerulus has a relatively normal histologic appearance.

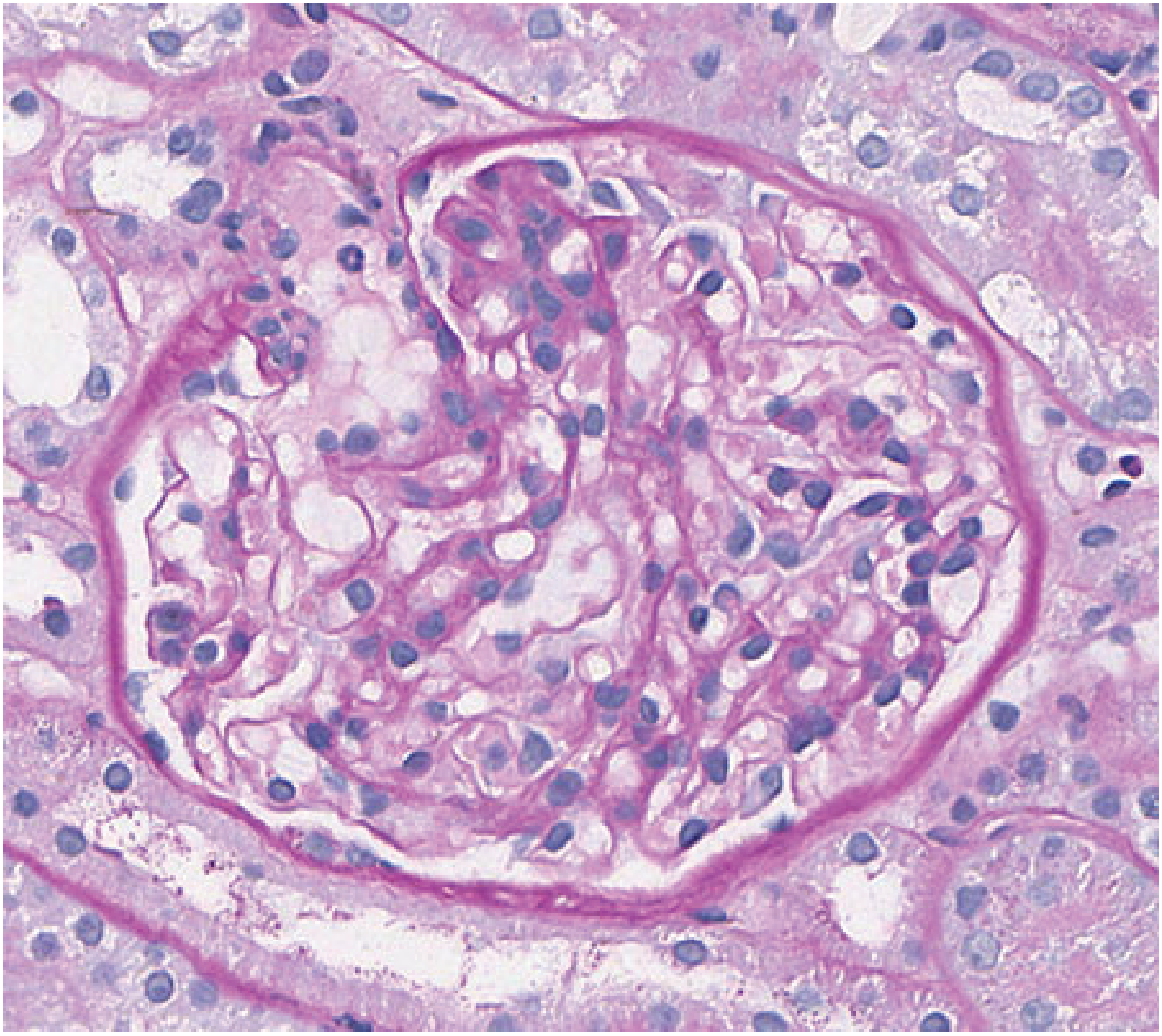

FIG.1B (PAS): The glomerulus has a relatively normal histologic appearance.

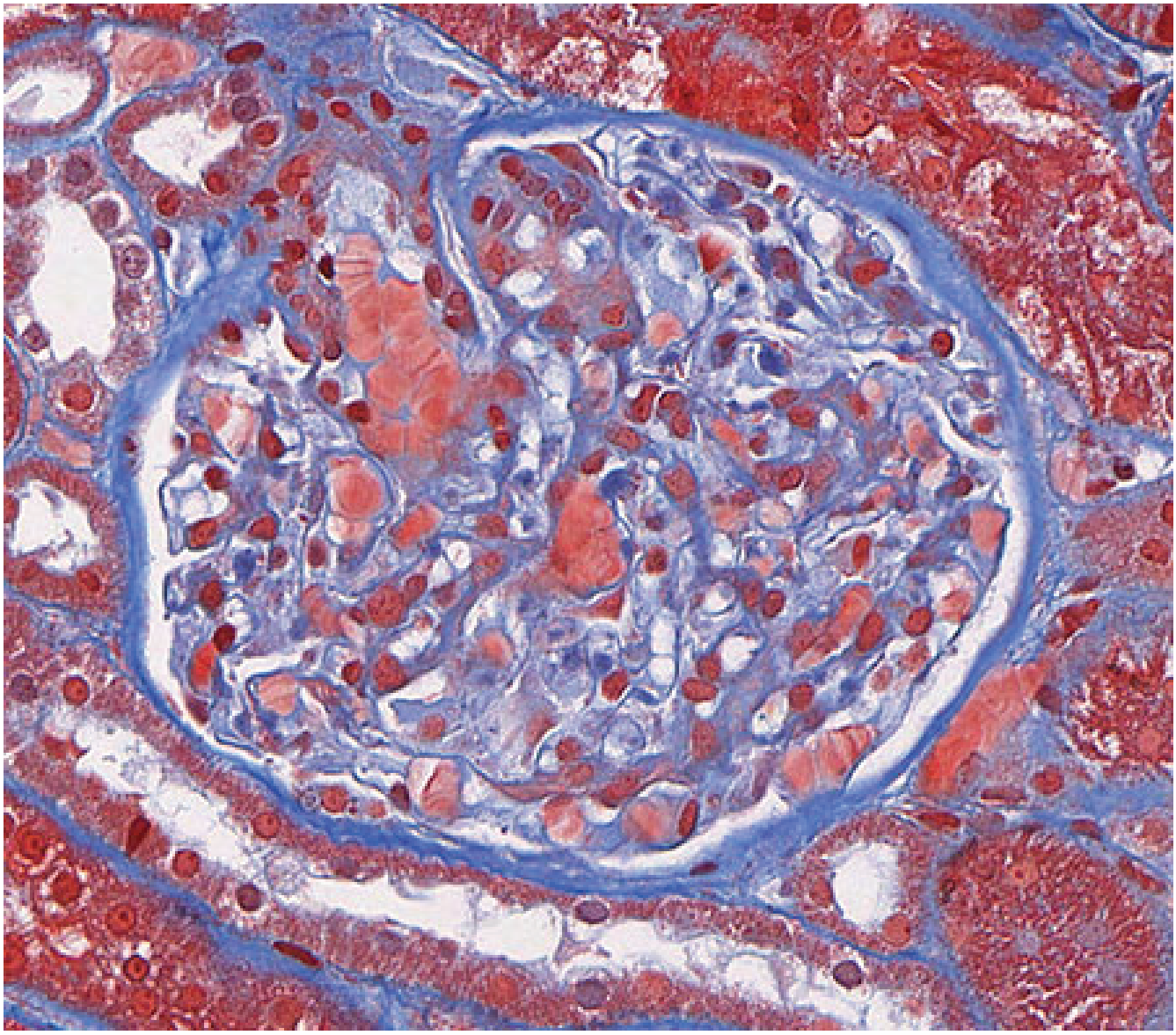

FIG.1C (MT): The glomerulus has a relatively normal histologic appearance.

FIG.1D (JMS): The glomerulus has a relatively normal histologic appearance.

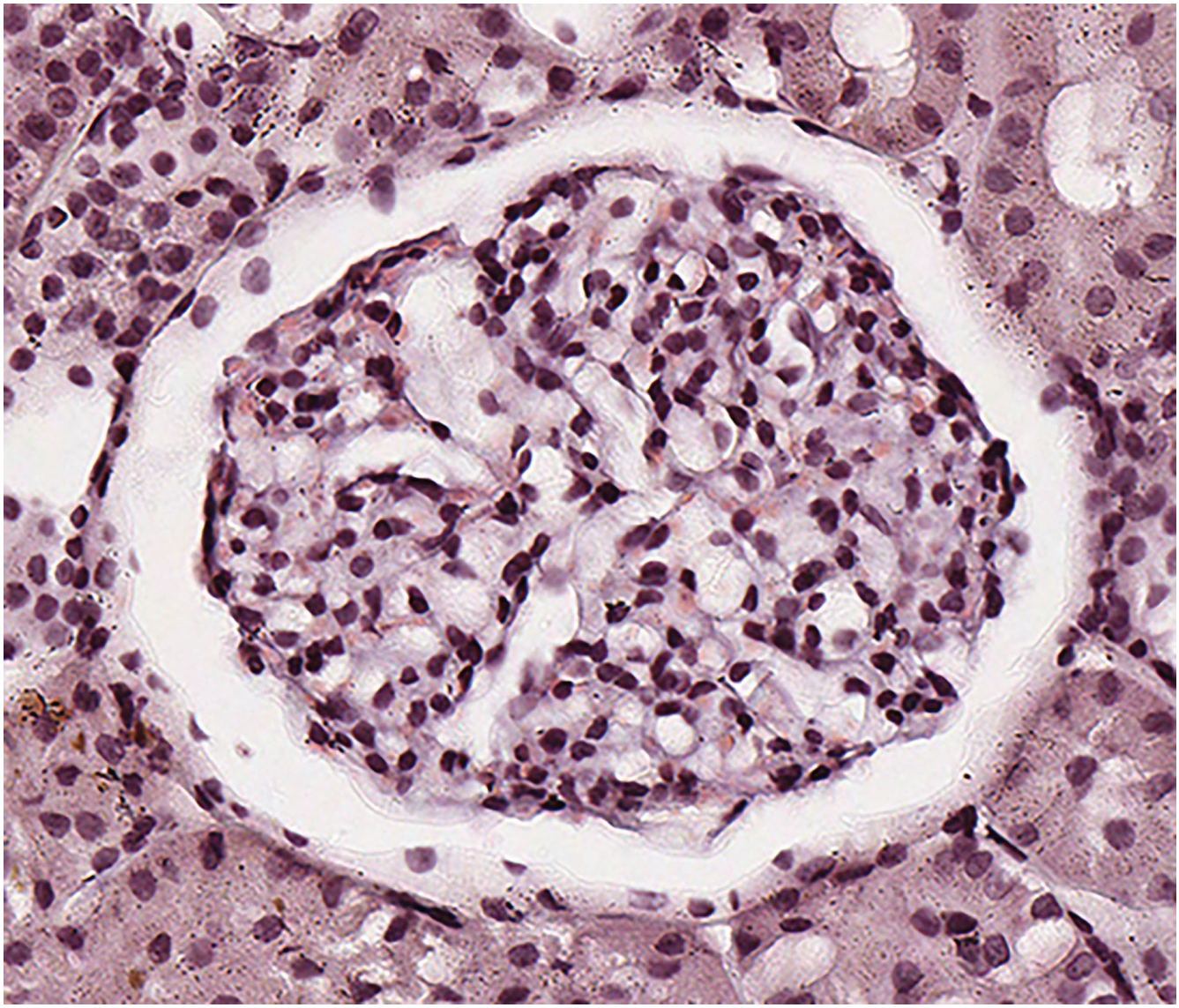

FIG.1E (CR): Glomerulus has a histologically normal appearance; amyloid is not evident. Please note because the sample was cut at 8µm thickness, the glomerulus appears hypercellular.

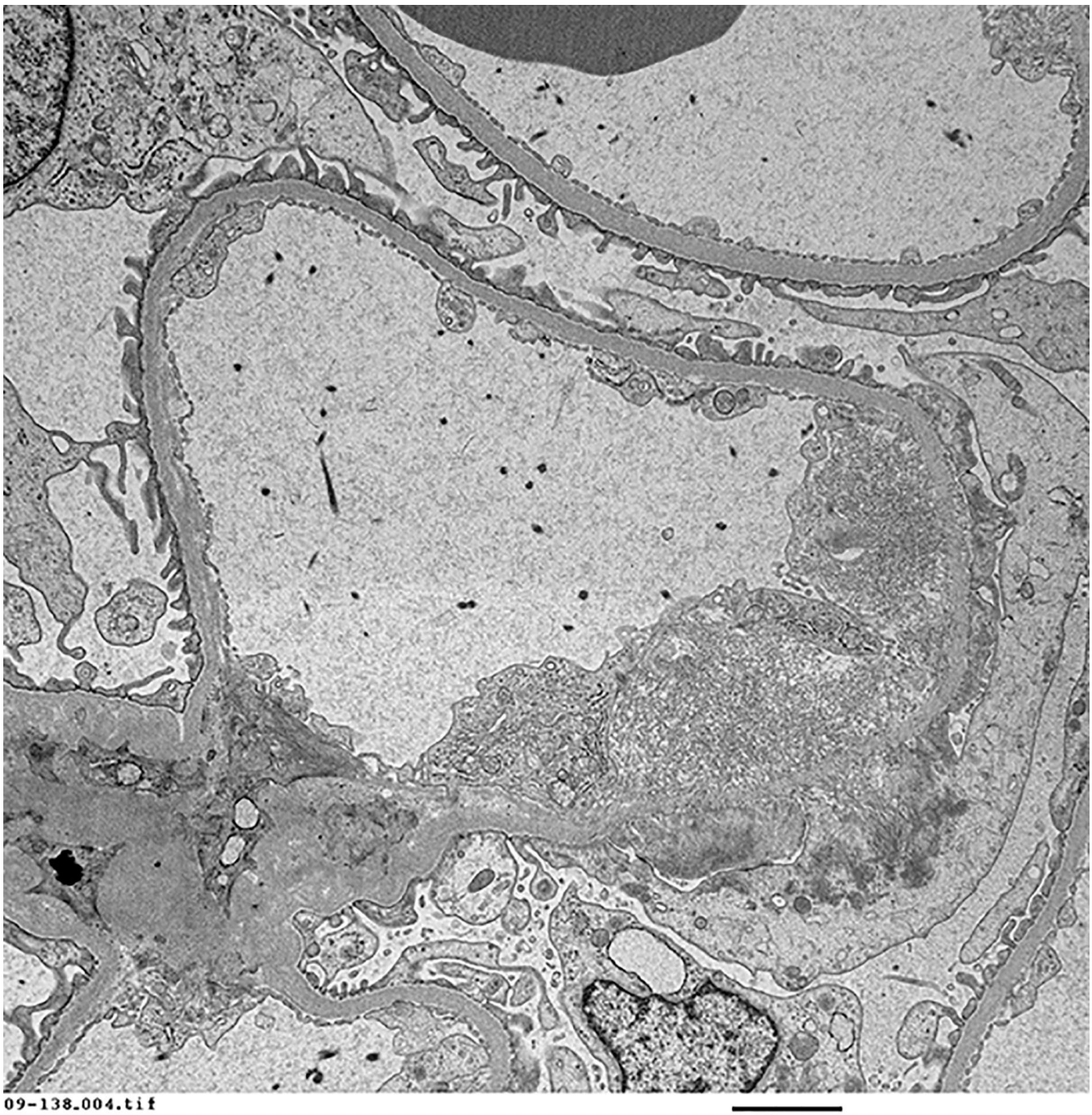

FIG.1F (TEM): There is segmental expansion of the capillary wall beneath the endothelium, with extension across the GBM, by non-branching, non-periodic, haphazardly arranged 9 to 11 nm diameter fibrils. These fibrils are only identified in small segments of the glomeruli. Podocyte foot processes over areas of fibril deposition are effaced.

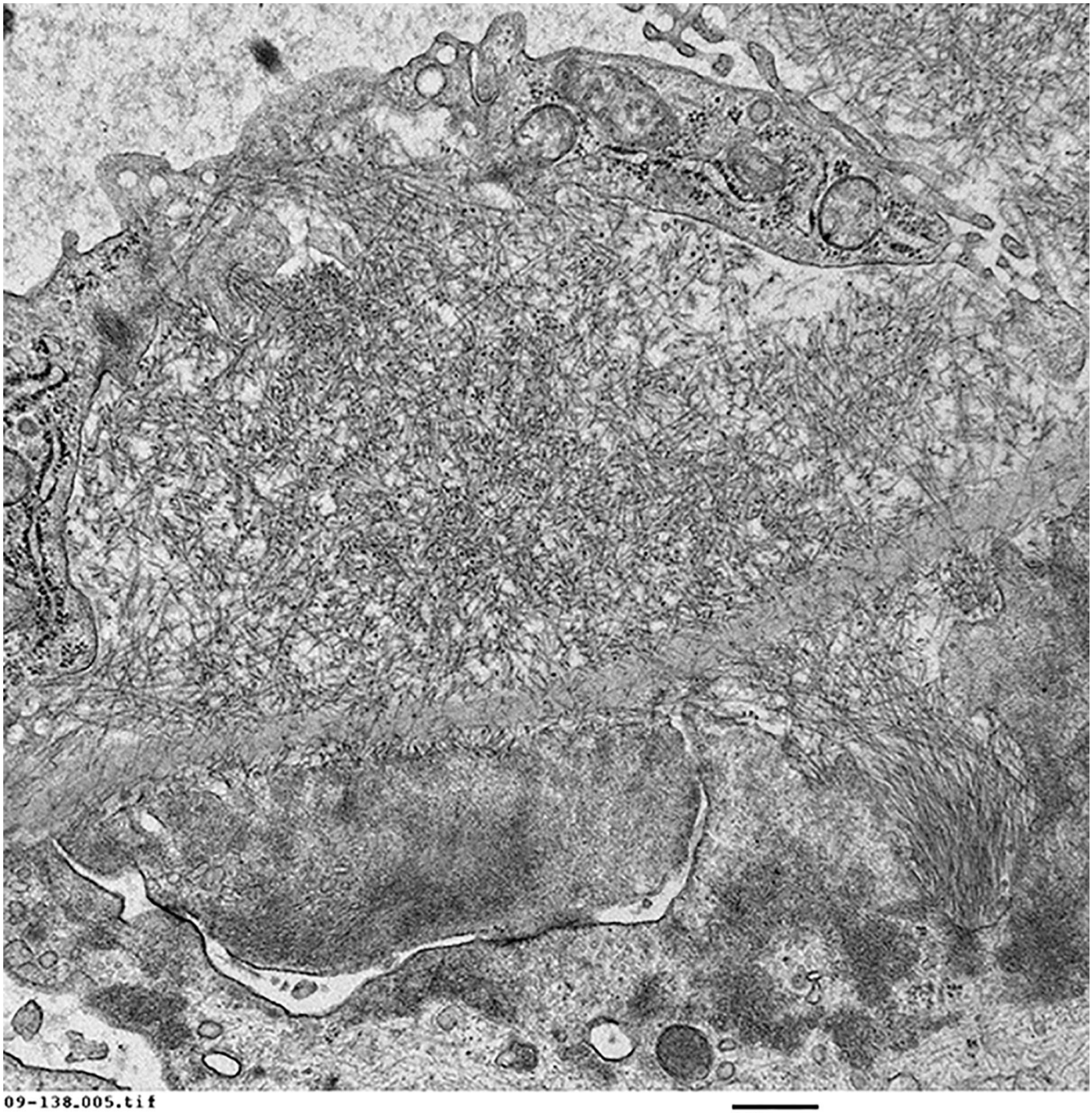

FIG.1G (TEM): Higher magnification of the amyloid fibrils, which cross the GBM and make a small partially organized projection (so-called spicule) towards the urinary space.

An interactive or media element has been excluded from this version of the text. You can view it online here:
https://ohiostate.pressbooks.pub/vetrenalpathatlas/?p=5

FIG.1H (TEM): Colorized version of above TEM image. (Yellow: endothelial cell, Blue: amyloid fibrils, Green: GBM, Pink: podocyte).

MILD AMYLOIDOSIS: Glomeruli have pale scattered deposits expanding most the mesangium and occasionally the capillary loops with rare occlusion of capillary lumina.

An interactive or media element has been excluded from this version of the text. You can view it online here:
https://ohiostate.pressbooks.pub/vetrenalpathatlas/?p=5

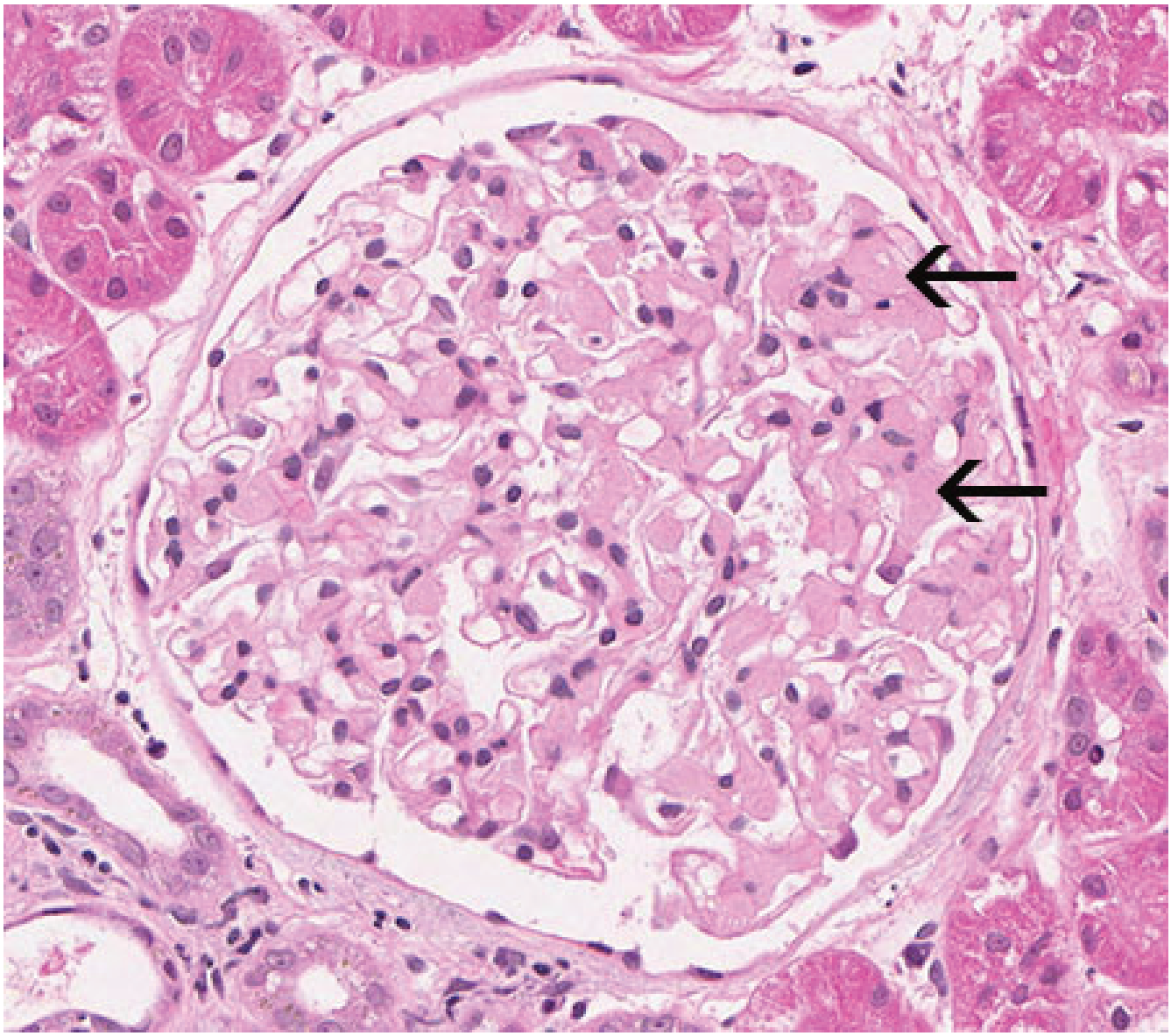

FIG.2A (HE): The mesangium is mildly and multifocally expanded by eosinophilic amorphous

material (arrows). The eosinophilia of amyloid is similar to that of glomerulosclerosis; thus HE stain can be unreliable for the diagnosis in mild cases.

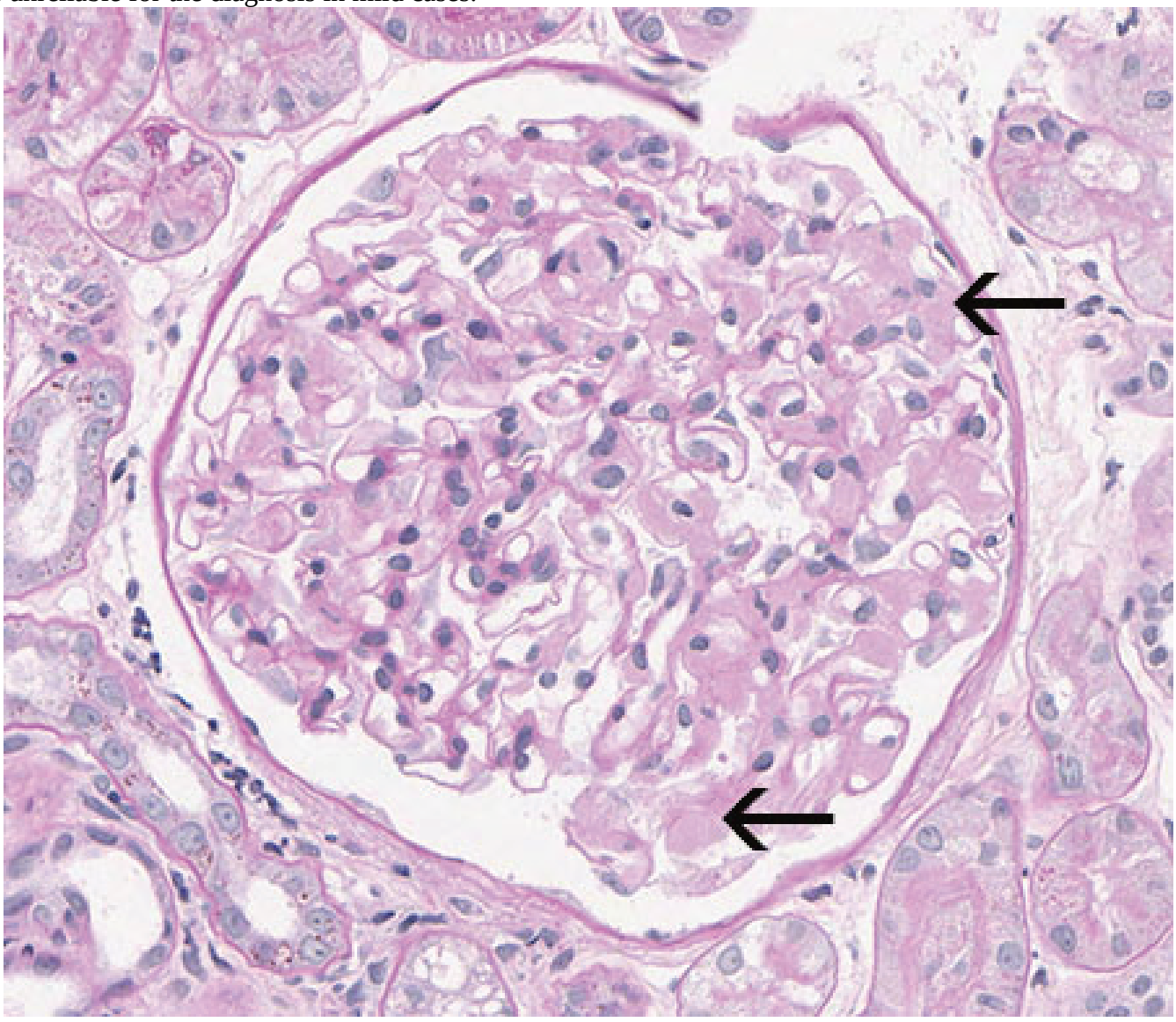

FIG.2B (PAS): Amyloid stains pale pink and waxy in the mesangium and capillary loops (arrows). There is no hypercellularity of the glomerular tuft.

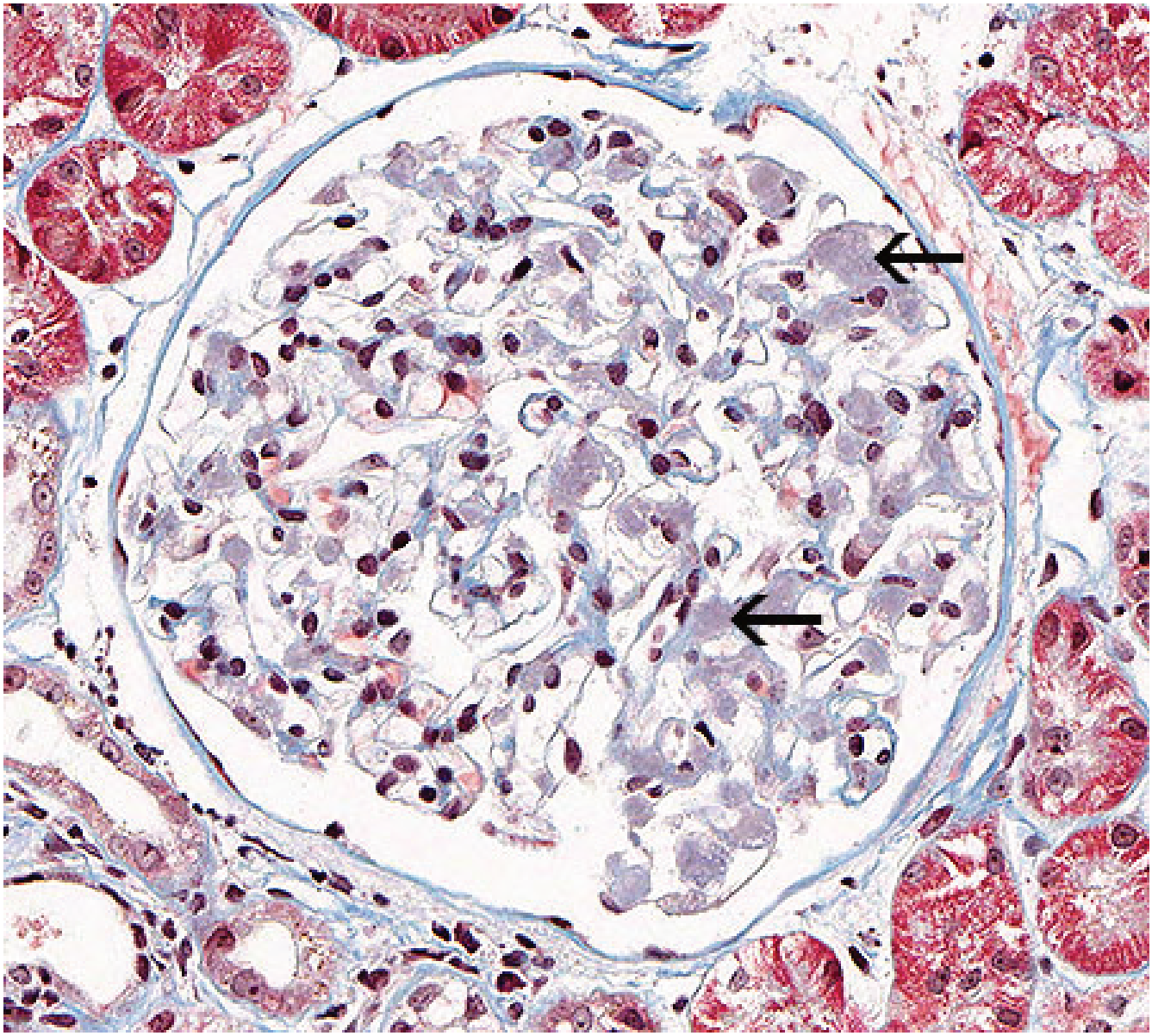

FIG.2C (MT): Amyloid deposits stain mottled blue to orange (arrows).

FIG.2D (JMS): Amyloid does not take up silver with the JMS method, and in this case it is a very small amount (circled).

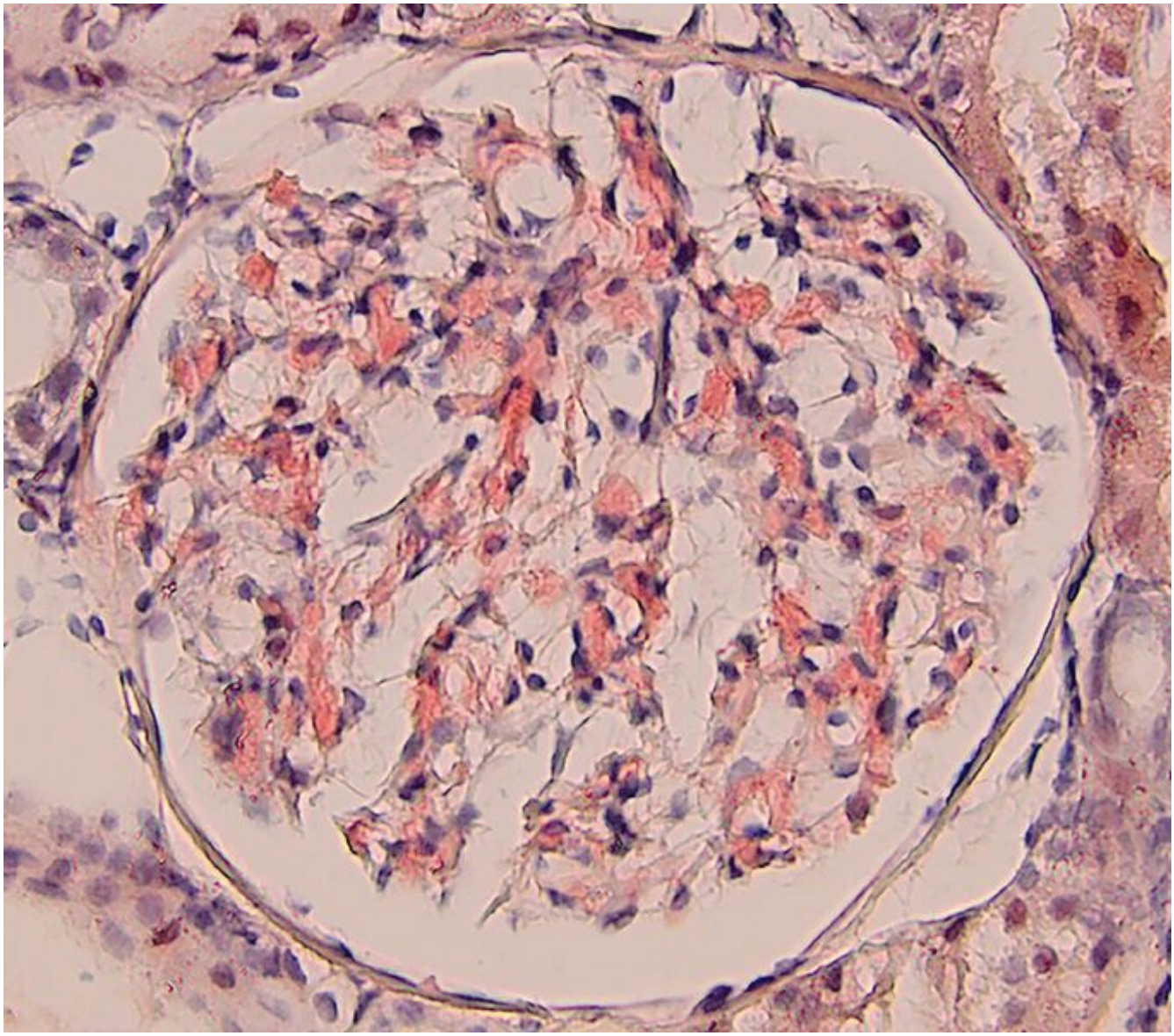

FIG.2E (CR): Amyloid is congophilic and it stains orange to peach. CR positive staining is essential to confirm the diagnosis.

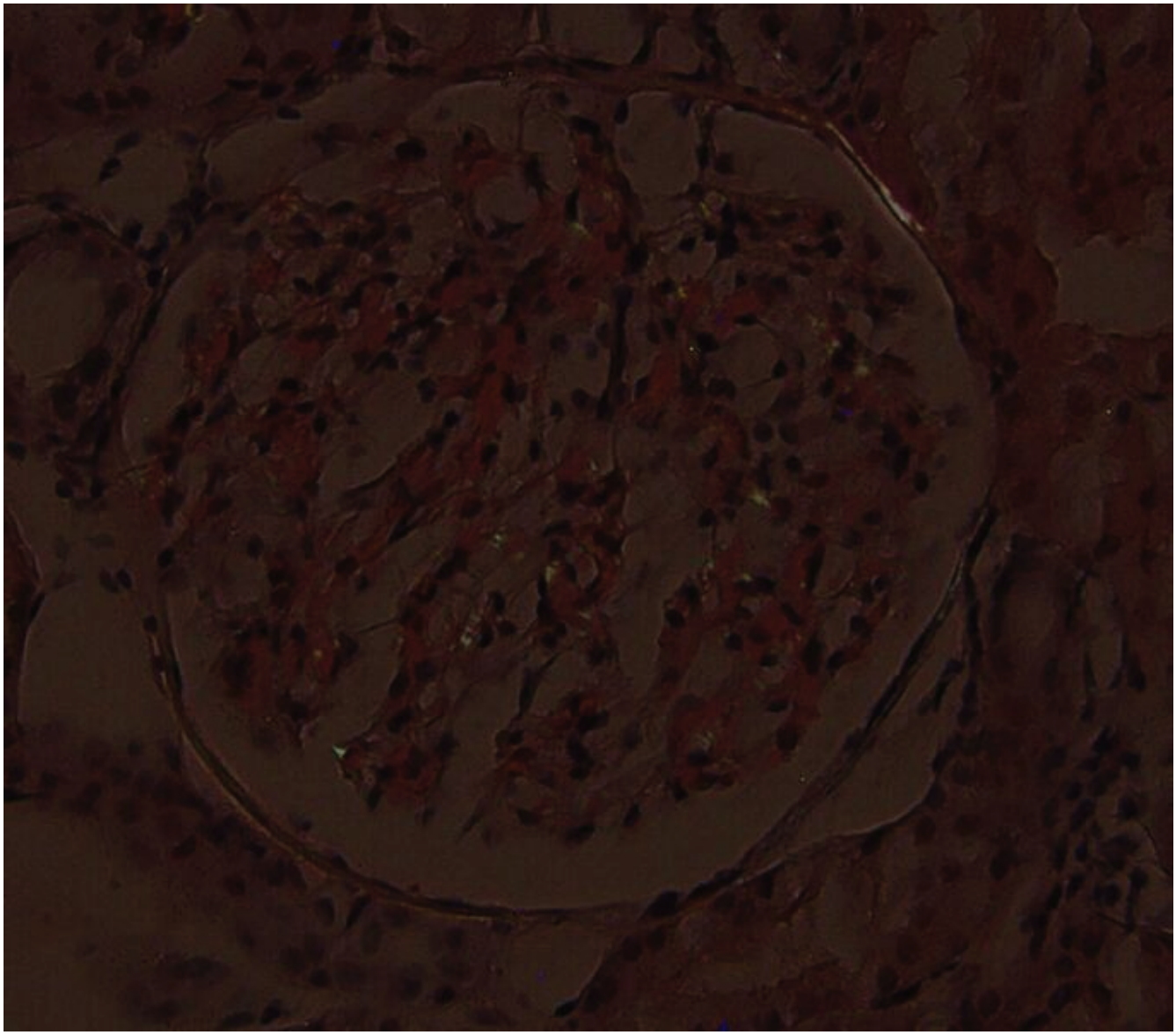

FIG.2F (CR viewed with polarized light): There are small foci of apple green birefringence. Of note, different areas will demonstrate birefringence at various planes of focus on the Z axis.

MODERATE AMYLOIDOSIS: There is diffuse global glomerular deposition of amyloid that widely expands the mesangium and capillary walls with compression and/or effacement of capillary lumina.

An interactive or media element has been excluded from this version of the text. You can view it online here:
https://ohiostate.pressbooks.pub/vetrenalpathatlas/?p=5

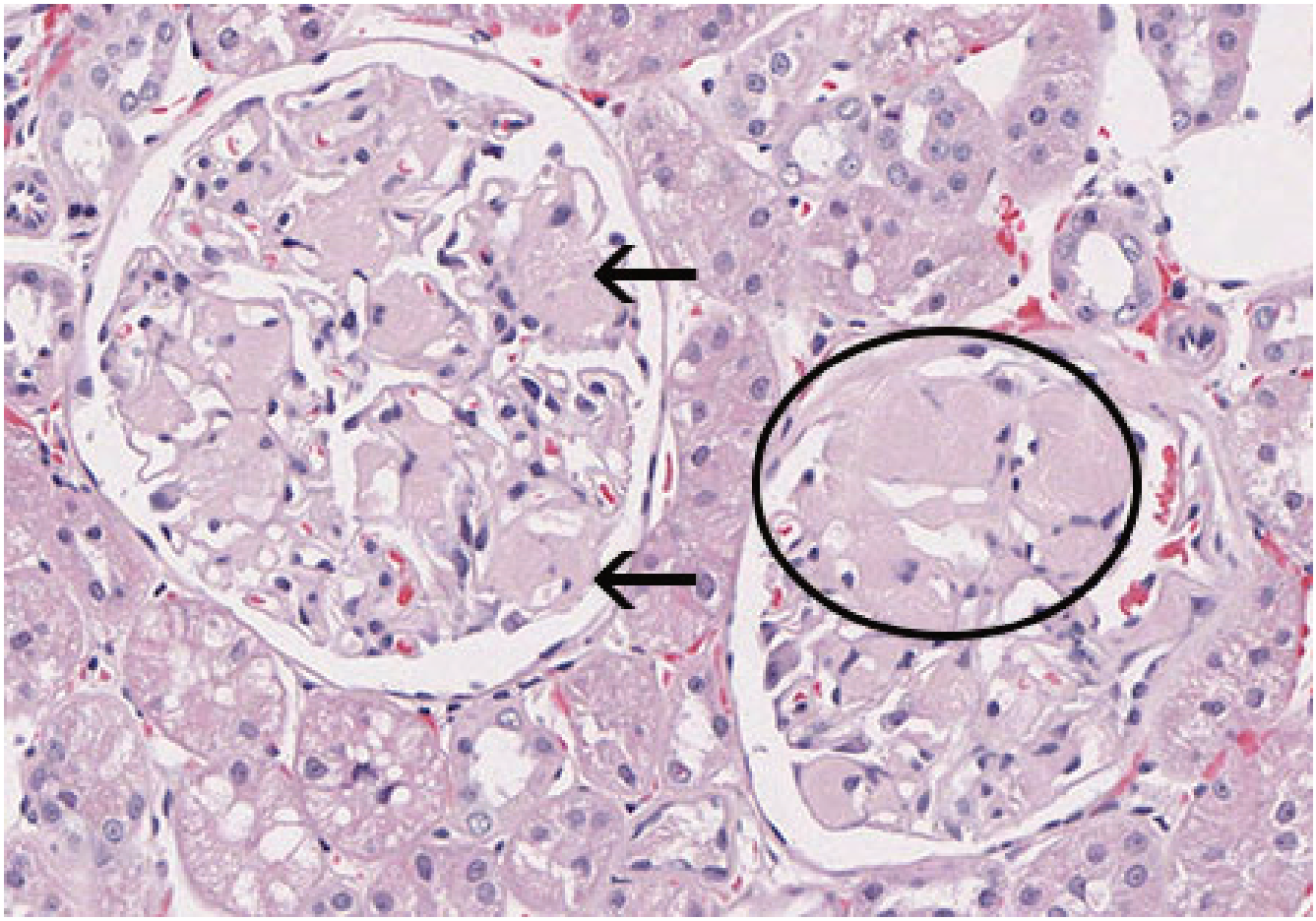

FIG.3A (HE): Mesangial zones are expanded by eosinophilic amorphous extracellular material (arrows) in one glomerulus. The other glomerulus has effacement of peripheral capillary loops by the amyloid (circled) as well as a synechia.

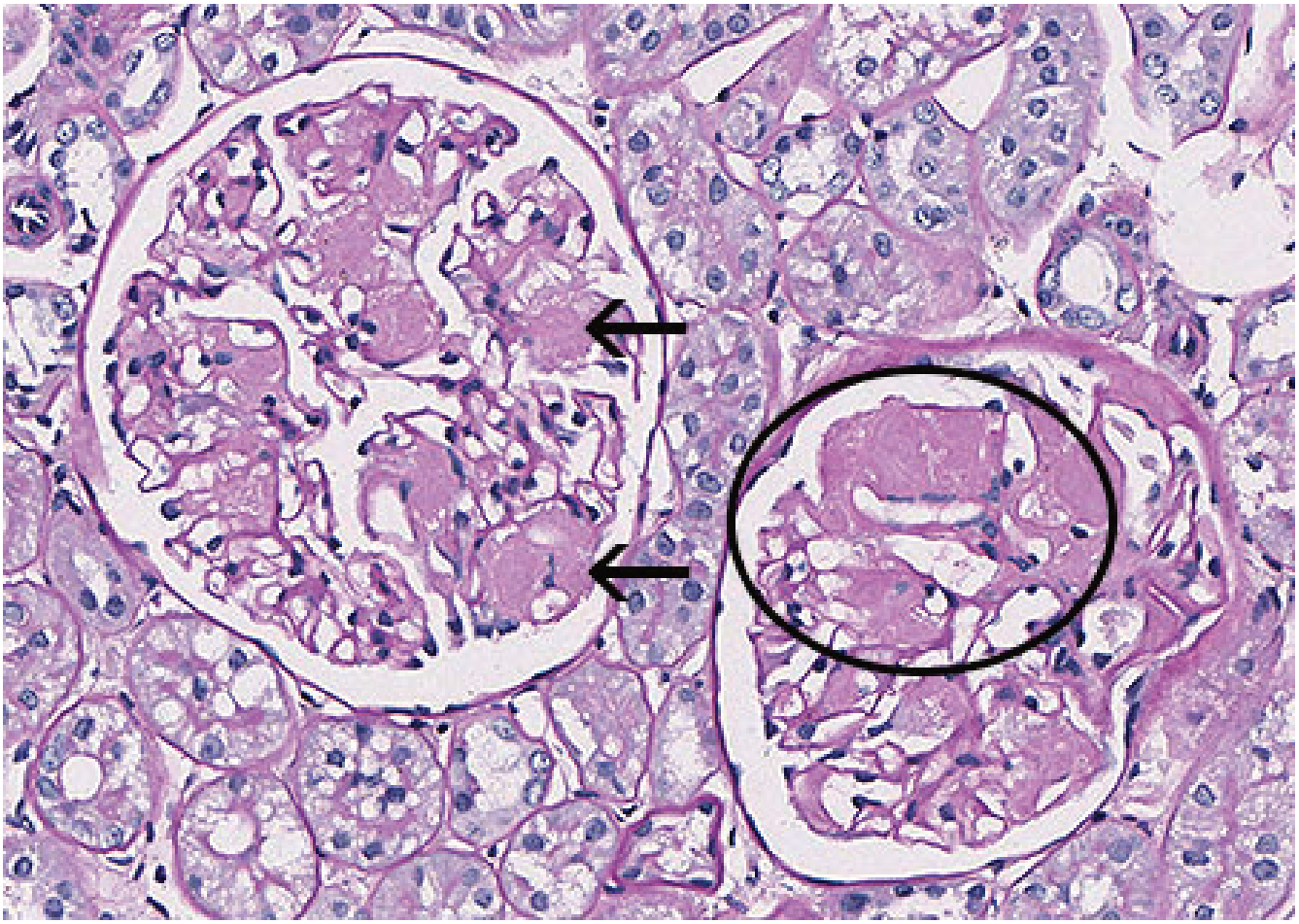

FIG.3B (PAS): Amyloid is pink and waxy (arrows). In the other glomerulus, there is effacement of peripheral capillary loops by the amyloid (circled).

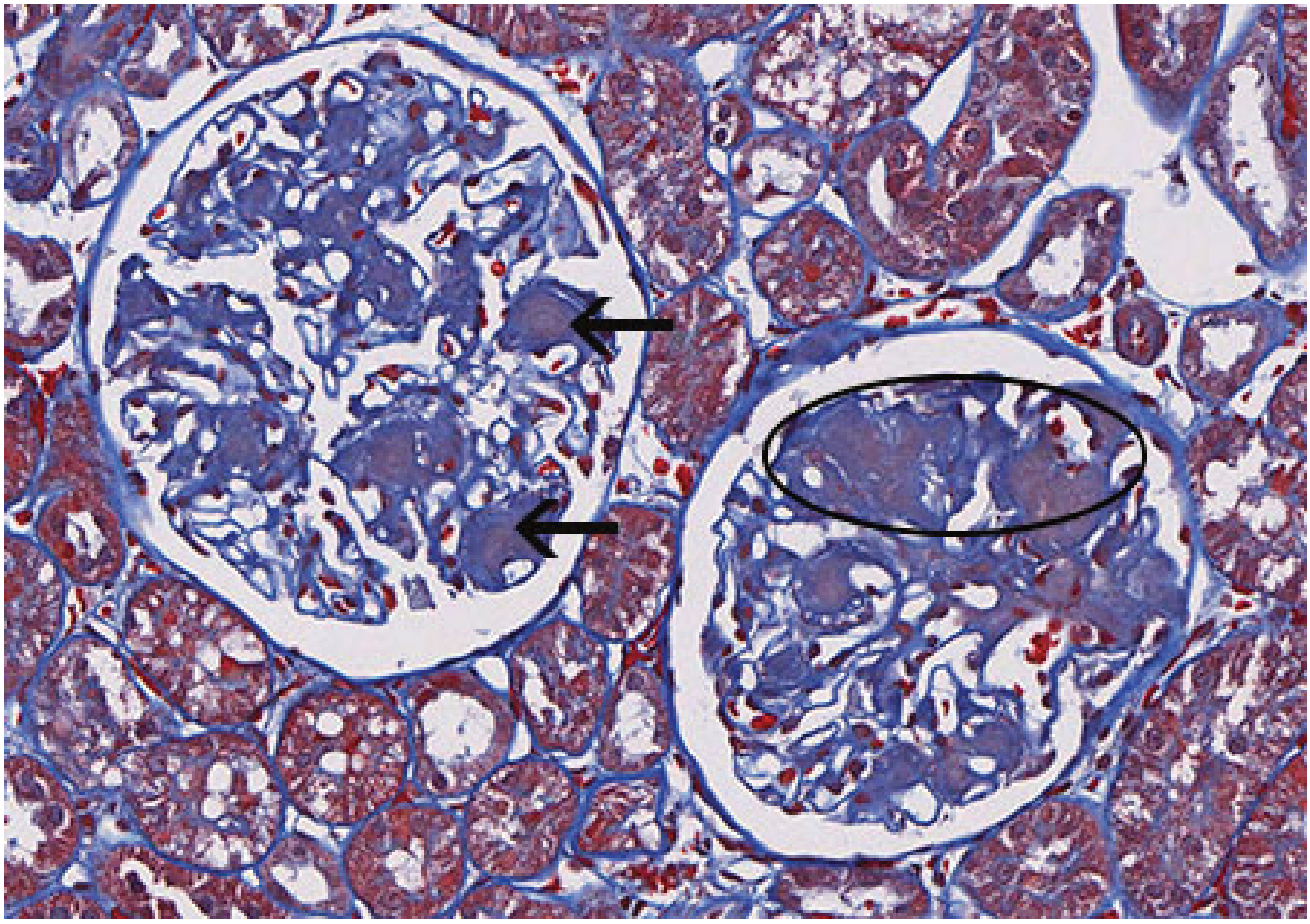

FIG. 3C (MT): Amyloid stains mottled peach to blue (arrows). In the other glomerulus, there is effacement of peripheral capillary loops by amyloid (circled).

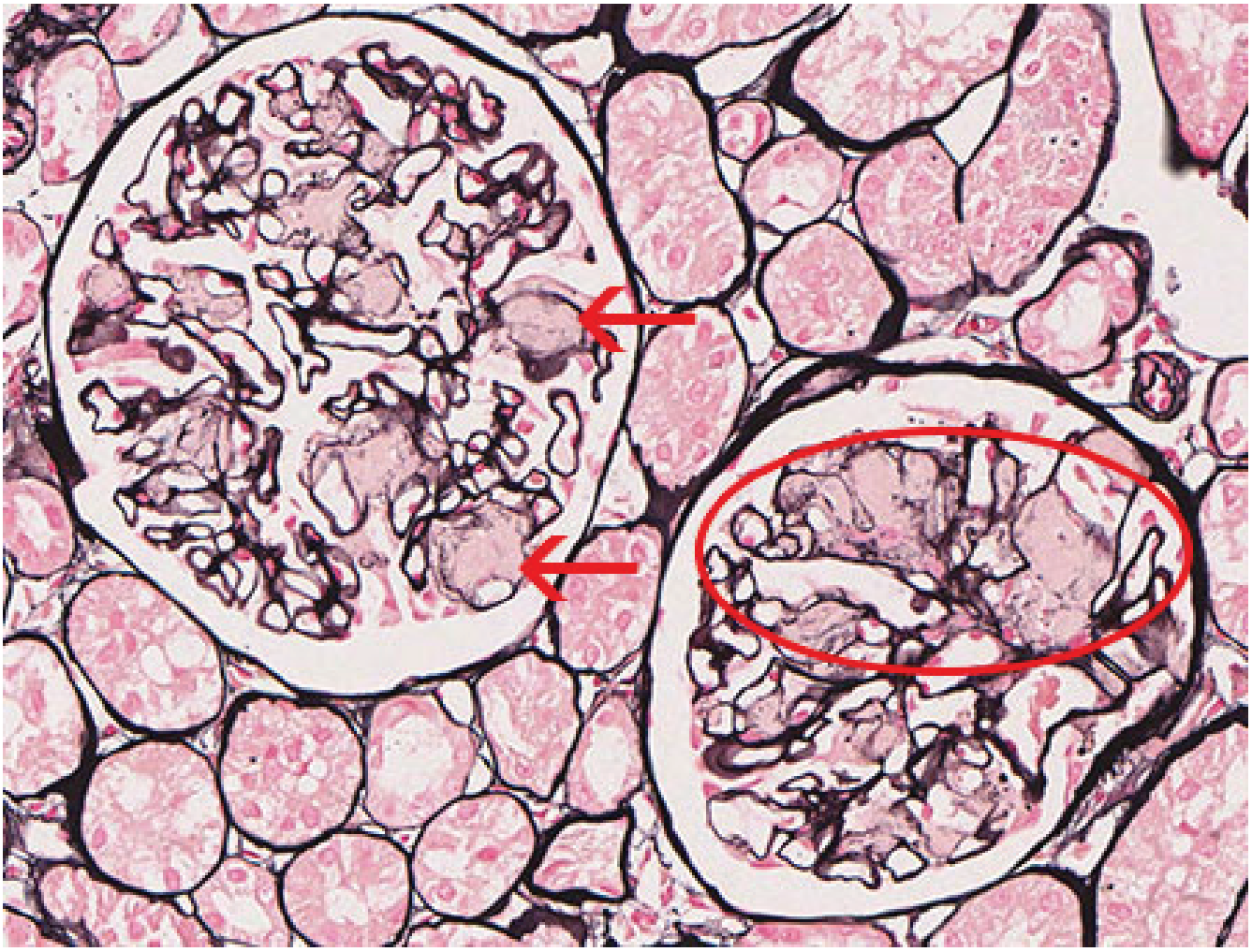

FIG.3D (JMS): Amyloid does not take up silver with the JMS method (arrows). In the other glomerulus, there is effacement of peripheral capillary loops by the amyloid (circled).

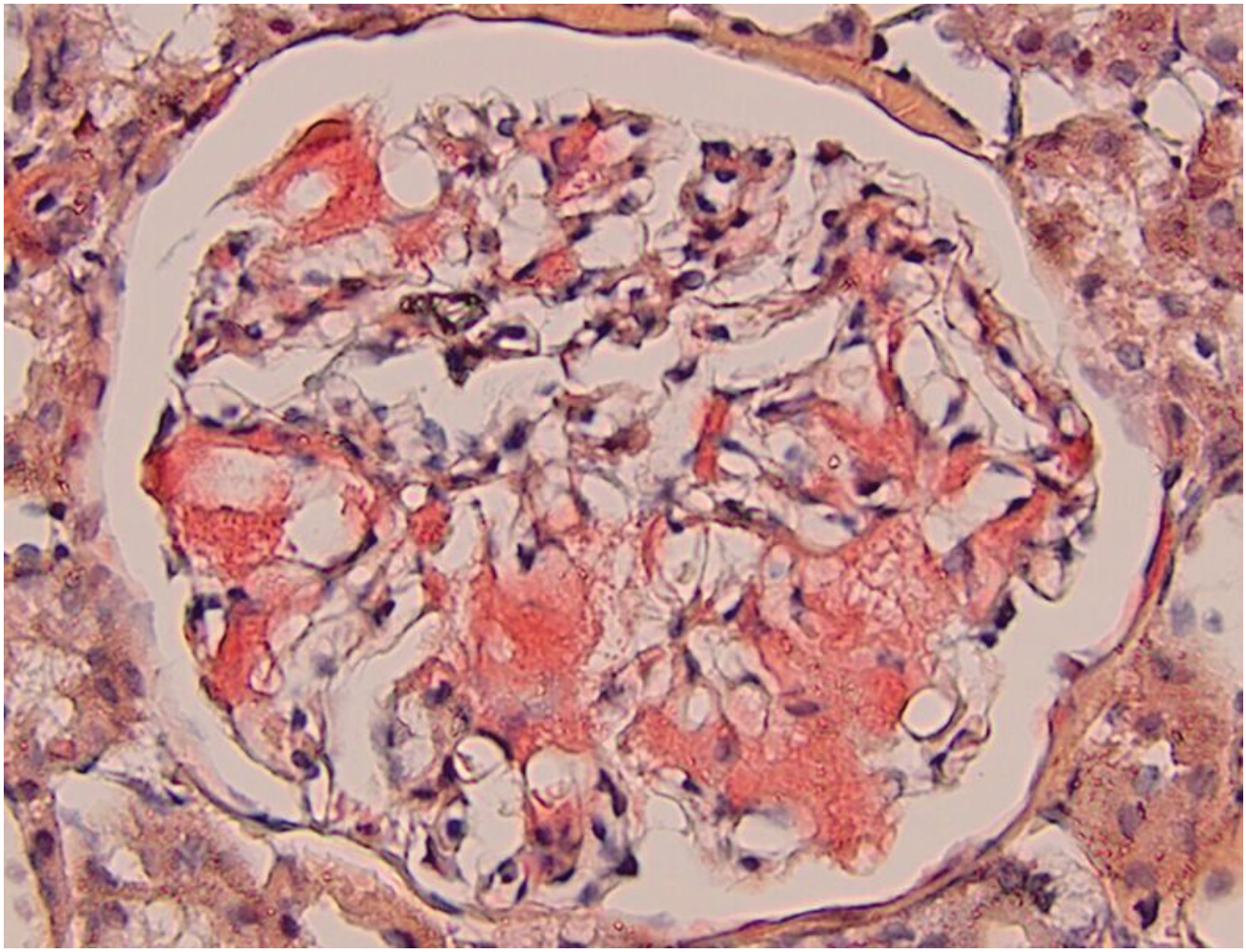

FIG.3E (CR): Amyloid is congophilic thus it stains orange to red with the specific stain. CR positive staining is essential to confirm the diagnosis.

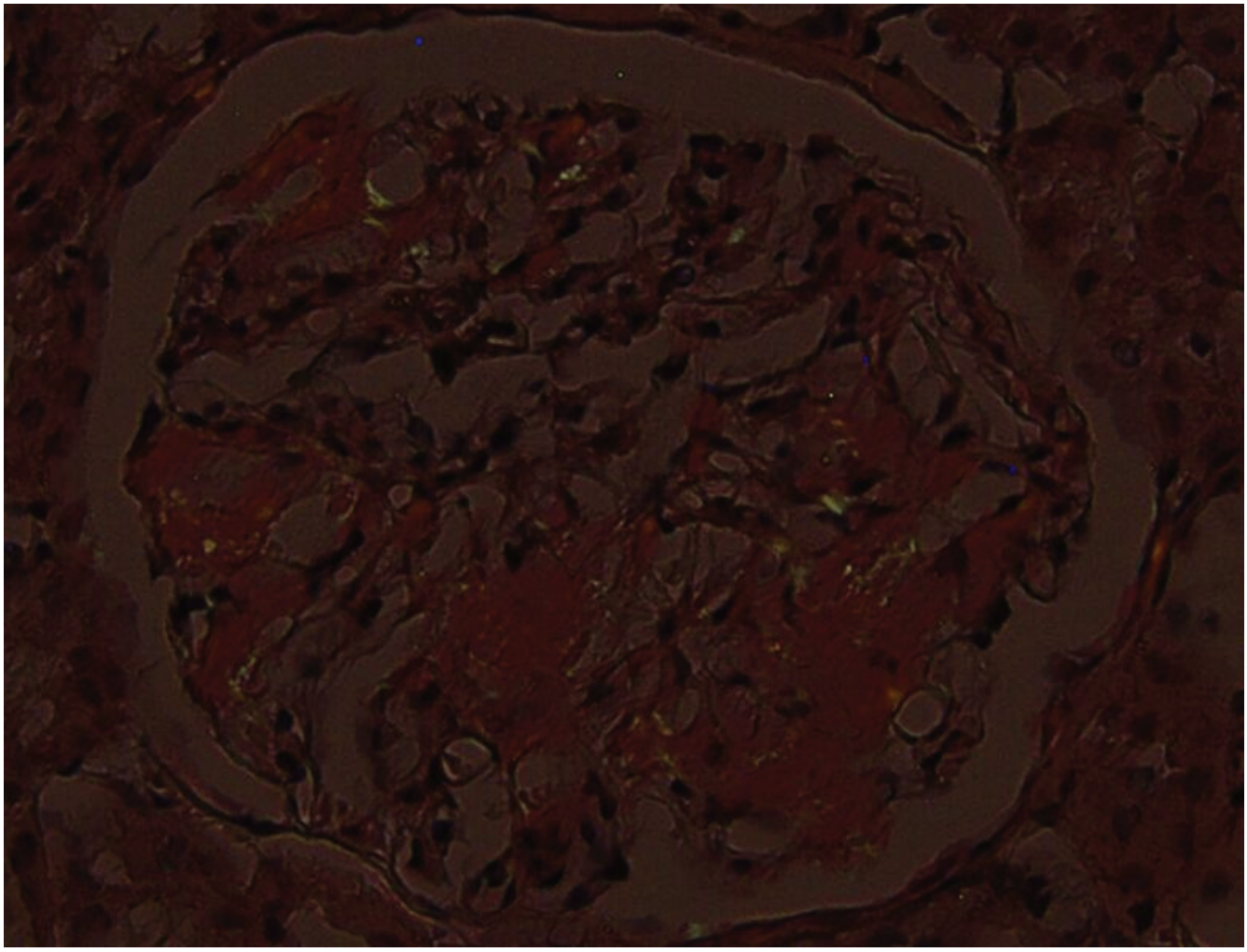

FIG.3F (CR viewed with polarized light): There are small foci of apple green birefringence. Of note, different areas will demonstrate birefringence at various planes of focus on the Z-axis.

SEVERE AMYLOID: Global effacement of most glomeruli by amyloid and there is associated hypocellularity.

An interactive or media element has been excluded from this version of the text. You can view it online here:
https://ohiostate.pressbooks.pub/vetrenalpathatlas/?p=5

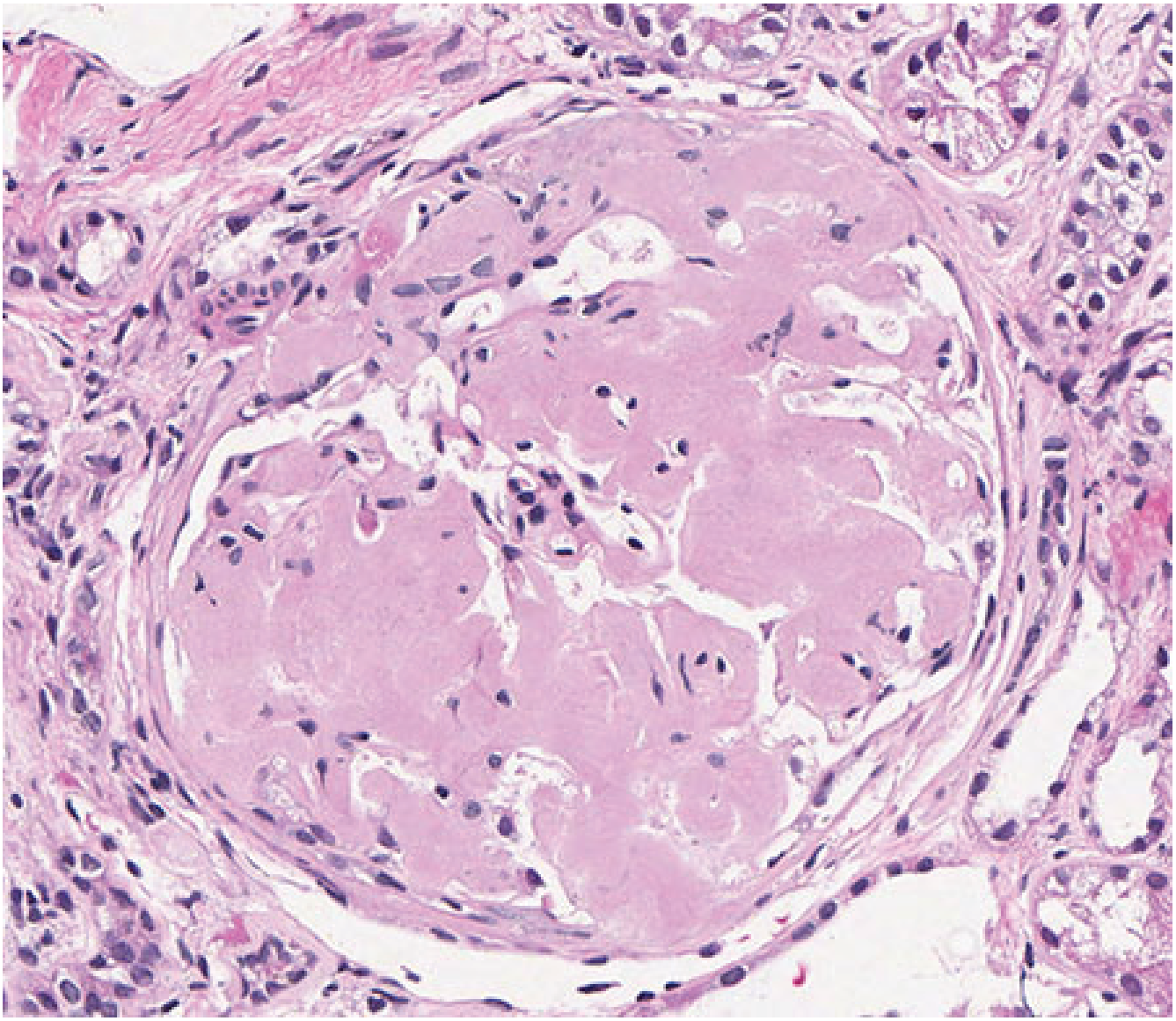

FIG.4A (HE): The major portion of the glomerular tuft is effaced by eosinophilic material and capillary lumena are difficult to identify. Note the surrounding interstitial fibrosis and tubular atrophy.

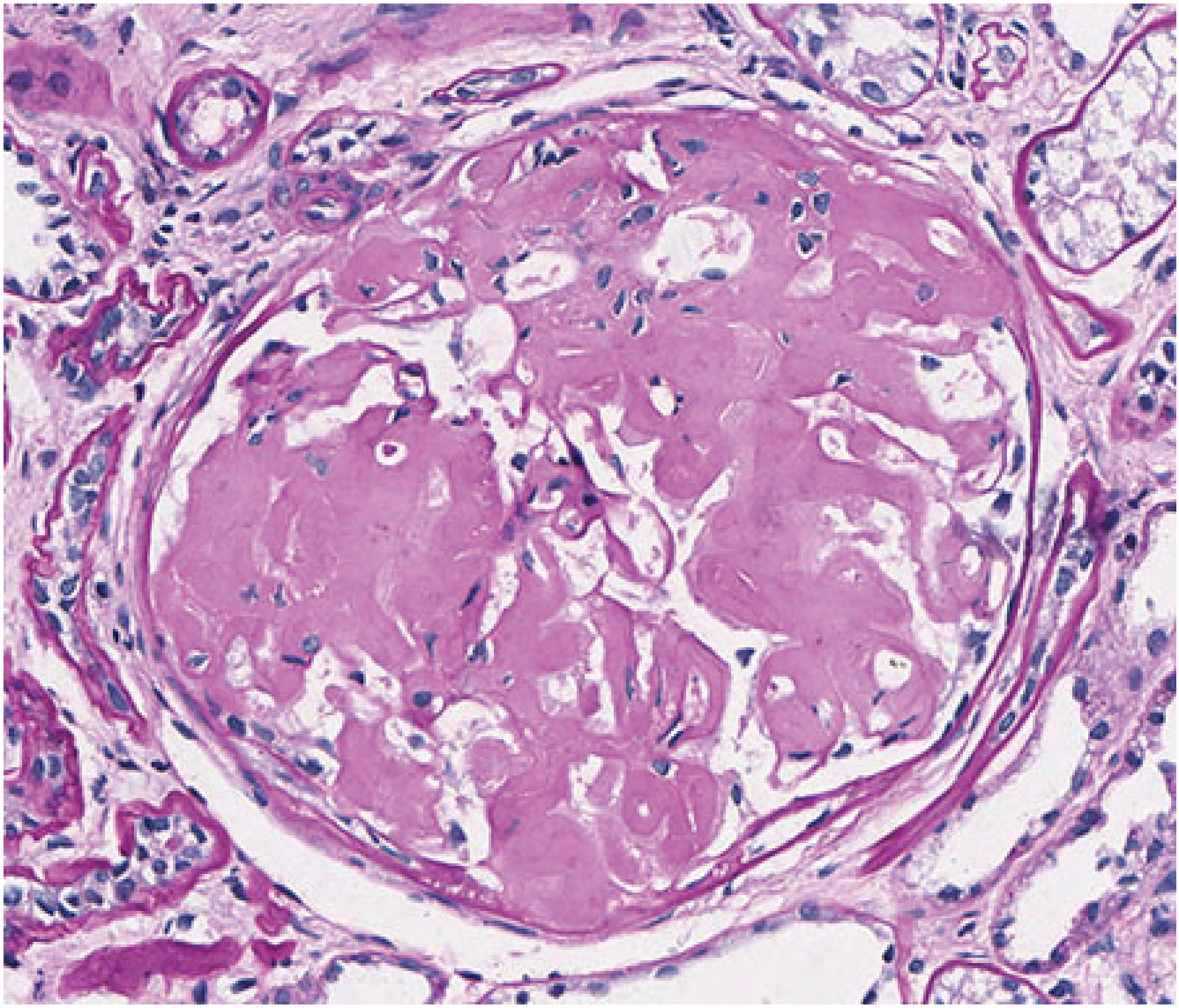

FIG.4B (PAS): Most glomeruli are effaced by waxy, pink material, and capillary lumens are difficult to identify.

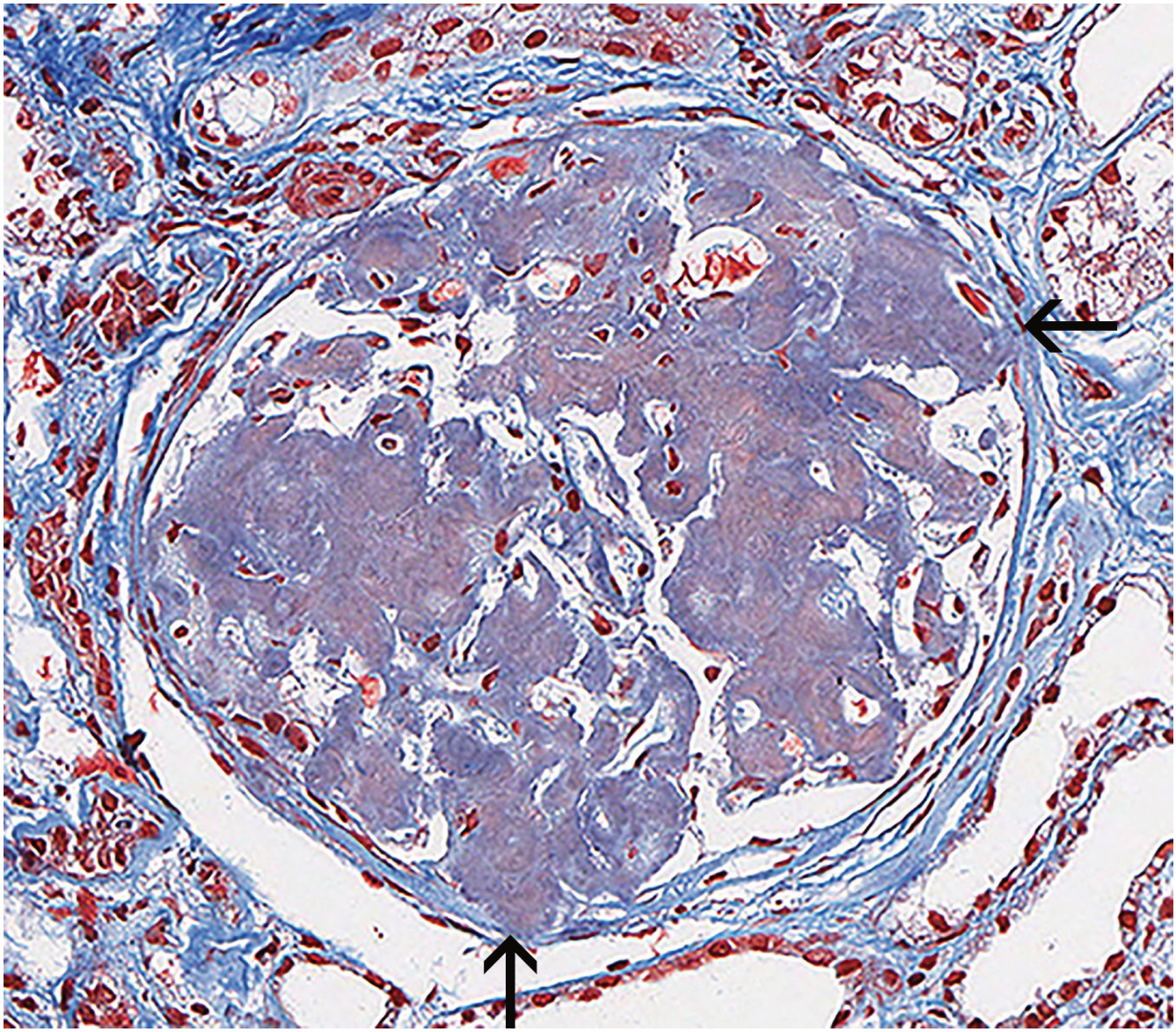

FIG.4C (MT): Amyloid deposits stain mottled blue to orange. Most glomeruli are effaced and capillary lumens are difficult to identify. Synechiae are also present (arrows).

FIG.4D (JMS): Amyloid does not take up silver with the JMS method. Most glomeruli are effaced by eosinophilic material and capillary lumens are difficult to identify. Synechiae are also present (arrows).

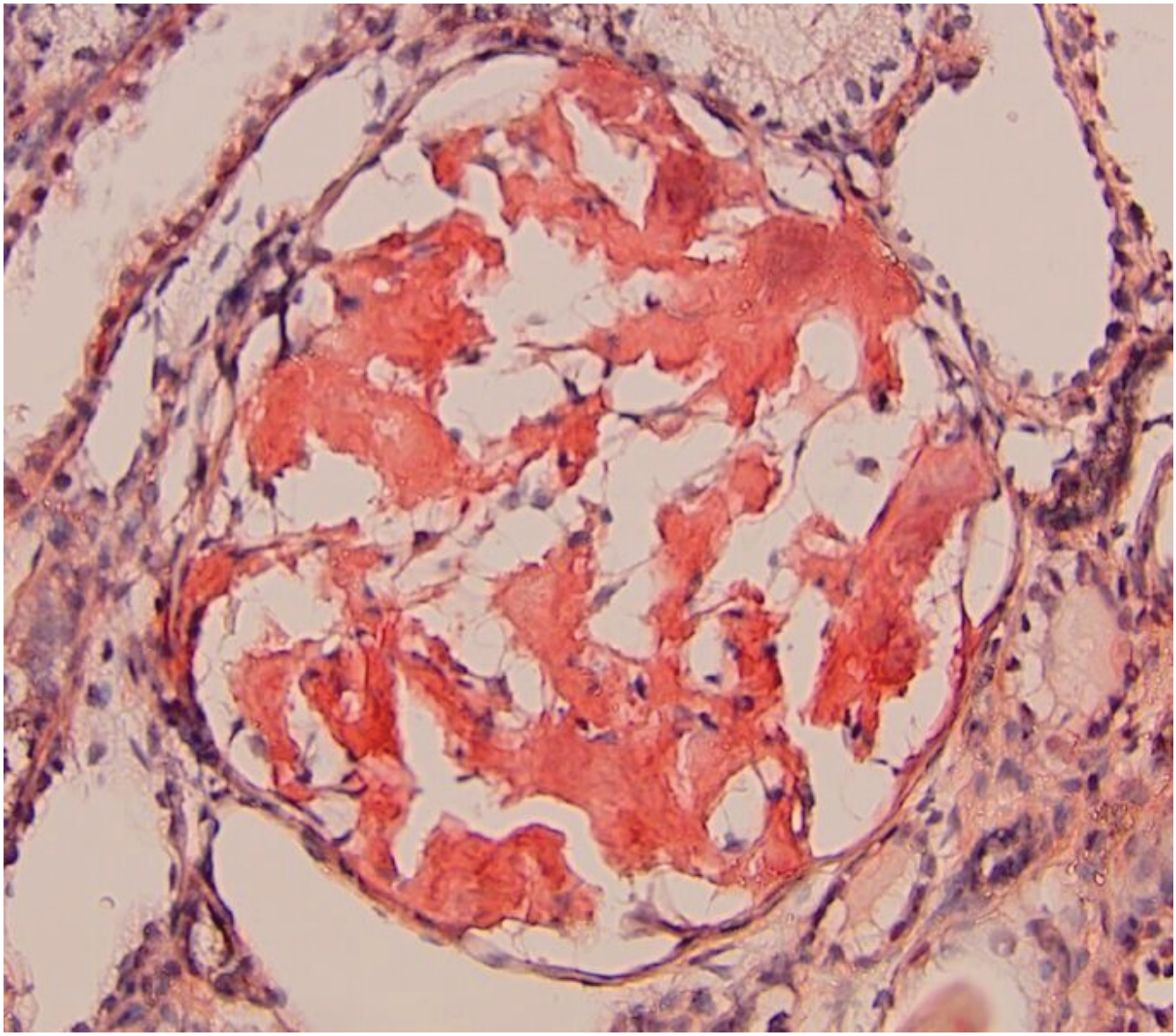

FIG.4E (CR): Amyloid is congophilic thus it stains orange to red with the specific stain. CR positive staining is essential to confirm the diagnosis.

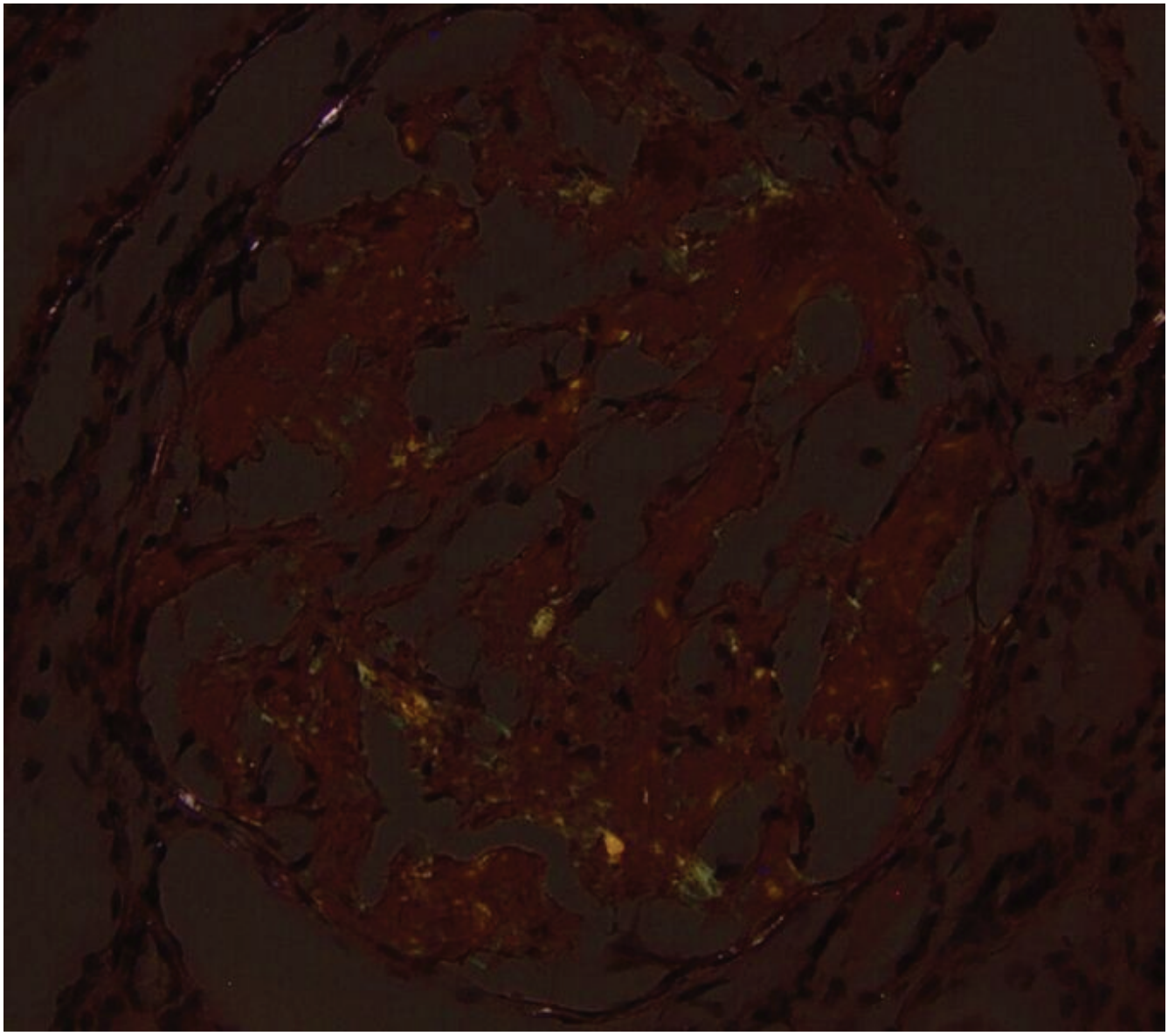

FIG.4F (CR viewed with polarized light): There are small foci of apple green birefringence. Of note, different areas will demonstrate birefringence at various planes of focus on the Z axis.

AMYLOID WITH SPICULES: In some animals with glomerular amyloidosis, the amyloid fibrils are organized into spicules, admixed with GBM material, extending toward the urinary space (see FIG.5C-5F). In humans, this histologic phenotype is called the “Roman helmet” or “coxcomb” appearance. Spicules can only be observed with special stains (MT and JMS) and by TEM.

An interactive or media element has been excluded from this version of the text. You can view it online here:
https://ohiostate.pressbooks.pub/vetrenalpathatlas/?p=5

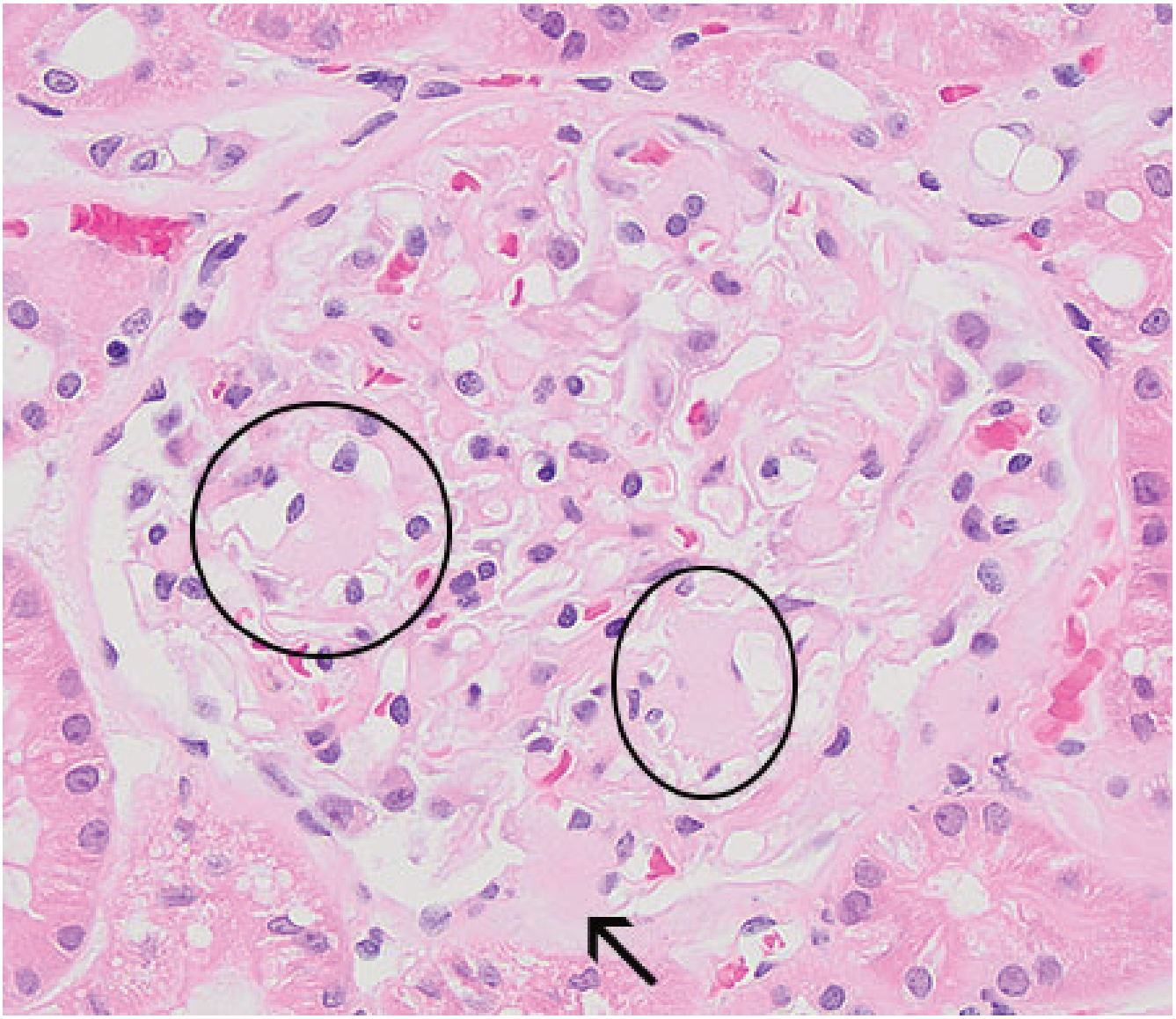

FIG.5A (HE): Mesangium is expanded by eosinophilic material consistent with amyloid (circles) and there is a synechia (arrow).

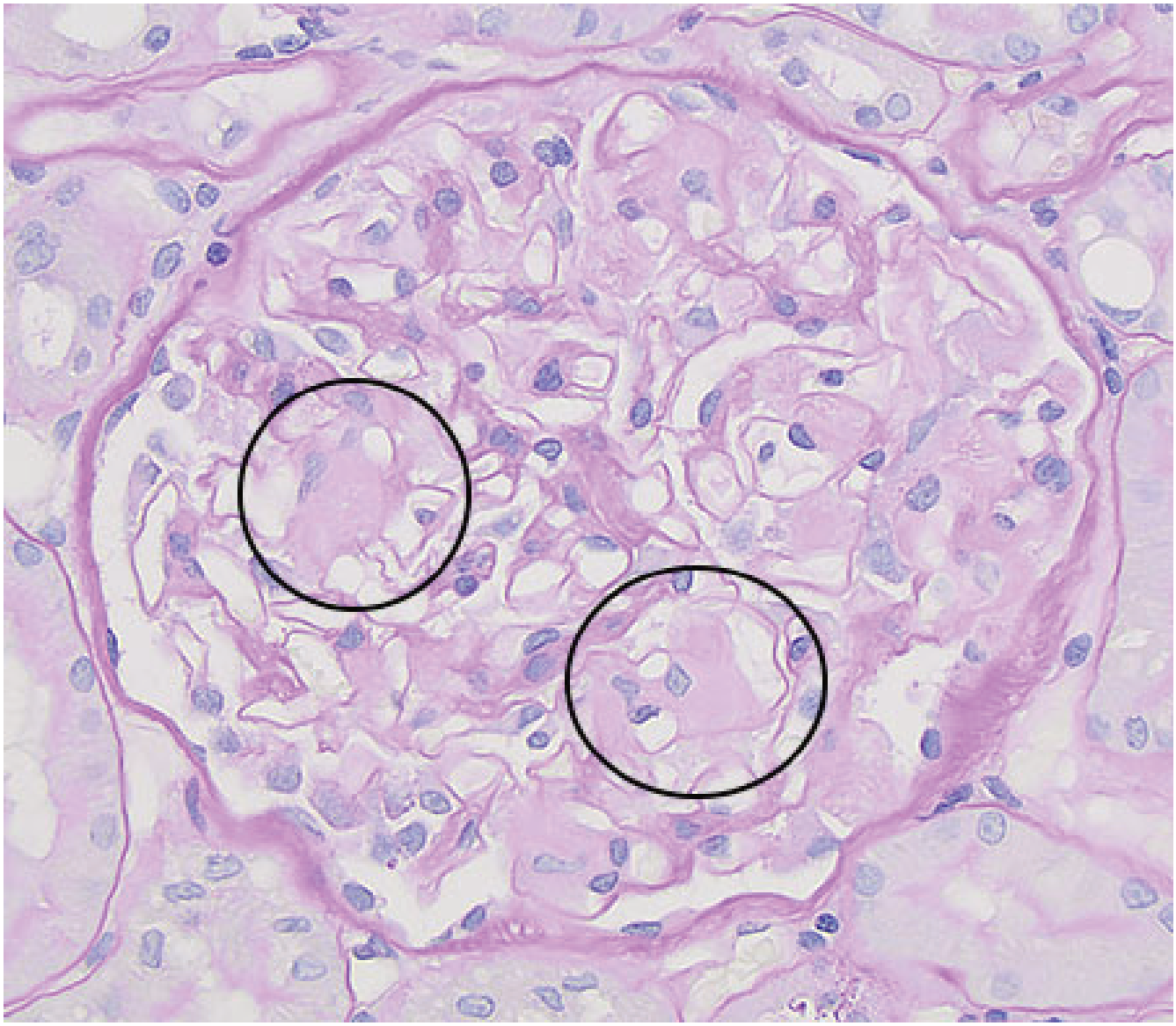

FIG.5B (PAS): Mesangium is expanded by pale pink material consistent with amyloid (circled).

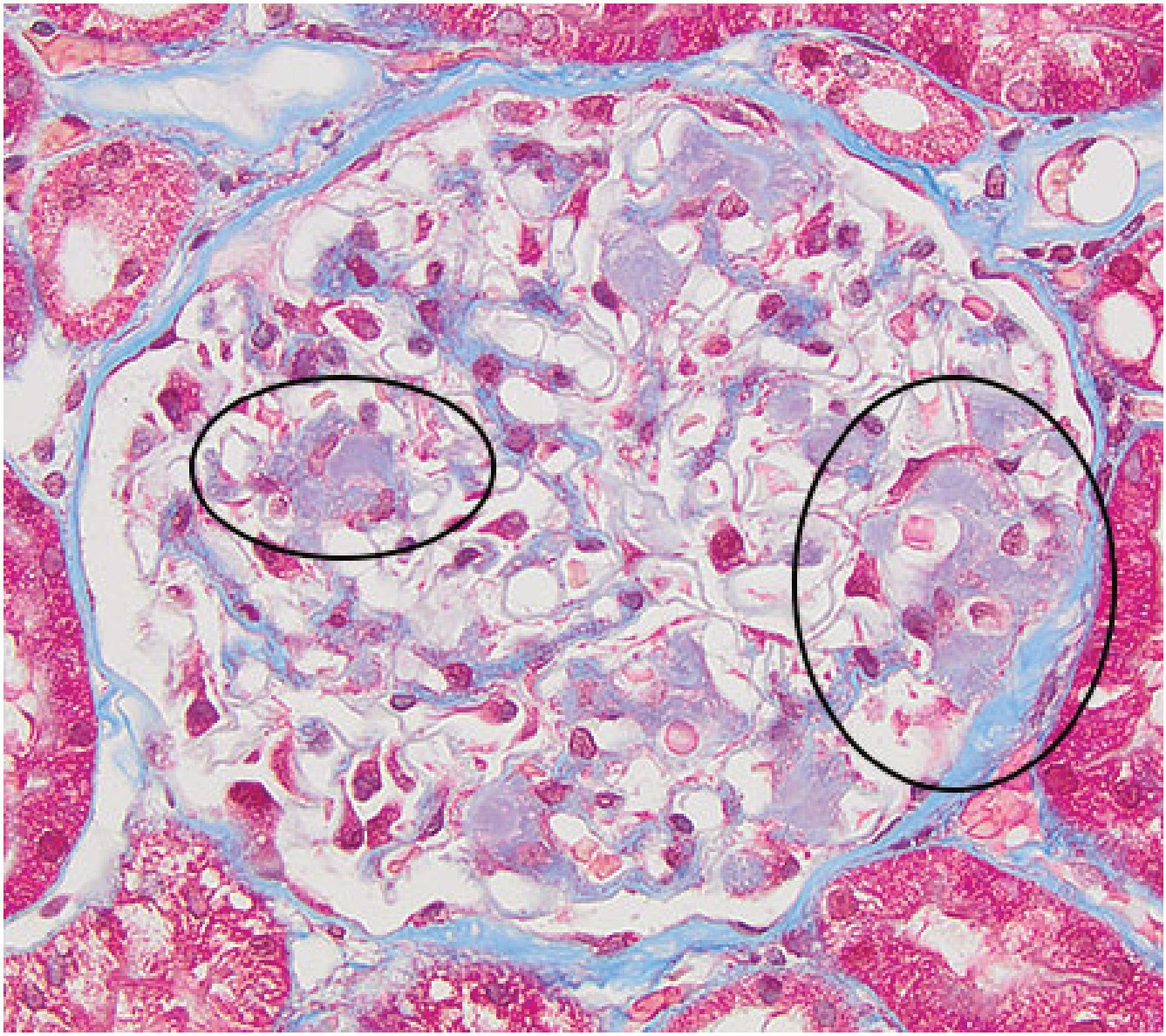

FIG.5C (MT): Mesangium is expanded by pale blue material consistent with amyloid (circled).

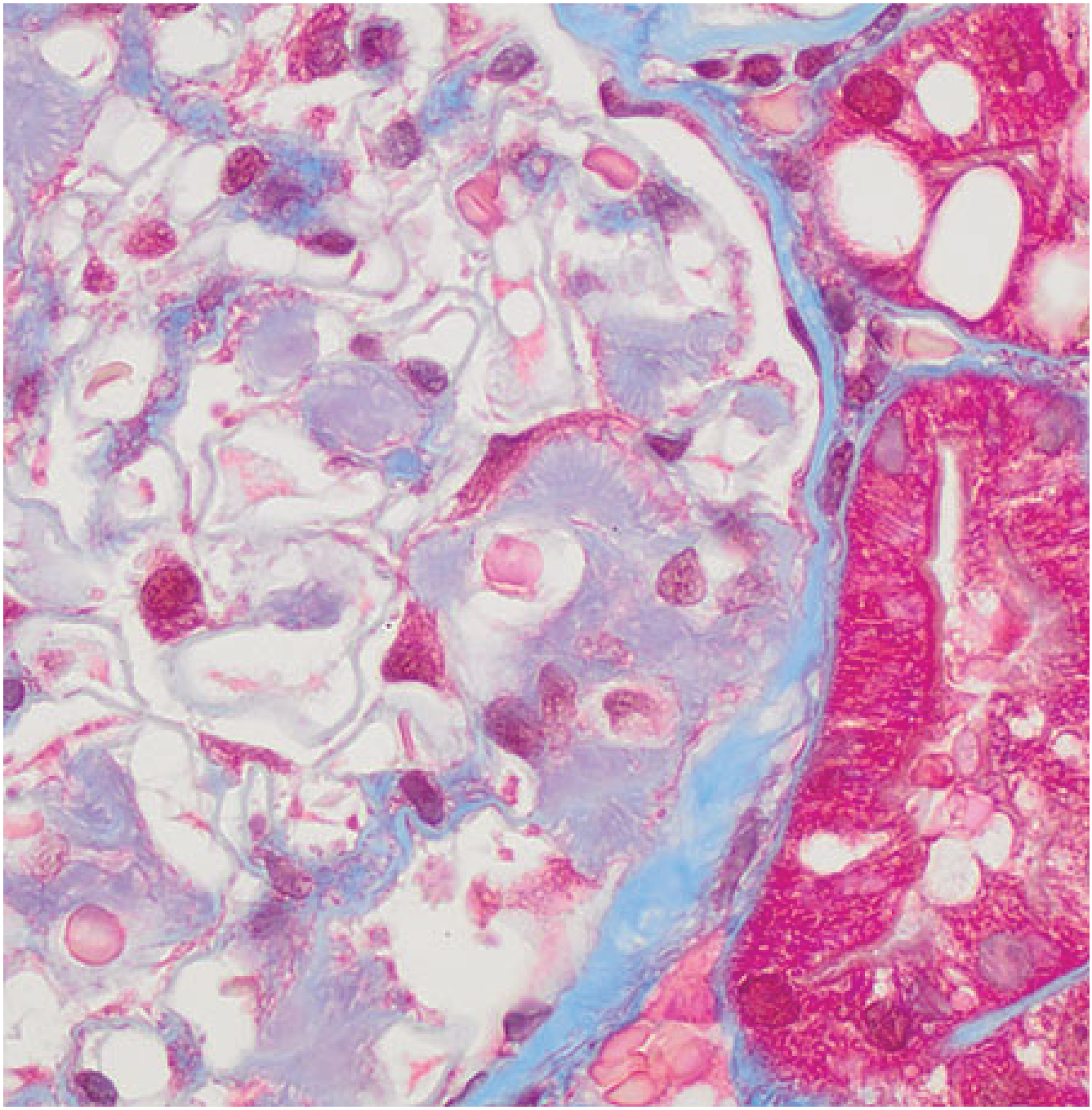

FIG.5D (MT): Higher magnification. There are pale blue spicular projections, representing a combination of amyloid and GBM material, towards the urinary space.

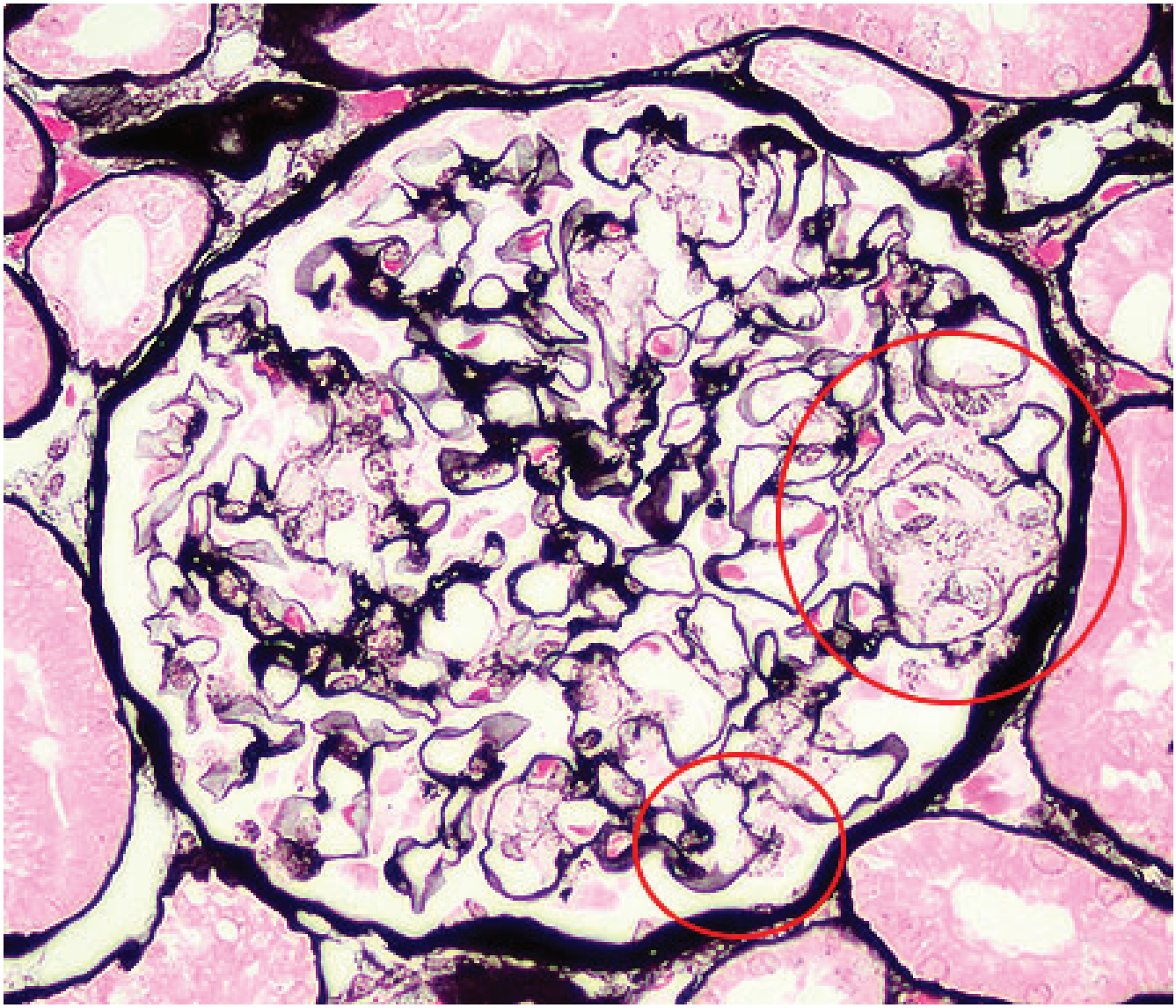

FIG.5E (JMS): There are focal spicular projections of GBM material towards the urinary space, perpendicular to the GBM (circled).

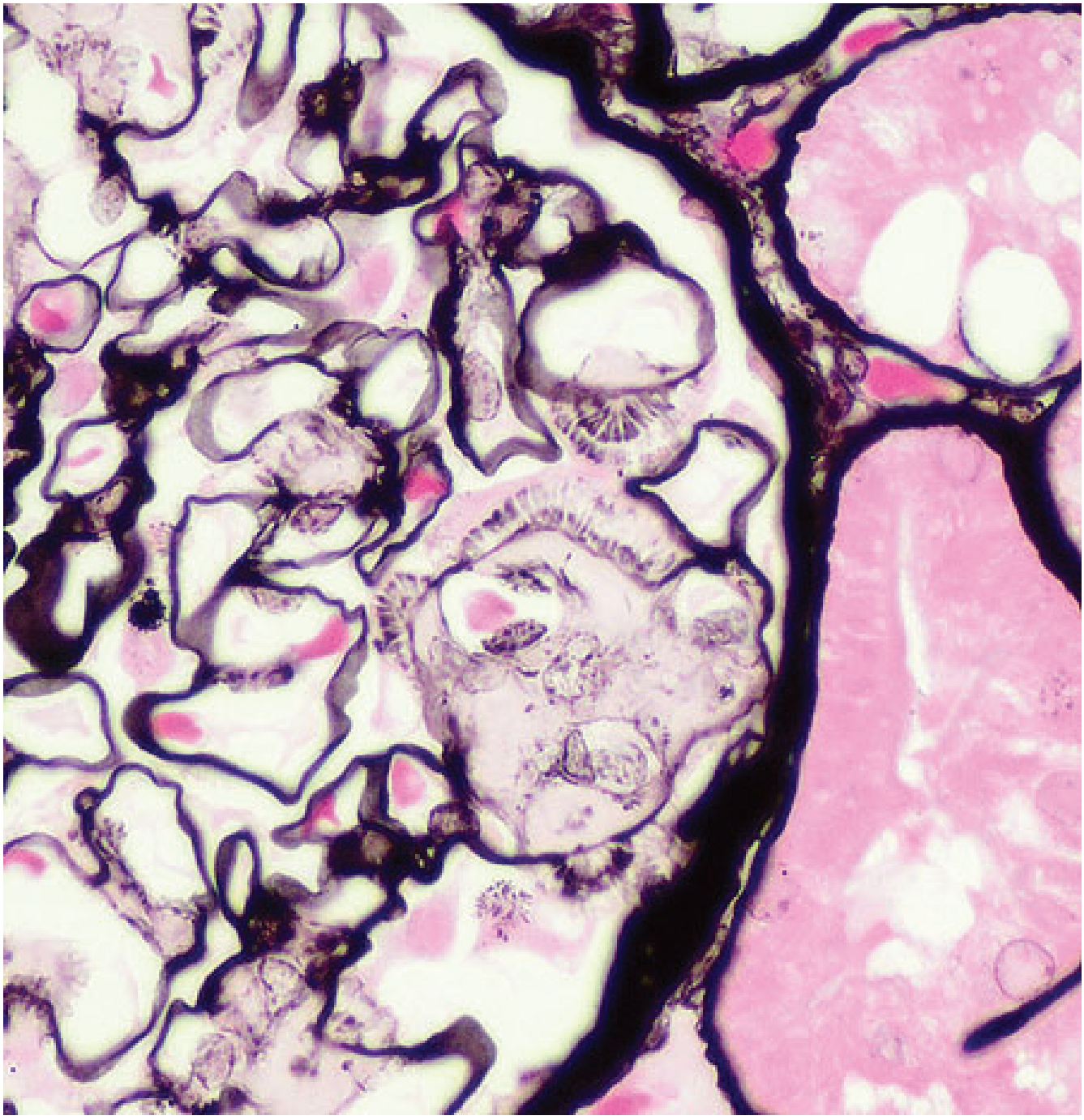

FIG.5F (JMS): Higher magnification of the spicular projections towards the urinary space, the spicules are focal and subepithelial.

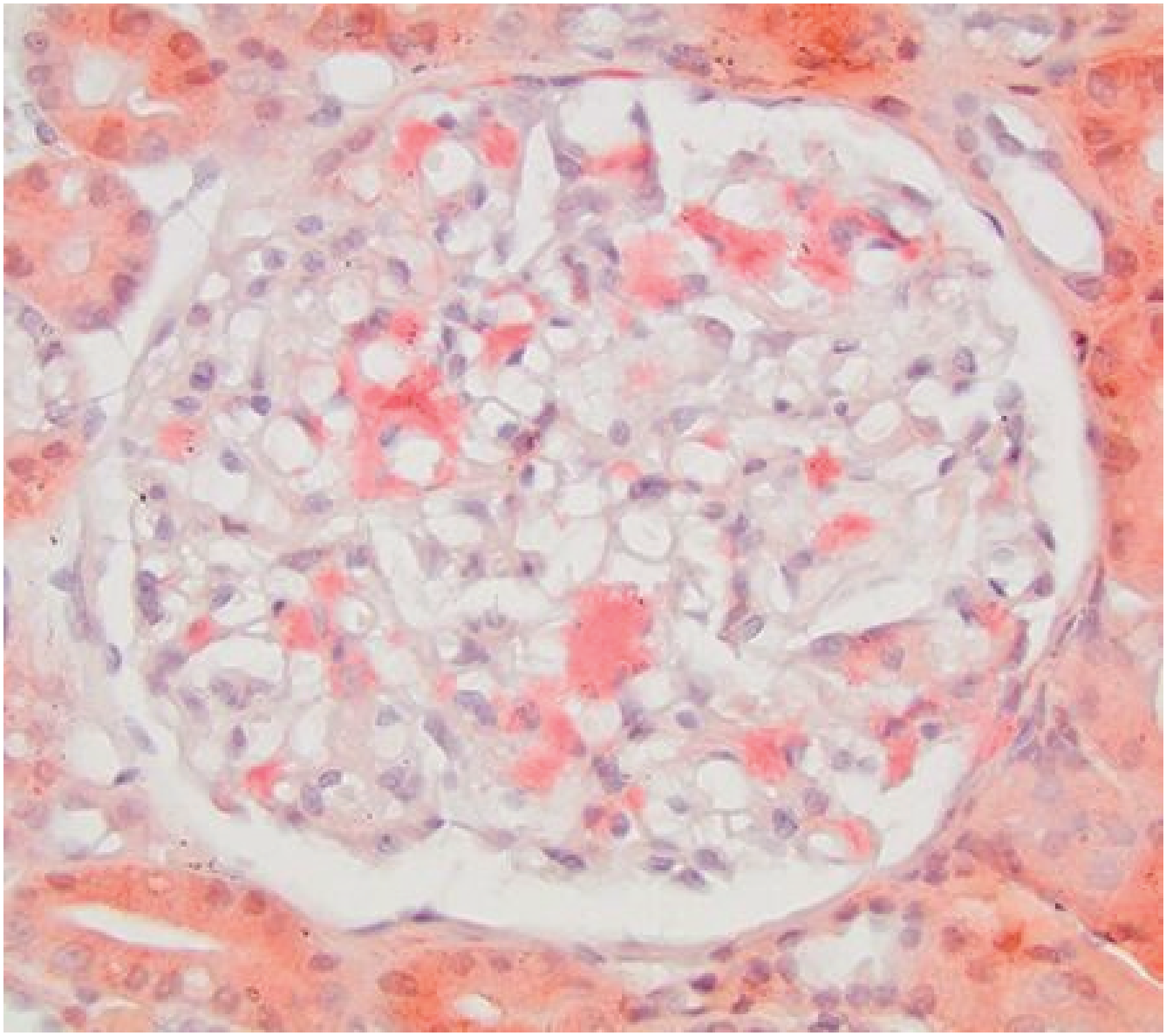

FIG.5G (CR): Congo red material expands the mesangium. Because CR method is performed on a thicker section (8-10 µm instead of 2-3 µm), spicules might be difficult to appreciate with this stain.

An interactive or media element has been excluded from this version of the text. You can view it online here:
https://ohiostate.pressbooks.pub/vetrenalpathatlas/?p=5

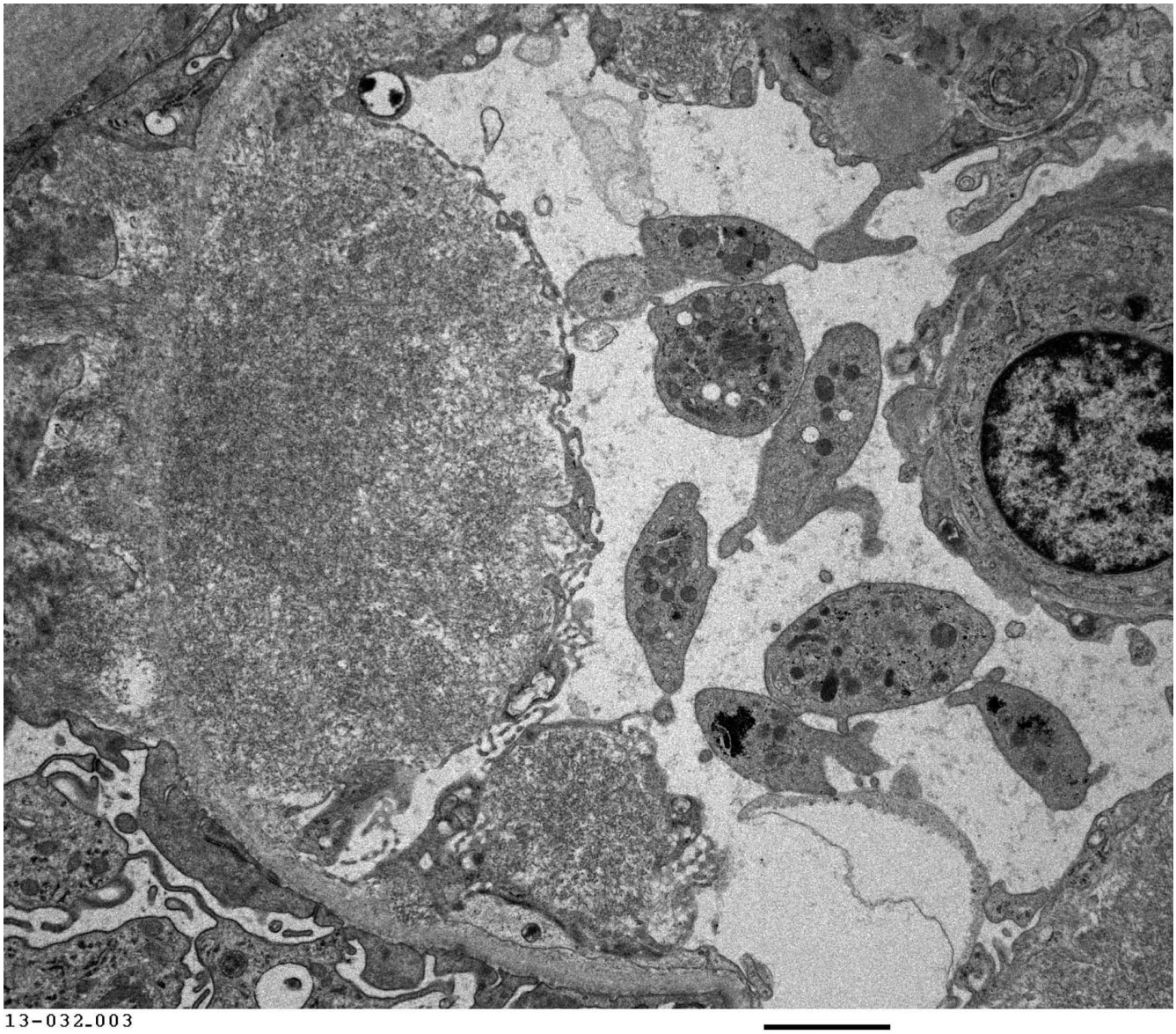

FIG.5H (TEM): Amyloid fibrils are densely packed and organized into small spicules oriented perpendicular to the GBM beneath podocytes. The podocyte is on the left side of this electron micrograph. There are multiple platelets within the capillary lumen.

An interactive or media element has been excluded from this version of the text. You can view it online here:
https://ohiostate.pressbooks.pub/vetrenalpathatlas/?p=5

FIG.5I (TEM): Colorized version of above TEM image. (Yellow: endothelial cell, Blue: amyloid fibrils, Green: GBM, Pink: podocyte). There are multiple platelets within the capillary lumen (uncolored).



FIG.5J (TEM): Higher magnification of the amyloid fibrils demonstrating their haphazard arrangement.

INTERSTITIAL AND VASCULAR AMYLOID: In some animals, amyloid is identified in interstitial regions or vessel walls.

An interactive or media element has been excluded from this version of the text. You can view it online here:
https://ohiostate.pressbooks.pub/vetrenalpathatlas/?p=5

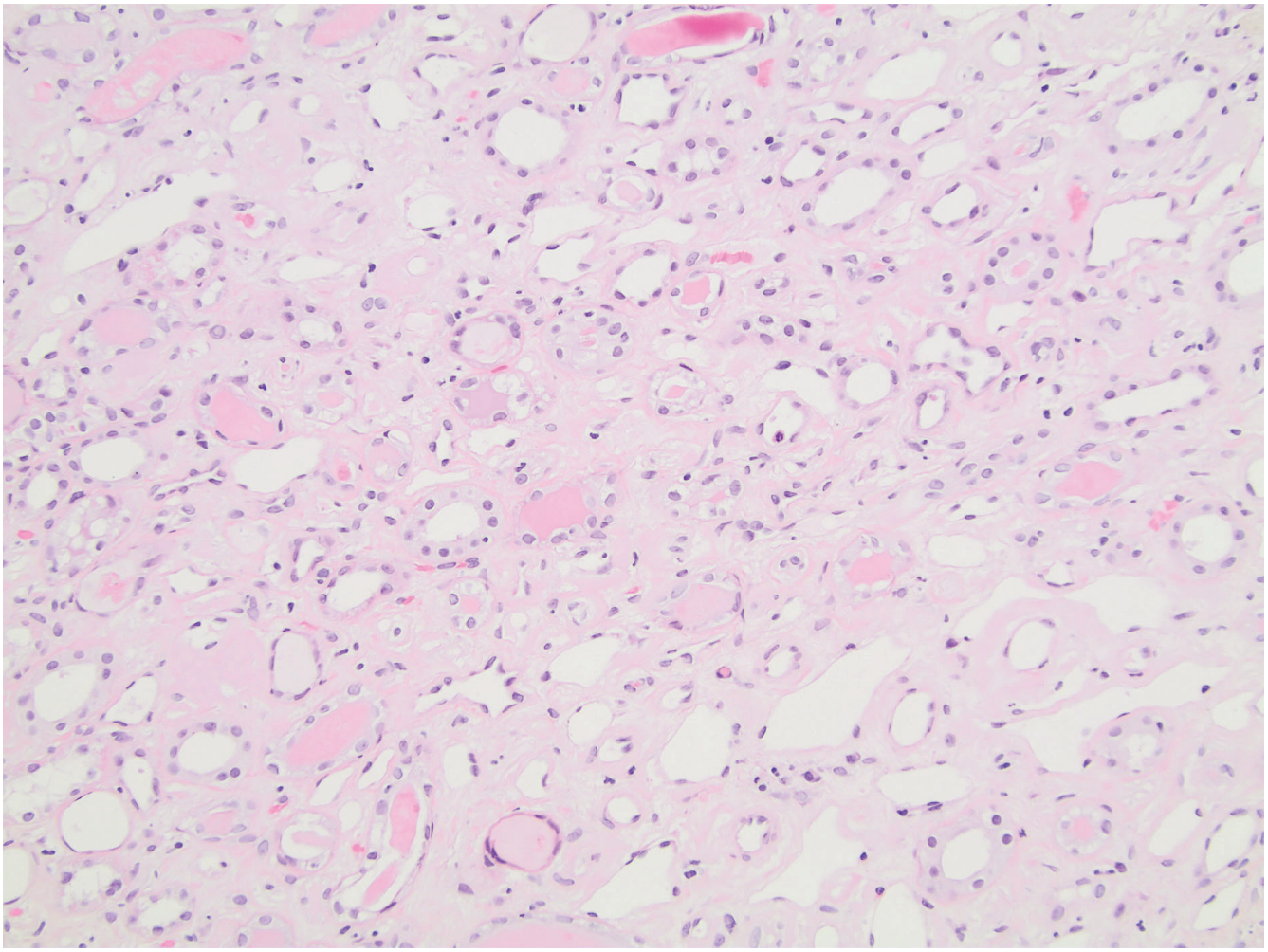

FIG.6A (HE): Medullary interstitium is mildly to moderately expanded by eosinophilic material; many tubules contain protein casts.

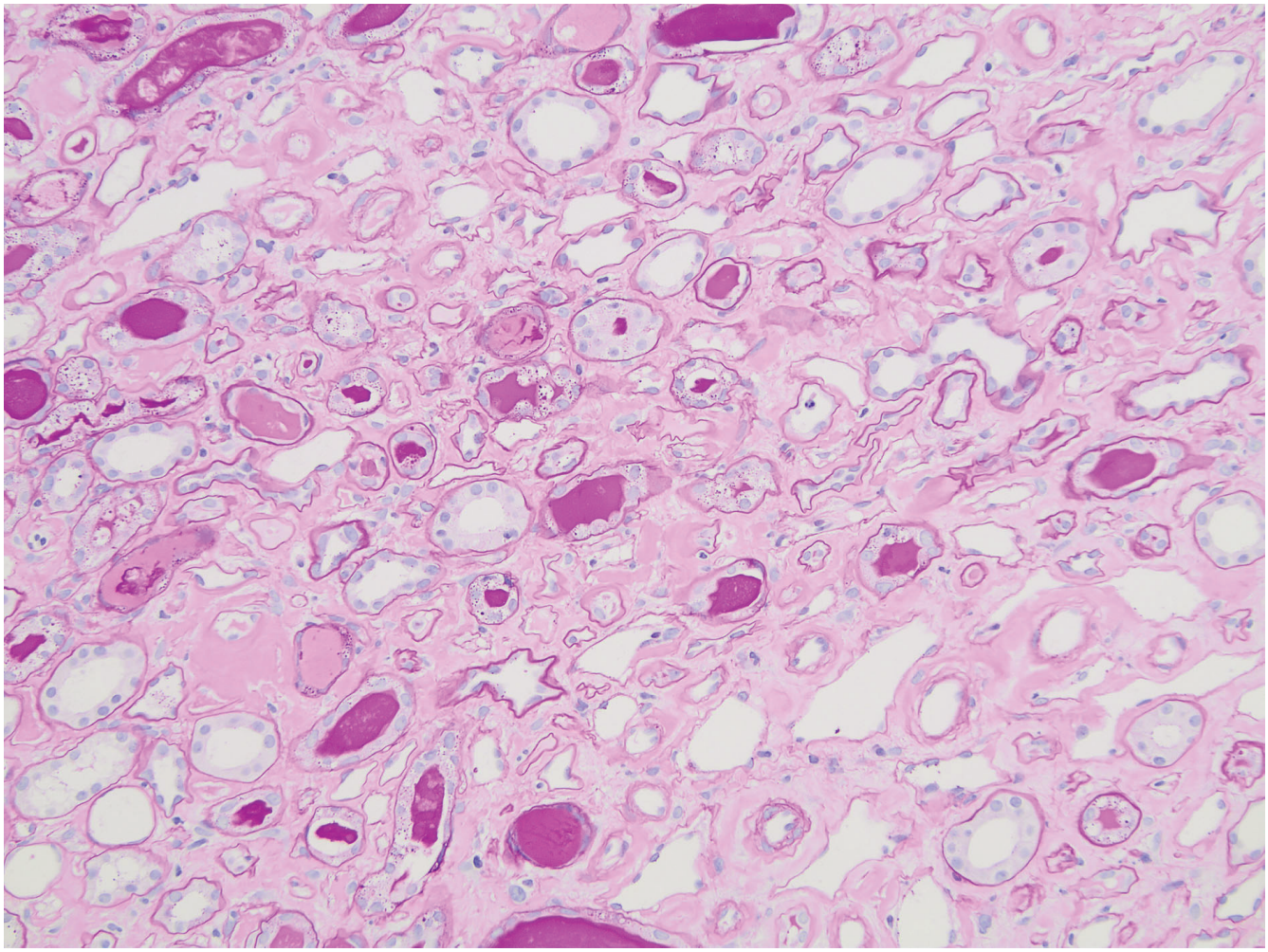

FIG.6B (PAS): Medullary interstitium is mildly to moderately expanded by pale pink material; many tubules are atrophic characterized by wrinkled thickened tubular basement membranes. The intraluminal protein casts are PAS positive, varying from pink to magenta.

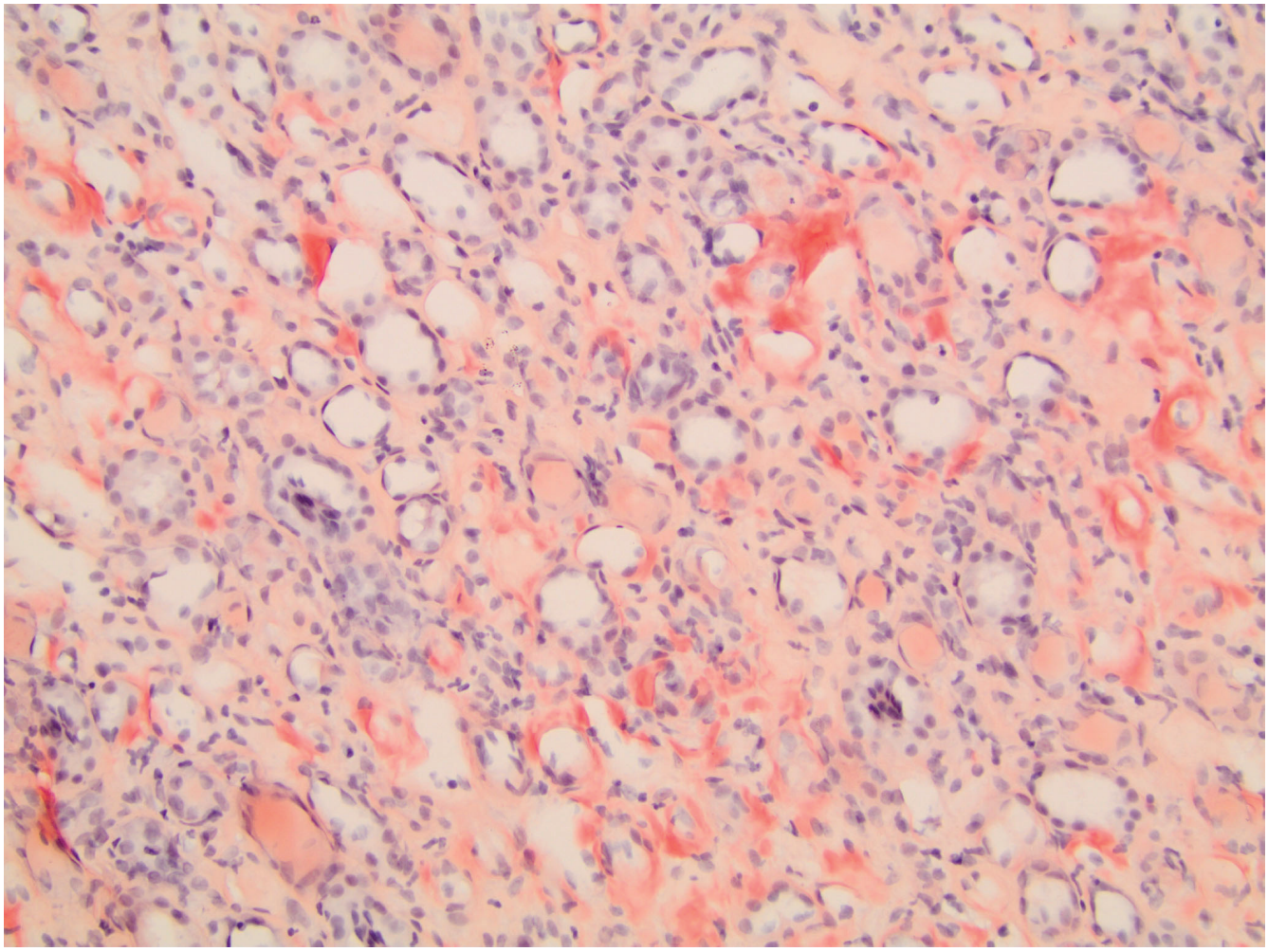

FIG.6C (CR): Medullary interstitium is mildly to moderately expanded by congophilic, peach material.

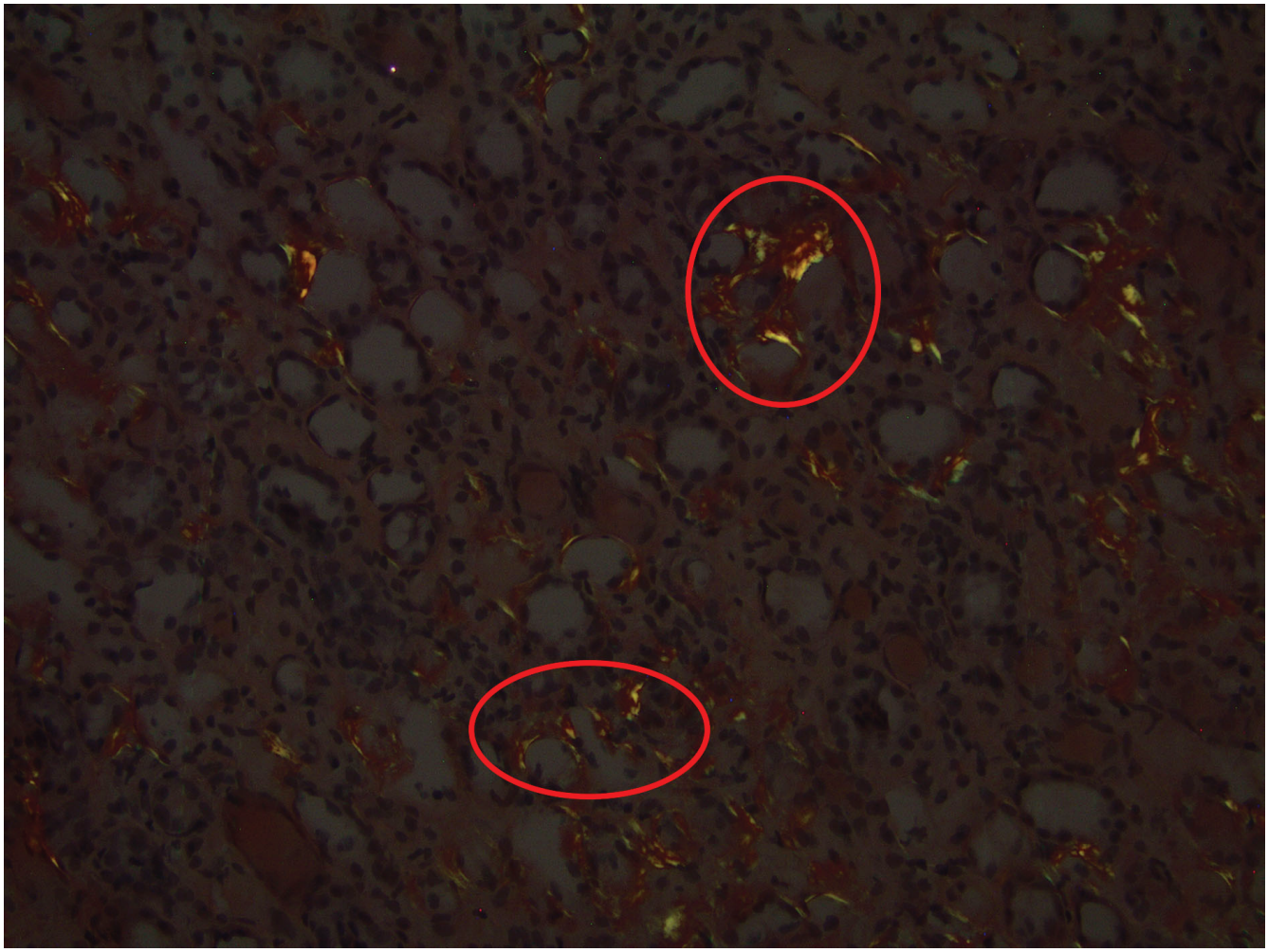

FIG.6D (CR viewed with polarized light): There is apple green birefringent material in the interstitium.

VASCULAR AMYLOIDOSIS: Arterial walls are expanded by congophilic material.

An interactive or media element has been excluded from this version of the text. You can view it online here:
https://ohiostate.pressbooks.pub/vetrenalpathatlas/?p=5

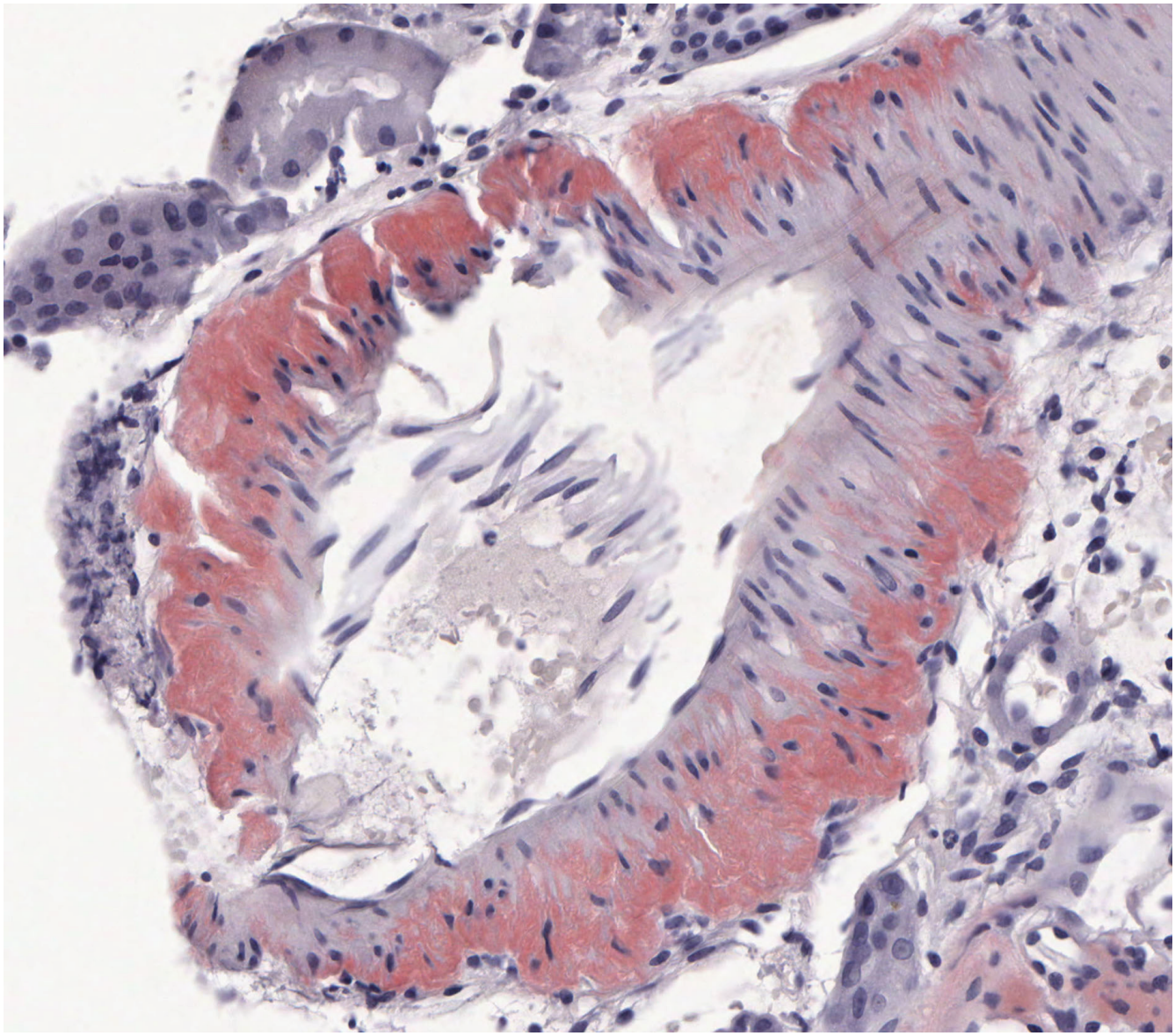

FIG.6E (CR): The wall of an arcuate caliber artery is expanded by congophilic material.

FIGURE 7: ADDITIONAL DIAGNOSTICS FOR AMYLOID: TEM reveals shows are haphazardly arranged fibrils (9-11nm in diameter) in glomeruli. IF demonstrates strong non-specific labeling of glomeruli.

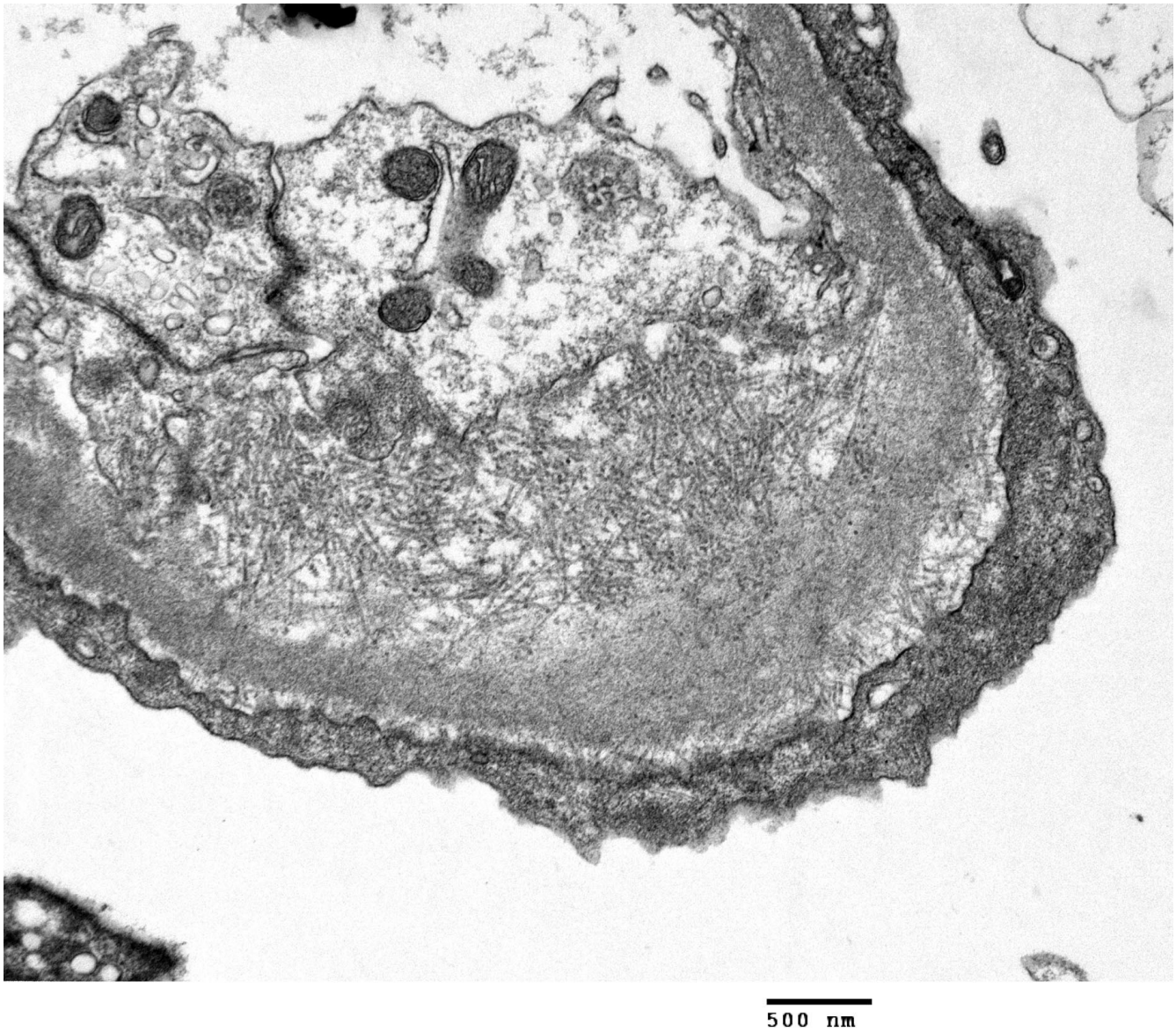

FIG.7A (TEM): There is subendothelial expansion due to the presence of haphazardly arranged fibrils, 9 to 11 nanometers in diameter. Some fibrils cross the GBM. The podocyte foot processes are effaced.

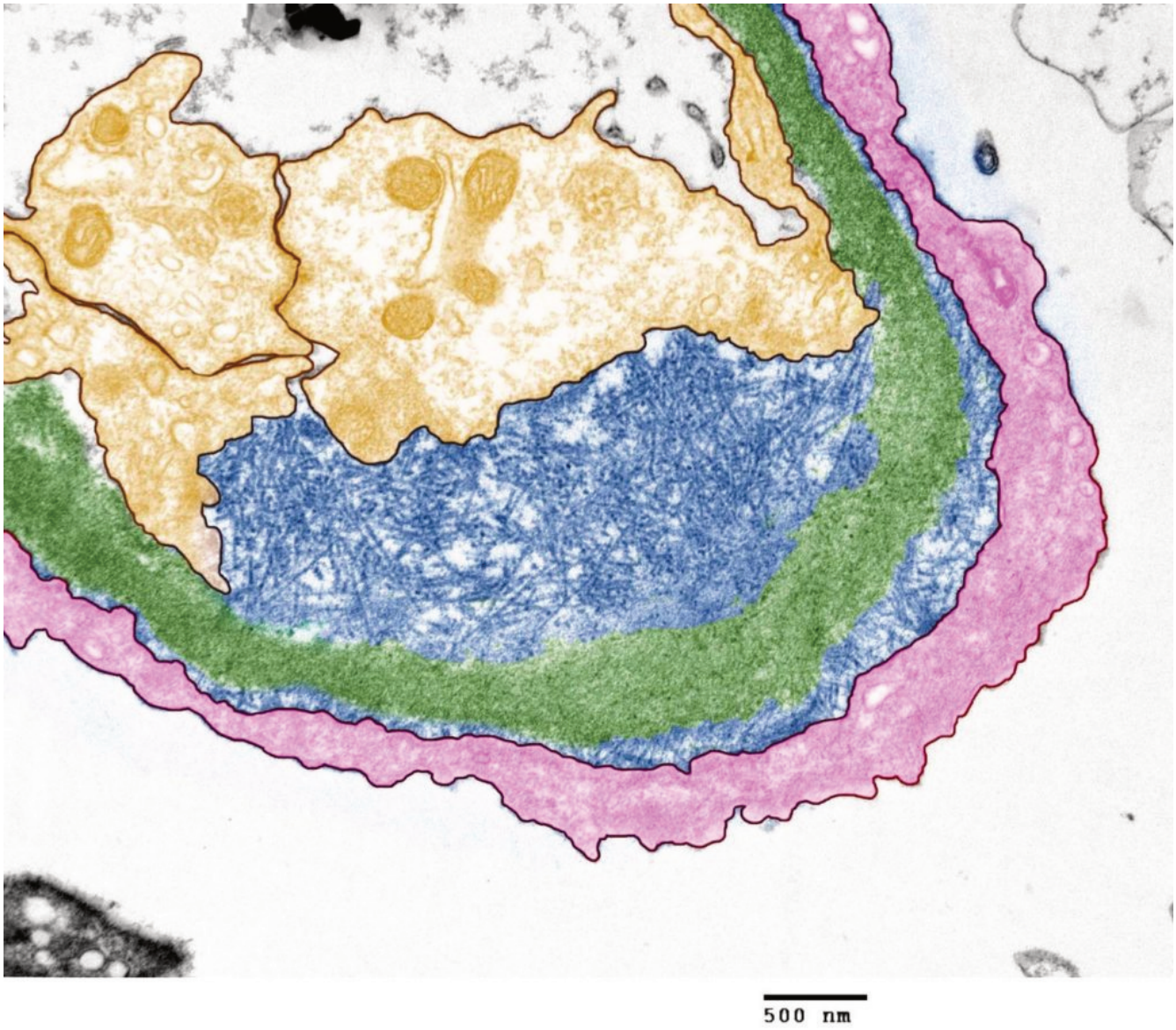

FIG.7B (TEM): Colorized version of previous TEM image (Yellow: endothelial cell, Blue: amyloid fibrils, Green: GBM, Pink: podocyte).

IF OF AMYLOIDOSIS: Strond non-specific labeling of glomeruli.

An interactive or media element has been excluded from this version of the text. You can view it online here:
https://ohiostate.pressbooks.pub/vetrenalpathatlas/?p=5

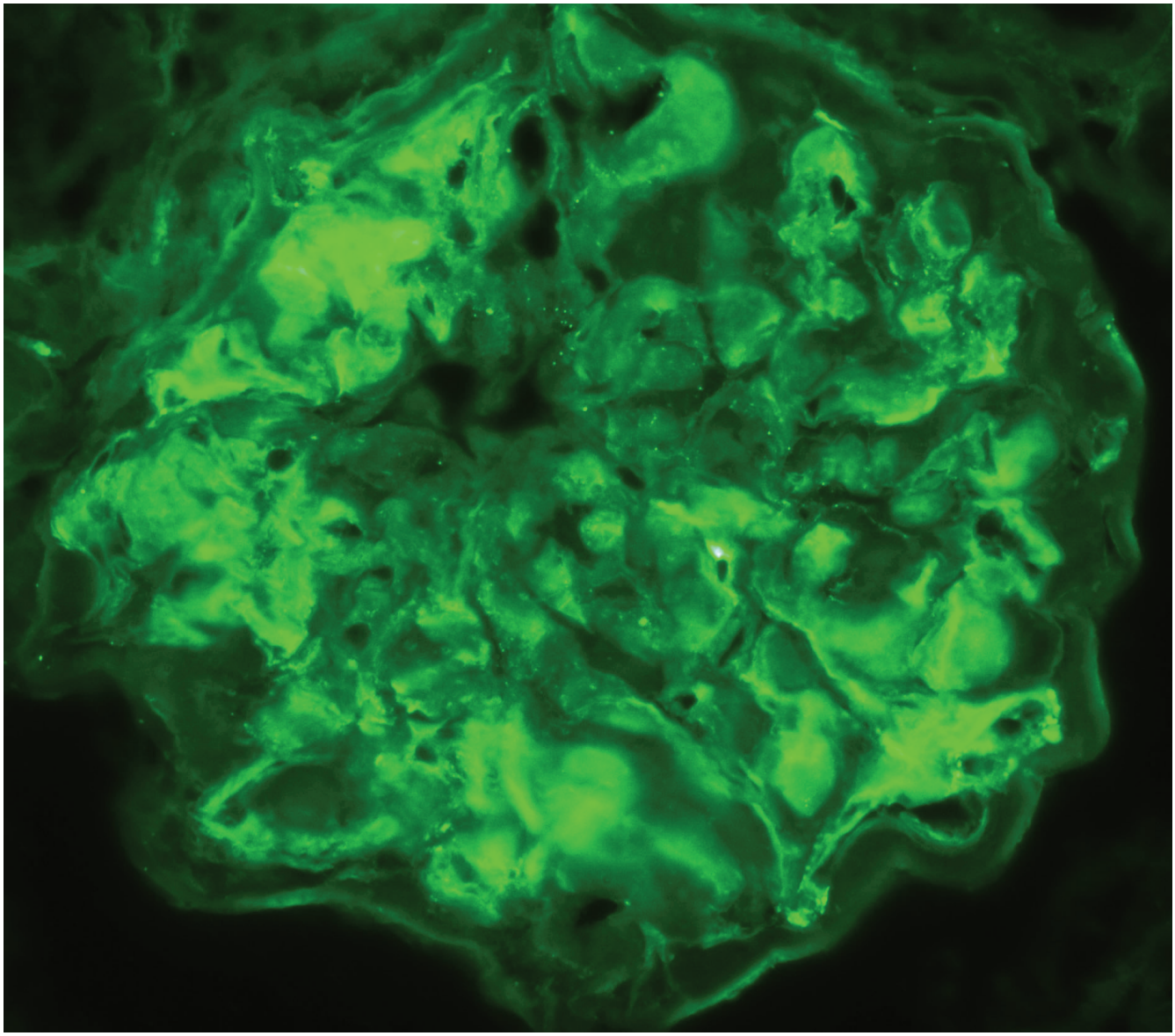

FIG.7C (IF for LLC): Granular labeling is not identified; however, there is moderate to strong splotchy non-specific labeling of the glomerular tuft due to entrapment of normal plasma proteins within the amyloid fibrils.

Differential Diagnoses for Amyloidosis:

Disease	Defining Histologic Features	Defining Ultrastructural Features
Amyloidosis	• Material exhibits apple-green birefringence when the Congo red stain is viewed with polarized light. • Material does not take up silver with the JMS method. • ALL glomeruli are similarly affected (always generalized)	Haphazardly arranged, non-branching fibrils, 9 to 11nm in diameter
Non-amyloidotic fibrils	• Material might appear orange with the Congo red stain but does not exhibit birefringence when viewed with polarized light. • Material does not take up silver with the JMS method.	Haphazardly arranged fibrils > 12 nm and are often > 15nm
Glomerulosclerosis	• Birefringence is not a feature. • Expanded mesangium and capillary walls will take up silver with the JMS method. • Variability in severity of GS among glomeruli, some glomeruli may not be affected (may be focal)	Discrete fibrils are not identified.

Key Diagnostic Features of Amyloidosis

- Expansion of the mesangium and / or the capillary walls by extracellular material to a similar degree in all glomeruli.
- The material stains pink with HE, pale pink with PAS, orange or blue with MT, does not take up silver with the JMS, is orange / peach with the CR method, and exhibits apple green birefringence when the CR is viewed with polarized light.
- Ultrastructurally, fibrils are 9 to 11nm in diameter and do not branch. They are usually haphazardly arranged but can form spicular aggregates along the capillary walls with corresponding remodeling of the GBM material.
- IF can demonstrate bright non-specific labeling.
- Amyloid can also be present in the interstitium and in vasculature. Interstitial deposition more likely to be associated with azotemia.

Amyloidosis References

- Segev, G., Cowgill, L. D., Jessen, S., Berkowitz, A., Mohr, C., Aroch, I. (2012). Renal Amyloidosis in Dogs: A Retrospective Study of 91 Cases with Comparison of the Disease between Shar-Pei and Non-Shar-Pei Dogs. *Journal of Veterinary Internal Medicine*, 26(2): 259-268.
    - http://onlinelibrary.wiley.com/doi/10.1111/j.1939-1676.2011.00878.x/epdf
- Olsson, M., Tintle, L., Kierczak, M., Perloski, M., Tonomura, N., Lundquist, A., Meadows, J. R. S. (2013). Thorough Investigation of a Canine Autoinflammatory Disease (AID) Confirms One Main Risk Locus and Suggests a Modifier Locus for Amyloidosis. *PLoS ONE*, 8(10): e75242.
    - http://doi.org/10.1371/journal.pone.0075242
- Schneider, S.M., Cianciolo, R.E., Nabity, M.B., Clubb, F.J., Brown, C.A. Lees, G.E. (2013), Prevalence of Immune-Complex Glomerulonephritides in Dogs Biopsied for Suspected Glomerular Disease: 501 Cases (2007–2012). *J Vet Intern Med*, 27: S67–S75.
    - http://onlinelibrary.wiley.com/doi/10.1111/jvim.12247/full
- Cianciolo, R.E., Mohr, F.C., Aresu, L., Brown, C.A., James, C., Jansen, J.H., Spangler, W.L., van der Lugt, J.J., Kass, P.H., Brovida, C., Cowgill, L. D., Heiene, R., Polzin, D.J., Syme, H., Vaden, S.L., van Dongen, A., Lees, G. E. (2016), World Small Animal Veterinary Association Renal Pathology Initiative: Classification of Glomerular Disease in Dogs. *Vet Pathol*, 53(1):113-135.
- Vaden, S. (2011), Glomerular Disease. *Topics in Comp Anim Med*, 26(3), 128-134.
    - http://dx.doi.org/10.1053/j.tcam.2011.04.003
- DiBartola, S.P., Tarr, M.J., Parker, A.T., Powers, J.D., Pultz, J.A (1989), Clinicopathologic findings in dogs with renal amyloidosis: 59 cases (1976-1986). *JAVMA*, 195(3): 358-64.

Juvenile Onset Chronic Kidney Disease (Juvenile Nephropathy)

JUVENILE-ONSET CHRONIC KIDNEY DISEASE

Please note that the diseases and lesions discussed in this chapter might not always result in proteinuria. They are included here to provide a comprehensive overview of canine renal diseases. In our experience, diagnosis of juvenile onset kidney diseases is a common motivation for obtaining a renal biopsy. Some of the diseases listed below have a known pathogenesis (discussed at the beginning of the chapter) whereas others are likely due to disordered nephrogenesis (discussed at the end).

- The terms "Juvenile-onset chronic kidney disease" (JOCKD) and "juvenile nephropathy" (JN) are loosely defined as any non-inflammatory, degenerative, or developmental chronic kidney disease in young animals (approximately 2 years of age or less), although clinical signs might not become apparent until later in life. In many cases, the pathogenesis might not yet be known. They are not necessarily congenital diseases, and JOCKD is often a diagnosis of exclusion. More restrictive definitions apply to diseases observed within families or breeds, and they are termed familial nephropathy and breed nephropathy, respectively. "Hereditary nephropathy" is the term used once the inheritance pattern of a nephropathy has been determined. Our approach in this chapter is to discuss juvenile renal diseases for which the pathogenesis is fairly well-established and/or definitive diagnostic criteria exist. Then we will broach the topic of abnormal kidney development in utero or during the neonatal period.

HEREDITARY GLOMERULAR DISEASES

- These are a group of progressive glomerular diseases. The genetic causes of some, but certainly not all, have been identified.
- Light microscopic features are not pathognomonic, but they are indicative of a primary glomerular disease with secondary involvement of the other renal compartments.
    - Glomeruli can be hypercellular, with segmental to global mesangial expansion.
    - Cystic glomerular atrophy is often prominent.
    - Tubulointerstitial changes are varied and can include: interstitial inflammation, fibrosis, tubular atrophy and dilation with intraluminal collection of proteinaceous material.
    - These secondary lesions (glomerulosclerosis, glomerulocystic atrophy and tubulointerstitial injury) can obscure the primary cause. However, they are important to mention because the marked degree of injury in young dogs might be the initial clue that raises the index of suspicion for a hereditary glomerular injury.

COLLAGENOFIBROTIC GLOMERULOPATHY (Collagen Type III Glomerulopathy)

- Rare glomerulopathy characterized by expansion of mesangium and capillary wall by massive accumulations of type III collagen fibrils, lesser amounts of type V collagen, and fibronectin.

- It affects all glomeruli and, similar to amyloidosis, it can be mild, moderate, or severe according to the dimension and confluence of the deposits and the effacement of tuft architecture.
- With routine histochemical staining, it is somewhat similar to amyloidosis but deposits are not congophilic, and they lack the nodular character typical of amyloid. Because the mesangial expansion is mostly collagen, the material will stain dark grey to black with JMS, whereas amyloid will not take up silver. Electron microscopy reveals large cross-banded fibrils within the widened GBM and mesangium. Positive immunostaining for type III collagen further confirms this diagnosis.
- The typical clinical picture is a young dog (either sex) with marked proteinuria and eventually azotemia. It is a progressive disease, and a cure is not available.

An interactive or media element has been excluded from this version of the text. You can view it online here:
https://ohiostate.pressbooks.pub/vetrenalpathatlas/?p=907

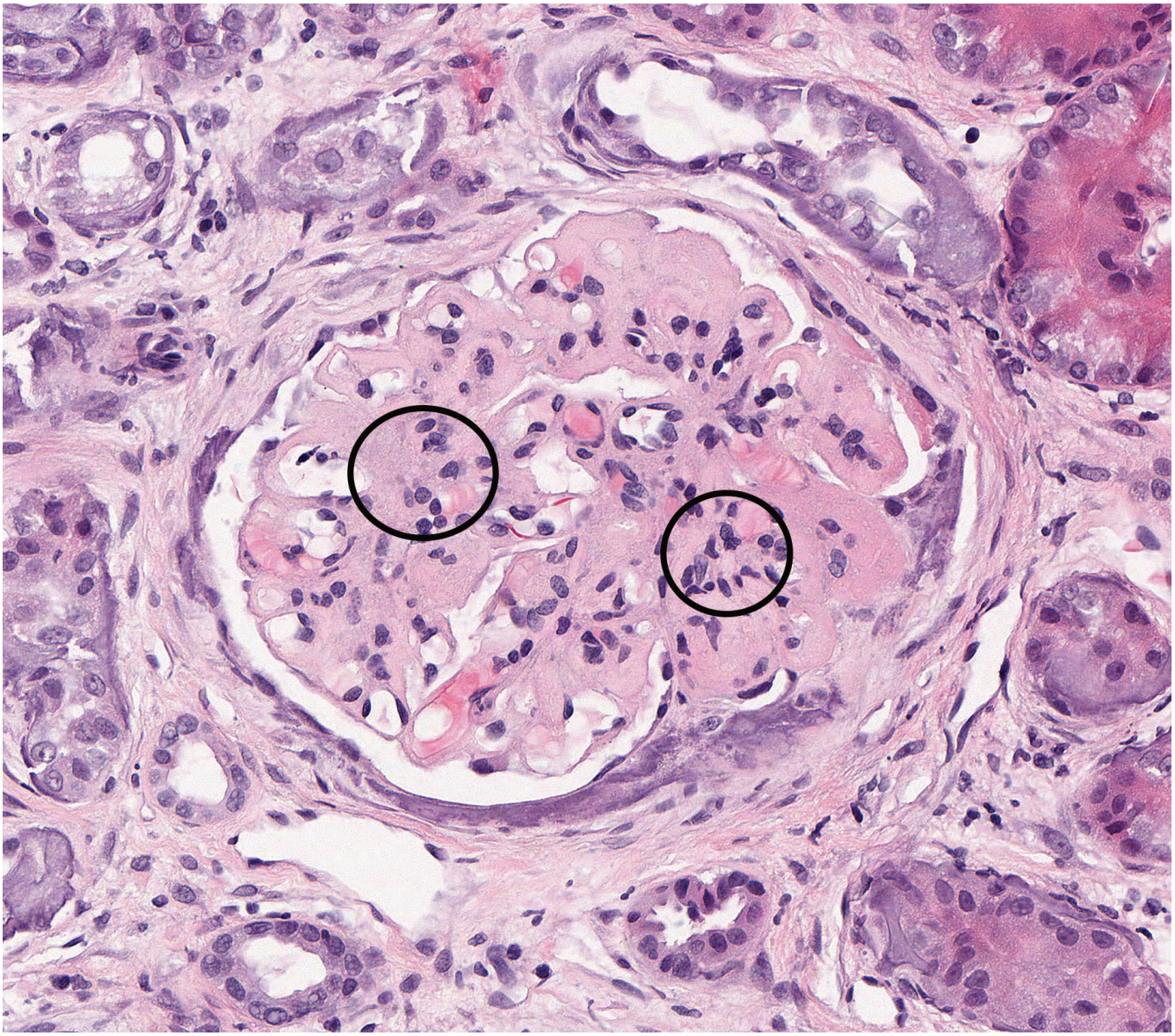

FIG.1A (HE): There is global expansion of the mesangium and capillary loops by eosinophilic material with multifocal collapse of capillary lumina. On HE the material closely resembles amyloid, and other histochemical staining is necessary to differentiate the two diseases. Segmental to diffuse mesangial hypercellularity is observed (circles). Mineralization of the Bowman's capsule and small synechiae are also present in this image.

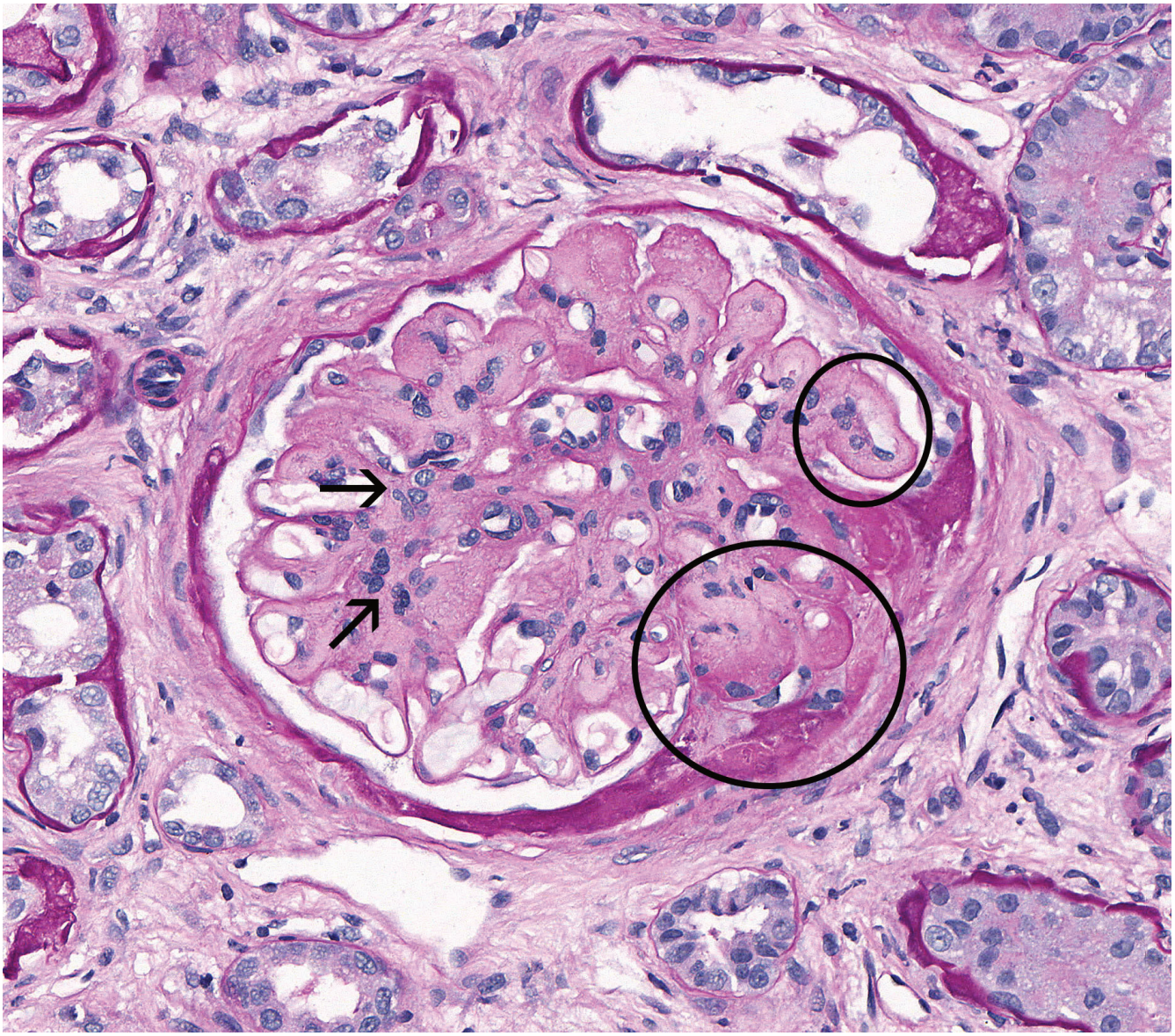

FIG.1B (PAS): The deposited material is weakly positive on PAS. There is expansion of the mesangium and capillary loops with narrowing and partial collapse of capillary lumina (circled). Segmental to diffuse mesangial hypercellularity is observed (arrows).

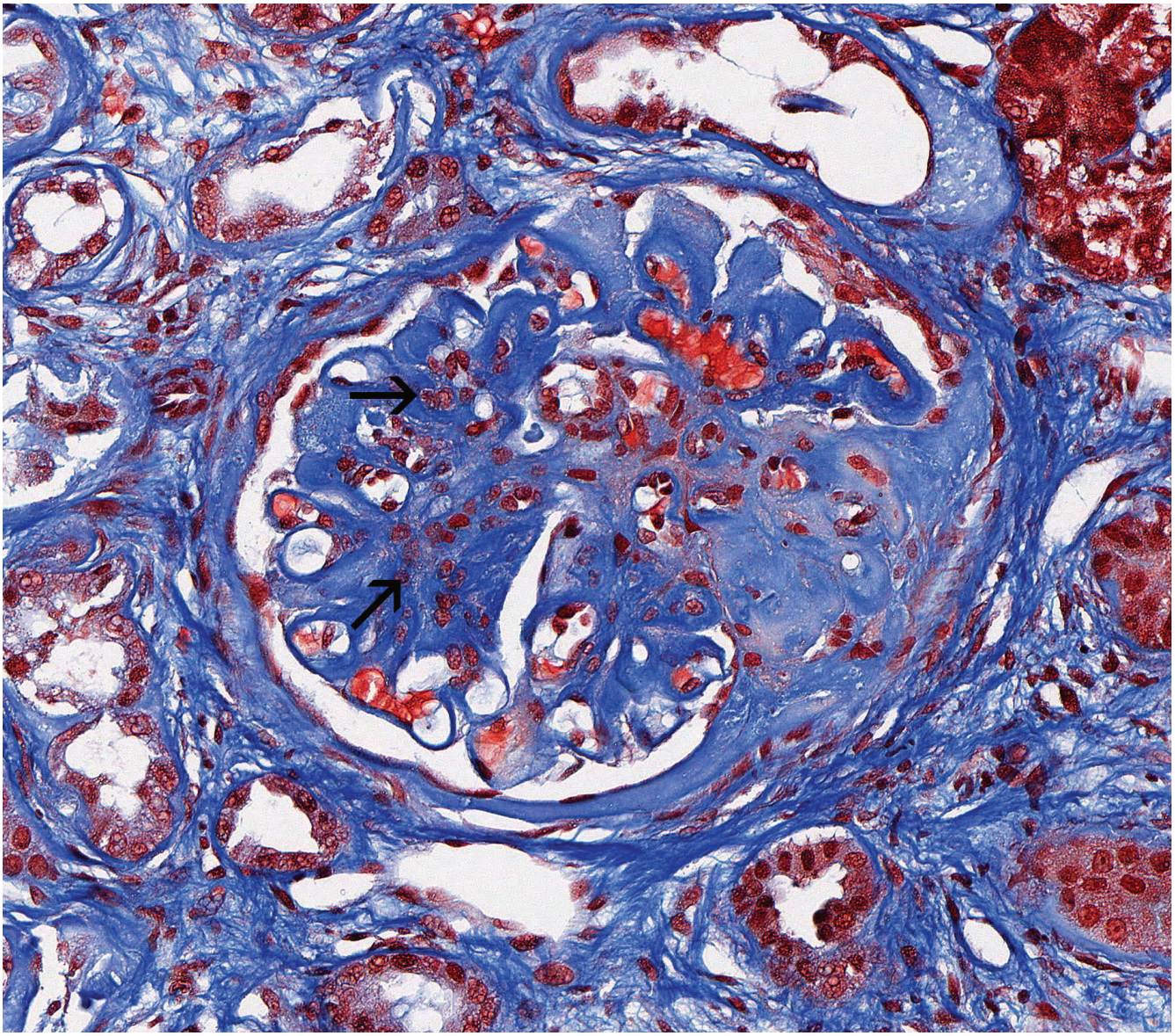

FIG.1C (MT): Non-amyloidotic fibrillary deposits stain deep blue. Segmental to diffuse mesangial hypercellularity is observed (arrow).

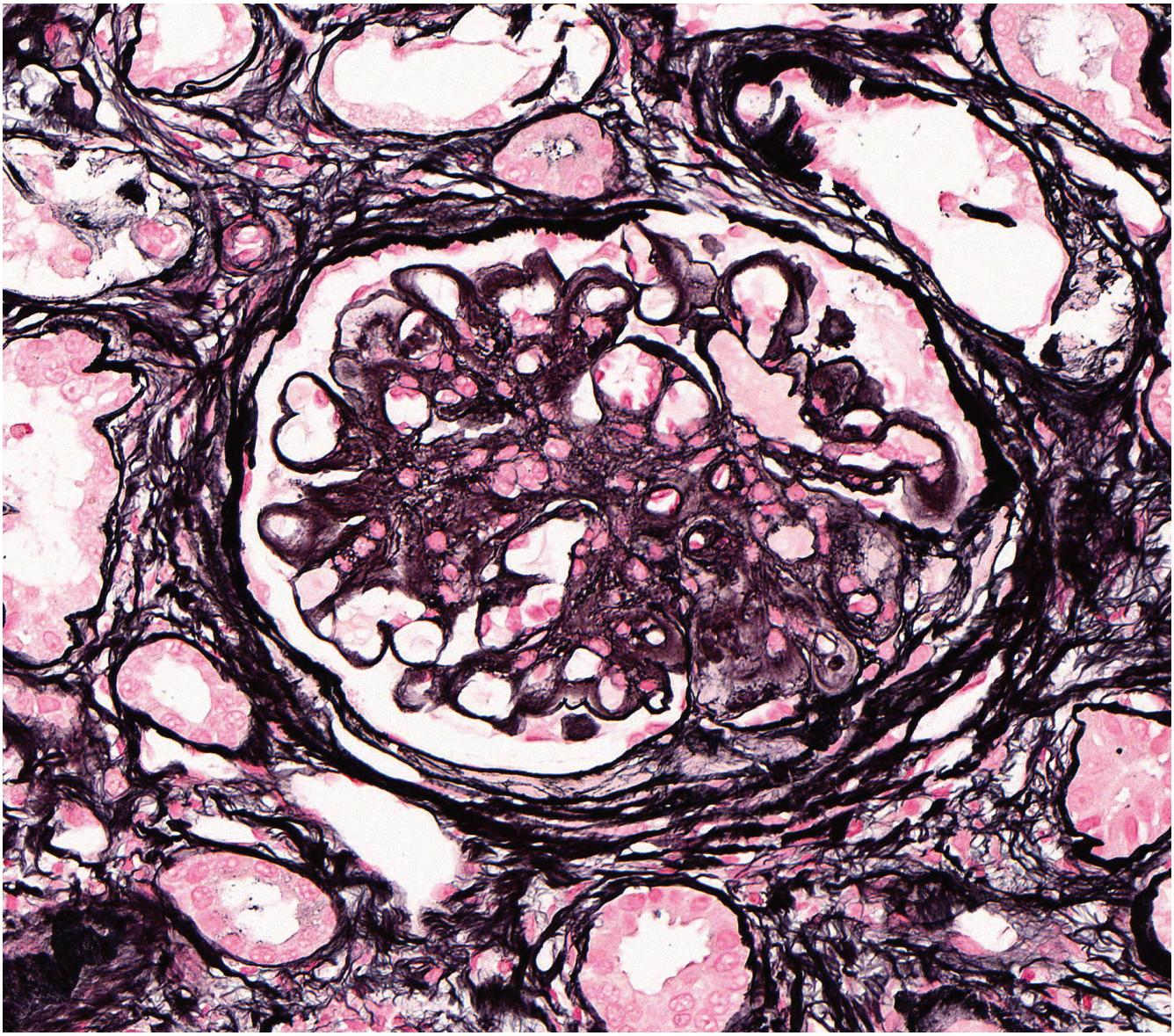

FIG.1D (JMS): Deposits take up silver with the JMS method.

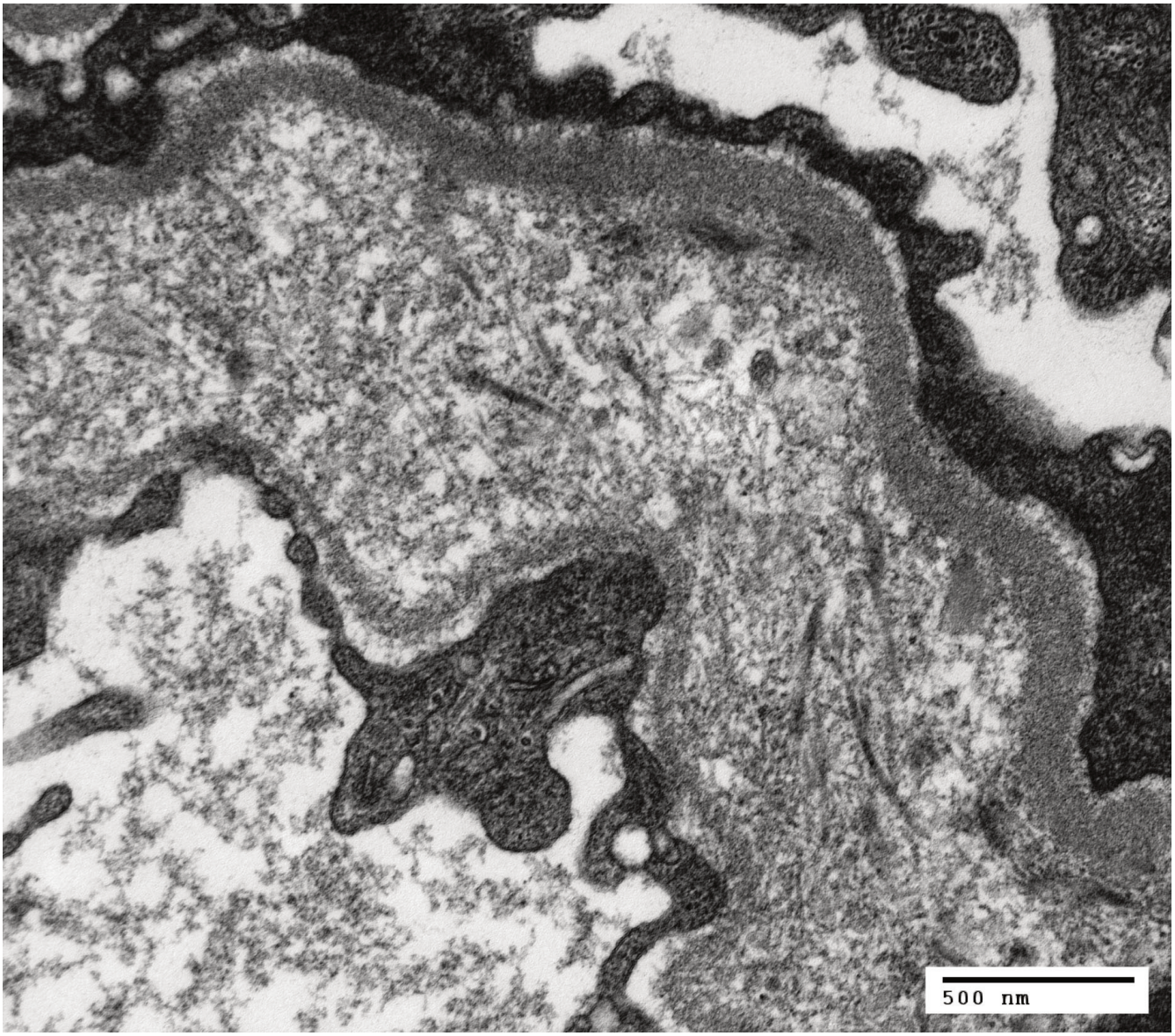

FIG.1E (TEM): The glomerular basement membrane is markedly widened and contains variably sized fibrils and granular material. There is podocyte foot process effacement.

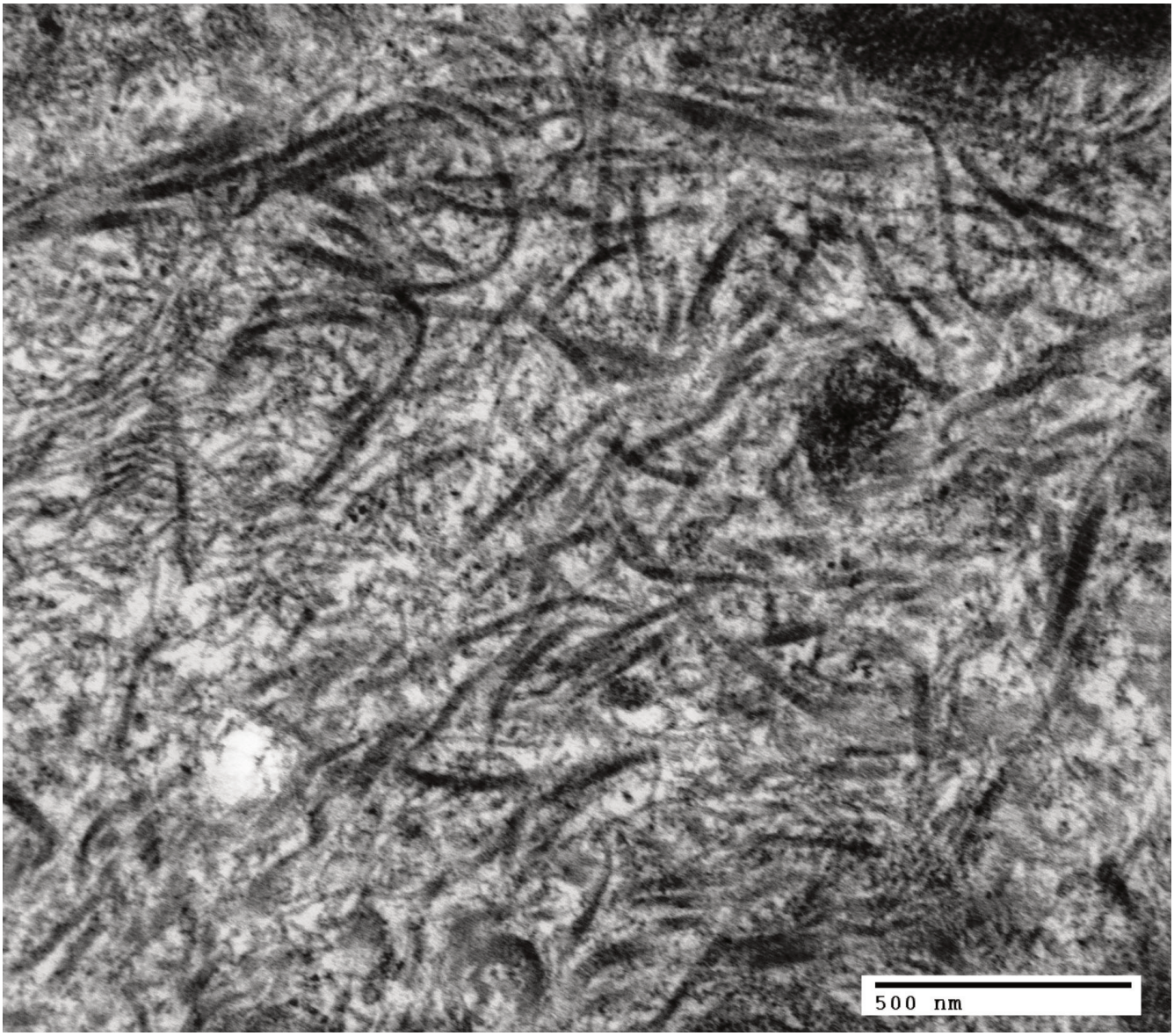

FIG.1F (TEM): The fibrils are often curvilinear and measure 10-33 nm in diameter. Prominent cross striations can be appreciated in larger fibrils.

ALPORT SYNDROME-LIKE NEPHROPATHY

- Alport nephropathy in humans is caused by an inherited defect in type IV collagen, which is a major component of glomerular basement membrane (GBM). Alport syndrome is caused by mutations in genes that encode the proteins for alpha-3 chain (COL4A3), alpha-4 chain (COL4A4), and/or alpha-5 chain (COL4A5) of type IV collagen, resulting in a structurally abnormal GBM and eventual glomerulosclerosis.
- JOCKD due to mutations in type IV collagen genes have been confirmed in few canine breeds (English cocker spaniel, English springer spaniel, Samoyed), as well as in a family of mixed-breed dogs from Navasota, Texas. Two different mutations in COL4A4 are responsible for the disease in English Cocker Spaniels and English springer spaniels, each of which is inherited as an autosomal recessive trait. Two different mutations in COL4A5 are

responsible for the disease in Samoyeds and the Navasota dogs, each of which is inherited as an X-linked trait. These diseases often have been referred to as "Hereditary Nephropathy" (HN), autosomal recessive HN (ARHN), or X-linked HN (XLHN) in published reports.

- Light microscopic features are not specific for this disease. Glomerulosclerosis is common later in the disease, which may be misdiagnosed as MPGN based on light microscopy alone because the glomeruli can be hypercellular and the GBM is irregularly thickened.

Clinical Features

- Alport syndrome-like nephropathy is initially characterized by marked proteinuria prior to 6 months of age (Lees 2013).
- An increase in UPC is typically first observed between 4-6 months of age; if the dog is monitored closely, microalbuminuria can be identified prior to an increase in UPC (as early as 2 months of age in some dogs).
- The UPC typically reaches as high as 10-20. Hypoalbuminemia is commonly observed, but subcutaneous edema and/or ascites is not expected.
- Mild microscopic hematuria may be observed.
- Males with X-linked hereditary nephropathy (XLHN) and both males and females homozygous for autosomal recessive hereditary nephropathy (ARHN) demonstrate a progressive decline in GFR, typically reaching end-stage renal disease by one year of age (range 6-24 months of age). Dogs >2 years of age are unlikely to have XLHN or homozygous ARHN (Lees 1999) .
- Clinical signs are generally absent until moderate azotemia is present, after which a rapid clinical decline (usually within 1-2 months) is often observed.
- Hypertension is not a common feature of the disease.
- Carrier females with XLHN typically develop proteinuria by 6 months of age, but their proteinuria is less severe (UPC usually <5), and they demonstrate a more slowly progressive disease. The majority of carrier females have a normal lifespan, often succumbing to a non-renal disease.
- XLHN and ARHN have been identified in English Cocker Spaniels, English Springer Spaniels, Samoyeds, and mixed breed dogs. Of these, it has been identified as a breed-wide problem only in English Cocker Spaniels, and a genetic test has largely eliminated the disease in that breed (Lees 1998; Jansen 1987)
- A similar GBM lesion has been identified in Bull Terriers and Dalmatians (largely in Australia), but mutations in Type IV collagen have not been found. Similarly, reports of Doberman Pinschers, Beagles, and Rottweilers with the GBM lesion typical for HN are available in the literature (Hood 1995).

An interactive or media element has been excluded from this version of the text. You can view it online here:
https://ohiostate.pressbooks.pub/vetrenalpathatlas/?p=907

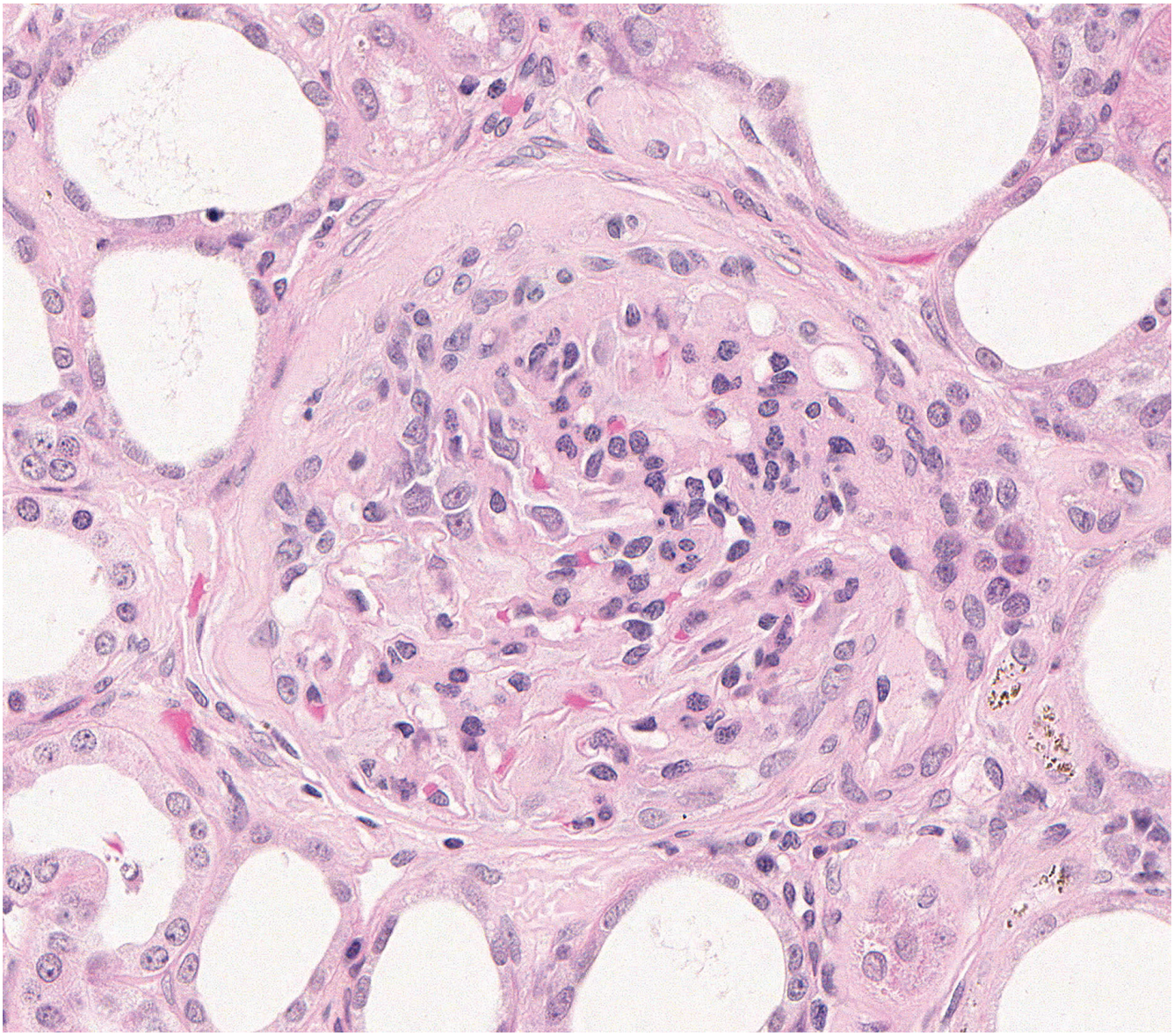

FIG.2A (HE): There is moderate to marked mesangial cell hypercellularity. A large portion of the capillary tuft is adhered to the thickened Bowman's capsule. The surrounding interstitium is fibrotic.

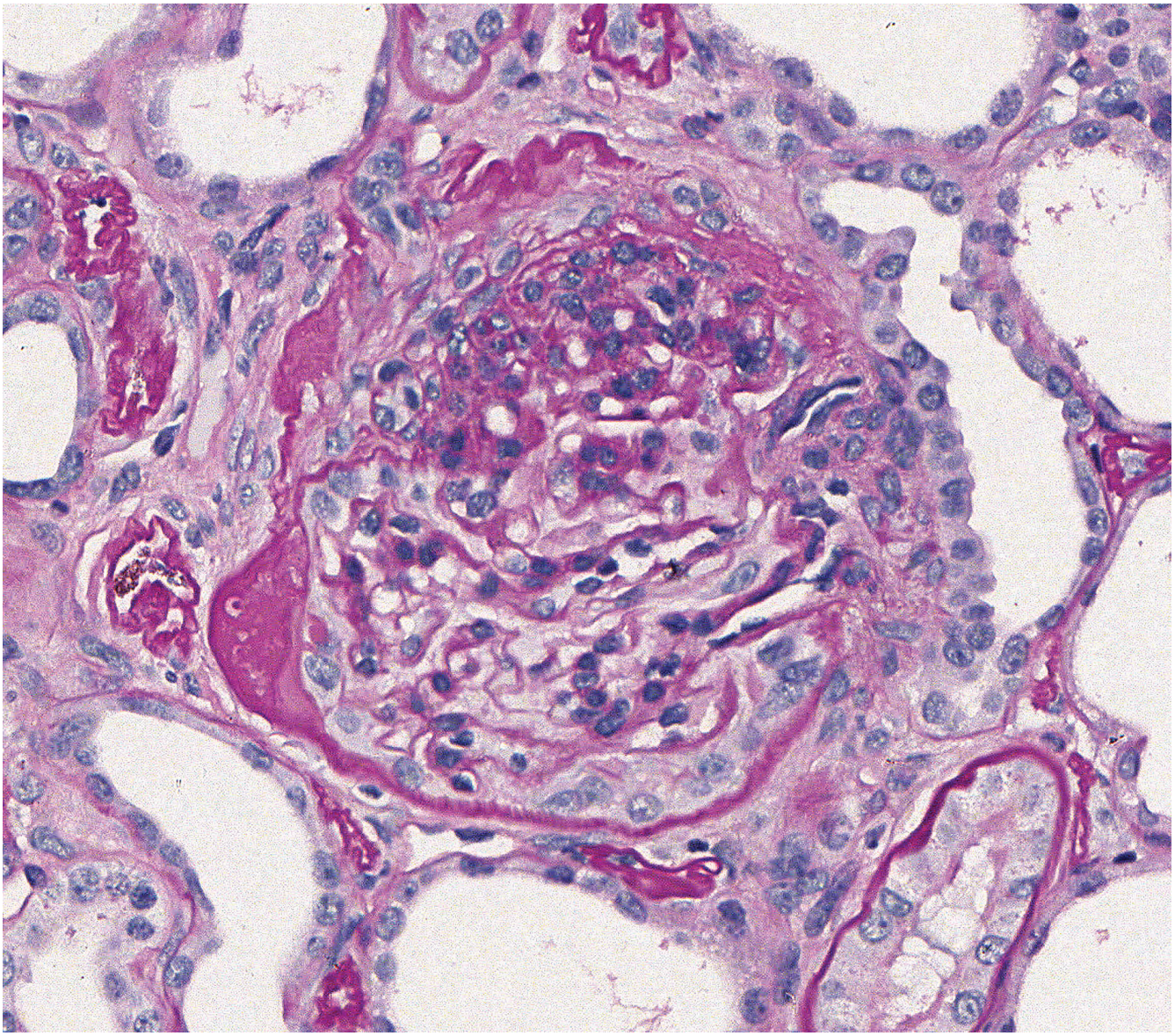

FIG.2B (PAS): There is segmental sclerosis of the capillary tuft, with adhesion of this portion to Bowman's capsule (synechia). Note thickening, wrinkling, and cellular proliferation in area of synechia. There is podocyte hypertrophy and parietal epithelial cell hyperplasia.

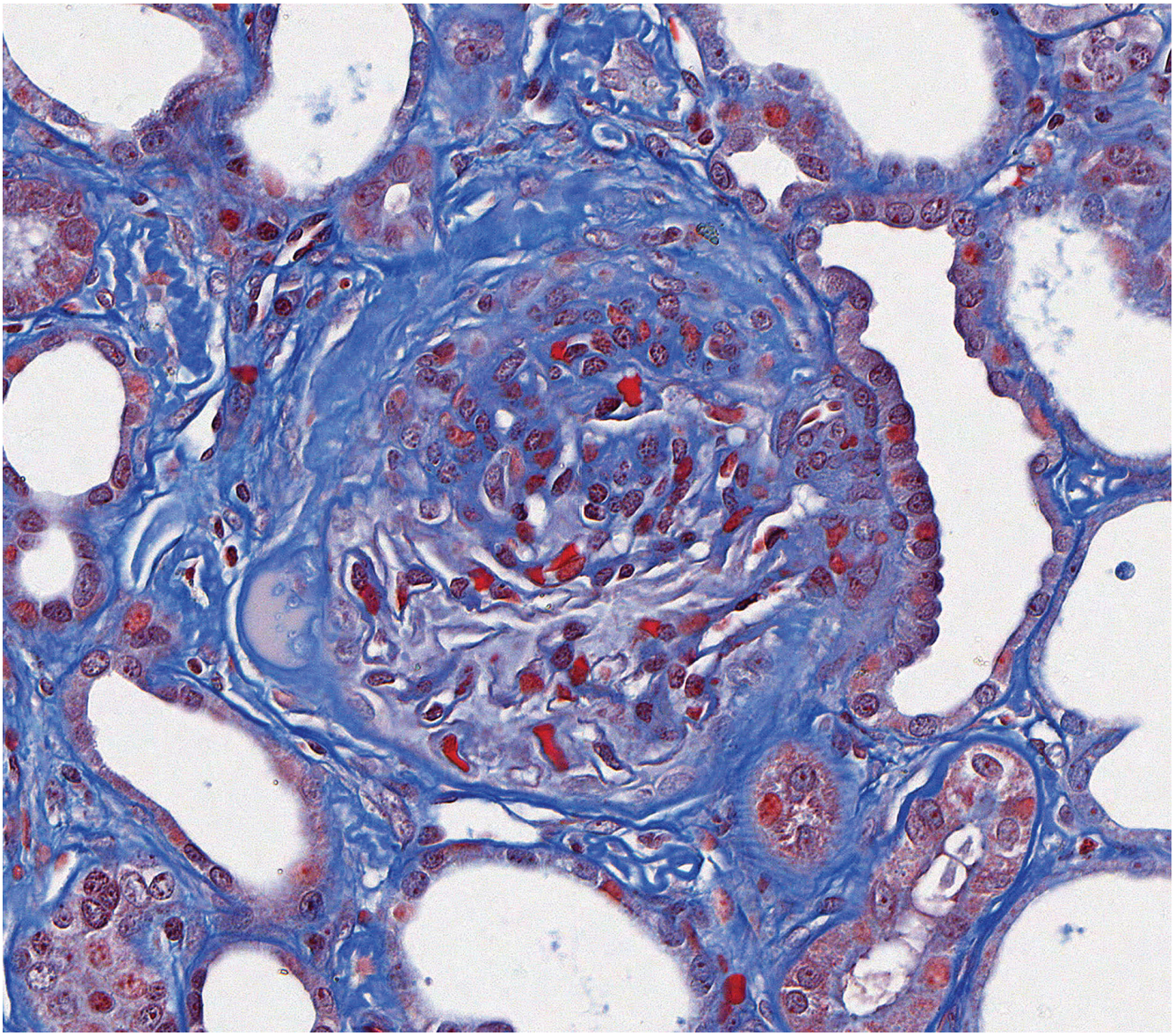

FIG.2C (MT): Segmental sclerosis with an extensive adhesion, wrinkling, and thickening of Bowman's capsule, and fibrosis and mild inflammation in the adjacent interstitium.

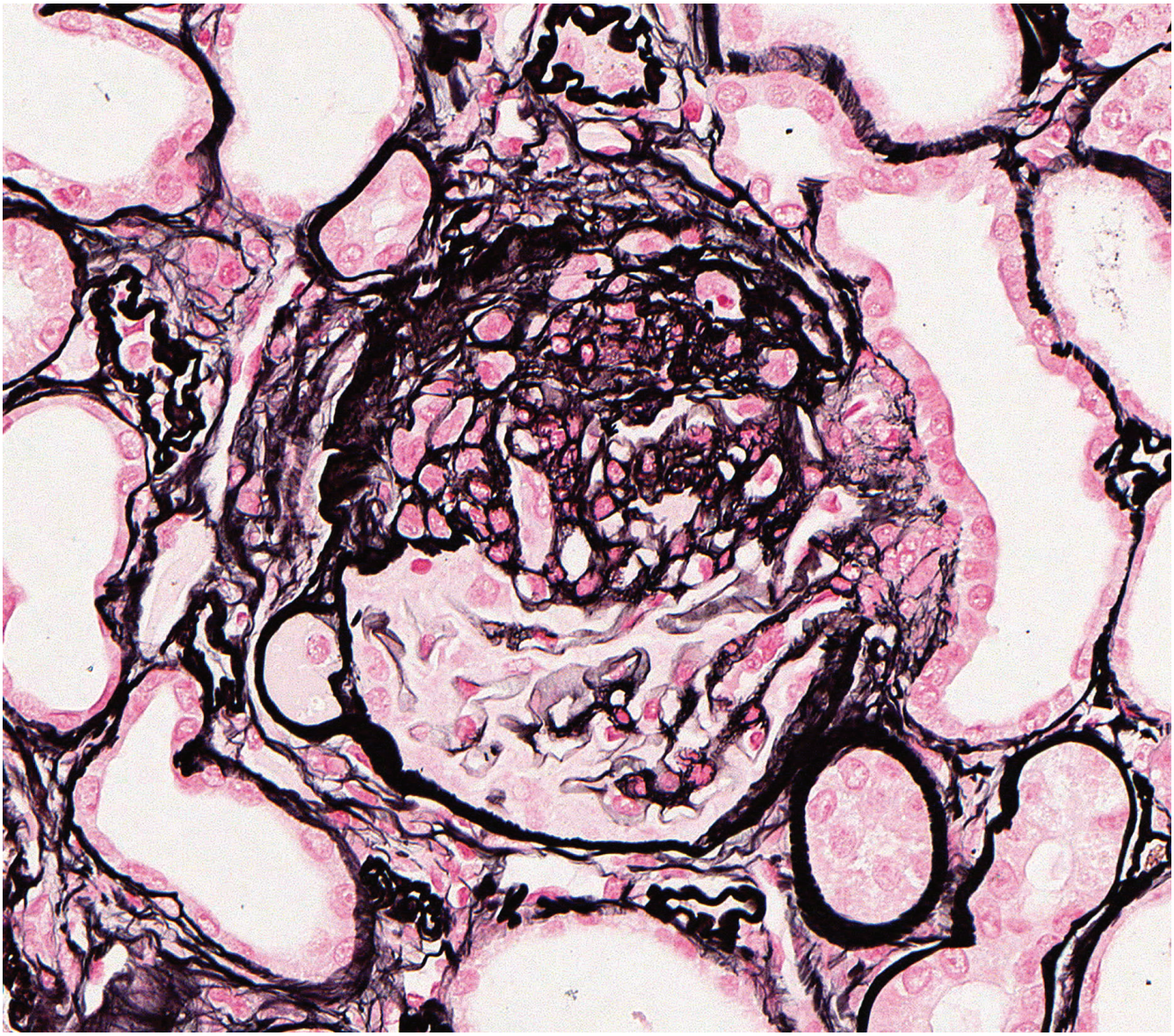

FIG.2D (JMS): Segmental sclerosis with an extensive adhesion, wrinkling, and thickening of Bowman's capsule, and fibrosis and mild inflammation in the adjacent interstitium.

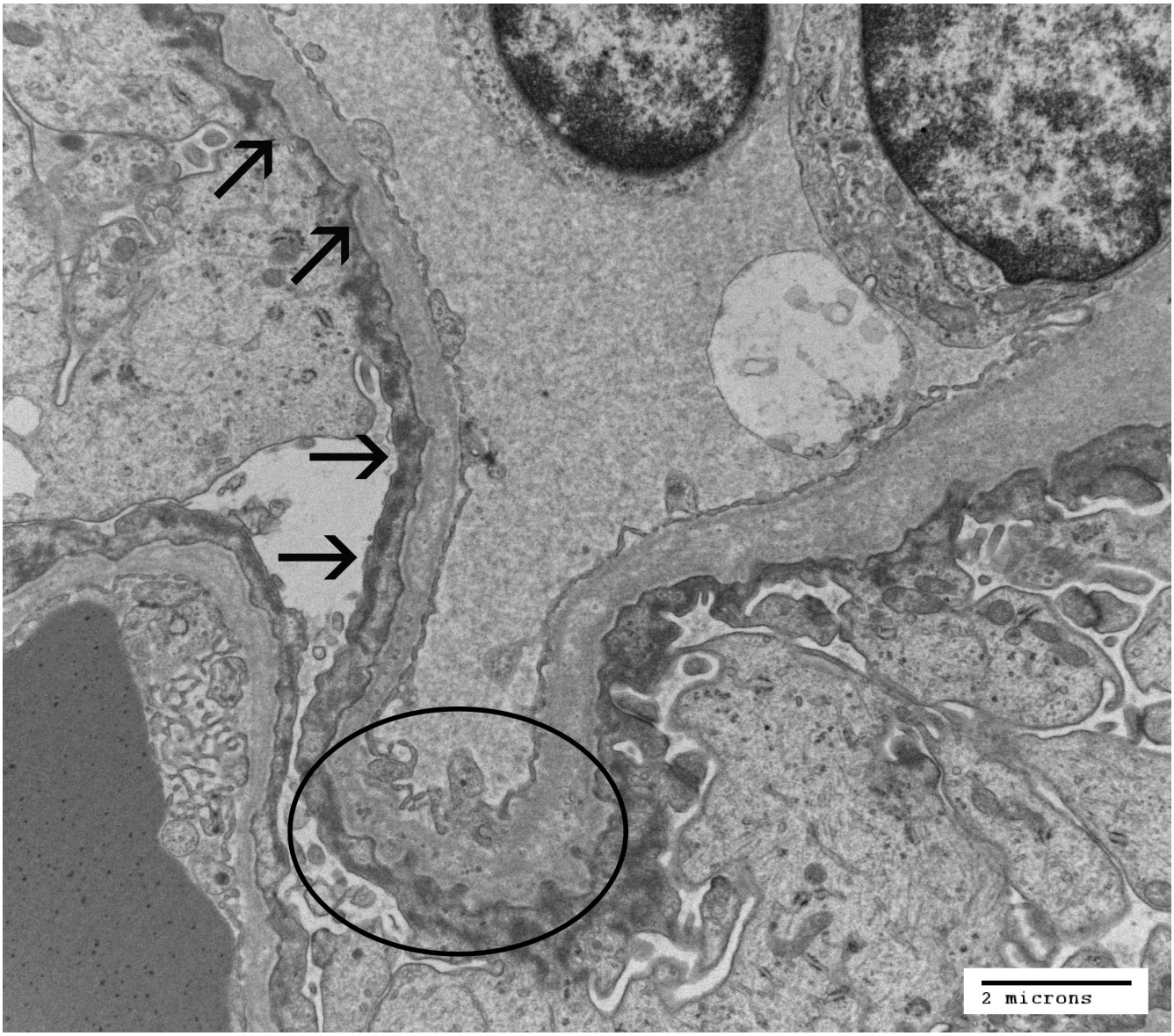

FIG.2E (TEM): Electron microscopy demonstrates the characteristic ultrastructural lesion of irregular GBM thickening and splitting. Other nonspecific changes include diffuse severe foot process effacement, reorganization of intracellular actin filaments (arrows), and irregularity of the abluminal GBM (circled).

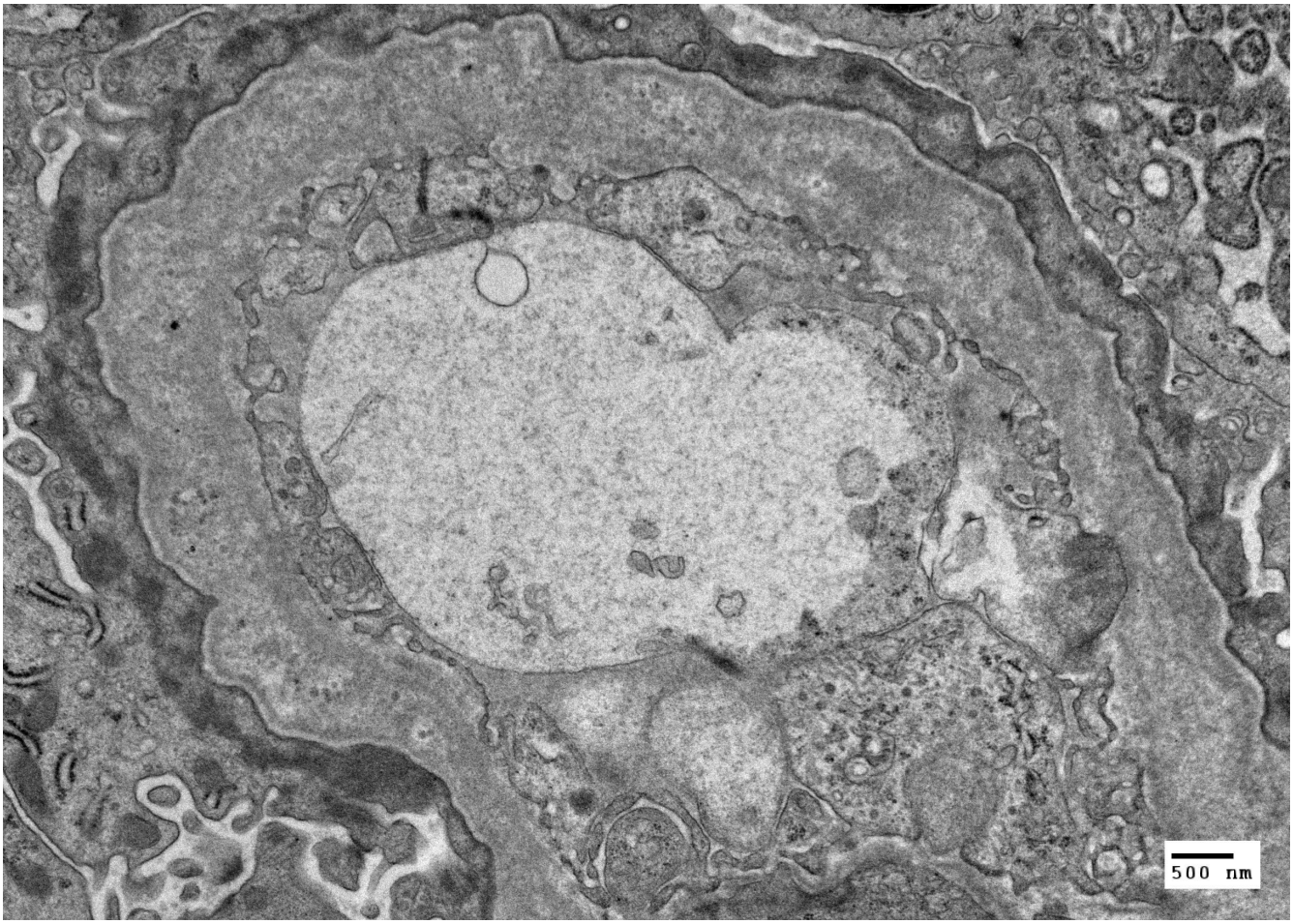

FIG.2F (TEM): The distinctive splitting, multilamination, and fragmentation of the lamina densa of the GBM is evident.

JUVENILE ONSET CHRONIC KIDNEY DISEASE DUE TO RENAL MALDEVELOPMENT

A short note on renal embryology is provided to illustrate the complex development of the kidney and to provide insight into patterns of malformation in the different compartments of the kidney. The mammalian kidney derives from the intermediate mesoderm of the urogenital ridge, a structure found along the posterior wall of the abdomen in the developing fetus. It develops in three successive stages known as the pronephros, the mesonephros, and the metanephros. In mammals, although the pronephros and mesonephros are required for renal development, they are transient structures which regress, allowing the metanephros or "metanephric kidney" to differentiate into the adult kidney. The completion of nephrogenesis in the dog can take up to two weeks post-natally (Eisenbrandt, 1979).

Nephrogenesis results from a series of inductive interactions between the metanephric mesenchyme (blastema) and the epithelial ureteric bud. Diagrams of the stages of nephron development are depicted below and an animation of the stages is also available. In the animation, the scrollbar below the image enables one to visualize the interaction between the ureteric bud at the metanephric mesenchyme.

1. The epithelial-lined **ureteric bud,** an outgrowth of the distal end of the mesonephric duct, invades into the surrounding mesenchyme, and undergoes reiterative cycles of elongation, bifurcation, and differentiation to eventually form

the **collecting ducts**, **renal pelvis**, and **ureter** by a process referred to as branching morphogenesis.

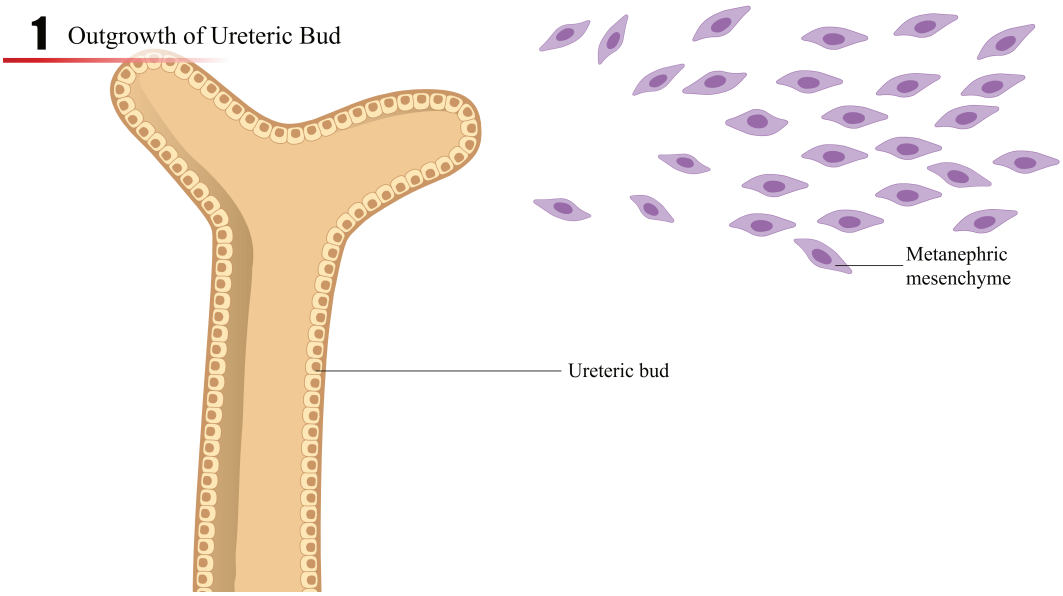

2. The **metanephric mesenchyme,** by reciprocal induction with the ureteric bud, condenses, forms cellular aggregates, and undergoes mesenchymal – to – epithelial transition to become the **renal vesicle**.

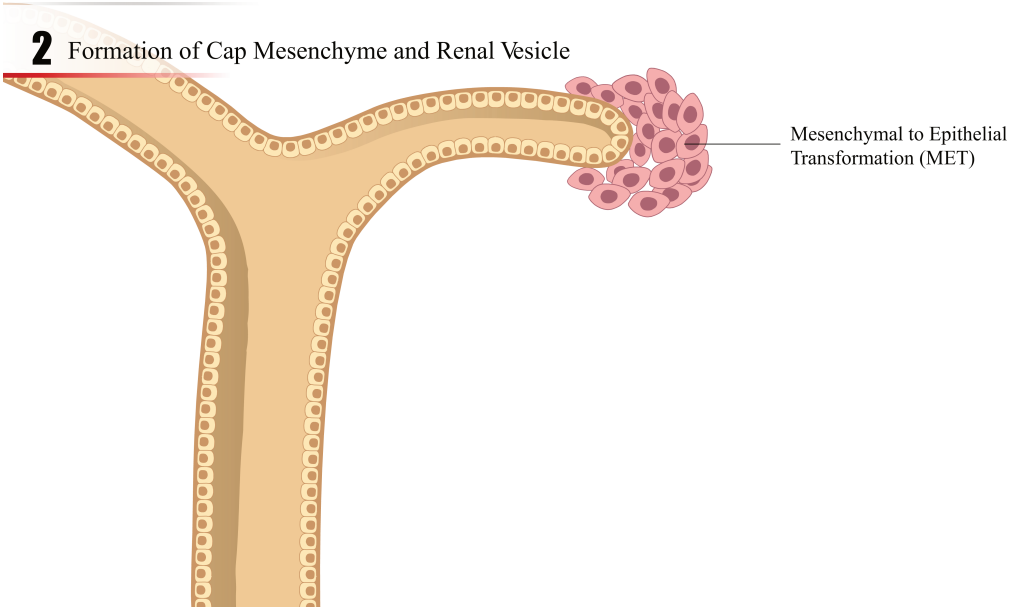

3. The **renal vesicle** elongates and continues development through the comma-shaped body, S-shaped body, capillary loop and matures into the precursor of the **nephron** (**tubules and glomerulus**).

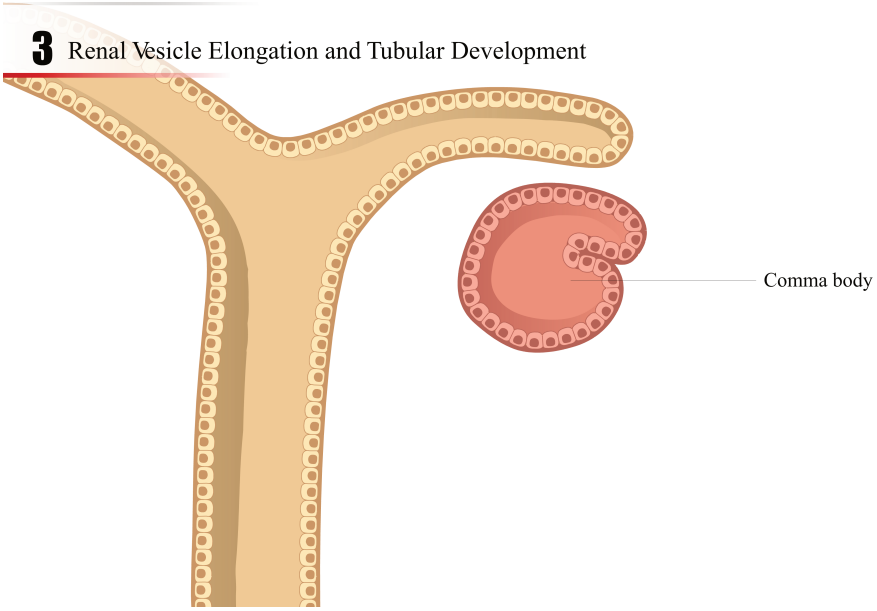

4. Podocyte progenitor cells, first identified in the S-shaped body stage, attract the ingrowth of endothelial cells. Capillary branching and mesangial cell recruitment and differentiation proceed until glomerular tuft formation is complete (**glomerulogenesis**).

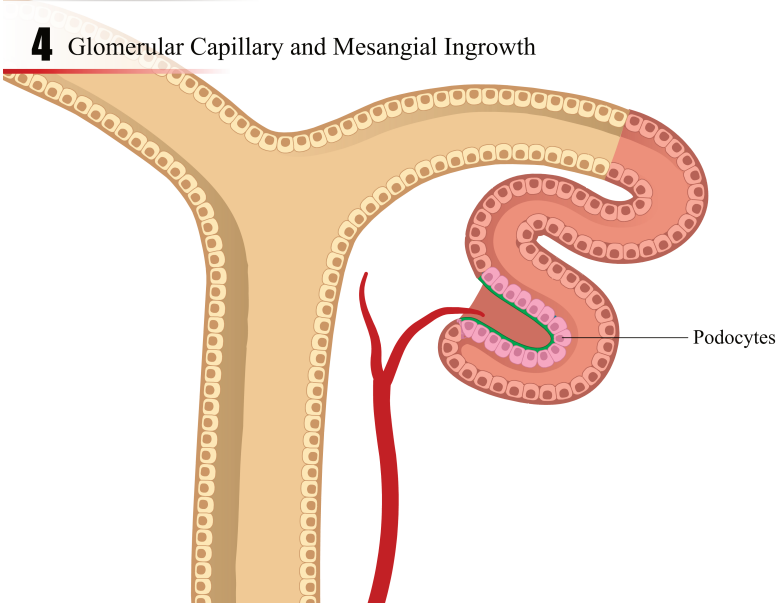

5. The tubular portion of the nephron elongates while the glomerular capillary bed arborizes to form the final structure.

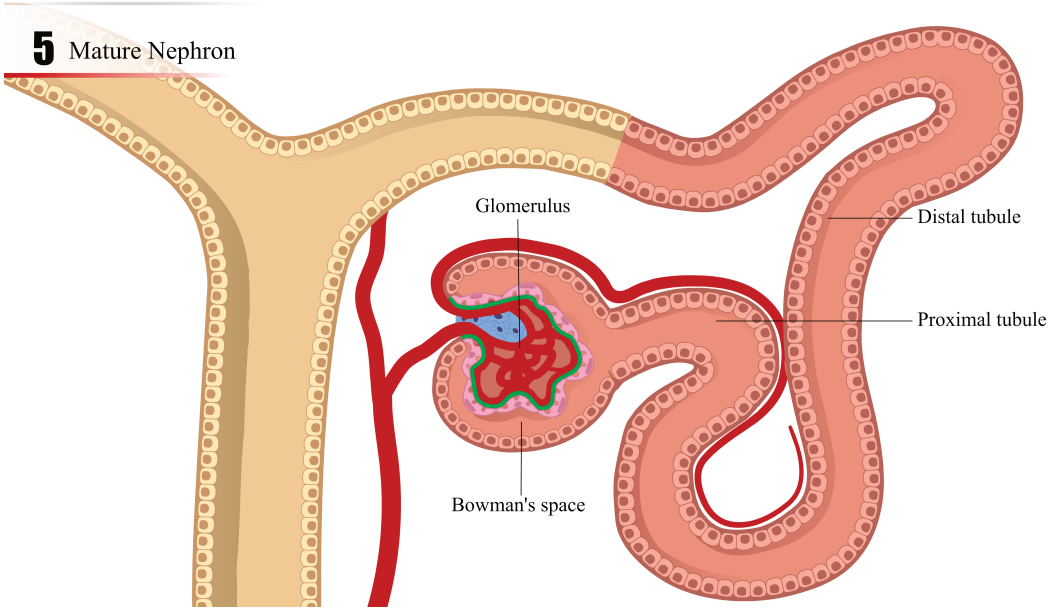

In some species, including dogs, nephronogenesis and development continue during the post-natal period, reportedly up to 2 weeks after birth. The neonatal kidney from a 5 day old dog (Figure 3) has a prominent subcapsular zone of ongoing glomerular tuft development and tubular elongation.

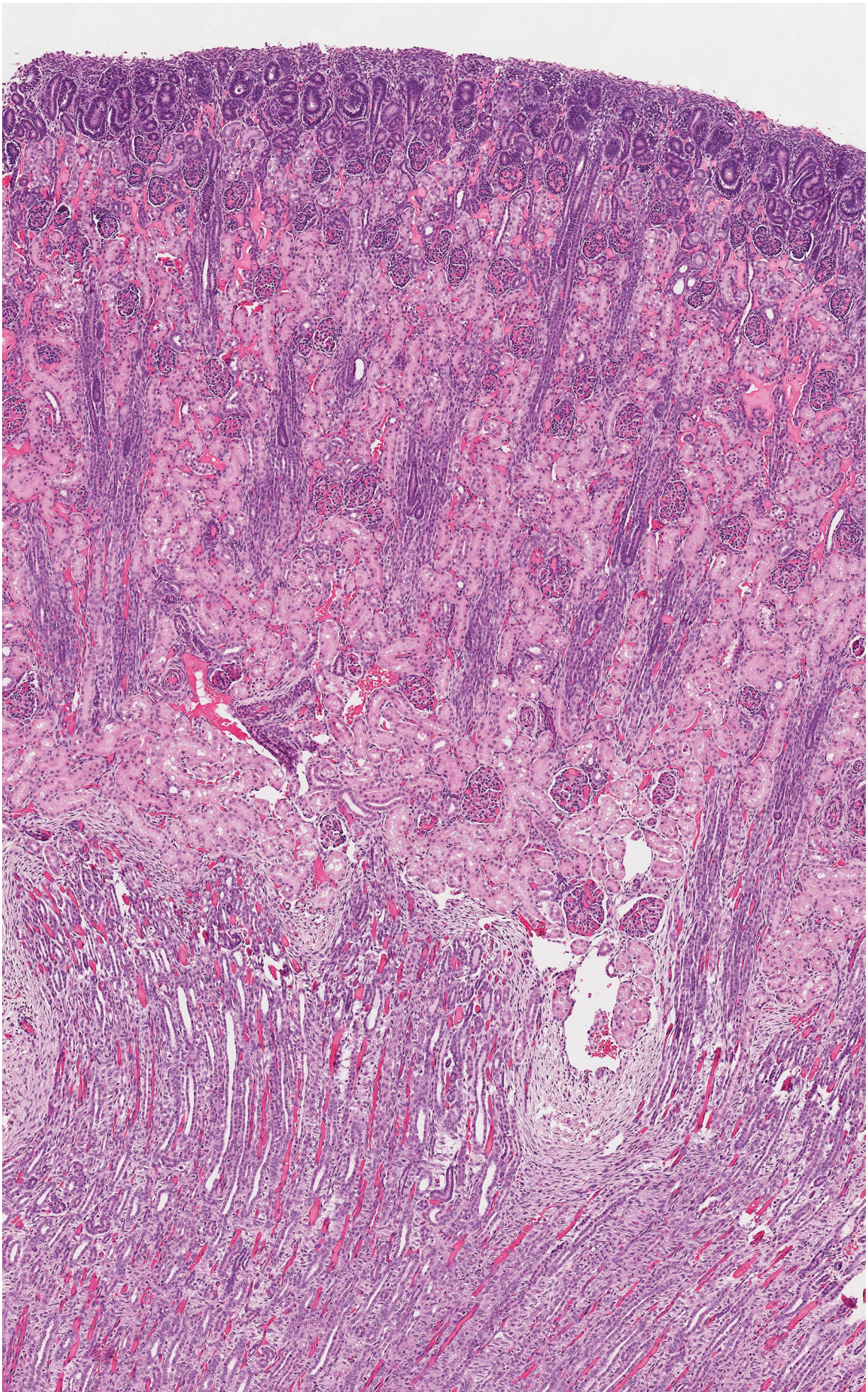

FIG.3A (HE): Beneath the renal capsule there is a blueish zone due to the crowded nuclei and small amounts of cytoplasm.

An interactive or media element has been excluded from this version of the text. You can view it online here:
https://ohiostate.pressbooks.pub/vetrenalpathatlas/?p=907

FIG.3B (HE): Higher magnification of Fig.3A. The subcapsular cortex contains metanephric mesenchyme and vesicles, with glomerulogenesis and nephron maturation progressing towards the outer subcapsular cortex. Note the S-shaped body (rectangle) with developing podocytes. The immature glomerulus has capillaries, although the podocytes are still arranged in a prominent row around the periphery of the tuft (arrows).

- Importantly, disrupted, disorganized and inadequate interactions between the metanephric mesenchyme, ureteric bud and stroma may result in renal maldevelopment.
- Renal hypoplasia is when the kidneys are smaller than expected but all of the components are mature and the architecture is normal.
- Renal maldevelopment is a type of JOCKD but they are not synonomous. Renal maldevelopment refers to disorganized development of renal parenchyma either in utero or during the neonatal period. Of note, the term “renal dysplasia” is deeply embedded in the veterinary lexicon; however, when used as a clinical diagnosis, renal dysplasia can be misconstrued by clinicians and animal owners as if it designated a single, specific disease entity. In our opinion, renal dysplasia should be viewed as a broad descriptive term for a general category of somewhat diverse disorders that are characterized by mostly developmental anomalies and/or lesions. We prefer to use “renal maldevelopment” as the diagnostic term for this category of disorders (ie, rather than renal dysplasia), because we believe that properly defining a new term will be more effective than attempting to re-define an old, sometimes misused, term.
- Renal maldevelopment is characterized at the light microscopic level by the presence of structures in the kidney that are inappropriate for the stage of development of the animal. The most frequent finding in renal maldevelopment are fetal / immature glomeruli and tubules located within radiating segments extending from the subcapsular surface to the corticomedullary junction (indicating asynchronous differentiation of nephrons). There also might be regions with a paucity of tubules and glomeruli; these foci instead contain non-inflamed connective tissue and often tortuous arterial profiles. Additional less common lesions of renal maldevelopment that are reported in dogs include: persistent mesenchyme, persistent metanephric ducts, atypical tubular epithelium, and dysontogenic metaplasia (presence of bone or cartilage in the renal parenchyma). Unfortunately, other than dysonotogenic metaplasia (which is a lesion that we have not personally observed within our own case material), there is not a consensus among pathologists regarding succinct definitions for these uncommon lesions. In fact, some lesions might even be acquired as opposed to be congenital. Specifically, in our experience, we have seen metanephric ducts

and atypical tubular epithelium in adult dogs with varying underlying renal diseases (e.g. nephrolithiasis). Furthermore, the lesions listed above should not be considered pathognomonic for renal maldevelopment. For example, scattered fetal glomeruli are present in many adult small breed dogs and indicate arrested nephron development. Given the reserve capacity of the kidney, a few scattered immature nephrons are rarely clinically significant, and they can be identified in geriatric dogs with normal renal function. Therefore, diagnosis of renal maldevelopment is often a matter of degree, extent of the lesion, and the timepoint at which nephron development went awry.

- Secondary lesions in juvenile nephropathies include compensatory hypertrophy and hyperplasia of glomerular tufts and tubules, interstitial fibrosis, tubulointerstitial inflammation, pyelonephritis, dystrophic mineralization, cystic glomerular atrophy, microcystic tubules, retention cyst, and glomerular lipidosis.

An interactive or media element has been excluded from this version of the text. You can view it online here:
https://ohiostate.pressbooks.pub/vetrenalpathatlas/?p=907

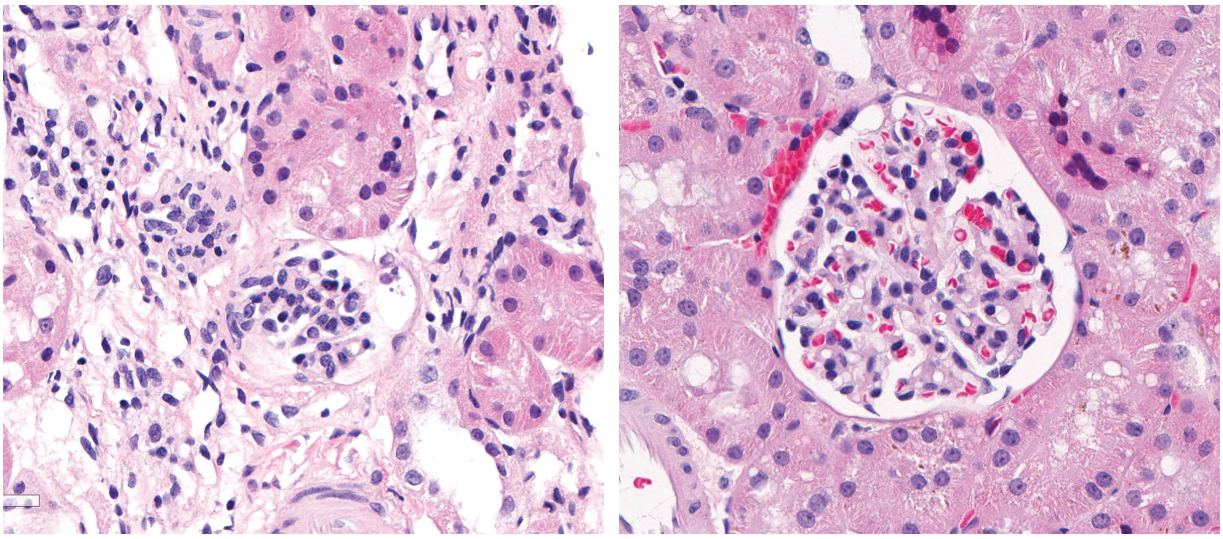

FIG.4A (HE): These 2 photomicrographs depict glomeruli from the same biopsy core taken at the same magnification. The left panel shows 2 fetal glomeruli which are small and poorly capillarized. The glomerulus in the center of the image has a mildly dilated Bowman's capsule. The right panel shows a normal glomerulus.

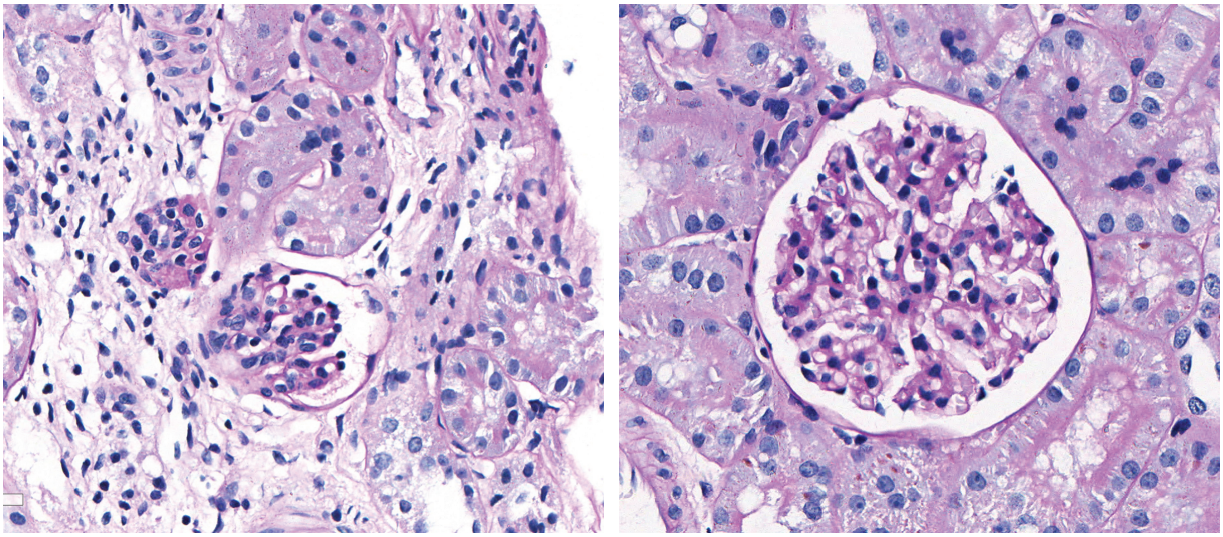

FIG.4B (PAS): Same glomeruli as depicted in above HE photomicrographs. It is easier to see the smaller fetal glomerulus in this stain because the PAS highlights the poorly expanded capillary network.

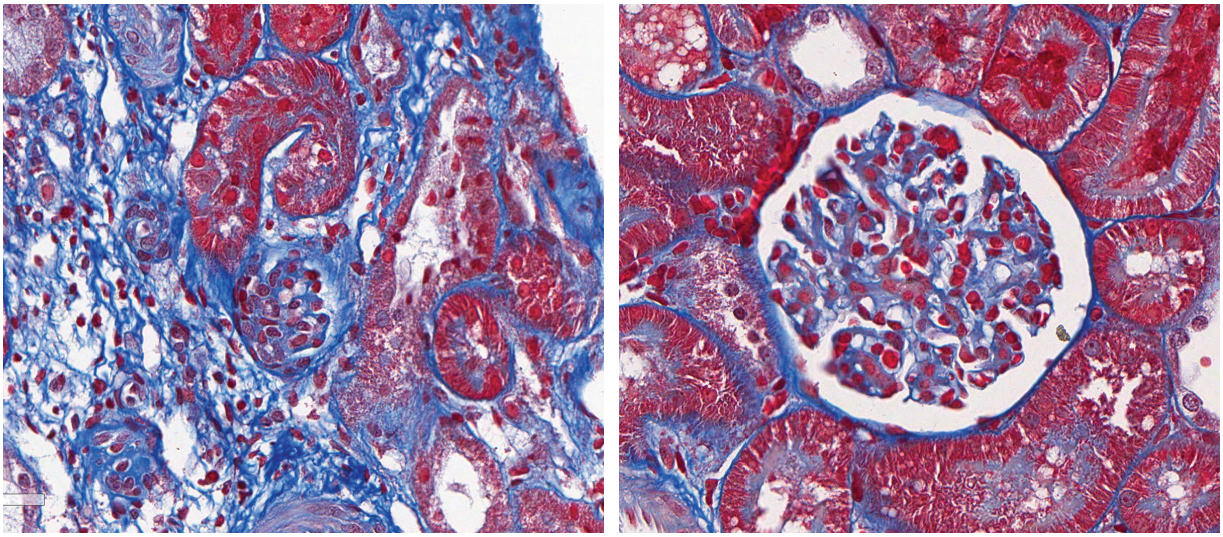

FIG.4C (MT): Same glomeruli as above. Because fetal glomeruli are small, one is not present in this section. This stain highlights the mildly inflamed interstitial fibrosis in this region with the fetal glomeruli, which is a common feature of maldevelopment.

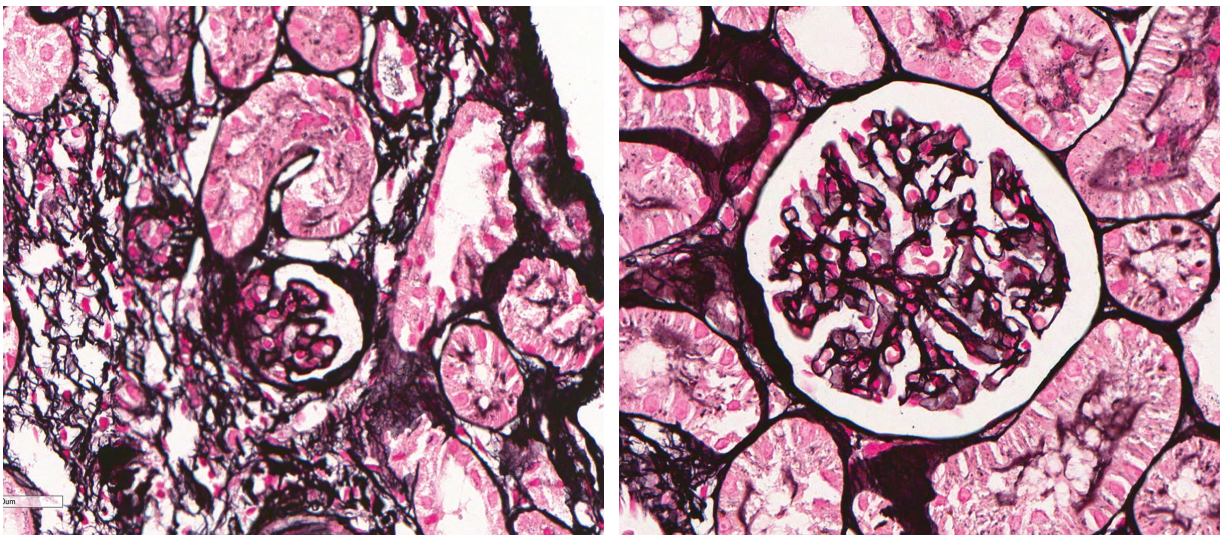

FIG.4D (JMS): Same glomeruli as above, again with only one fetal glomerulus in the left panel.

In addition to fetal glomeruli, dogs with renal madelevelopment might have large regions of dense collagen with minimal to mild inflammation and a paucity of tubular profiles.

An interactive or media element has been excluded from this version of the text. You can view it online here:
https://ohiostate.pressbooks.pub/vetrenalpathatlas/?p=907

An interactive or media element has been excluded from this version of the text. You can view it online here:
https://ohiostate.pressbooks.pub/vetrenalpathatlas/?p=907

FIG.5A (HE): Large region of dense collagen with numerous small, fetal or immature glomeruli (arrows). There is minimal inflammation, suggesting that the collagen is not secondary to previous inflammation or infection.

An interactive or media element has been excluded from this version of the text. You can view it online here:
https://ohiostate.pressbooks.pub/vetrenalpathatlas/?p=907

FIG.5B (PAS): The PAS stain is useful to highlight the numerous fetal or immature glomeruli (arrows). In the HE stain, they can often blend in with the background collagenous matrix.

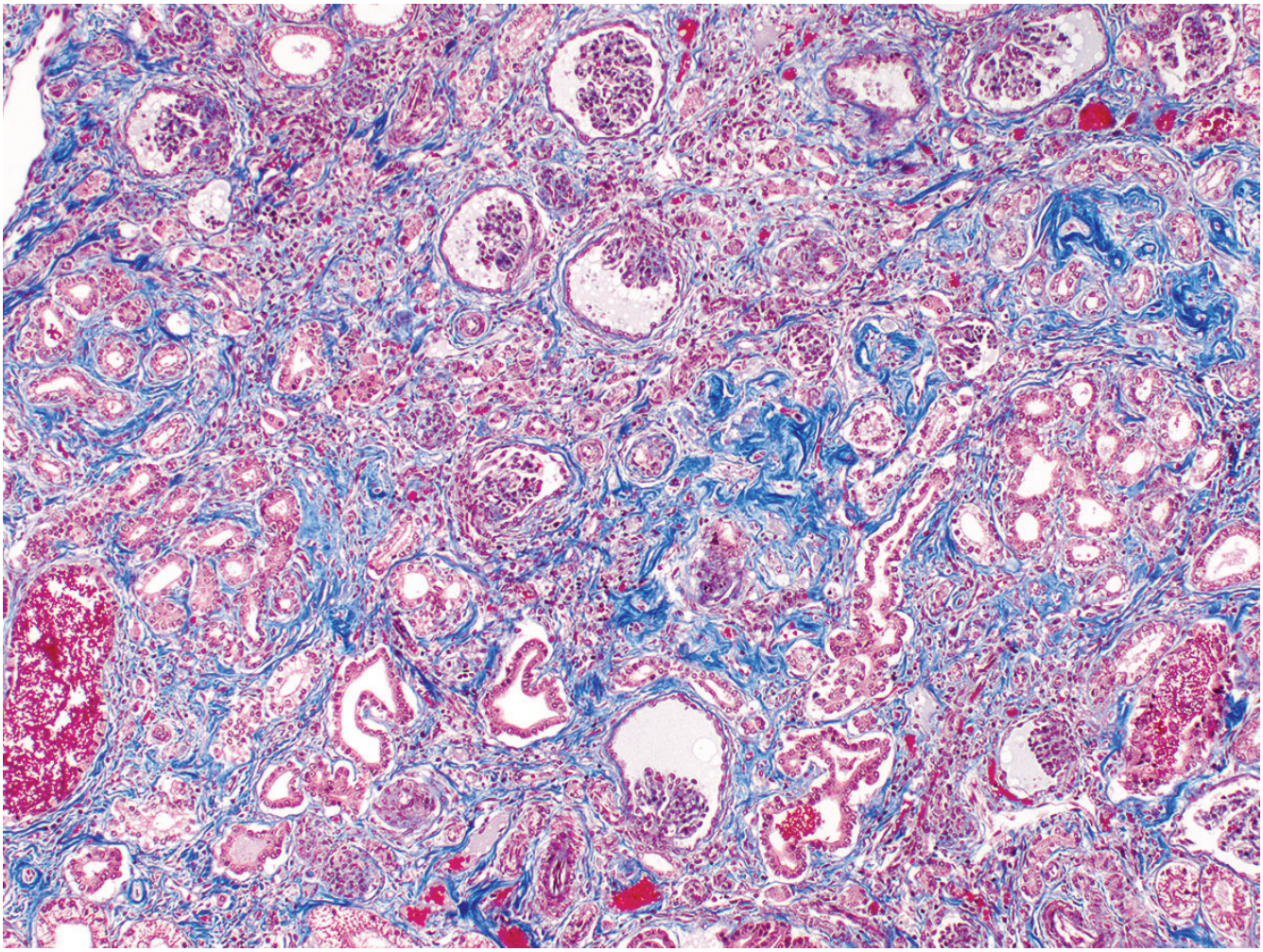

FIG.5C (TRI): The dense interstitial collagen stains dark blue.

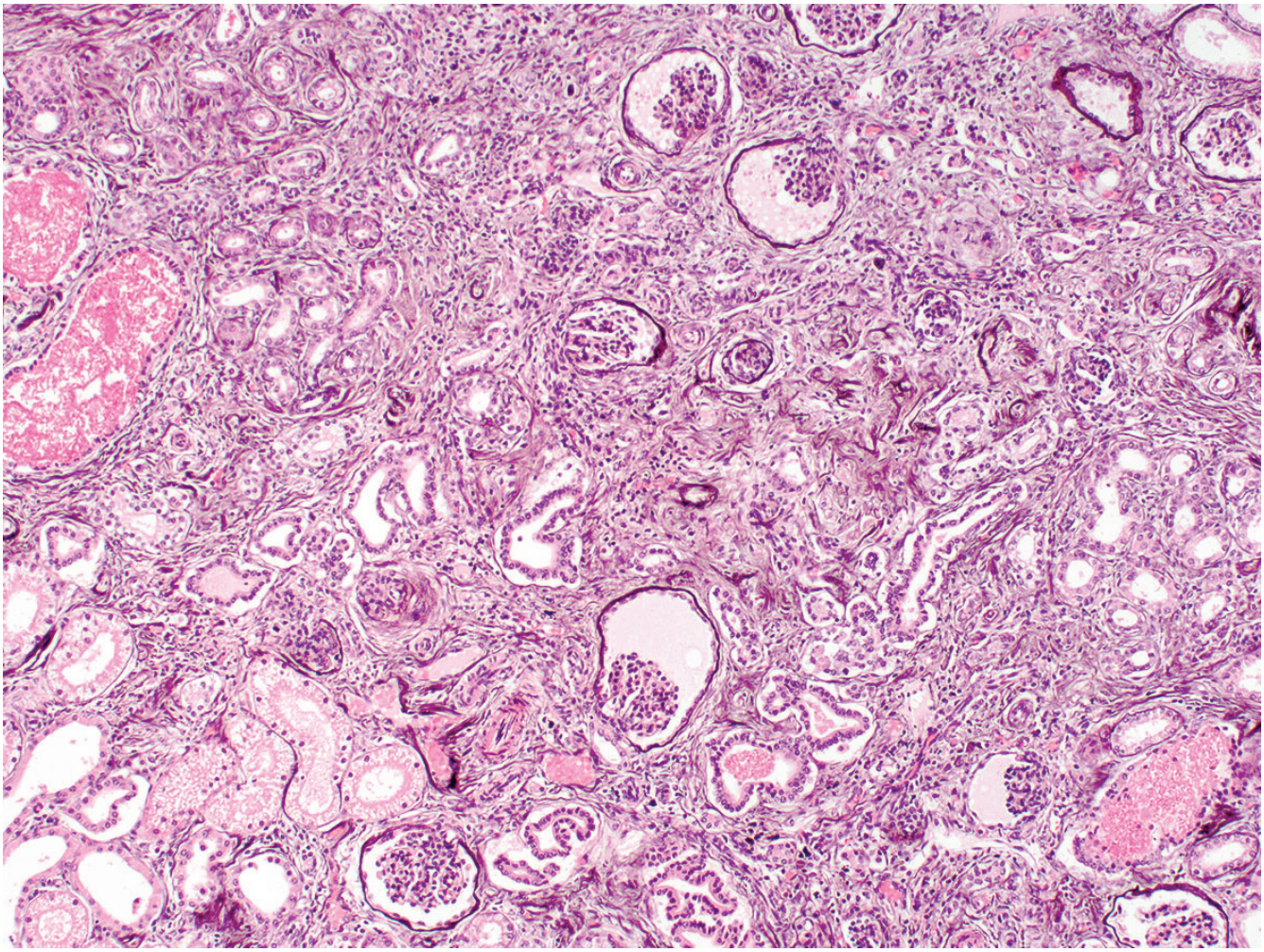

FIG.5D (PAMS): The silver stain highlights the basement membranes of the glomerulus, Bowman's capsules and tubules.

In many cases, the region of maldevelopment has a wedge-shaped appearance radiating towards the renal capsule. These likely represent lobules or nephron units that did not develop normally and are immediately adjacent to normal renal parenchyma.

An interactive or media element has been excluded from this version of the text. You can view it online here:
https://ohiostate.pressbooks.pub/vetrenalpathatlas/?p=907

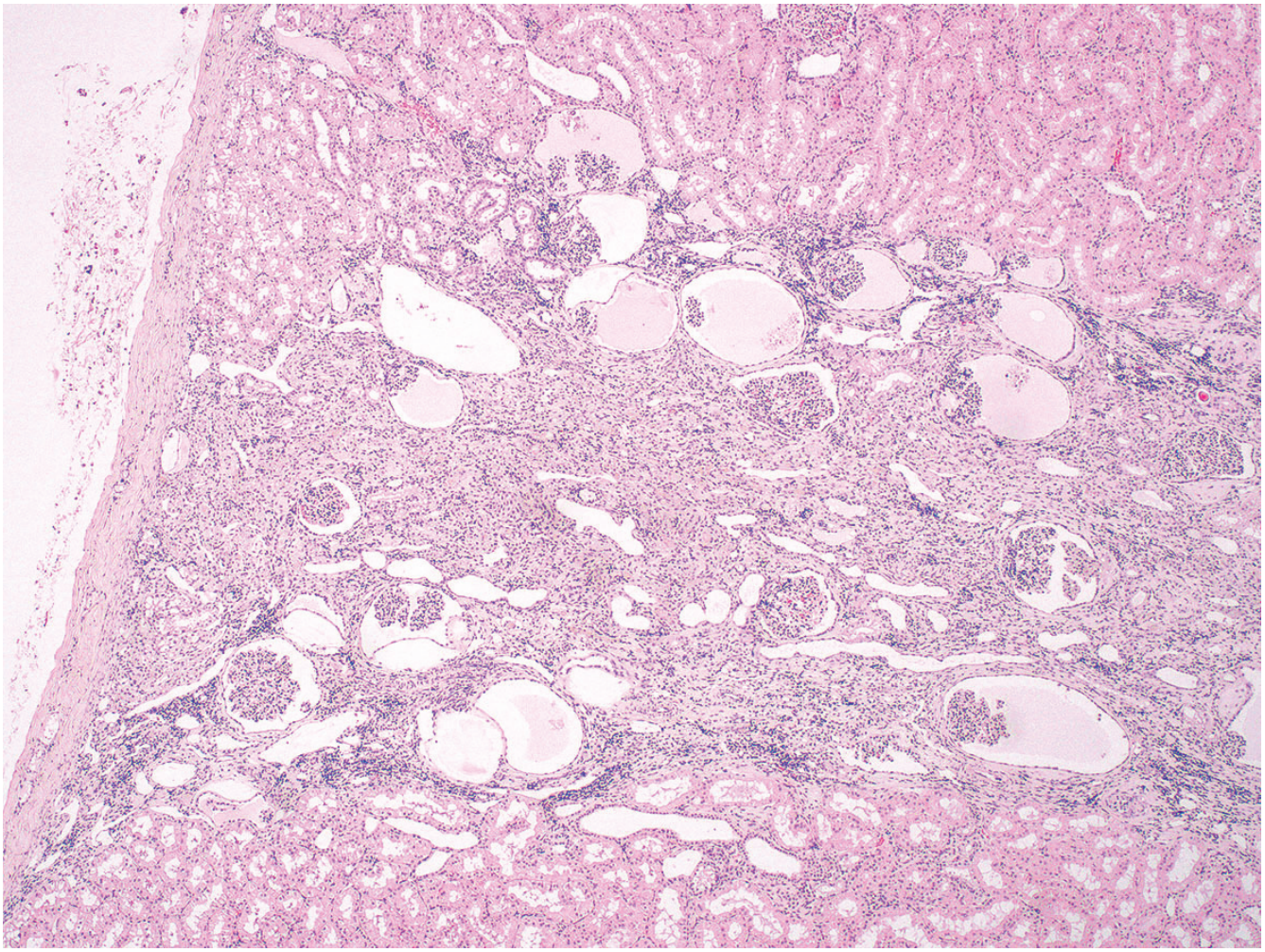

FIG.6A (HE): In this sample of renal cortex, there is a radiating streak of mildly inflamed interstitial fibrosis that separates the dilated ducts and glomeruli with cystic Bowman's capsules.

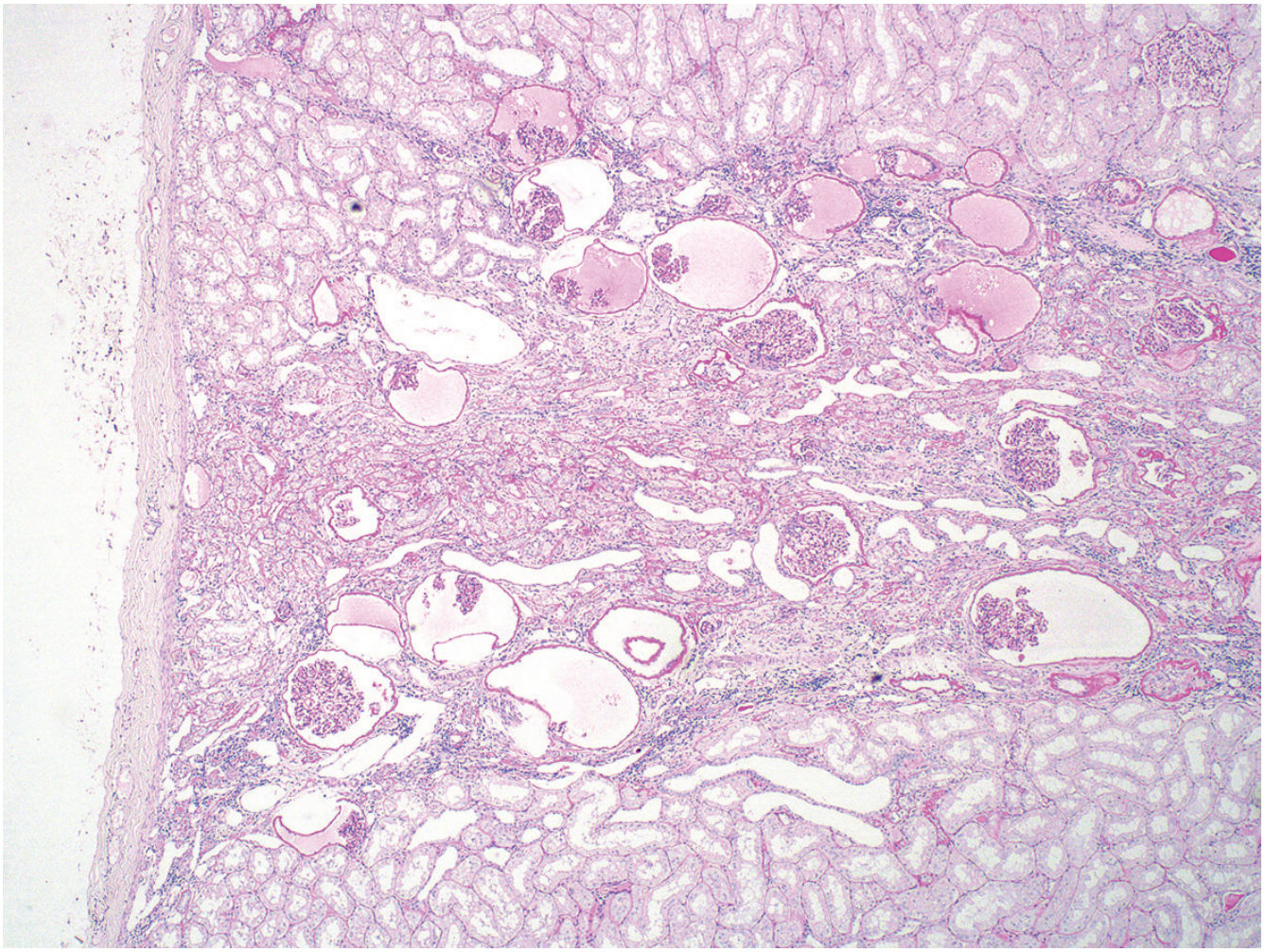

FIG.6B (PAS): Same region as above. This stain highlights the basement membranes of small tubular profiles.

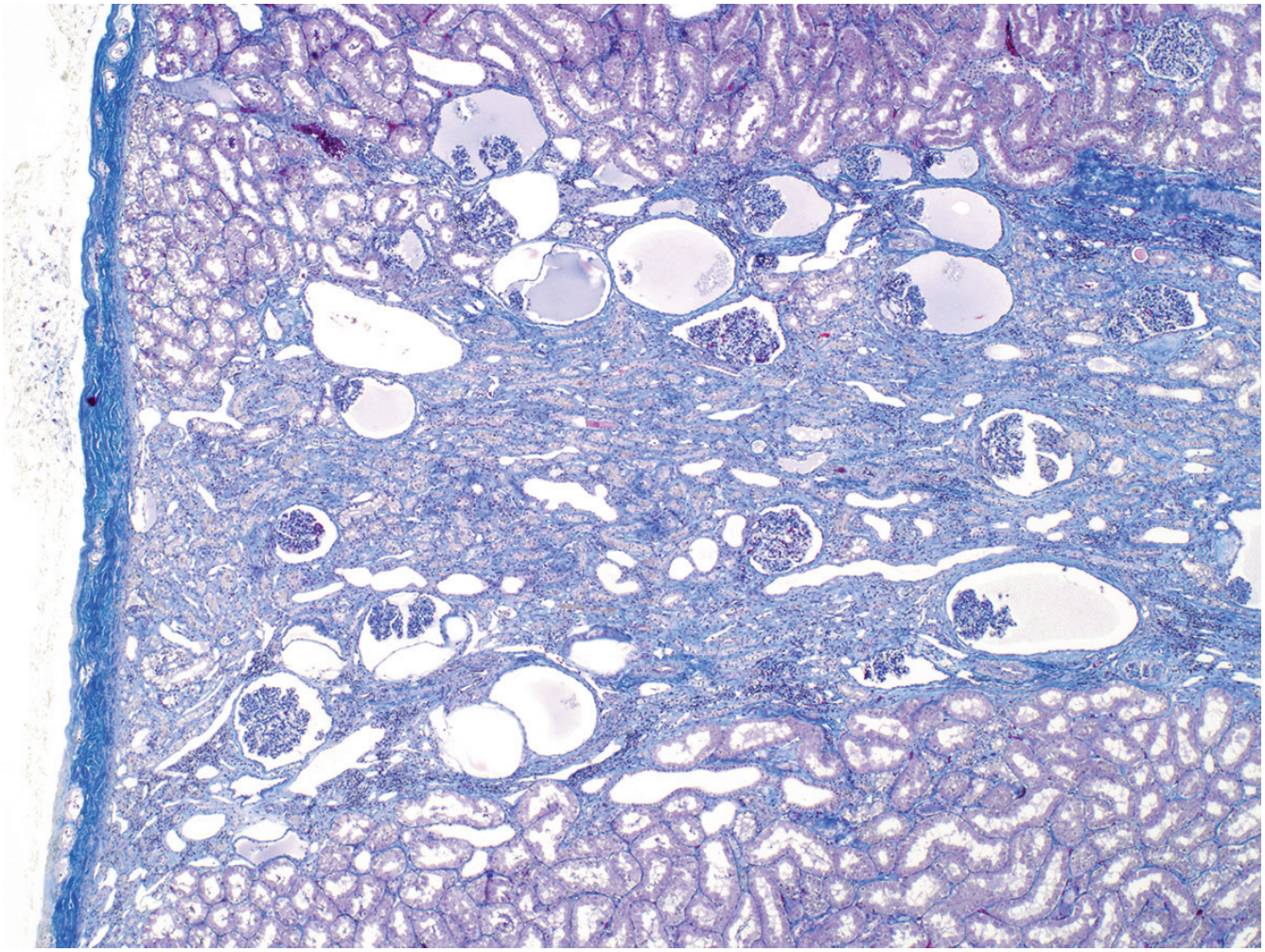

FIG.6C (MT): Same region as above. This stains highlights the interstitial fibrosis that separates the small tubular profiles.

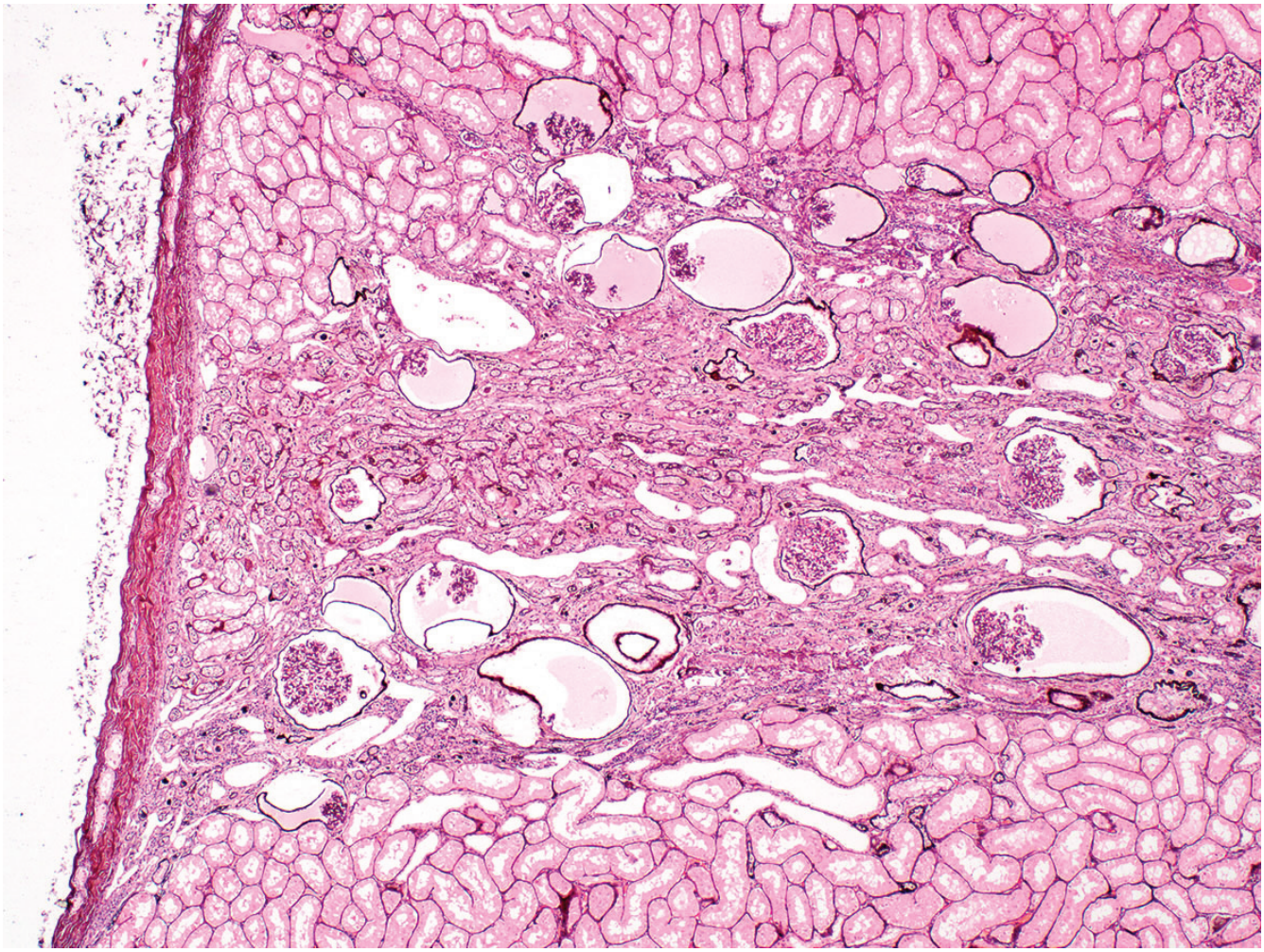

FIG.6D (PAMS): The basement membranes of the dilated Bowman's capsules and tubular basement membranes stain prominently.

The wedge or lobular appearance can be easy to discern in nephrectomy or autopsy samples, but imagine how a needle core biopsy of the above kidney might appear. Regions of dense collagen will likely be harder to cut through, compared to the normal parenchyma. In our experience, core biopsies from animals with abnormally developed wedges or lobules will harvest only small portions of the collagenous tissue which are immediately adjacent to normal kidney tissue. Importantly, however, the fetal glomeruli in these pieces should be included in the overall count to estimate the proportion of non-functioning nephrons in the patient.

An interactive or media element has been excluded from this version of the text. You can view it online here:
https://ohiostate.pressbooks.pub/vetrenalpathatlas/?p=907

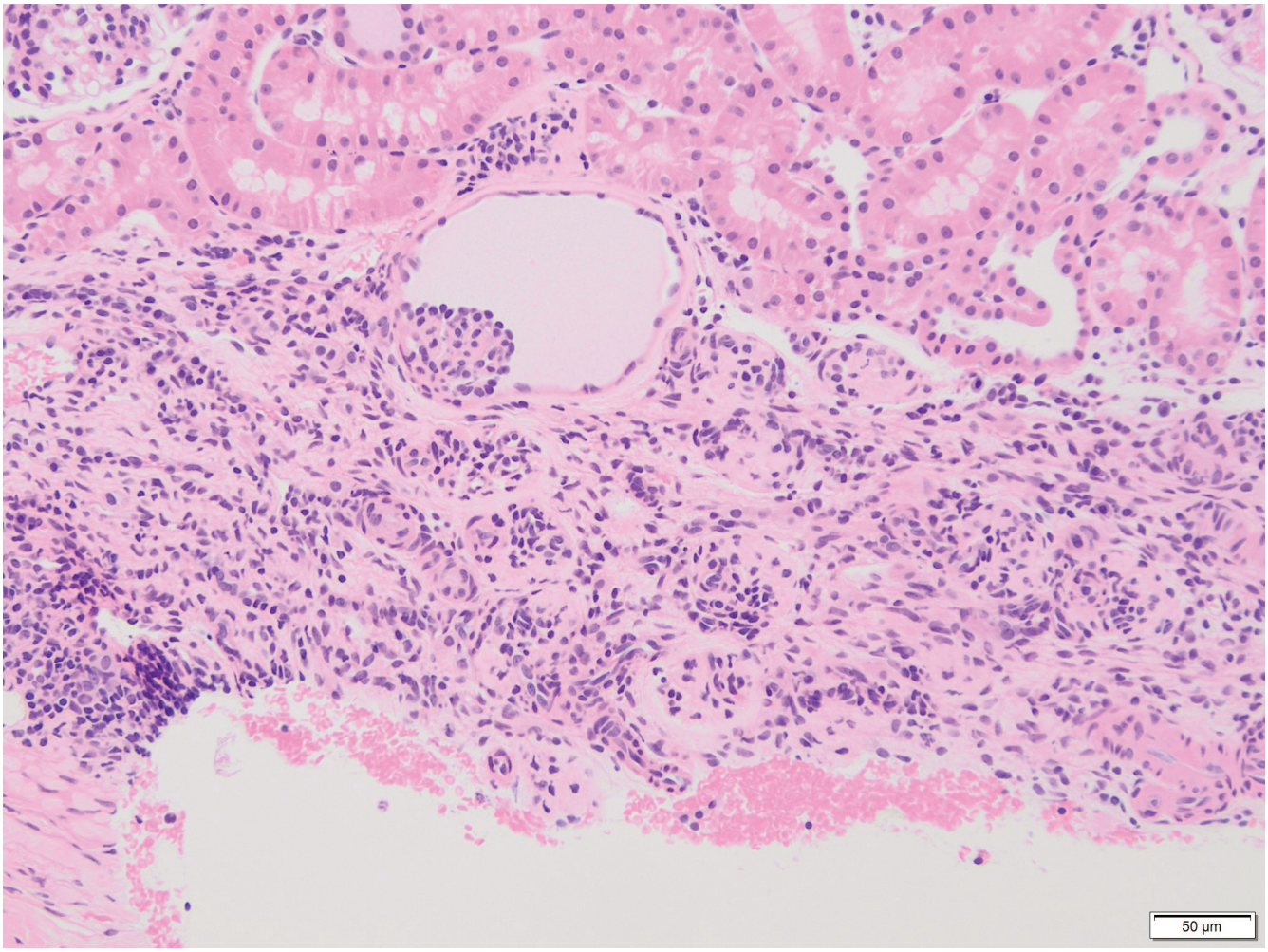

FIG.7A (HE): The HE stain shows a well-demarcated region of collagen and small aggregates of nuclei, which are the fetal glomeruli. One fetal glomerulus is contained within a moderately dilated Bowman's

capsule. The adjacent renal parenchyma appears normal.

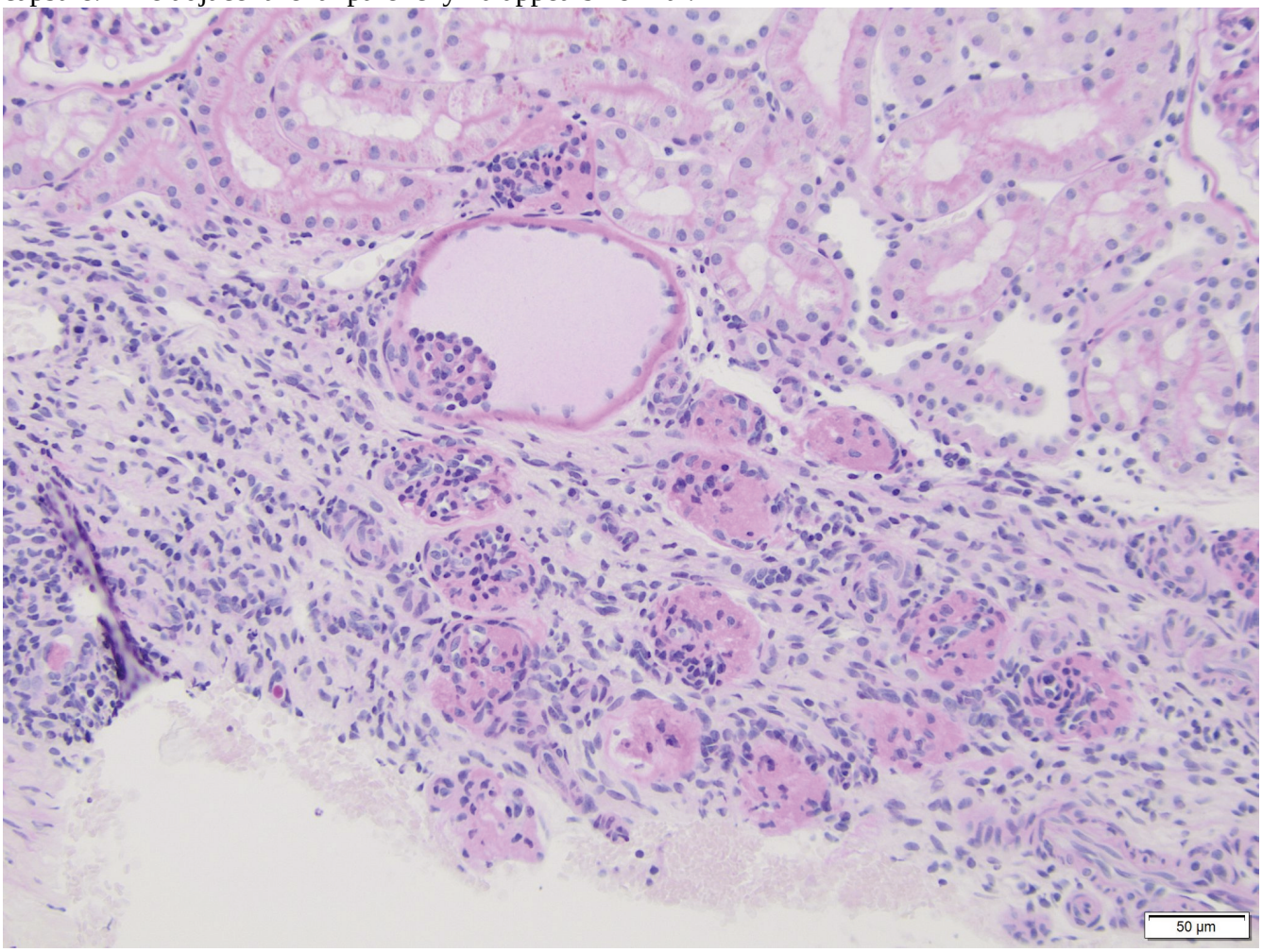

FIG.7B (PAS): The PAS stain highlights the numerous fetal glomeruli at the edge of a core biopsy. The adjacent renal parenchyma appears normal.

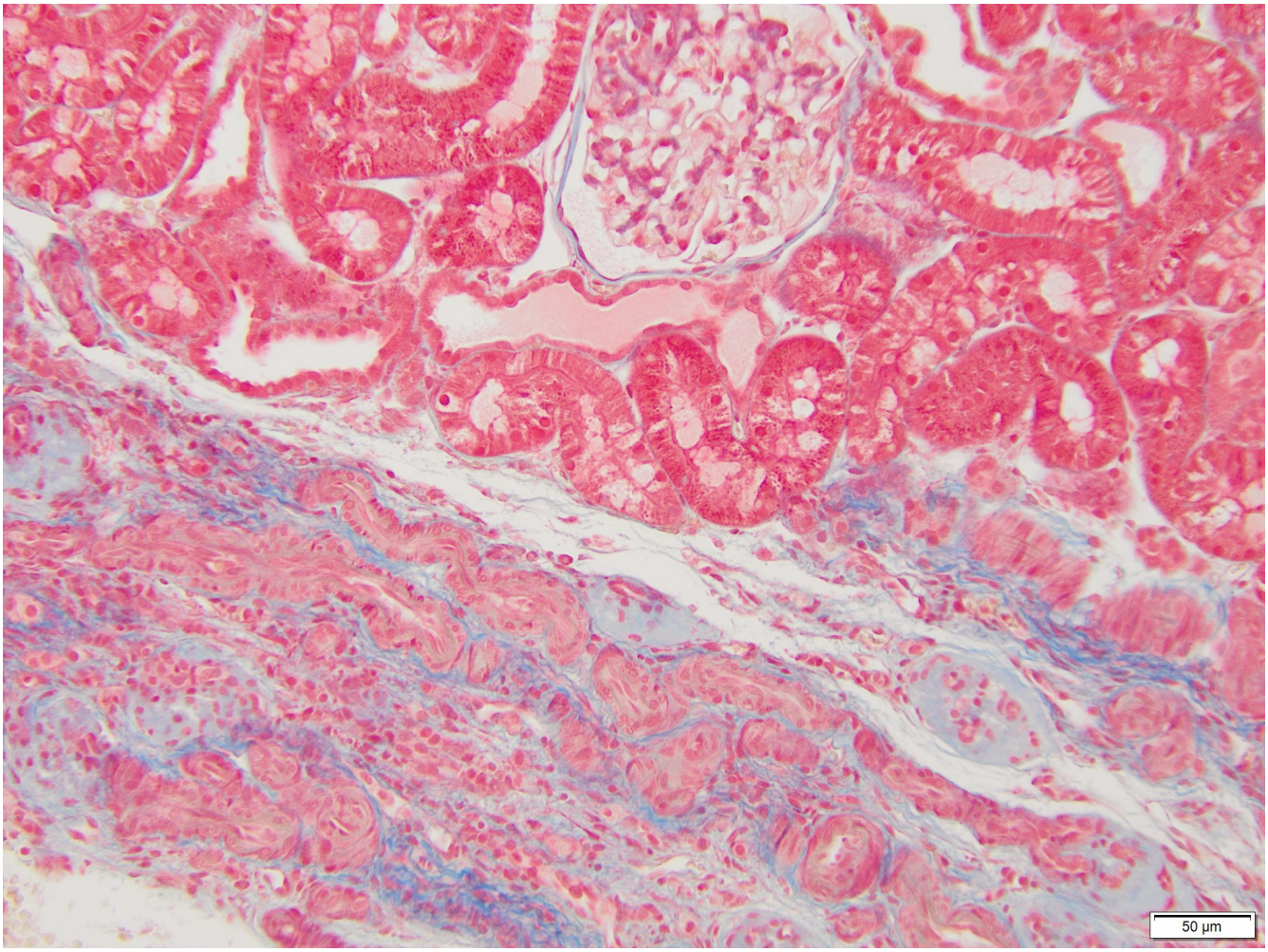

FIG.7C (MT): The fetal glomeruli are somewhat difficult to see because the collagen blends with the interstitium. However, multiple arterial profiles are close together,

whereas they would normally be separated by glomeruli and tubular profiles.

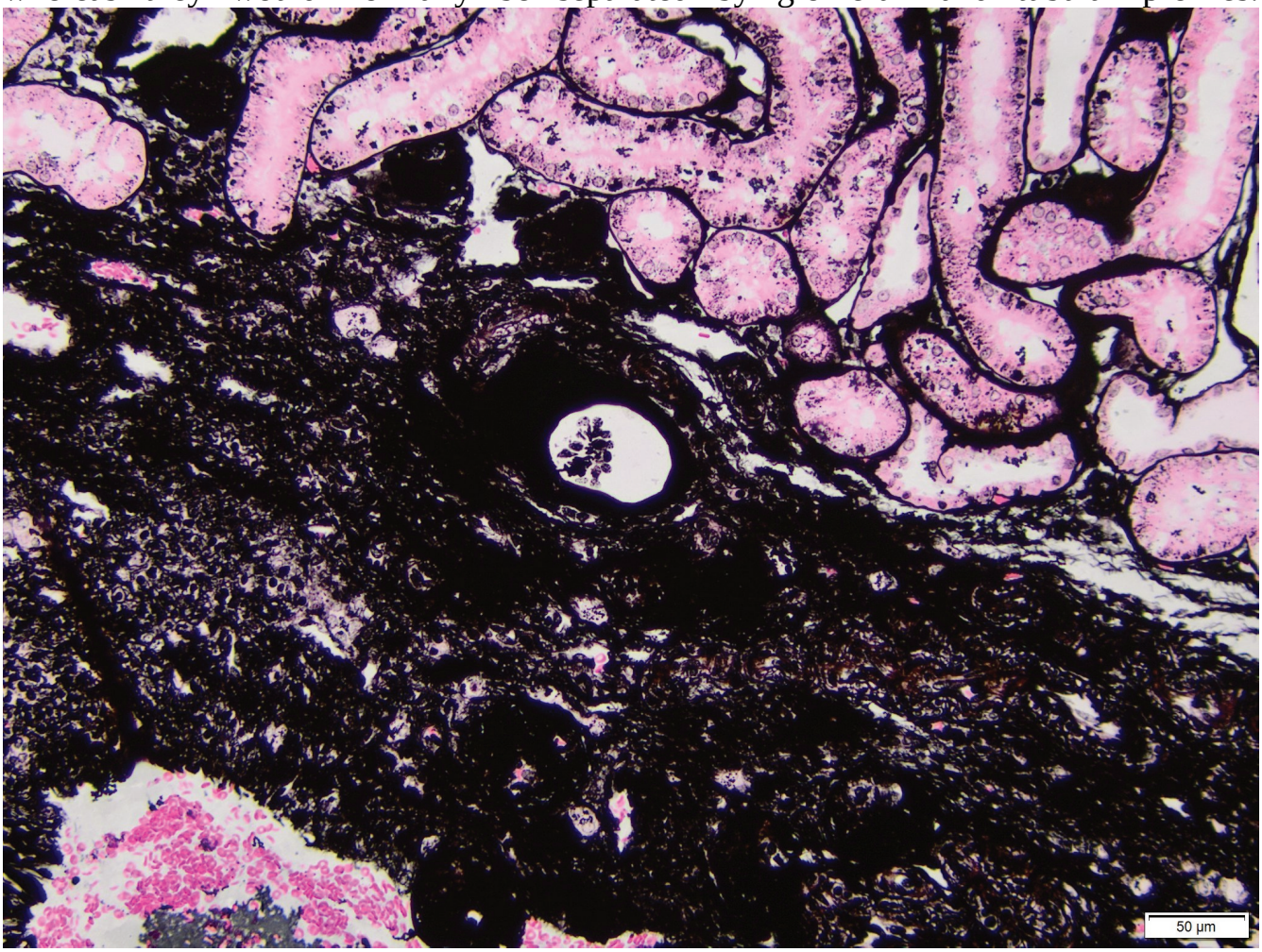

FIG.7D (JMS): The maldeveloped region stains dark black with the JMS stain. A single glomerular profile with a dilated Bowman's capsule is evident at the junction between normal and abnormal parenchyma.

Other less common lesions of renal malevelopment include numerous cystically dilated tubules or ducts. These are unusual lesions in young animals with normal nephron development. Notably, however, diffuse tubular and ductal dilation can be acquired lesions secondary to obstruction. Therefore, examination of the papilla, renal pelvis and lower urinary tract is recommended to rule out obstructive nephropathy. Focal dilation can be secondary to intratubular / intraductal casts or from compression by the interstitium.

An interactive or media element has been excluded from this version of the text. You can view it online here:
https://ohiostate.pressbooks.pub/vetrenalpathatlas/?p=907

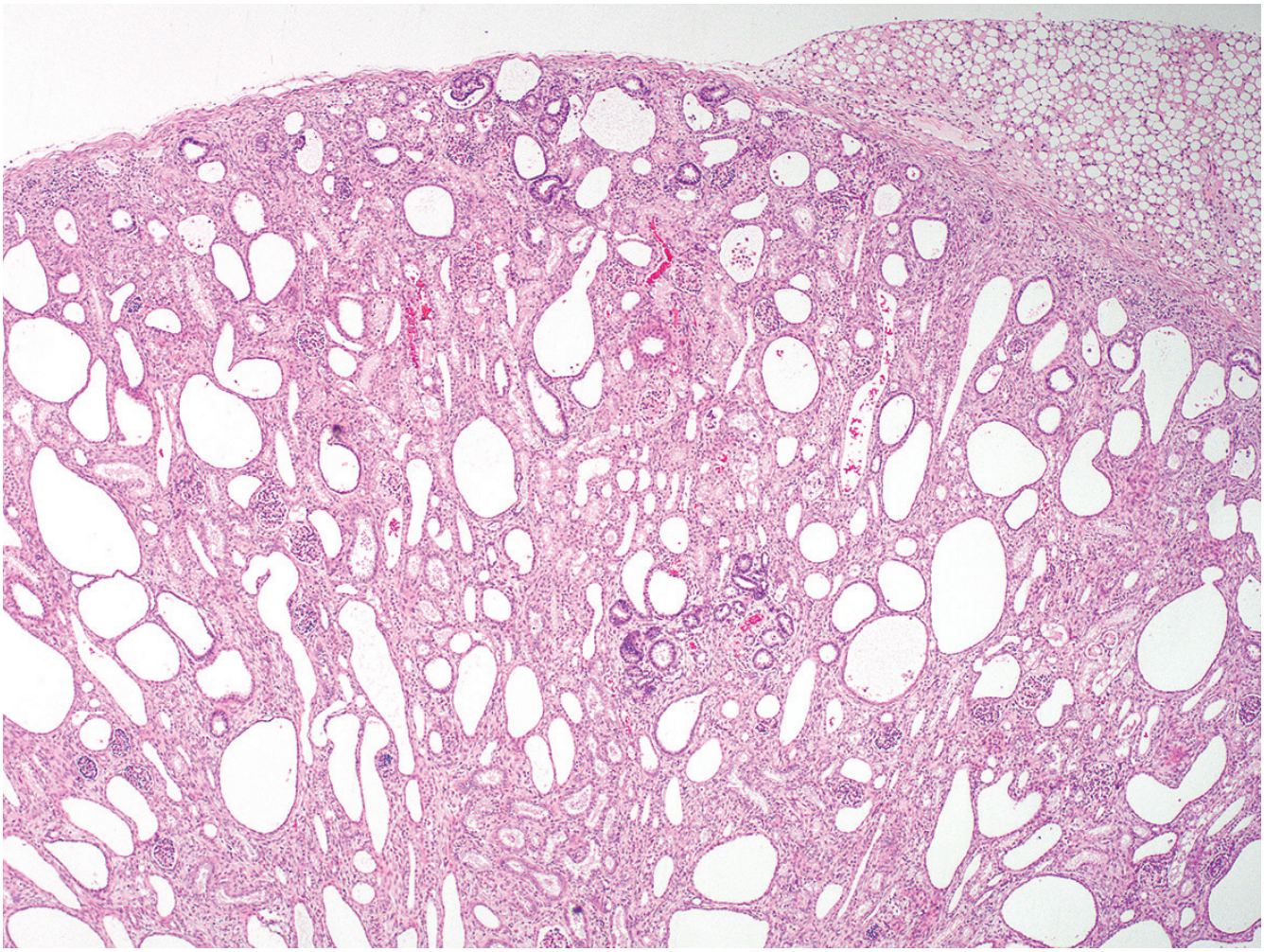

FIG.8A (HE): The entire cortical parenchyma is abnormal with numerous dilated tubular and ductal profiles. This appearance can be mistakenly called polycystic kidney disease (PKD); however, the diagnosis of PKD should be reserved for cases in which there are proven mutations in PKD-1 or PKD-2 genes. Cysts in PKD patients develop over time due to abnormalities in the primary cilia of tubular epithelial cells. Humans that have numerous cysts secondary to abnormal nephron development are diagnosed with “multicystic dysplasia”.

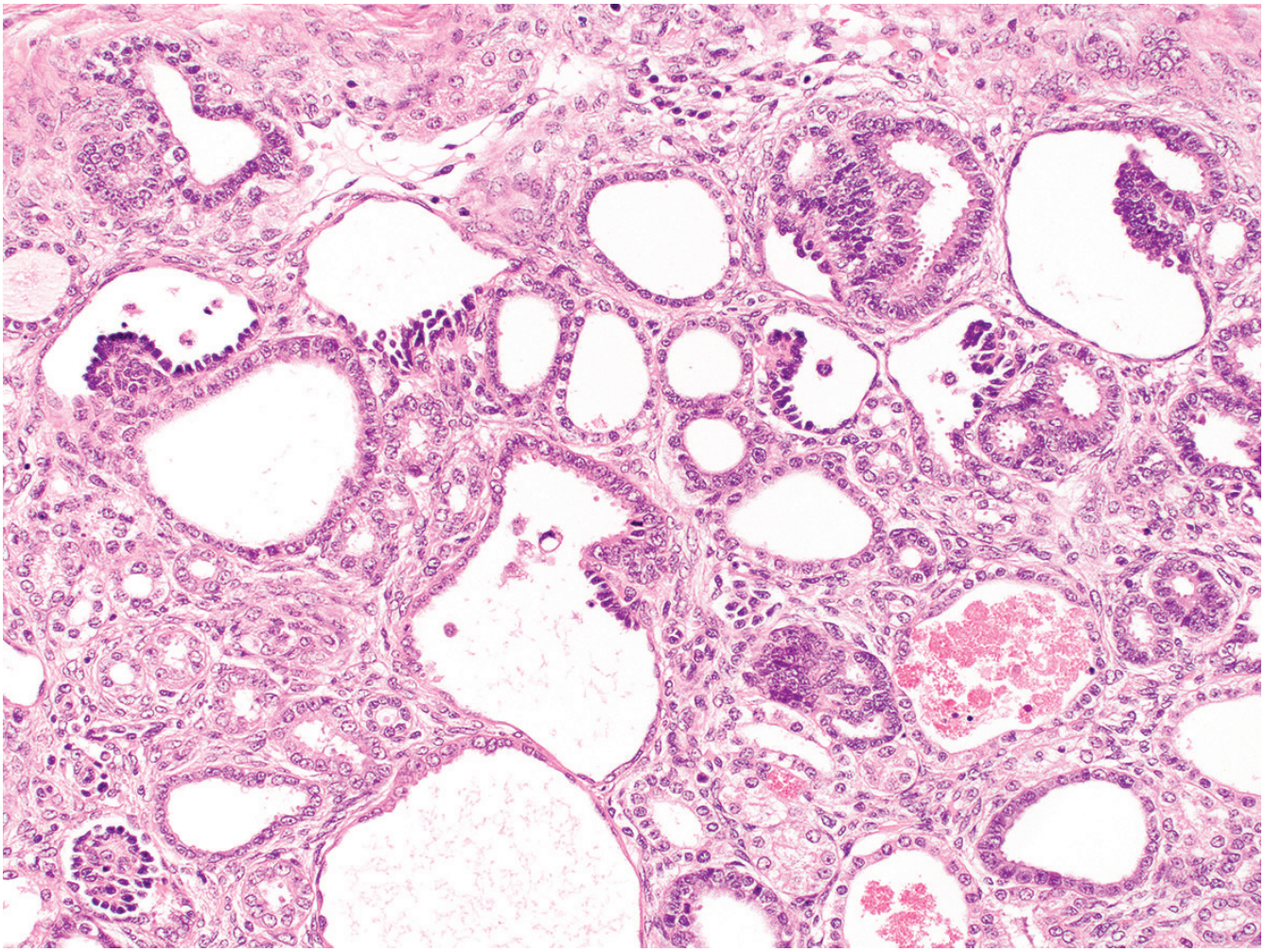

FIG.8B (HE): Higher magnification of the above photomicrograph shows that the dilated tubules and ducts are admixed with smaller tubules that have crowded columnar epithelium. There is also uninflamed fibrosis. A few tubules have red globular casts within their lumens. These casts are suggestive of fragmented red blood cells,

hemoglobin or myoglobin pigments.

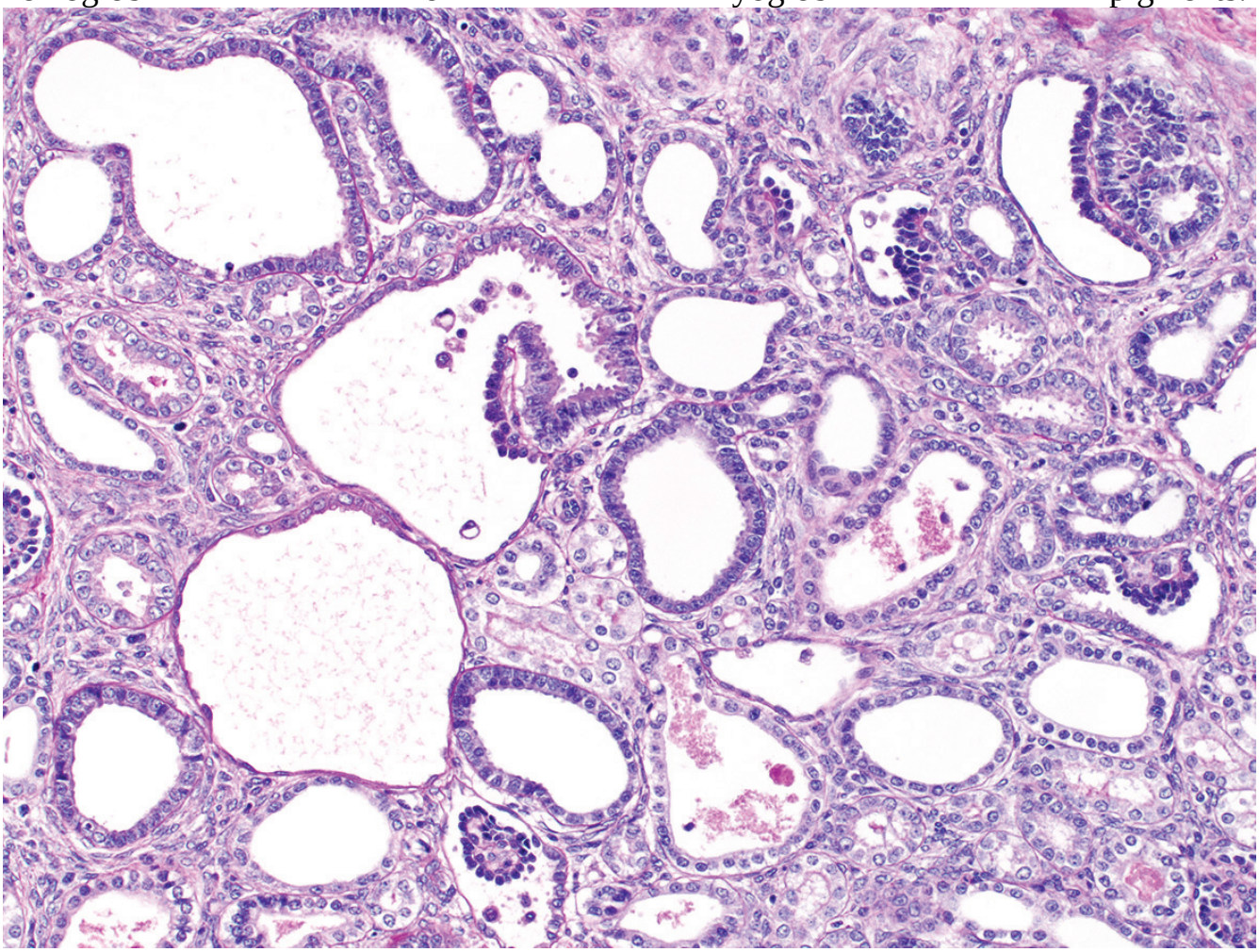

FIG.8C (PAS): This stain demonstrates that the dilated tubules and ducts lack a prominent apical brush border. There is one entire and one partial glomerulus in this photomicrograph.

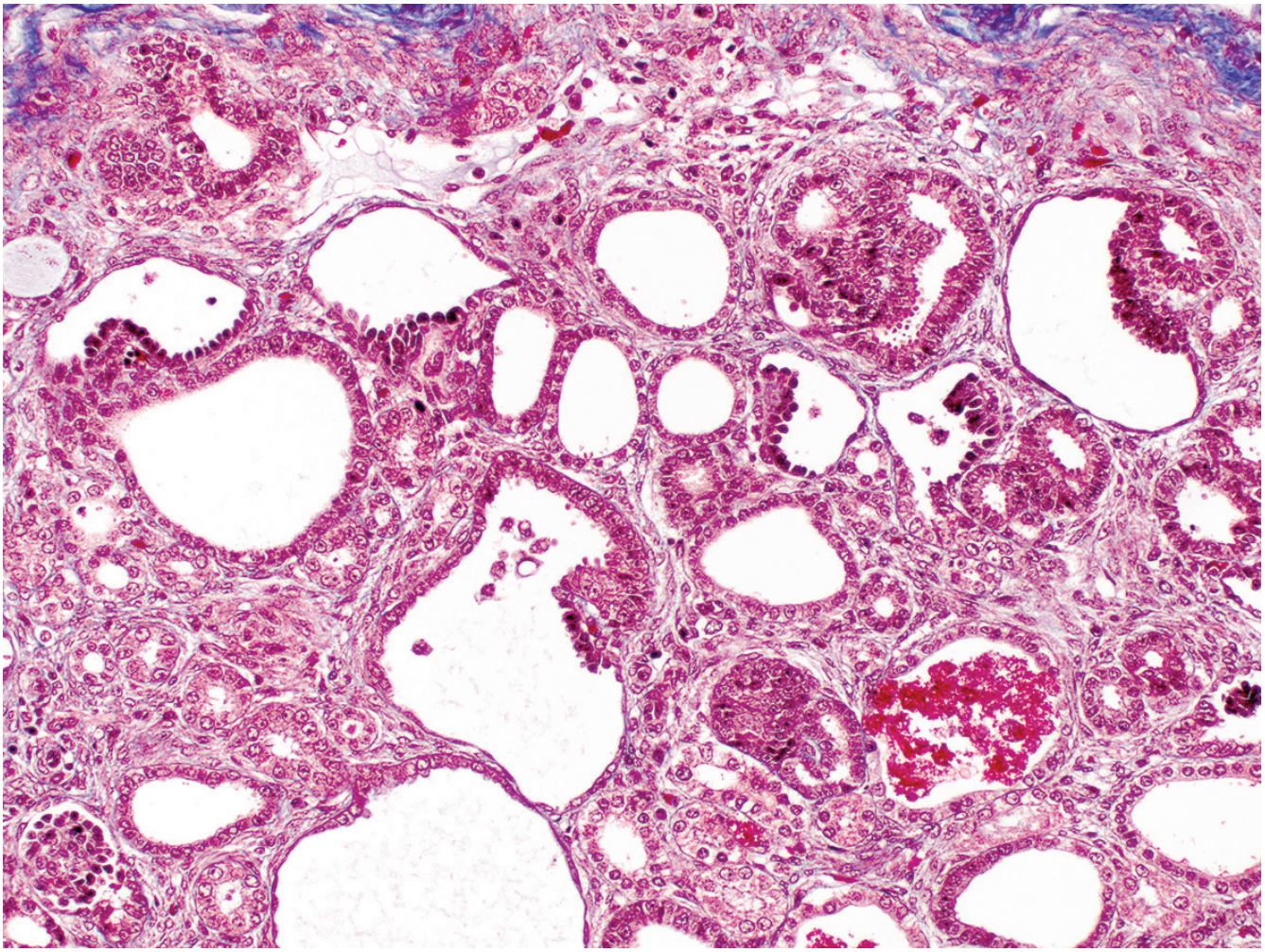

FIG.8D (MT): There is increased interstitial collagen in this specimen but it is not as dense as observed in Figure 5C. This might be a reflection of the difference in the age of the patients. The red globular casts that were seen in Figure 8B are bright red on with MT, suggestive of red blood cell fragments, hemoglobin or myoglobin.

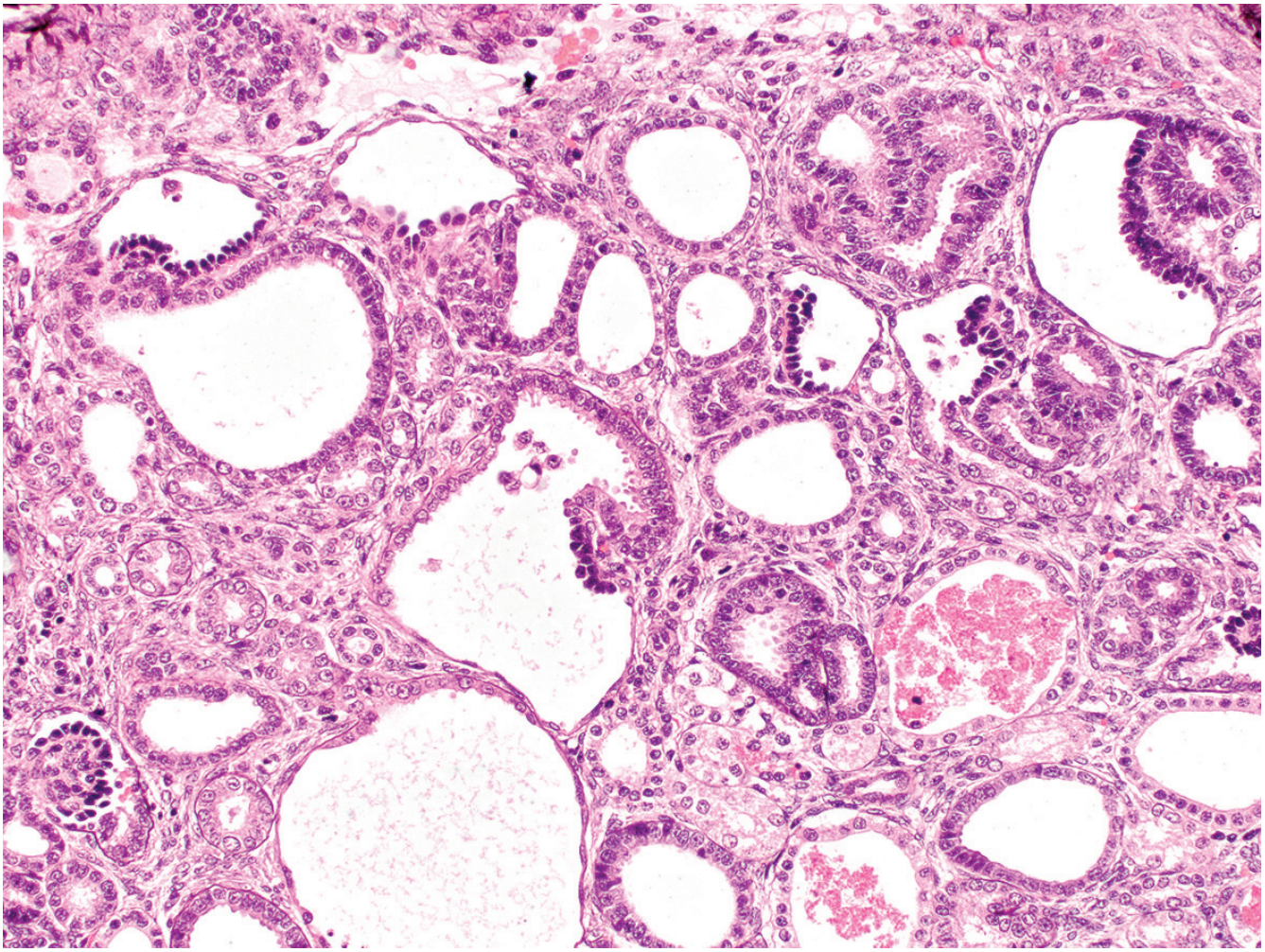

FIG.8E (PAMS): The tubular basement membranes are of normal thickness and do not have evidence of multi-lamination.

An interactive or media element has been excluded from this version of the text. You can view it online here:
https://ohiostate.pressbooks.pub/vetrenalpathatlas/?p=907

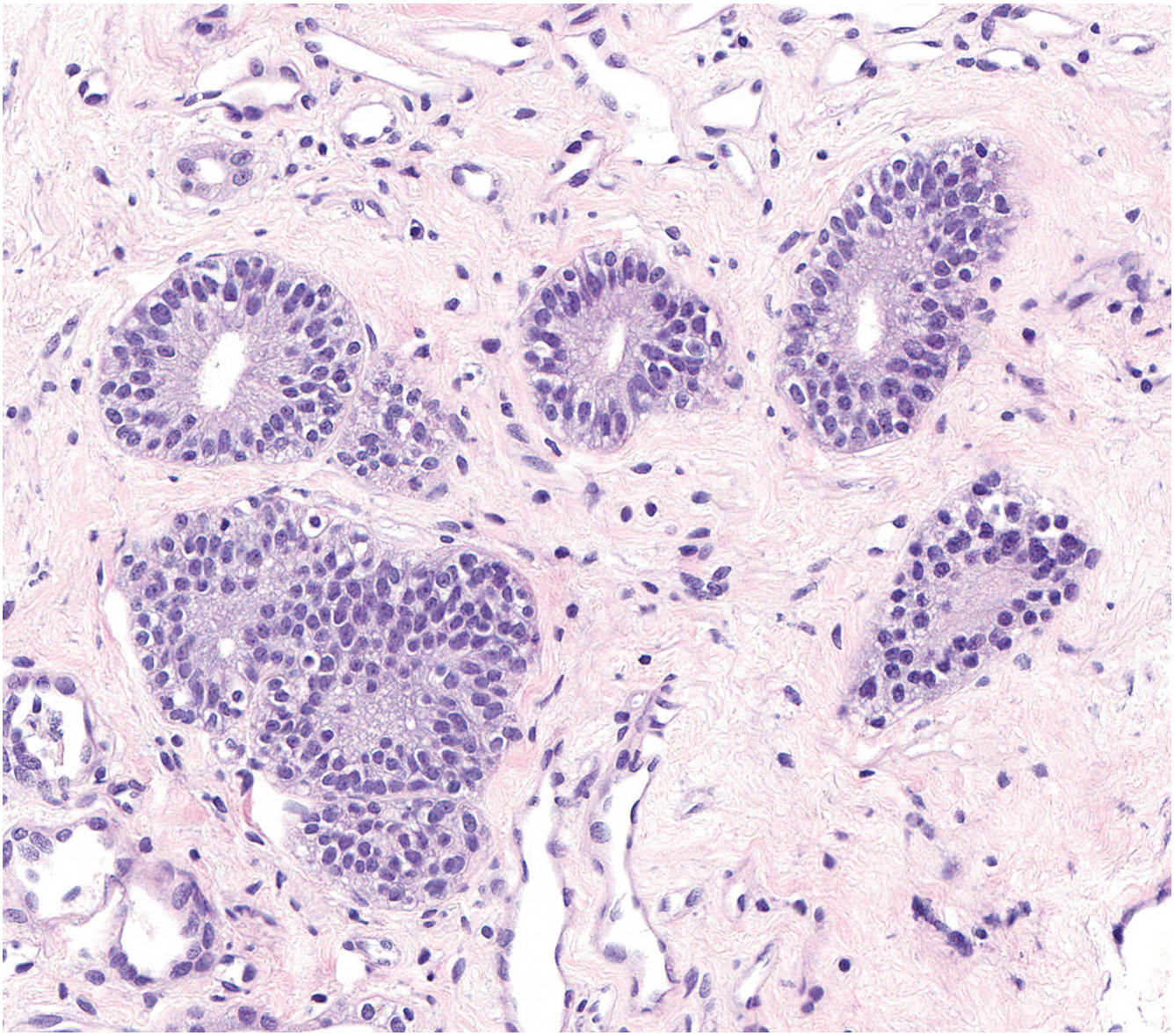

FIG.9A (HE): In samples that contain medullary tissue, ducts such as these might be identified. They are line by tall columnar to pseudostratified epithelium and are sometimes called “metanephric ducts”.

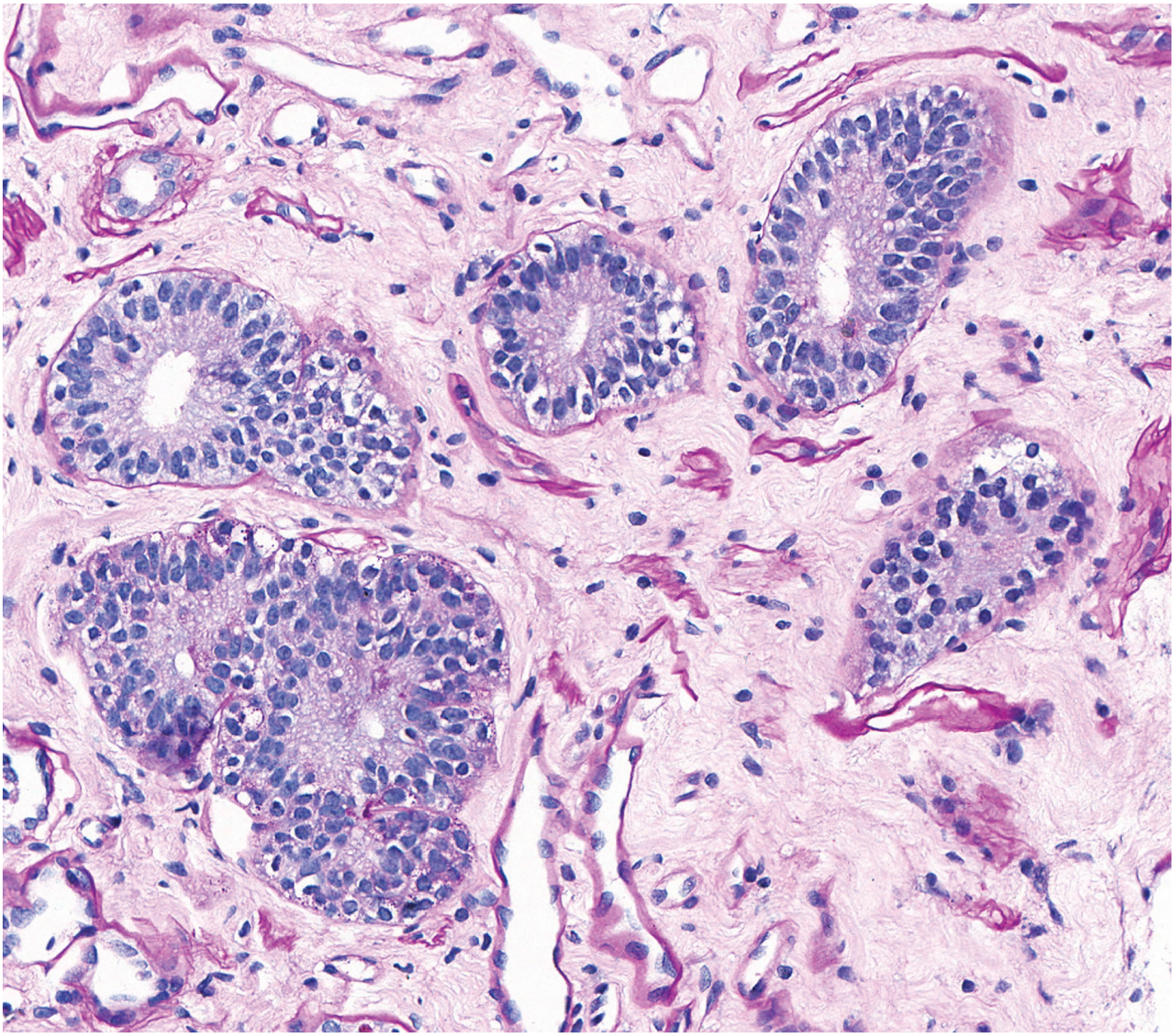

FIG.9B (PAS): This stain shows the ducts with the tall columnar epithelium but there are also admixed tubular profiles with cuboidal to attenuated epithelium (segments of Loops of Henle).

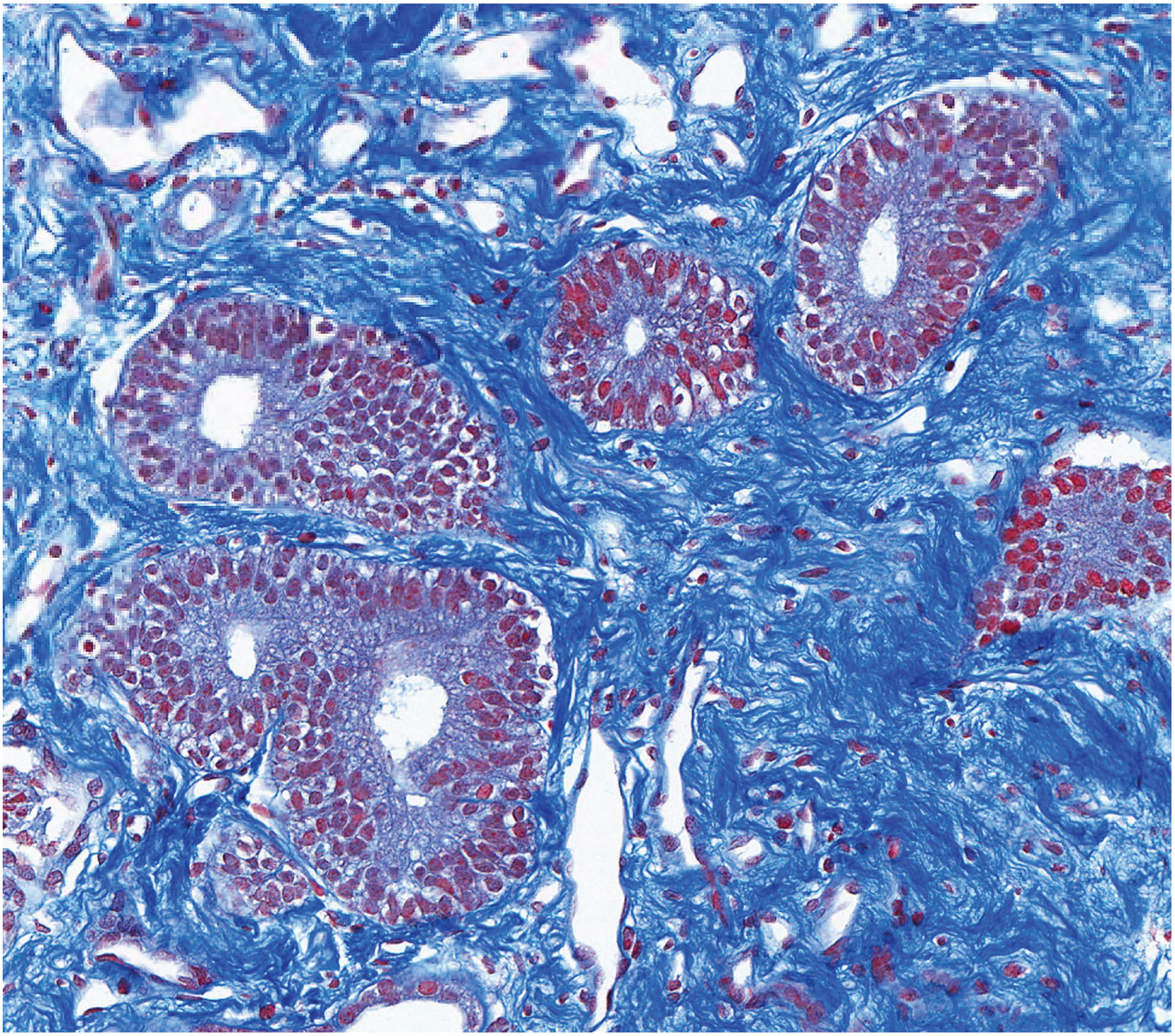

FIG.9C (MT): There is usually increased collagenous matrix in the medullary interstitium in normal kidneys. This should not be diagnosed as papillary or medullary fibrosis.

FIG.9D (JMS): The same region as above.

In some breeds, as well as in some individual dogs, the histopathology can be dominated by the presence of small compressed glomerular tufts and severely dilated Bowman's capsules (glomerulocystic atrophy). This phenotype has been reported in the French bull mastiff but has also been observed in Boxer dogs. In humans, the lesion is sometimes diagnosed as Glomerulocystic Kidney Disease.

An interactive or media element has been excluded from this version of the text. You can view it online here:
https://ohiostate.pressbooks.pub/vetrenalpathatlas/?p=907

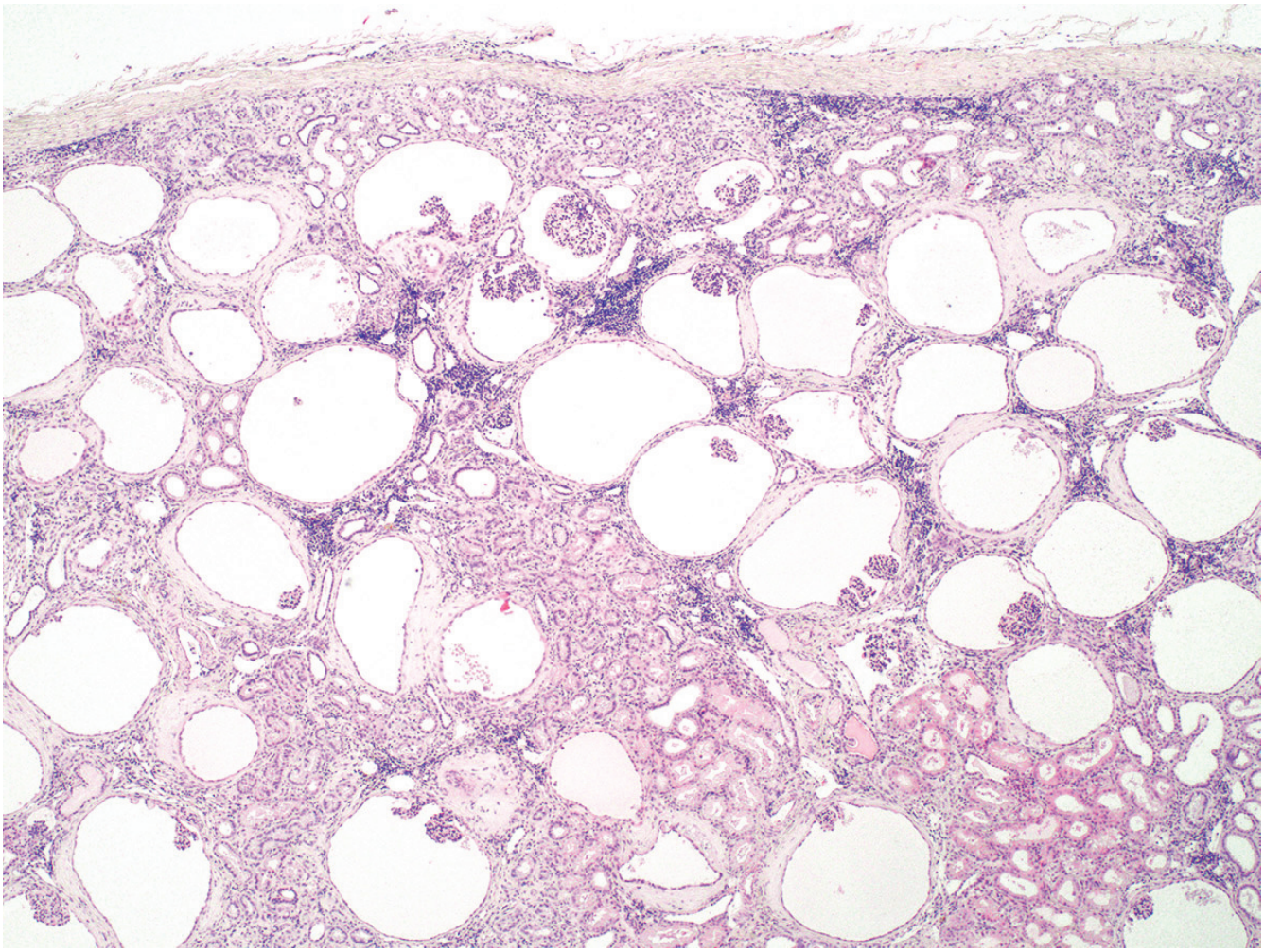

FIG.10A (HE): Most of the glomeruli are small compressed tufts within dilated Bowman's capsules. The clear circles are also dilated Bowman's capsules but the capillary tuft is so small that it is not present in the section. There is mild periglomerular inflammation likely due to small amounts of leakage of the urinary filtrate into the periglomerular interstitium. The tubular profiles are relatively normal.

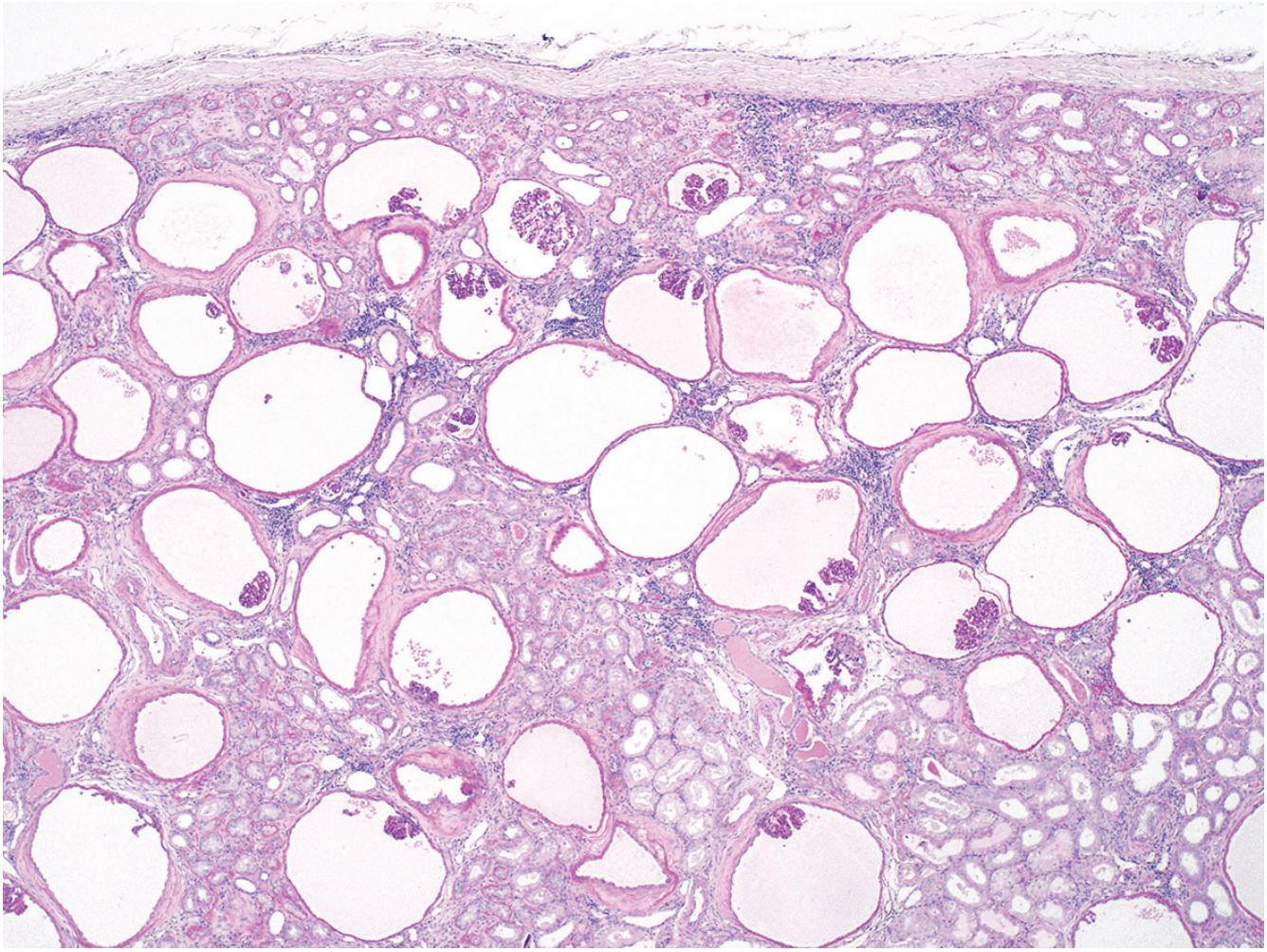

FIG.10B (PAS): The atrophic glomerular tufts stain dark pink and capillary lumens are difficult to appreciate.

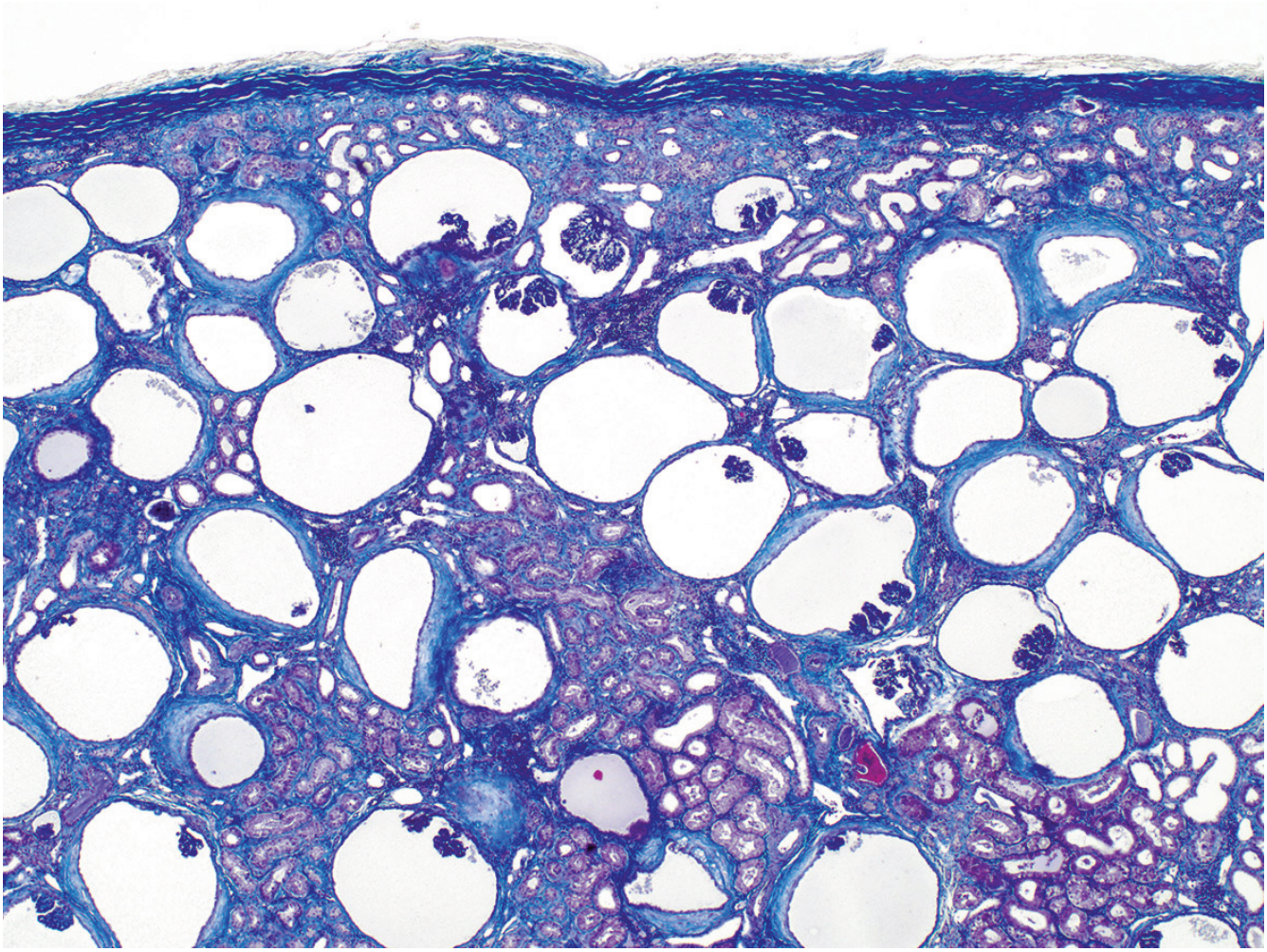

FIG.10C (MT): This stain highlights the collagen surrounding the dilated Bowman's capsules and the mild peritubular fibrosis as well.

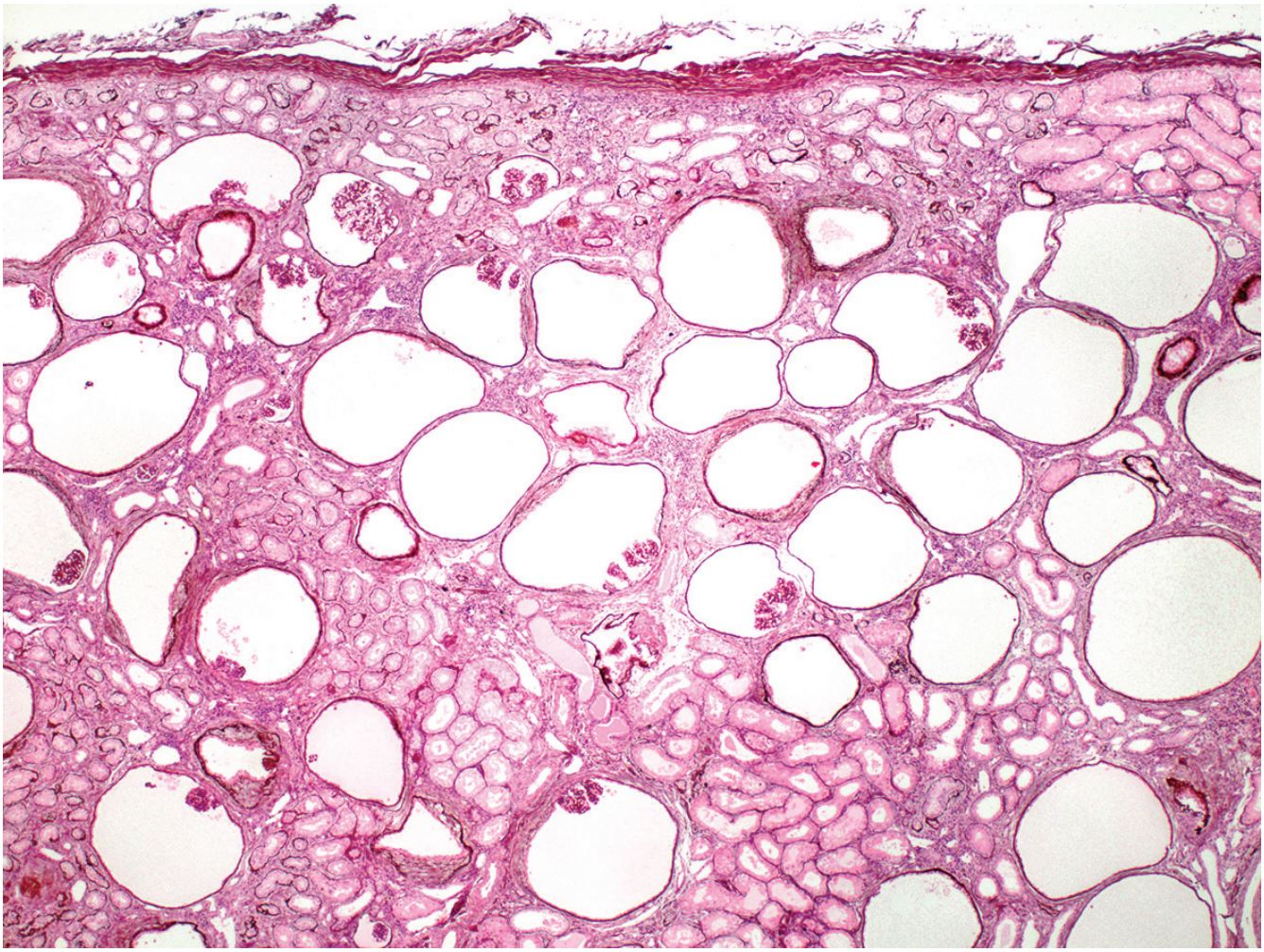

FIG.10D (PAMS): Similar to the PAS stain, the compressed glomerular tufts are easily identified with this stain.

Finally, if the maldevelopment involved a large proportion of nephrons, then the remaining “normal” nephrons undergo hypertrophy to compensate for the limited functioning nephron mass. However, more severe glomerular hypertrophy and hyperfiltration/glomerular hypertension may result in secondary focal segmental glomerulosclerosis (FSGS). Although this compensatory hypertrophy will also occur in older dogs that have lost nephrons (e.g. secondary to CKD), the hypertrophy is typically mild. In growing puppies, the glomeruli may become markedly to severely enlarged. Unfortunately, these glomerular changes can sometimes be mistakenly diagnosed as a “membranoproliferative (MPGN) pattern”. Given the association of MPGN and immune complex deposition, this type of misdiagnosis could lead to unwarranted immunosuppression. Therefore, large hypercellular glomeruli in young dogs should be alert the pathologist to look for other features of maldevelopment in order to avoid this type of mistake. Samples for TEM and IF can help with the final diagnoses in these confusing cases. Severe glomerular hypertrophy and hyperfiltration/glomerular hypertension may also result in secondary focal segmental glomerulosclerosis (FSGS).

An interactive or media element has been excluded from this version of the text. You can view it online here:
https://ohiostate.pressbooks.pub/vetrenalpathatlas/?p=907

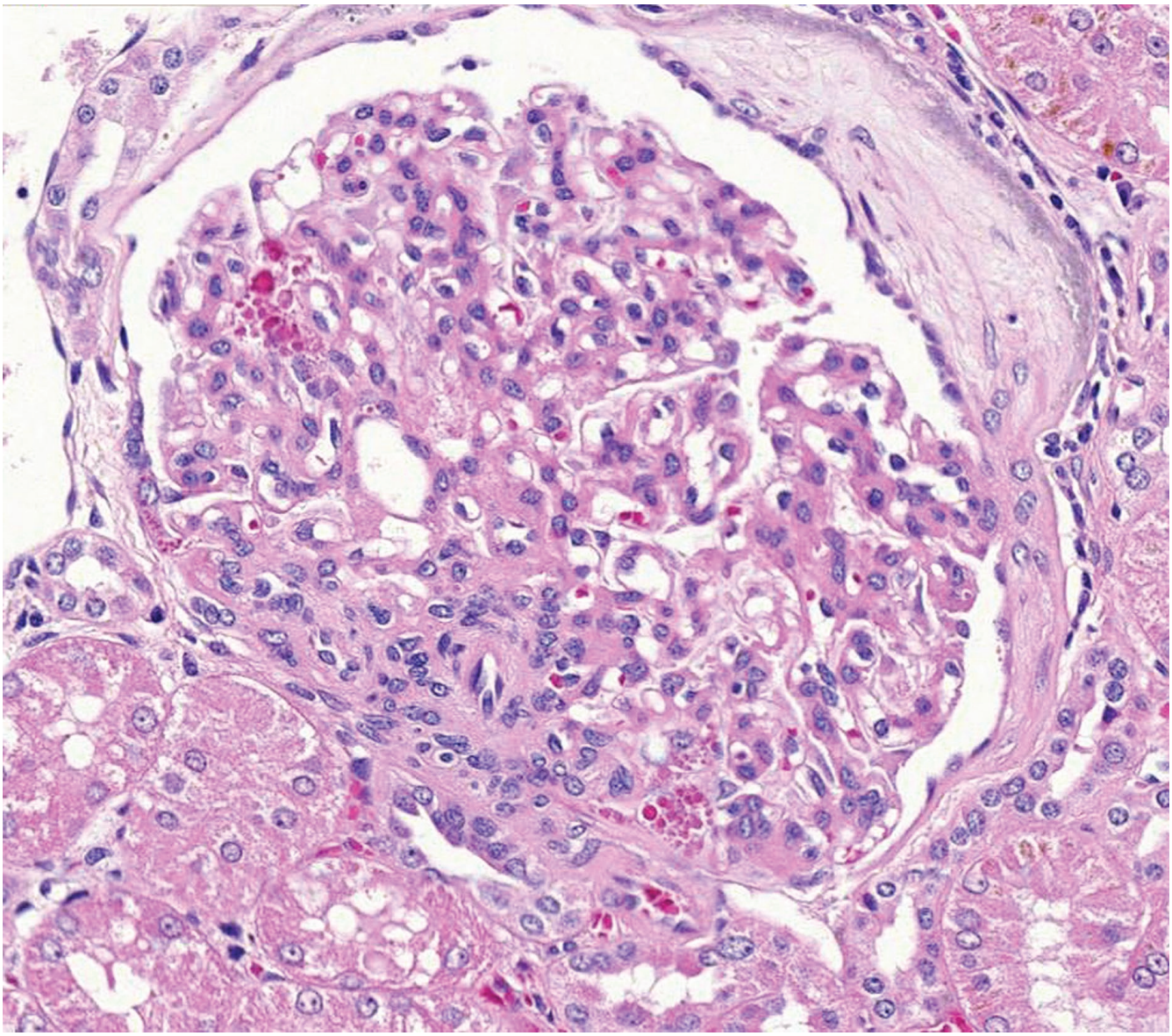

FIG.11A (HE): This glomerulus is markedly enlarged and the photomicrograph is 20X magnification, whereas most of the other glomeruli in this atlas were taken at 40X. There is a small synechiae and moderate periglomerular fibrosis. The podocytes contain prominent protein reabsorption droplets, indicative of injury to this cell lineage.

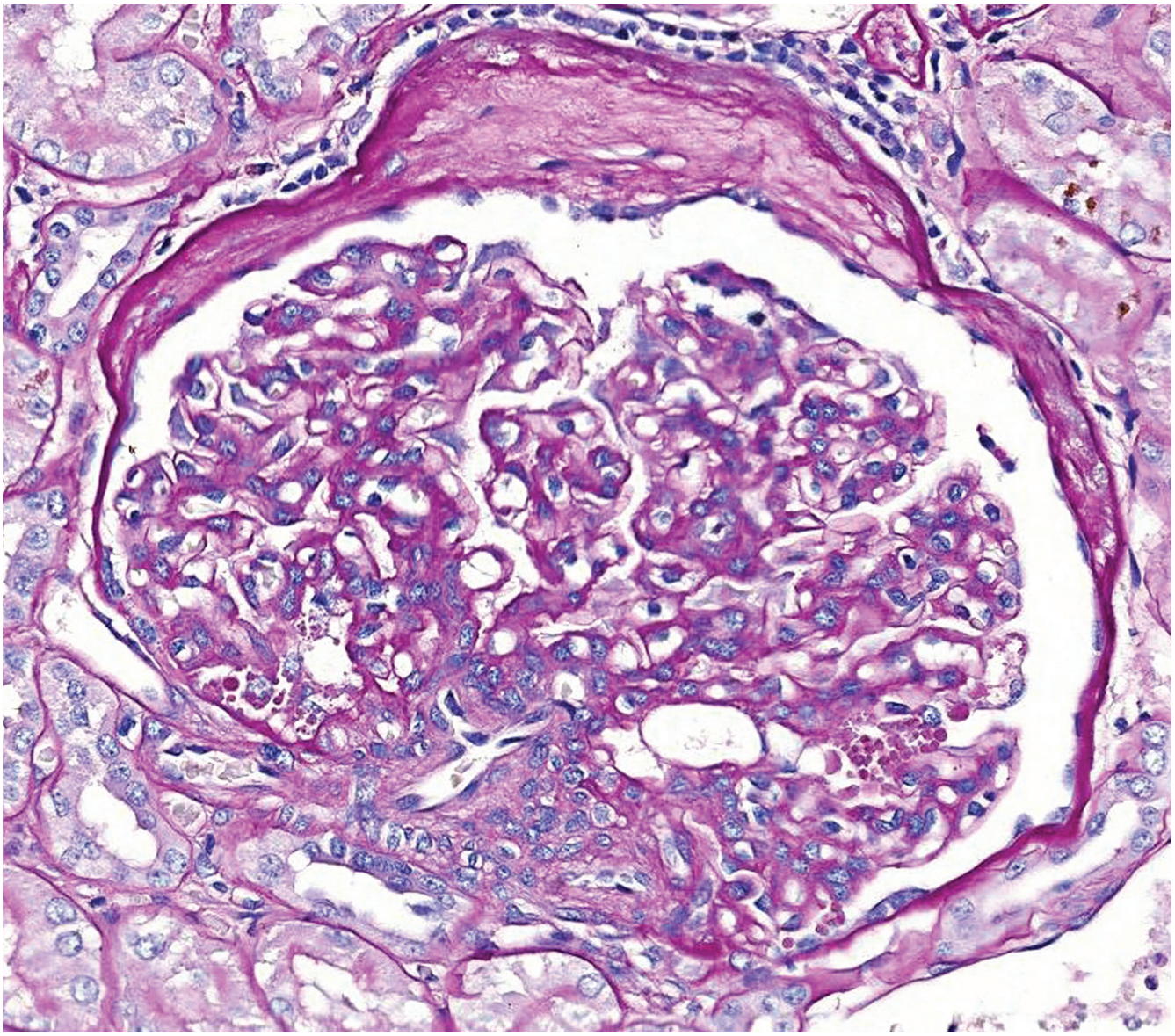

FIG.11B (PAS): Same glomerulus as depicted above. The synechia is not present in this section but there are prominent protein reabsorption droplets in podocytes.

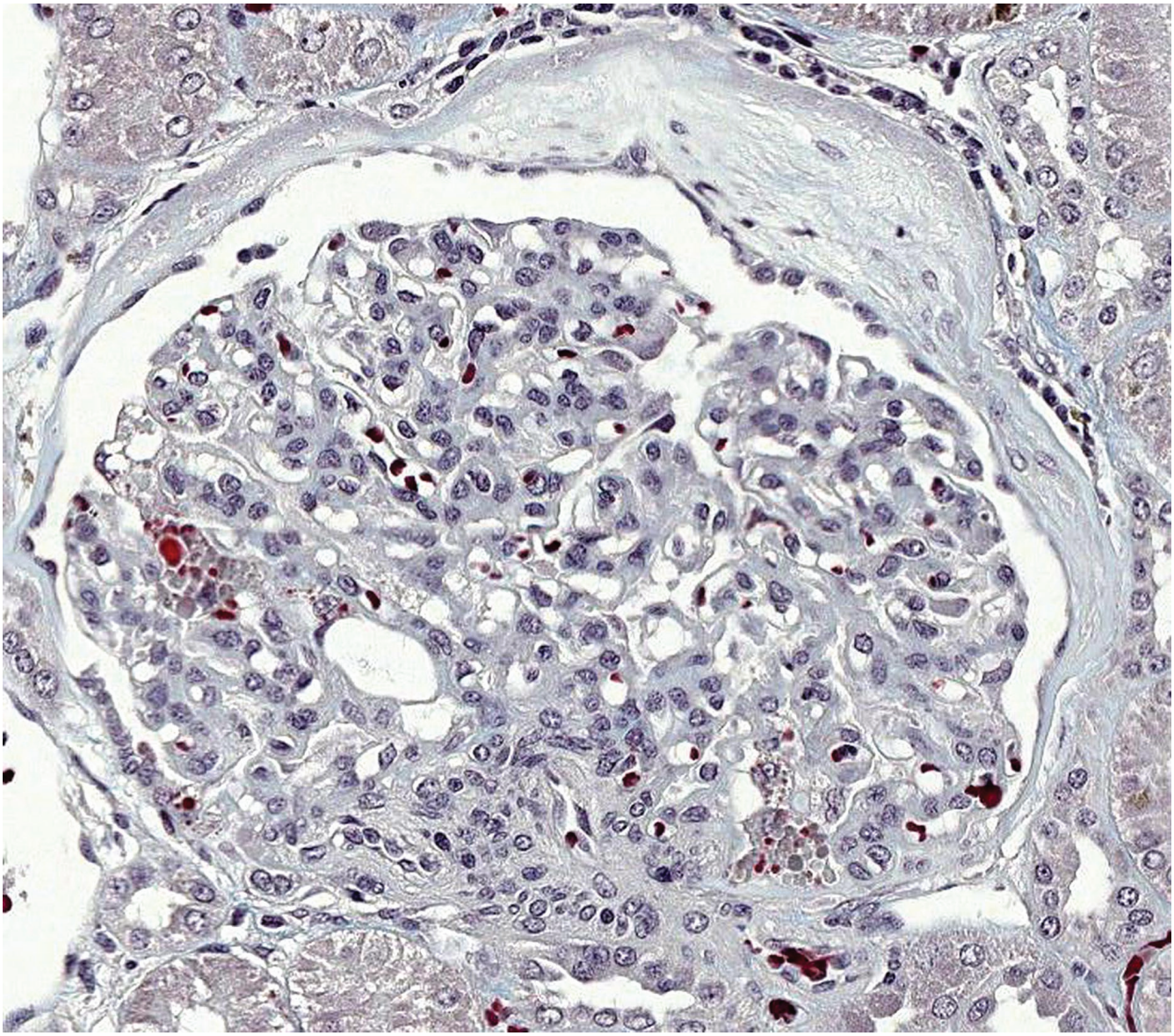

FIG.11C (MT): Same glomerulus as above. The podocyte protein droplets are bright red in this photomicrograph. (Please note that the blue collagen in this stain is paler than in other images because it was stained by a different histology laboratory than most of the other images.)

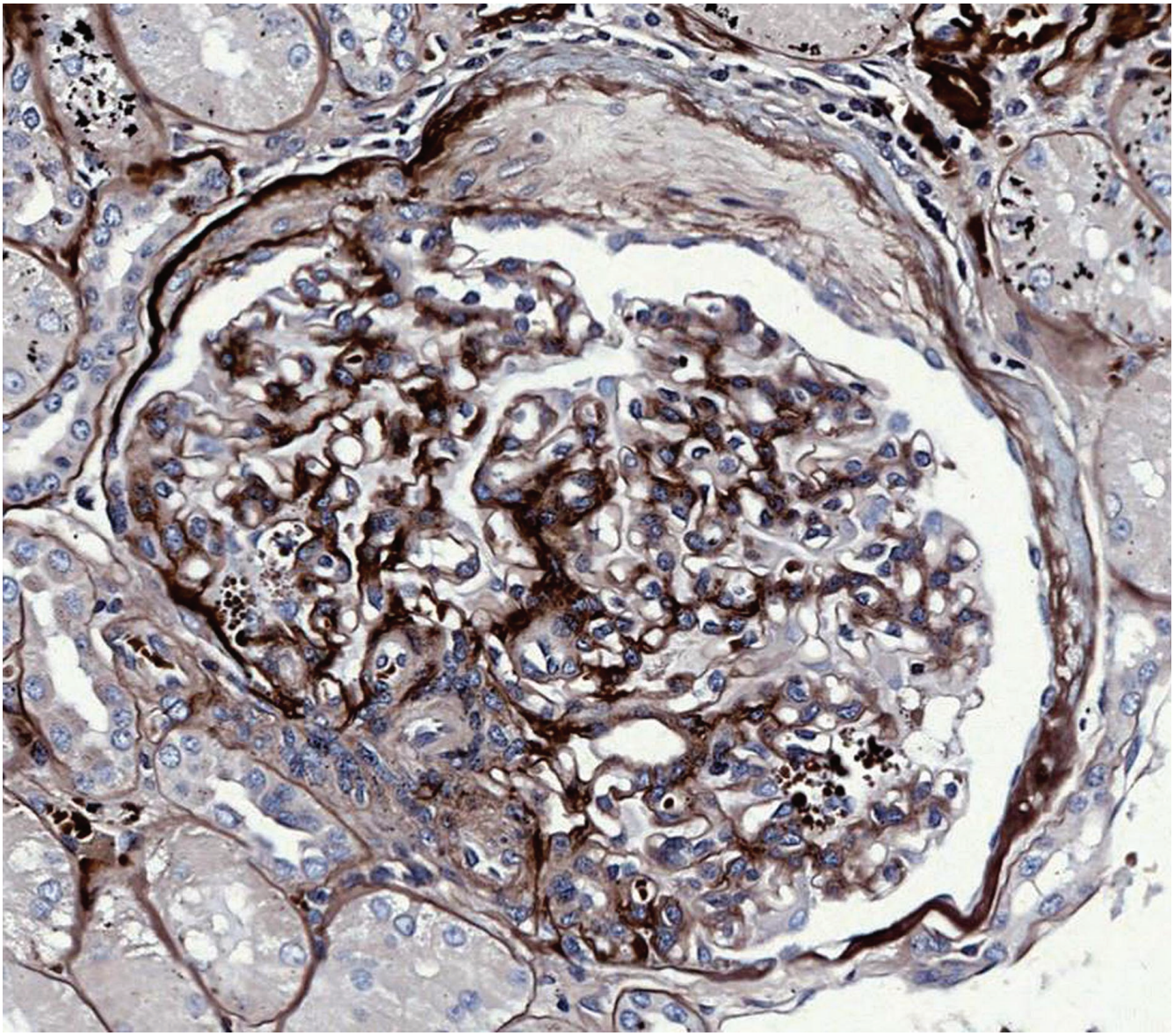

FIG.11D (JMS): Same glomerulus as above. There is another small synechia in a different location in this image.

Summary

As demonstrated above, there are a wide variety of chronic renal diseases that can be diagnosed in young dogs. Some diagnoses require TEM and, although they cannot yet be cured in dogs (or humans for that matter), a correct diagnosis is important for pedigree management and breeding decisions. Other diagnoses can be made based on histologic evaluation together with the clinical history (e.g. renal maldevelopment and ascending bacterial pyelonephritis). Clinicians are unlikely to submit a renal biopsy sample in order to diagnose pyelonephritis; however, diagnosing this condition in an autopsy sample from a neonate might be confusing because of the presence of fetal glomeruli. Moreover, correct diagnosis of maldevelopment (which could be hereditary) will help clinicians decide if relatives of the patient might be at risk. And to add one more layer of complexity, we have diagnosed young dogs with multiple of the previously described conditions. For example, dogs with malformed kidneys appear to be predisposed to urinary reflux and could develop ascending pyelonephritis. Additionally,

although it is rare, we have diagnosed ICGN in young dogs that also had lesions consistent with renal maldevelopment.

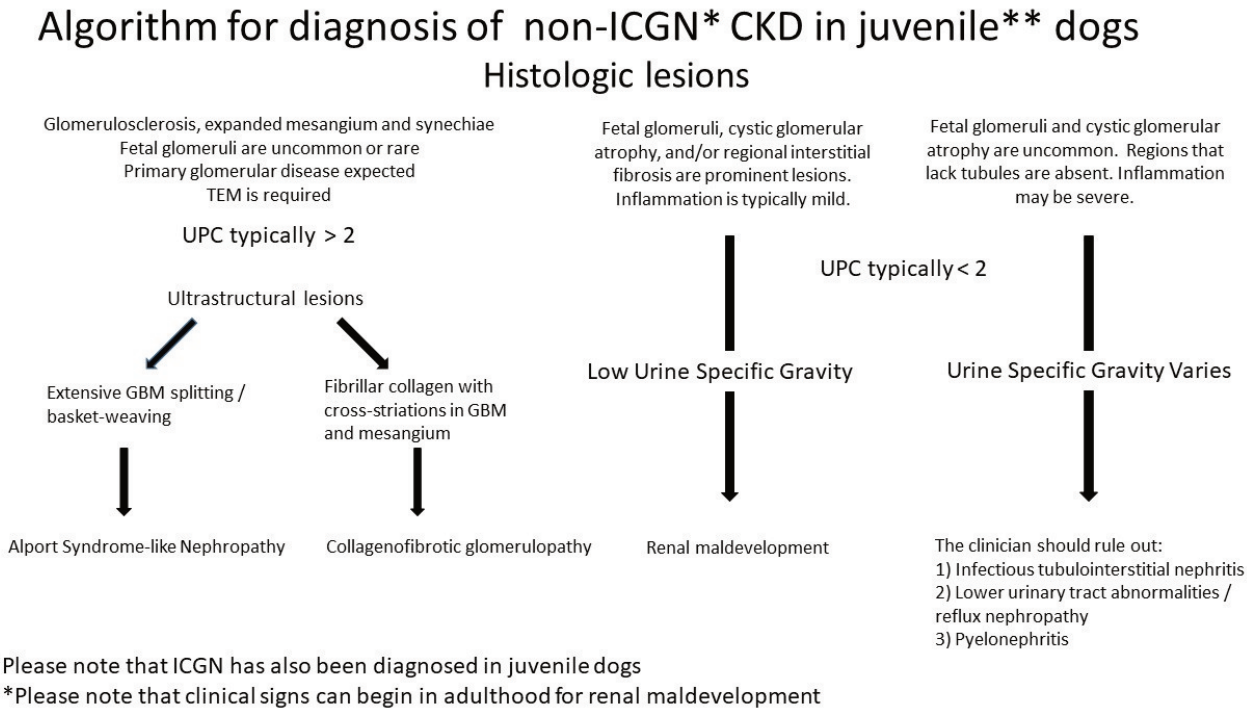

An interactive or media element has been excluded from this version of the text. You can view it online here:
https://ohiostate.pressbooks.pub/vetrenalpathatlas/?p=907

The authors would like to especially thank two collaborating veterinarians, Dr Rachel Lavoué, an internist at the University of Toulouse, France and Dr Guy Grinwis, a pathologist at Utrecht University, who both provided case material for this chapter.

Miscellaneous Glomerular Diseases

In addition to the common causes of proteinuric kidney disease in dogs, there are other patterns of glomerular injury that are rare or insufficiently characterized. With time, we hope to develop standardized criteria for diagnosis of these diseases and better understand their pathogeneses. Some of these diseases still have clinical features based on what we have gleaned from our database of cases, whereas the rarity of other diseases have precluded our ability to report the relevant clinicopathologic data.

MESANGIOPROLIFERATIVE GLOMERULONEPHRITIS WITH IMMUNE COMPLEXES

- Glomerular disease characterized by frequent mesangial hypercellularity (>3 nuclei) and associated mesangial matrix expansion secondary to the presence of immune complex deposits that are themselves limited to mesangial zones. Diagnosis requires TEM and IF to verify the presence of the immune complexes.
- There is often segmental sclerosis observed on histology.

Cases with mesangial expansion and / or hypercellularity without identifiable immune complex deposits should be given a descriptive diagnosis of "Glomerulopathy characterized by mesangial cell proliferation."

Clinical Features

- Initial sign is typically moderate to marked proteinuria (UPC > 2), although median UPC is lower than most other categories of glomerular disease, and rare cases can have a UPC as low as 0.5. Dogs with mesangioproliferative GN are unlikely to have a UPC higher than ~15, and they are more likely to have normal serum albumin concentration compared with many of the other categories of glomerular disease.
- Dogs with mesangioproliferative GN are more likely to be non-azotemic at the time of biopsy than other categories of glomerular disease.
- While rare cases have been identified in dogs as young as 4 months of age, dogs <1 year of age are unlikely to have mesangioproliferative GN.
- No breed predisposition is currently recognized.

An interactive or media element has been excluded from this version of the text. You can view it online here:
https://ohiostate.pressbooks.pub/vetrenalpathatlas/?p=408

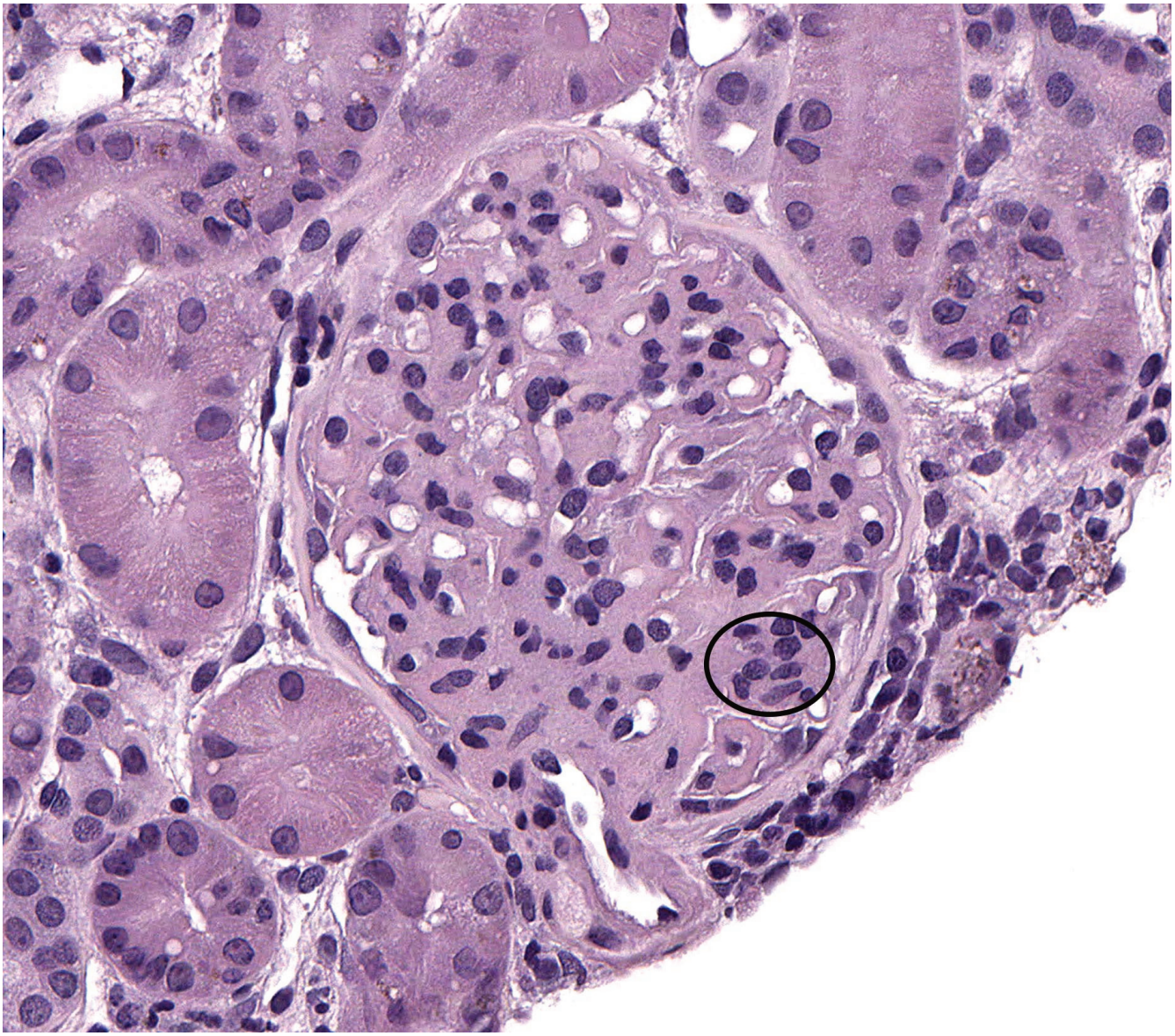

FIG.1A (HE): Moderate mesangial cell hypercellularity (greater than 3 nuclei in close apposition) within an expanded mesangial matrix (circled).

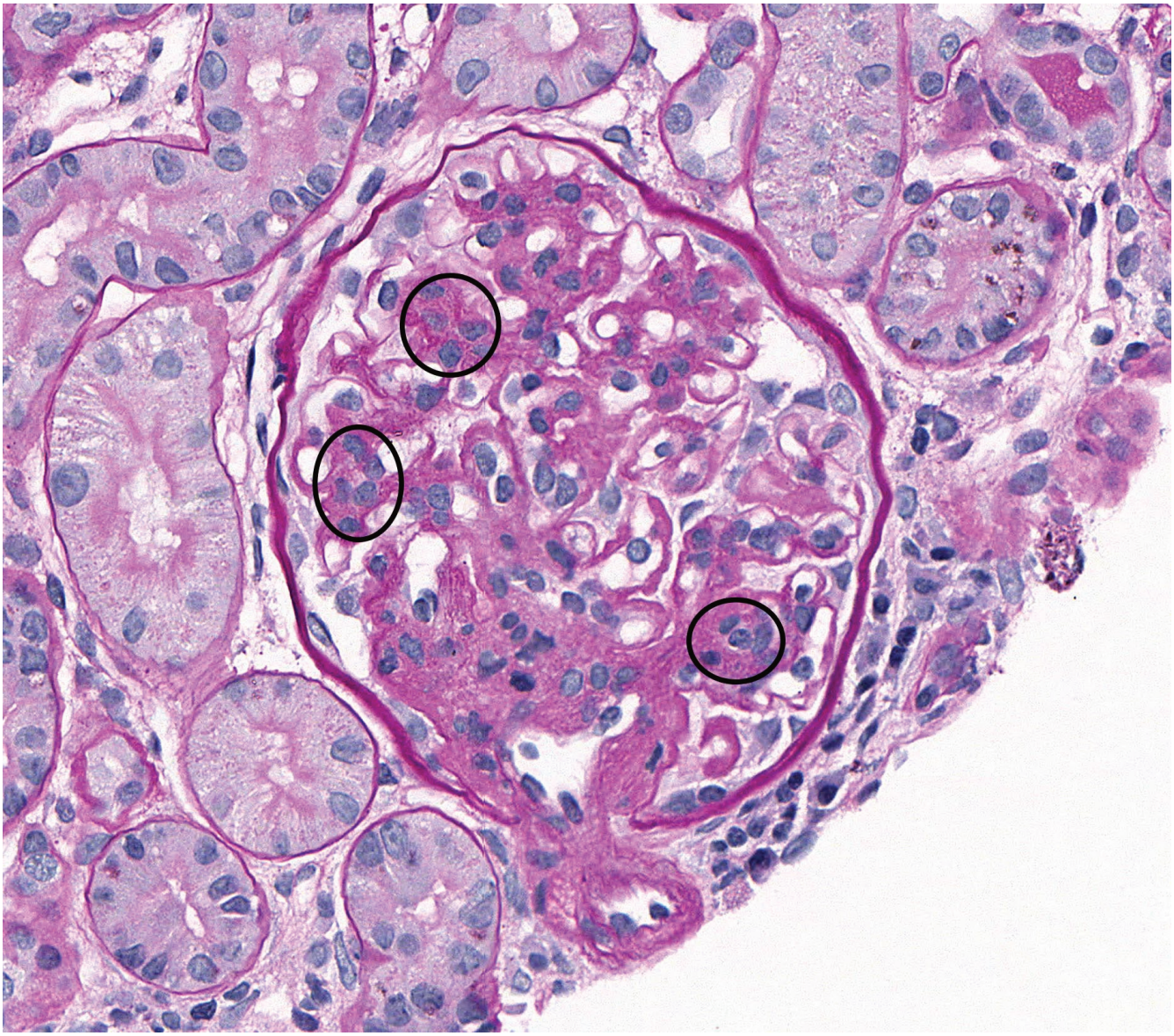

FIG.1B (PAS): Increased numbers of mesangial cells within an expanded matrix (circled).

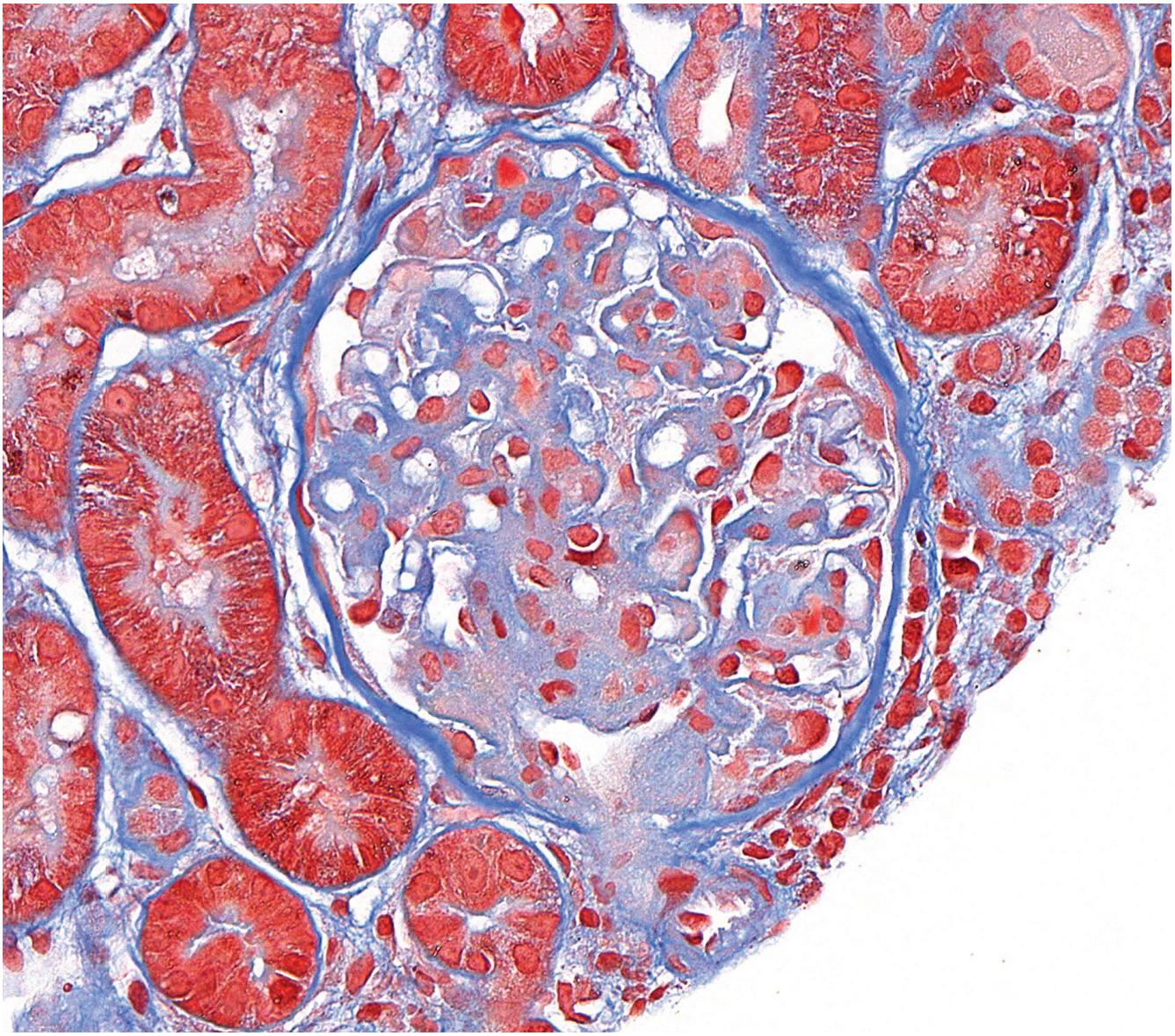

FIG.1C (MT): Mild to moderate mesangial cell hyperplasia with matrix expansion.

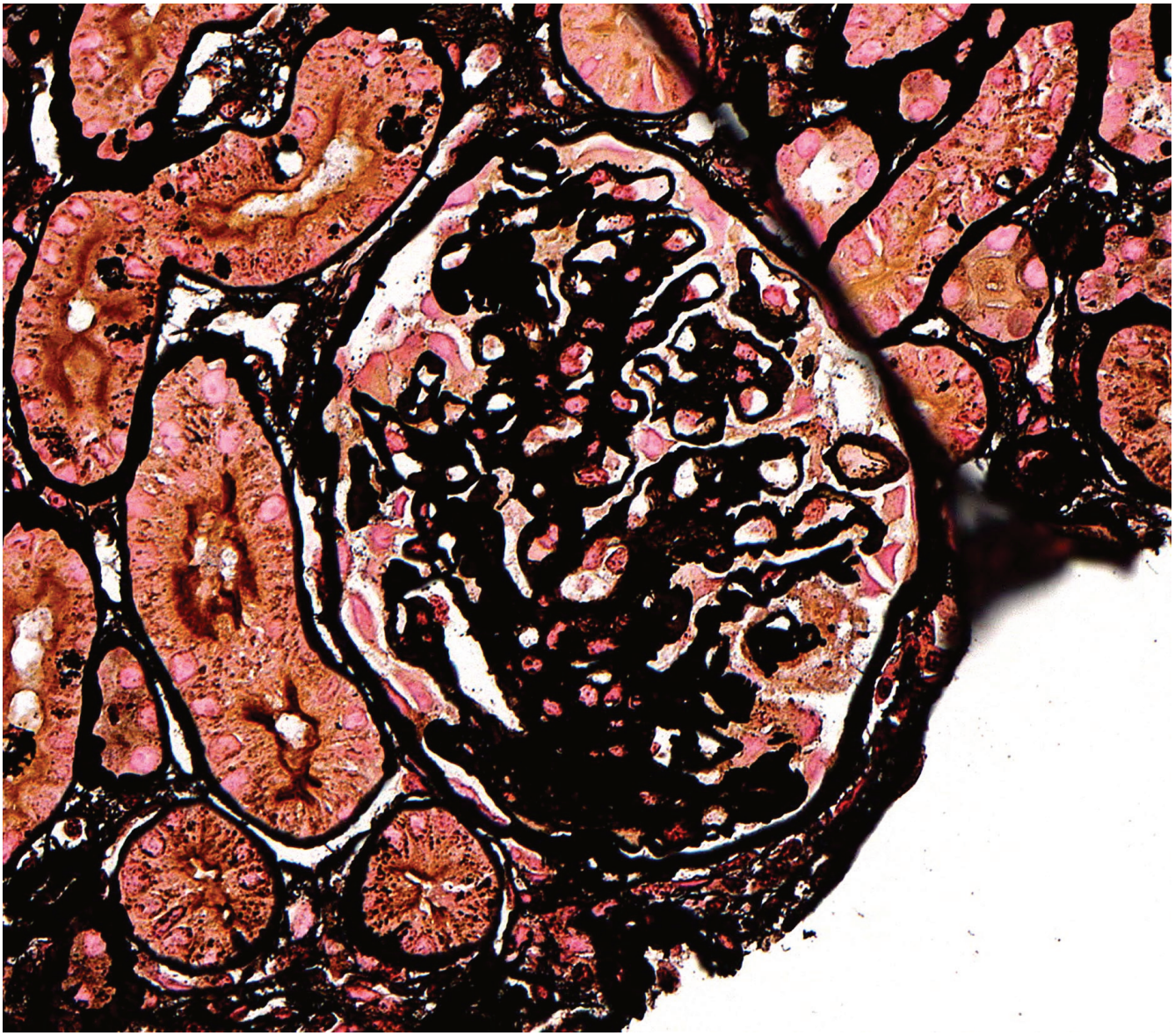

FIG.1D (JMS): The GBM is irregularly thickened. Please note that this JMS stain is dark due to prolonged time in silver.

An interactive or media element has been excluded from this version of the text. You can view it online here:
https://ohiostate.pressbooks.pub/vetrenalpathatlas/?p=408

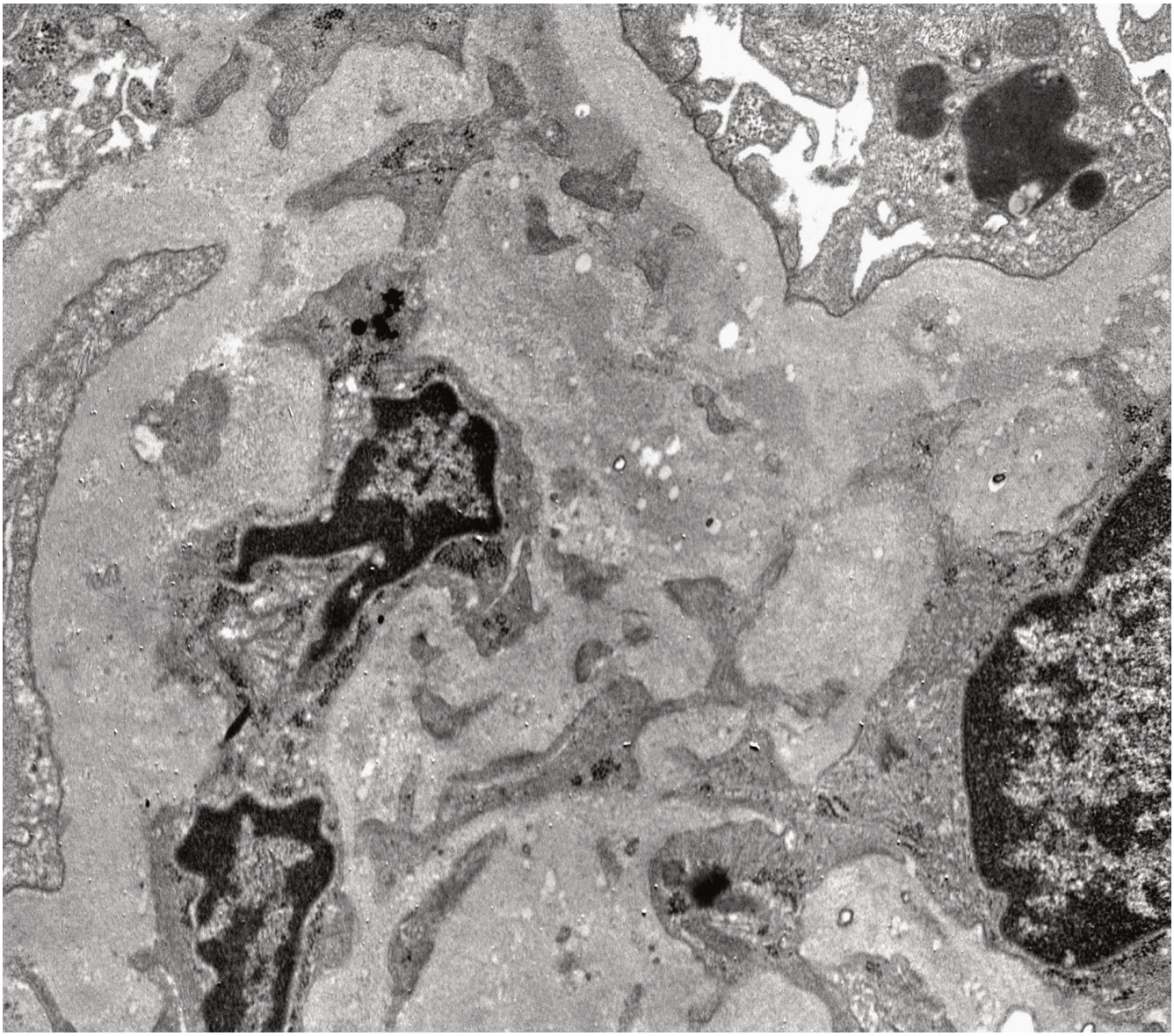

FIG.1E (TEM): Portions of 3 mesangial cell nuclei in close appostion (mesangial hyperplasia). Note multiple electron dense deposits withih the mesangial area, often just beneath the GBM (paramesangial).

An interactive or media element has been excluded from this version of the text. You can view it online here:
https://ohiostate.pressbooks.pub/vetrenalpathatlas/?p=408

FIG.1F (TEM): Colorized version of above TEM image with electron dense deposits (black) between the mesangial matrix (blue) and the paramesangial GBM (green). The podocytes are pink.

MINIMAL CHANGE DISEASE (Minimal change glomerulopathy)

- Minimal change disease is an uncommon (in dogs), acquired, potentially reversible, podocytopathy. May be drug-induced (reported in dogs given the tyrosine kinase inhibitor masitinib), idiopathic, or presumed immune-mediated (steroid responsive MCD in children).
- Characterized by relatively normal (hence the name) glomeruli via light microscopy and absence of specific tubulointerstitial or vascular lesions. The detection of glomerular changes and final diagnosis require TEM that will show global podocyte foot process effacement.
- Affected dogs are markedly proteinuric. Azotemia has been rarely reported due to presumed associated acute tubular necrosis.

An interactive or media element has been excluded from this version of the text. You can view it online here:
https://ohiostate.pressbooks.pub/vetrenalpathatlas/?p=408

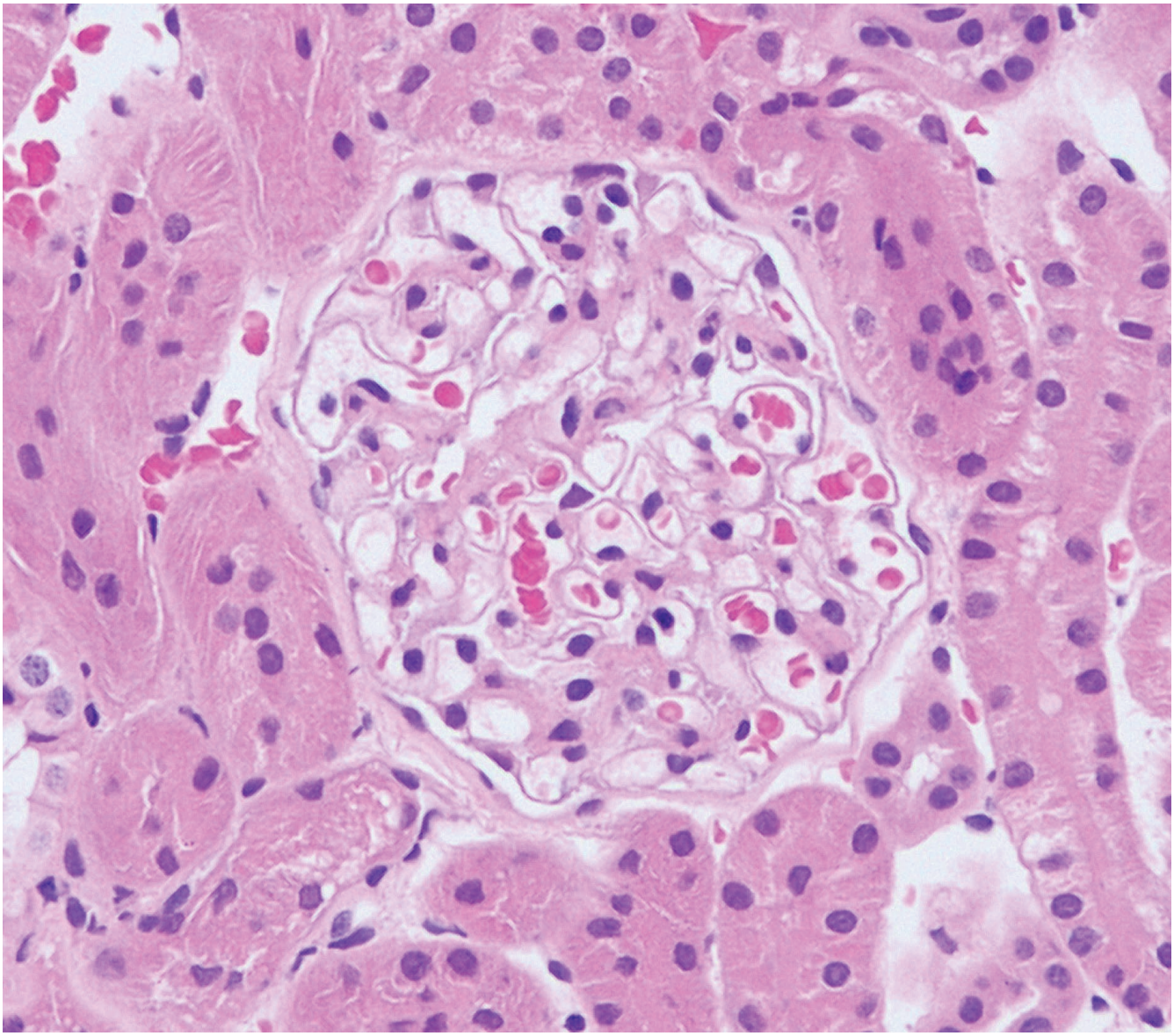

FIG.2A (HE): The glomerulus is normocellular.

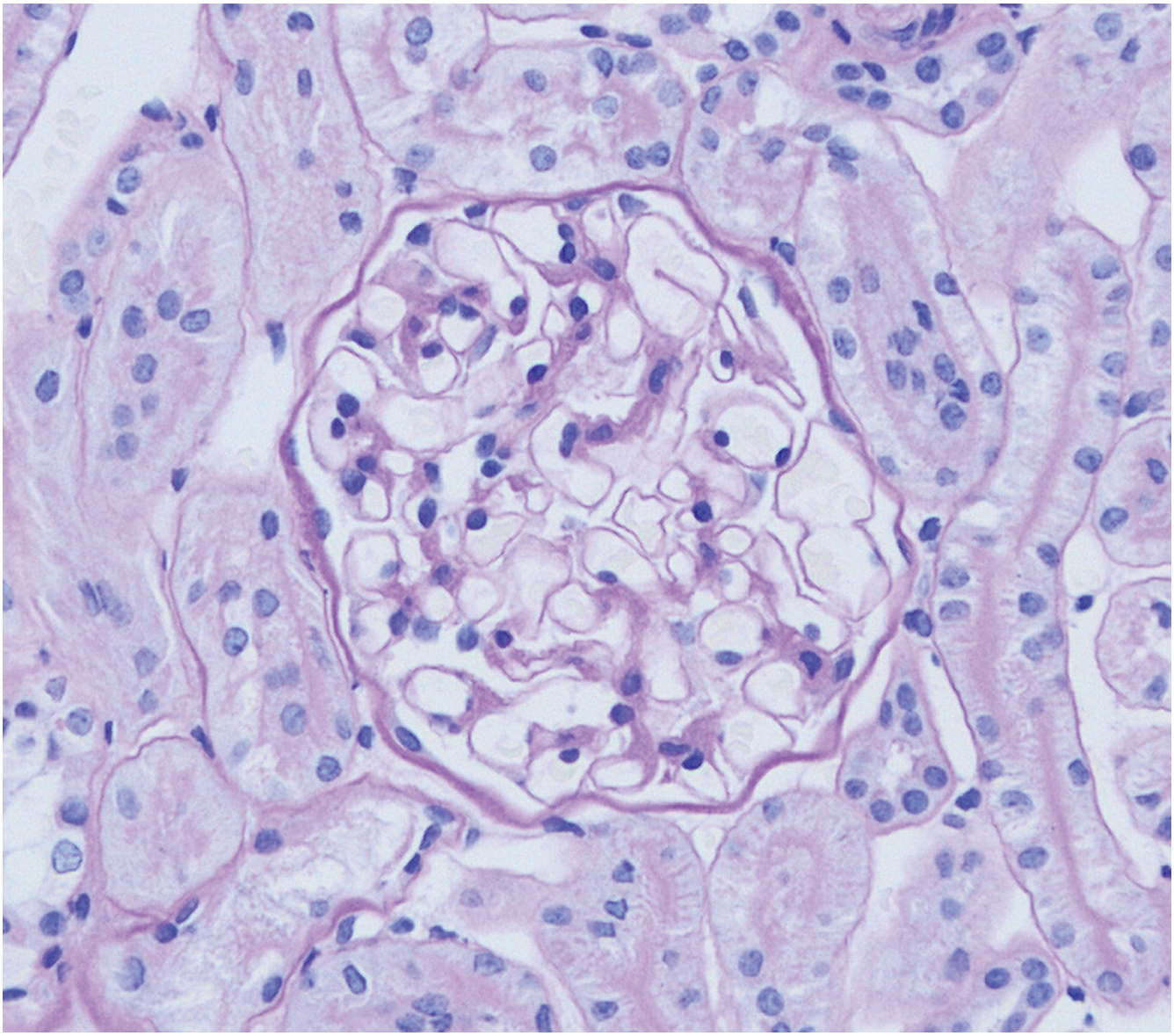

FIG.2B (PAS): The glomerulus is normocellular and the mesangium and GBM are unremarkable.

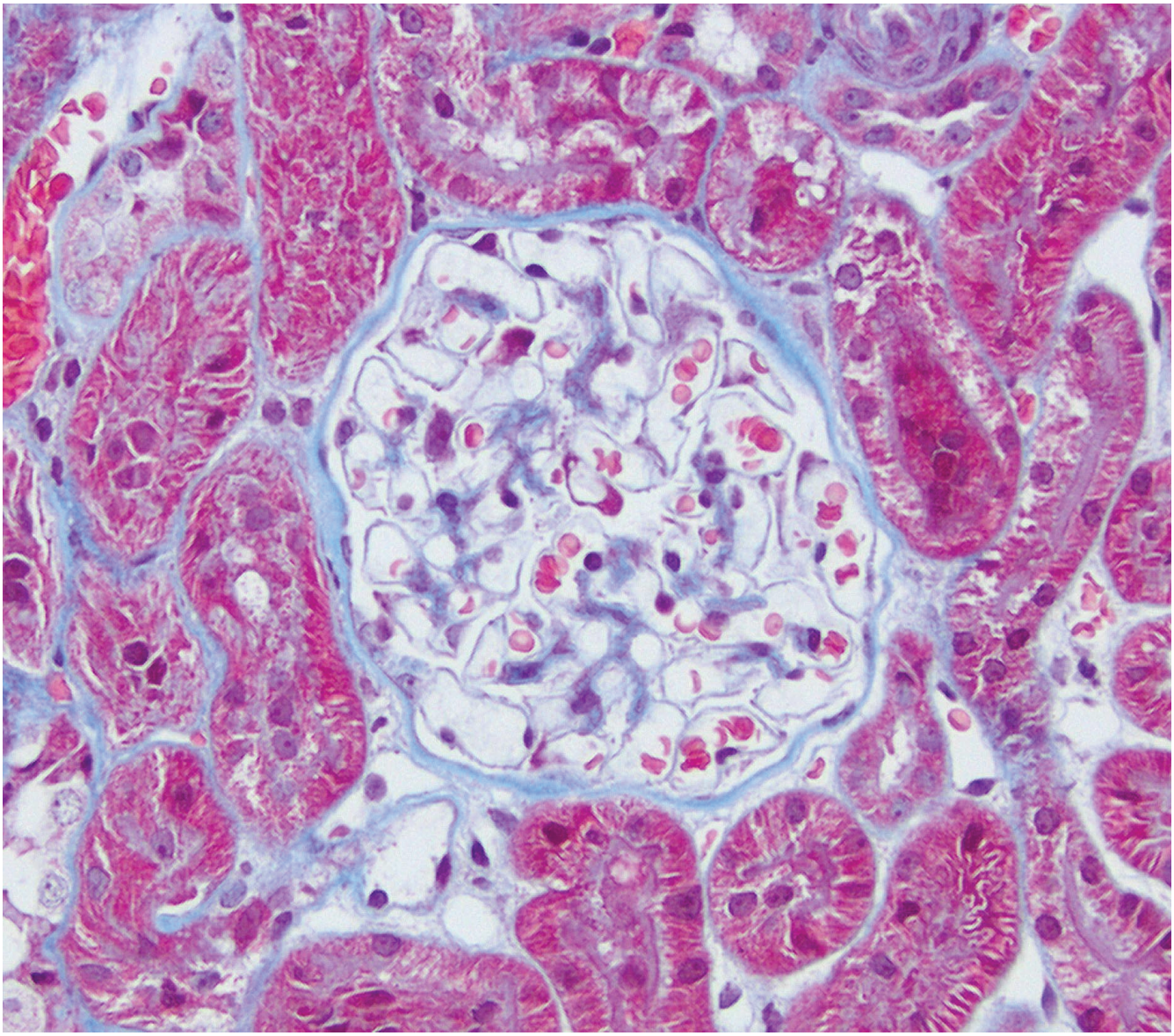

FIG.2C (MT): The glomerulus is histologically normal. Fuschinophilic (red) deposits are not osberved. The GBM is thin and uniform, the mesangium is normal, and there is no fibrosis in the surrounding interstitium.

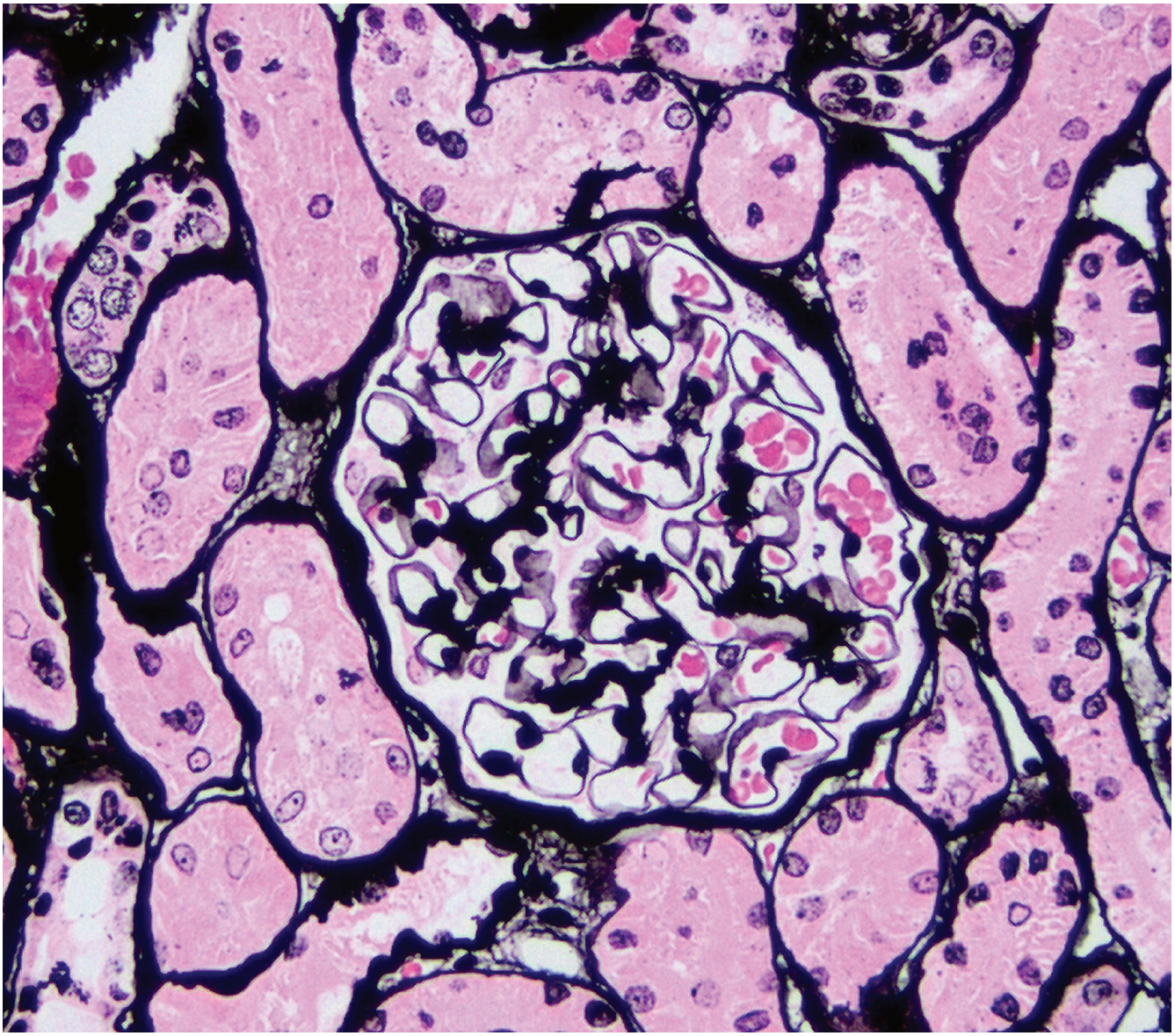

FIG.2D (JMS): Capillary walls are of normal thickness; there is no evidence of GBM remodeling.

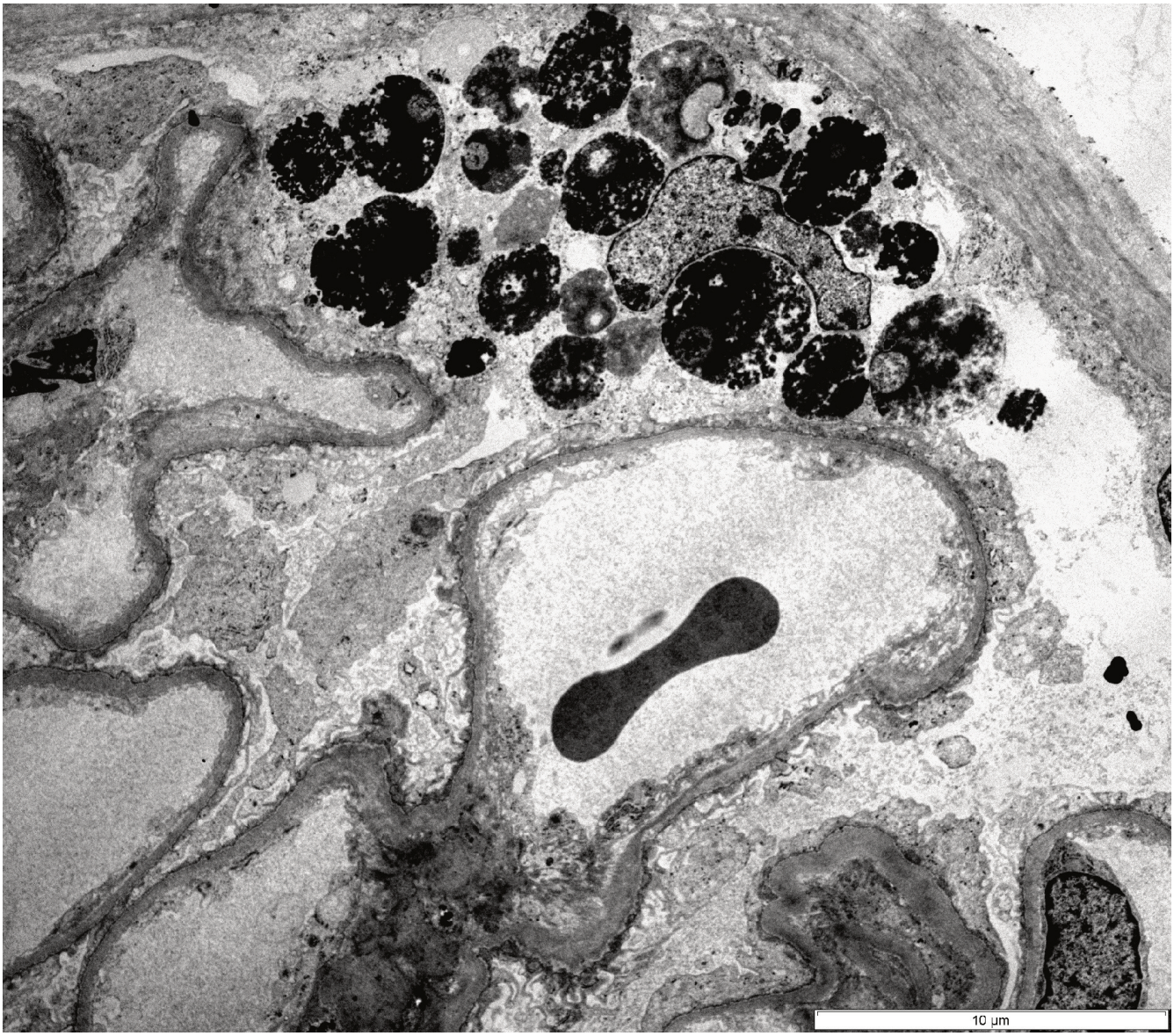

FIG.2E (TEM): Ultrastructural evidence of diffuse and global podocyte injury is present. In this case, one podocyte contains large electron dense lysosomes, and although difficult to appreciate at this low magnification, all podocytes exhibit foot process effacement.

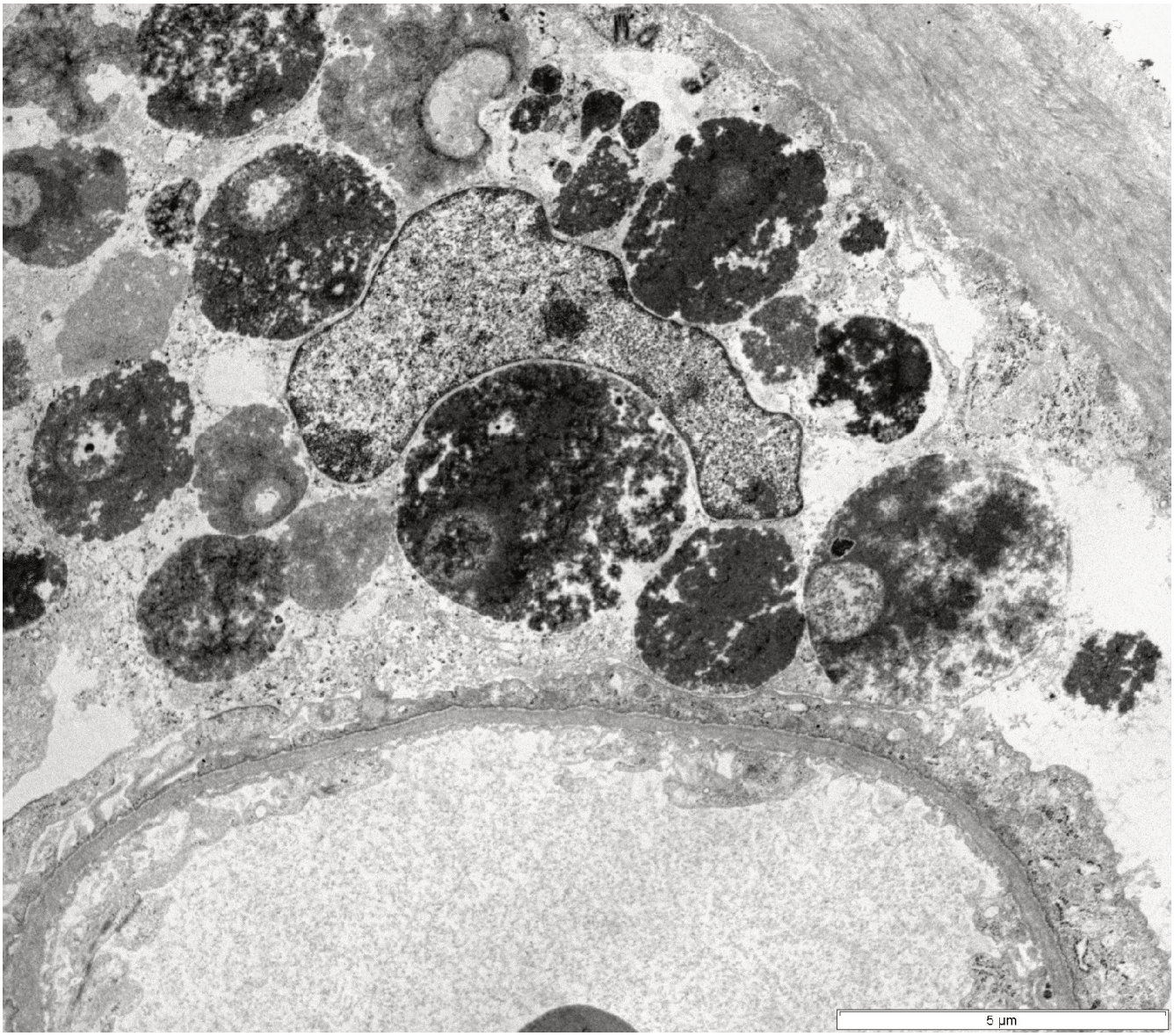

FIG.2F (TEM): Severe podocyte injury with foot process effacement, protein resorption droplets, and cell lysis. The endothelium is unremarkable, and neither electron dense deposits nor fibrils are evident.

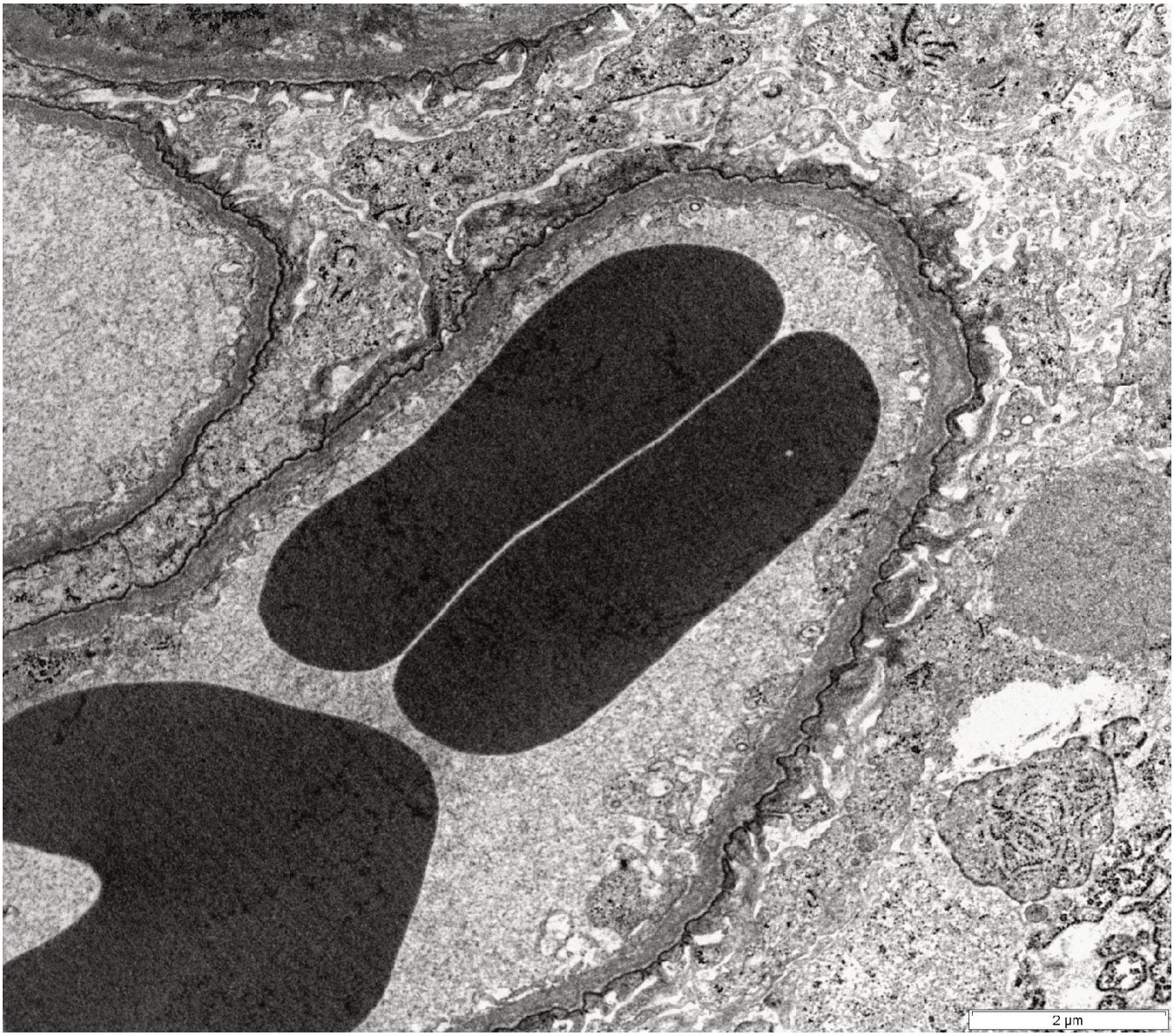

FIG.2G (TEM): There is diffuse foot process effacement. Podocytes are hypertrophied, with podocyte cytoplasm filling Bowman's space.

GLOMERULAR LIPIDOSIS

- Presence of large "foamy" cells found in one or multiple lobules of the glomerular tufts. The foamy appearance is given by the presence of intracytoplasmic vacuole that are sudanophilic (lipid material) but are clear with other routine staining (HE, PAS, MT and JMS).
- The origin of the cells is unknown but mesangial and endothelial origin has been proposed.
- Historically thought to be an incidental finding not affecting the glomerular function. A more severe disease is presumed if the lesion is detected in many glomeruli and if the glomerular architecture is severely effaced.
- Sometimes detected as sole lesion in proteinuric dogs.

An interactive or media element has been excluded from this version of the text. You can view it online here:
https://ohiostate.pressbooks.pub/vetrenalpathatlas/?p=408

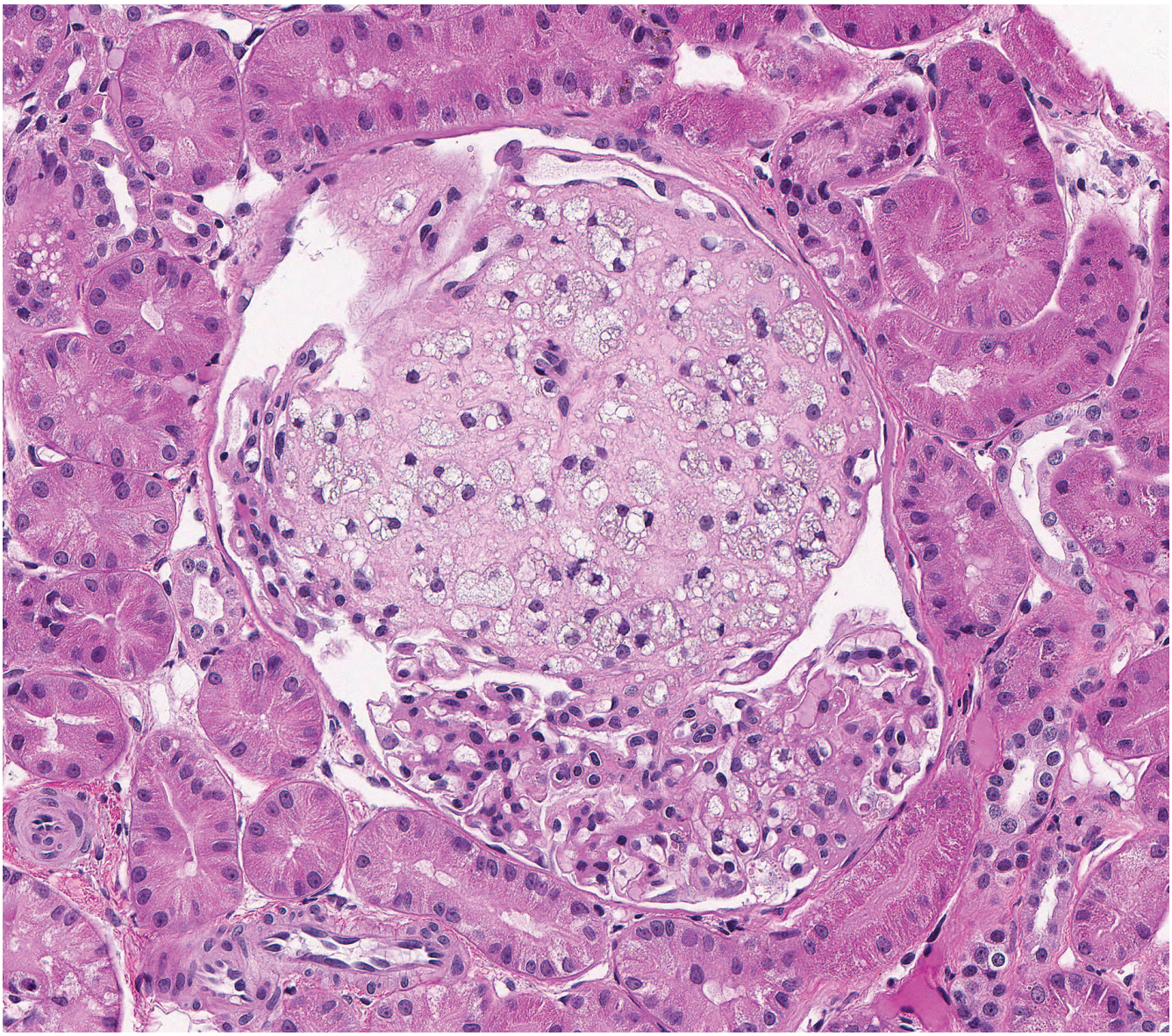

FIG.3A (HE): The glomerular tuft architecture is segmentally distorted and effaced with large “foamy” cells.

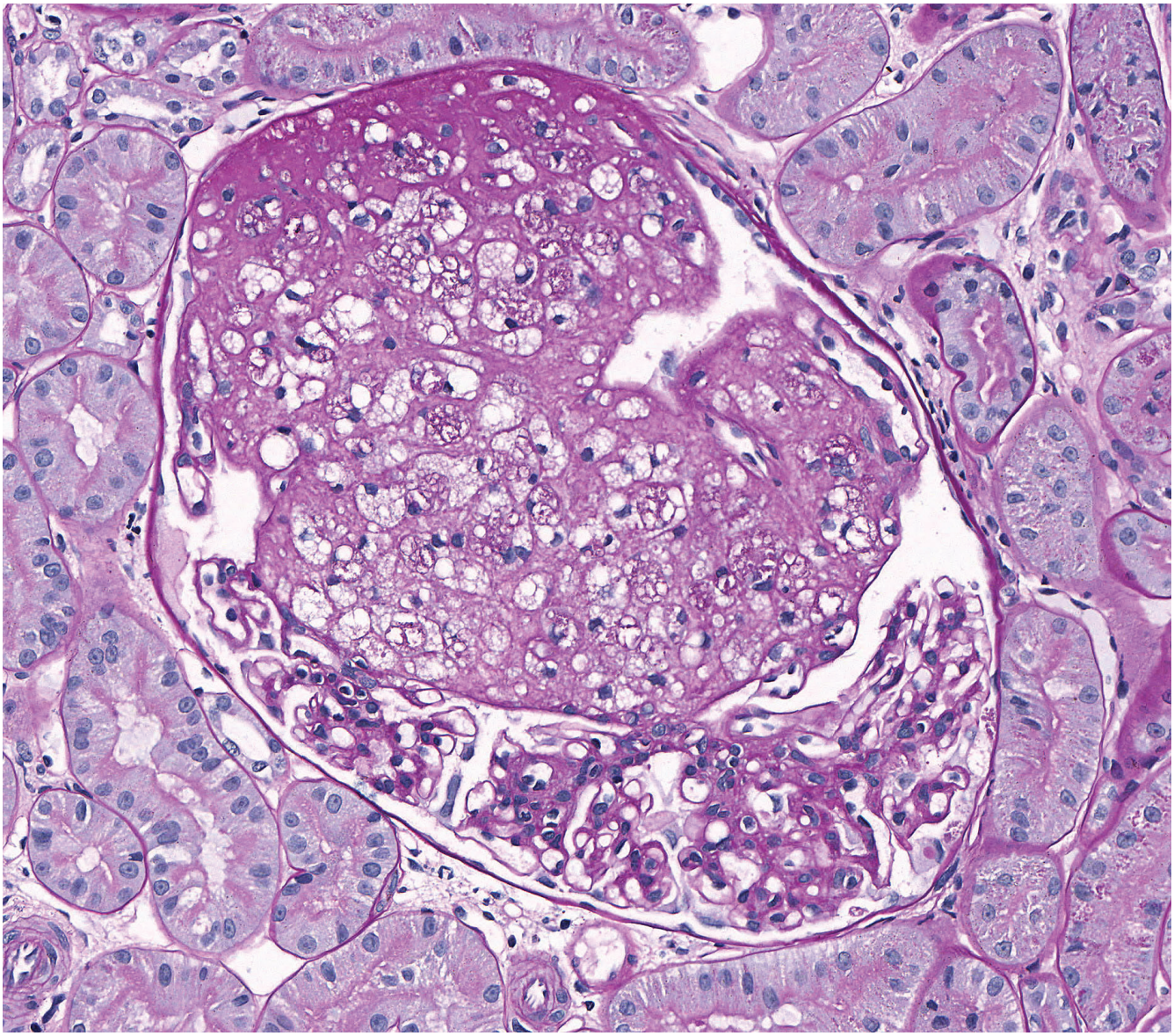

FIG.3B (PAS): The glomerular tuft architecture is segmentally distorted and effaced with large “foamy” cells. the remainder of the tuft appears fairly normal but compressed.

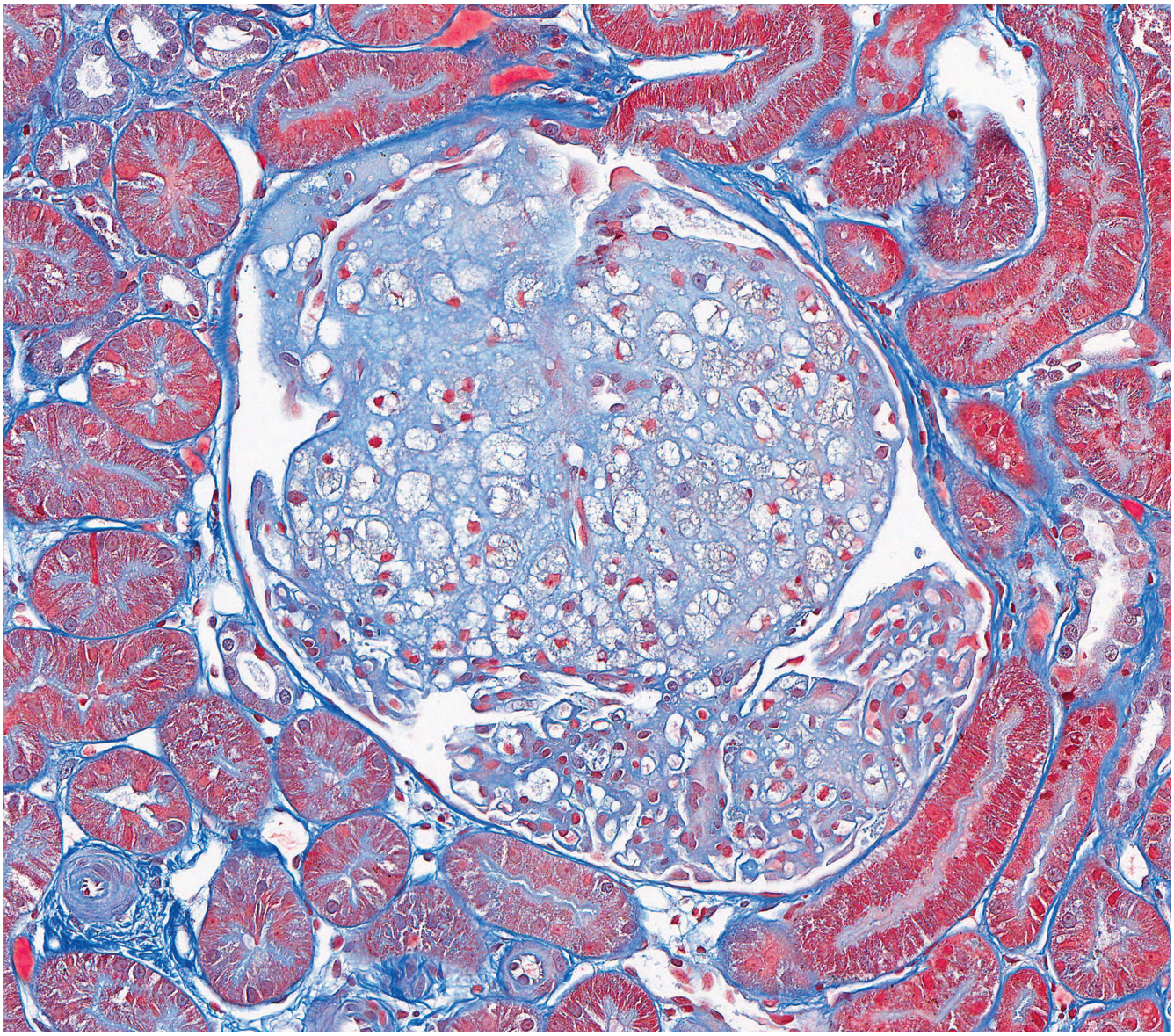

FIG.3C (MT): The glomerular tuft architecture is segmentally distorted and effaced with large “foamy” cells.

FIG.3D (JMS): The glomerular tuft architecture is segmentally distorted and effaced with large "foamy" cells. The capillary walls of the remaining portion of the glomerulus are of normal thickness and have a smooth contour.

THROMBOTIC MICROANGIOPATHY

- Lesions of renal thrombotic microangiopathy (TMA) are due to endothelial injury of glomerular capillaries and arterioles, which can manifest clinically as acute kidney injury with microangiopathic hemolytic anemia and thrombocytopenia. Microangiopathic hemolytic anemia is a condition in which erythrocytes are damaged and destroyed when traveling through small vessels. This damage can be due to small intravascular fibrin thrombi (as can occur in Disseminated Intravascular Coagulation) or due to severe endothelial damage from toxin exposure (e.g. envenomation), infection, immune-mediated (both complement system and antibody mediated) and severe acute hypertension, among other causes. Renal TMA is

rare and is characterized primarily by injury to glomerular capillaries and afferent arterioles with occasional inclusion of larger arteries. Canine diseases that include this lesion are few but can be seen in cases of severe hypertension, hemolytic-uremic syndrome, and most notably in idiopathic cutaneous and renal glomerular vasculopathy (CRGV). CRGV has been documented in racing greyhounds in the US and a variety of other breeds in the UK. Affected dogs present with cutaneous ulceration of the distal limbs, thrombocytopenia and acute kidney injury. Additionally, because of the association between TMA and acute hypertension, TMA lesions can be superimposed on other types of renal diseases such as immune complex mediated membranoproliferative glomerulonephritis. In these scenarios, both diseases should be diagnosed (for example: immune complex mediated MPGN with superimposed TMA) because the clinician should be aware that they are dealing with 2 types of processes.

- Light microscopic findings in cases of canine renal TMA might include:
    - Endothelial swelling with narrowing of capillary lumens.
    - Intra-capillary thrombi.
    - Fragmented erythrocytes (schistocytes)
    - Hyalinization and fibrinoid necrosis of afferent and intralobular arterioles and arteries.
    - With progression there may be duplication of the glomerular basement membrane seen as double contours with silver stain. IF studies are consistent with non-specific staining.
- Ultrastructural findings might include:
    - Endothelial swelling.
    - Detachment from the underlying basement membrane and necrosis.
    - Capillary lumens might contain platelets, fibrin, and cellular fragments.
    - In acute TMA, there is extensive subendothelial lucency of the glomerular basement membrane. Although this latter lesion has been documented in humans and dogs, it is rarely seen because the acute stages are often missed.
    - Chronically, there might be mesangiolysis and mesangial cell interpositioning with basement membrane duplication.
    - In scenarios where TMA is the only disease process, electron dense deposits consistent with immune complexes are not present; however, if TMA is secondary to ICGN and hypertension, it is possible to observe electron dense deposits as well as TMA lesions in the EM specimen.

An interactive or media element has been excluded from this version of the text. You can view it

online here:
https://ohiostate.pressbooks.pub/vetrenalpathatlas/?p=408

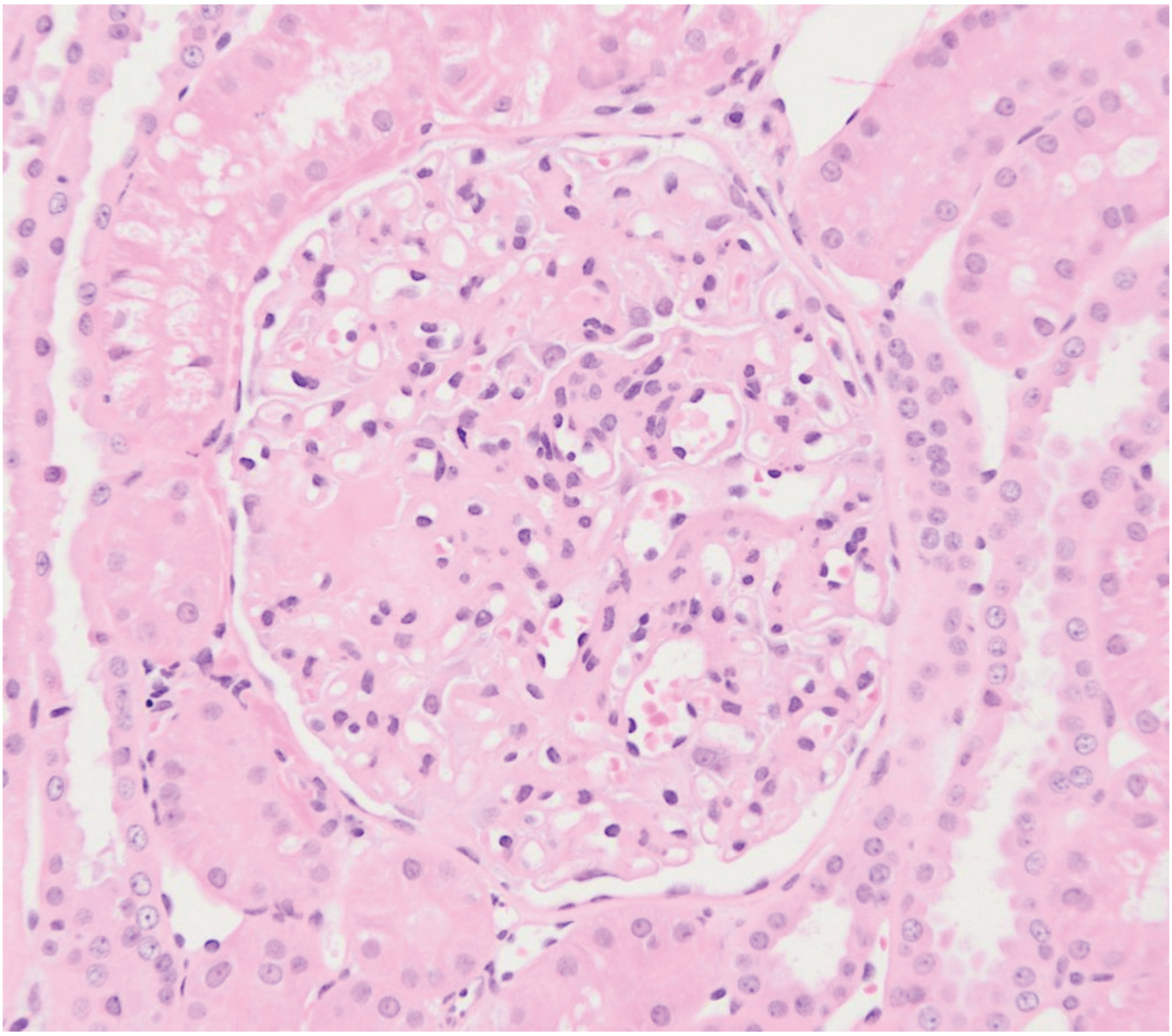

FIG.4A (HE): There is segmental eosinophilic hypocellular expansion of the mesangium which cannot be easily differentiated from a small amount of proteinaceous fluid in Bowman's space. Of note, only a small proportion (~10%) of the glomeruli in the sample had similar lesions; the remaining majority of the glomeruli appeared histologically normal.

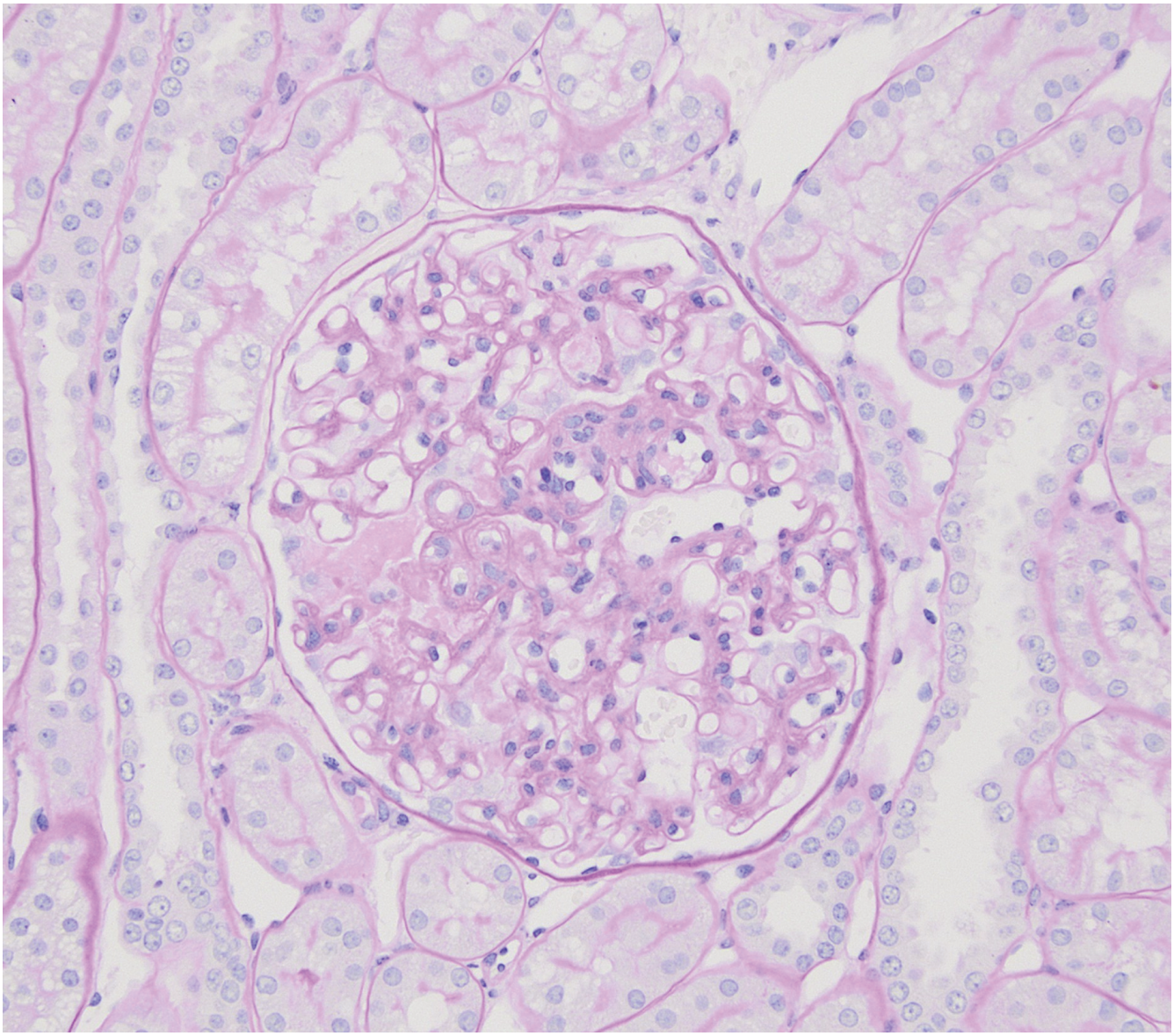

FIG.4B (PAS): This stain allows differentiation of the proteinaceous fluid in Bowman's space from the expanded mesangium. Additionally in the same region of the tuft, the capillary loops are multi-laminated, whereas they have a normal contour in the rest of the glomerulus.

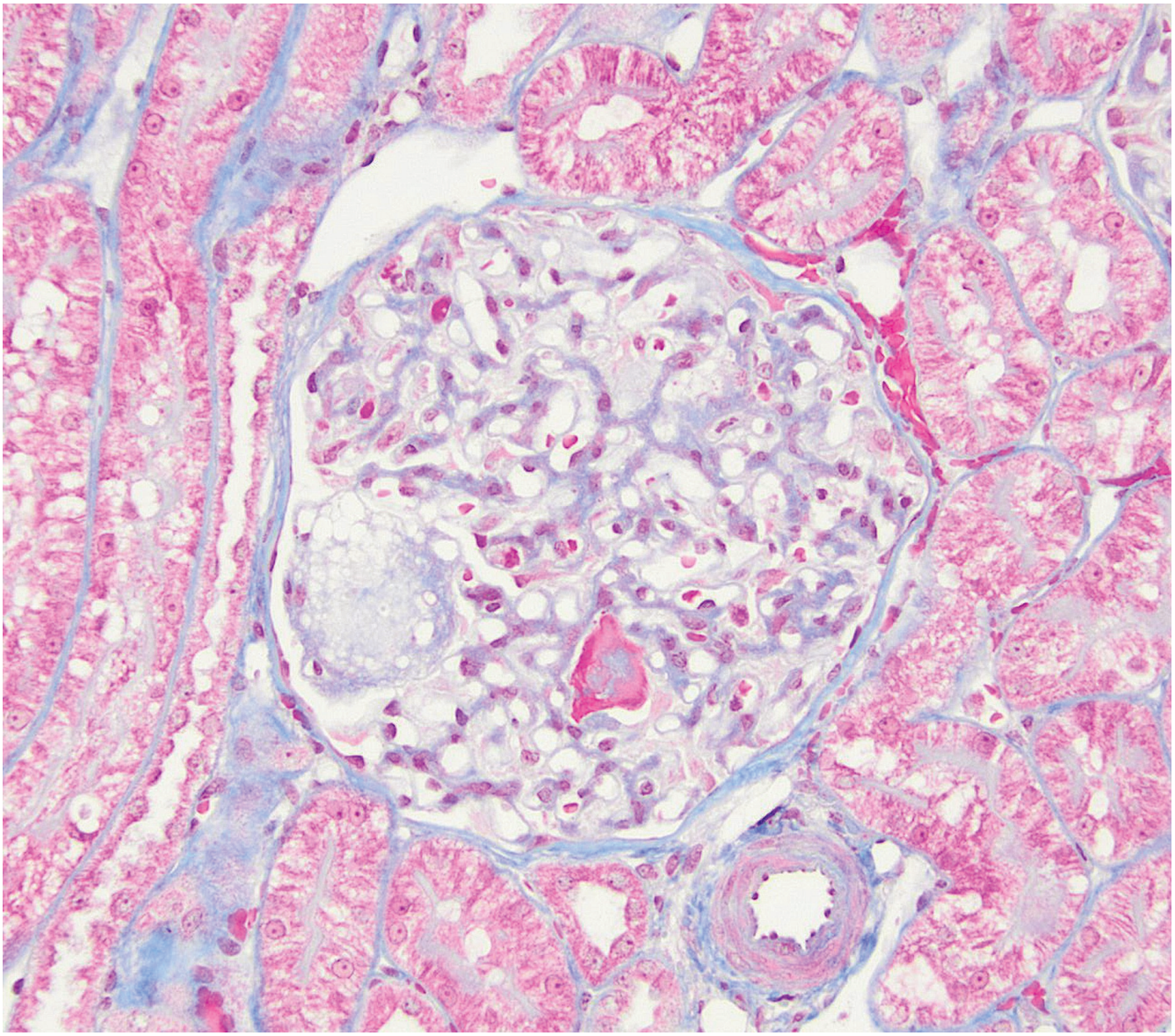

FIG.4C (MT): This stain highlights the hazy blue lucency of the mesangium (mesangiolysis) in a region of the tuft that still has patent peripheral capillary loops. Another region of proteinaceous fluid (central blue encircled by red material) is present at this level of section.

FIG.4D (JMS): Similar to the PAS stain, the JMS method highlights the double contouration of the capillary walls and separates this lesion from the proteinaceous fluid in Bowman's space.

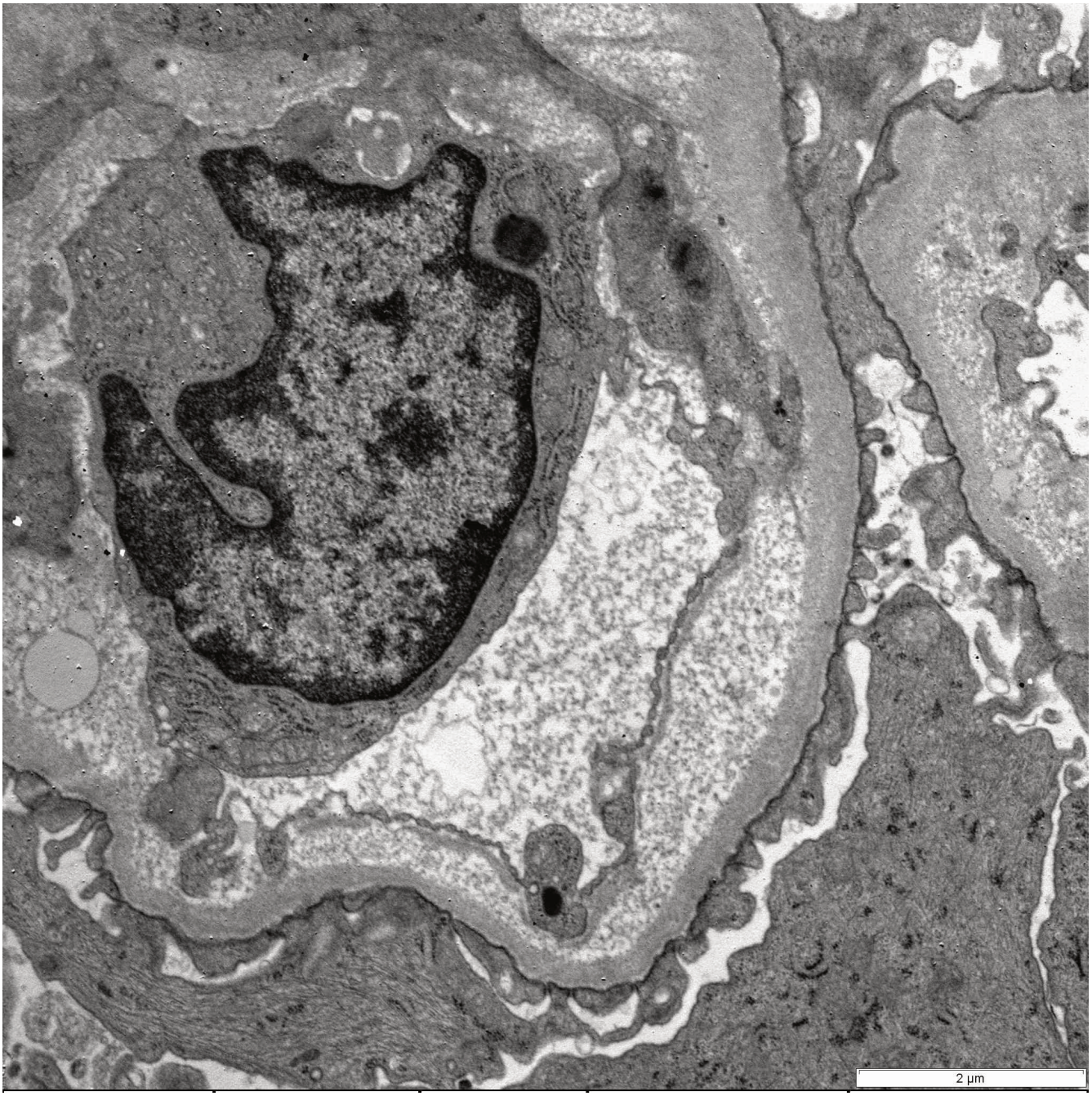

FIG.4E (TEM): There is subendothelial expansion of the glomerular basement membrane by relatively electron lucent flocculent material. The endothelial cell is swollen and the capillary lumen is compressed. Endothelial fenestrations are present in this TEM image. In acute TMA lesions, there can be loss of endothelial cell cytoplasm or of the fenestrations. Notably, even though there might only be a few glomeruli affected based on light microscopic appearance, there is more widespread damage based on ultrastructural evaluation, such that a randomly sampled glomerulus in the TEM sample demonstrated these lesions.

An interactive or media element has been excluded from this version of the text. You can view it online here:
https://ohiostate.pressbooks.pub/vetrenalpathatlas/?p=408

FIG.4F (TEM): Colorized version of above TEM. Green: GBM; Yellow: Endothelial cell; Pink: Podocyte; Blue: Mesangium.

An interactive or media element has been excluded from this version of the text. You can view it online here:
https://ohiostate.pressbooks.pub/vetrenalpathatlas/?p=408

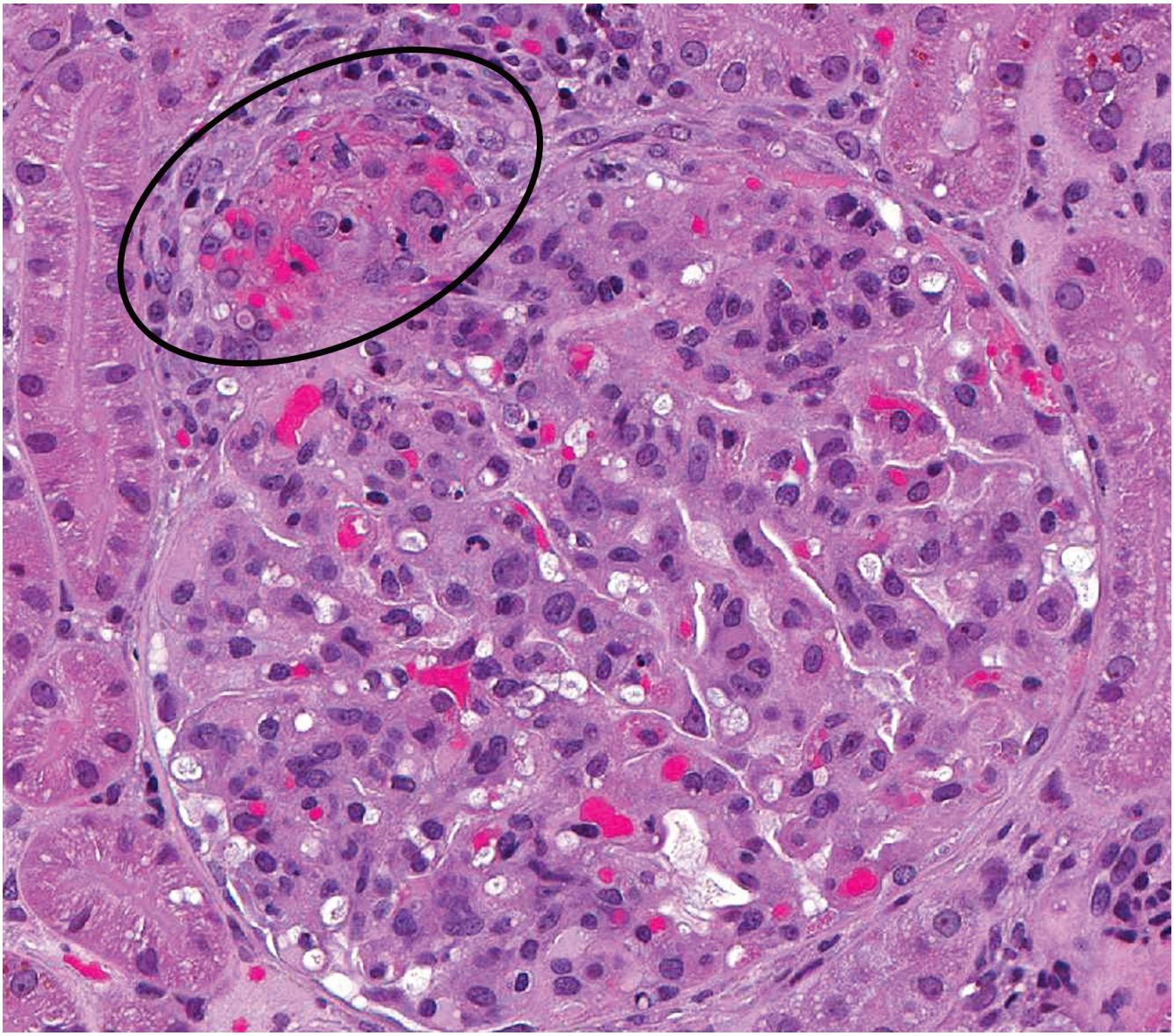

FIG.5A (HE): Thrombotic microangiopathic lesions can occur in patients that have underlying disease which might result in hypertension. In these scenarios, the vascular pole is usually affected (circled).

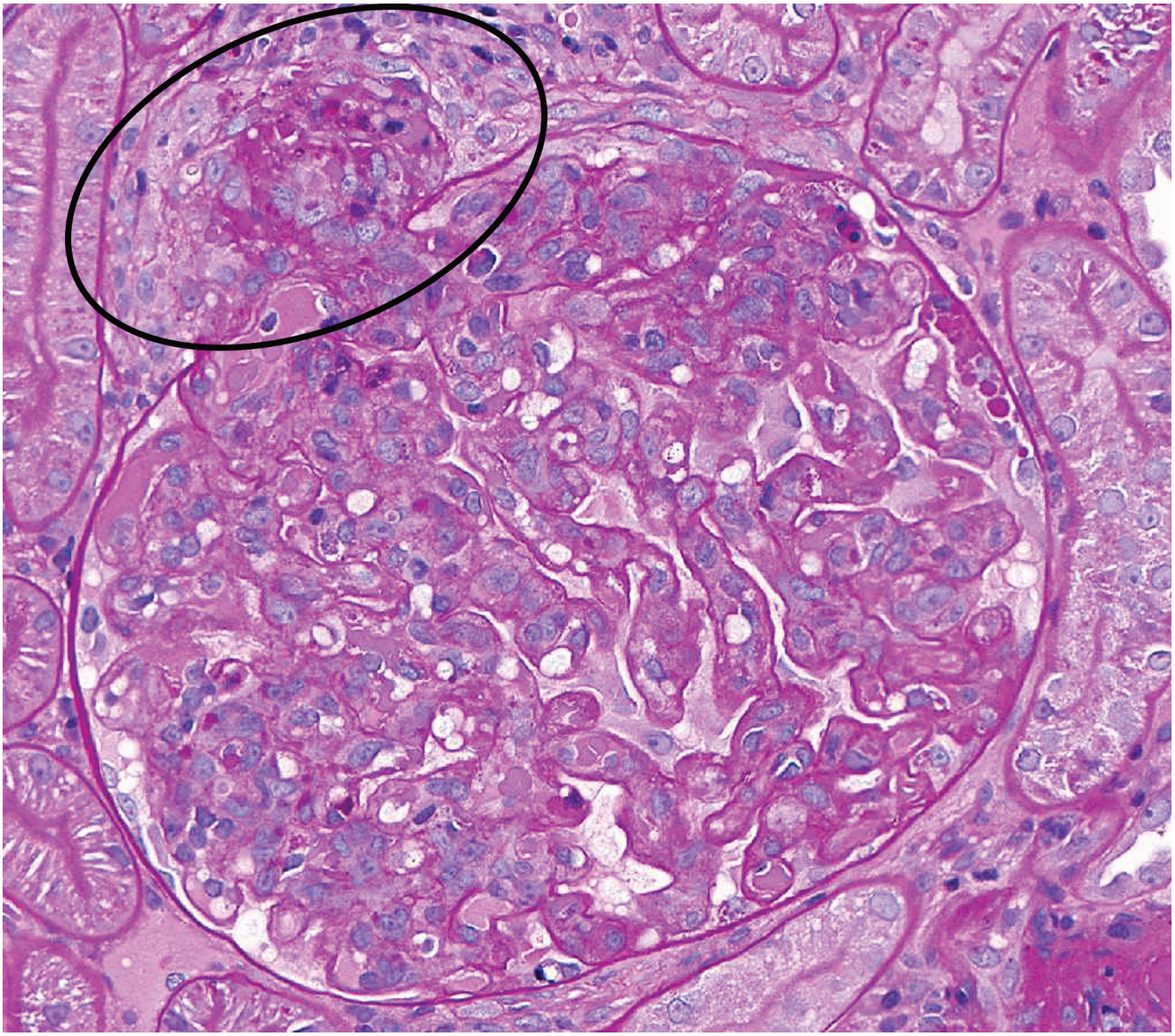

FIG.5B (PAS): In this stain, the fibrinoid degeneration of the arteriole is easily seen as fuschinophilic material in the wall (circled).

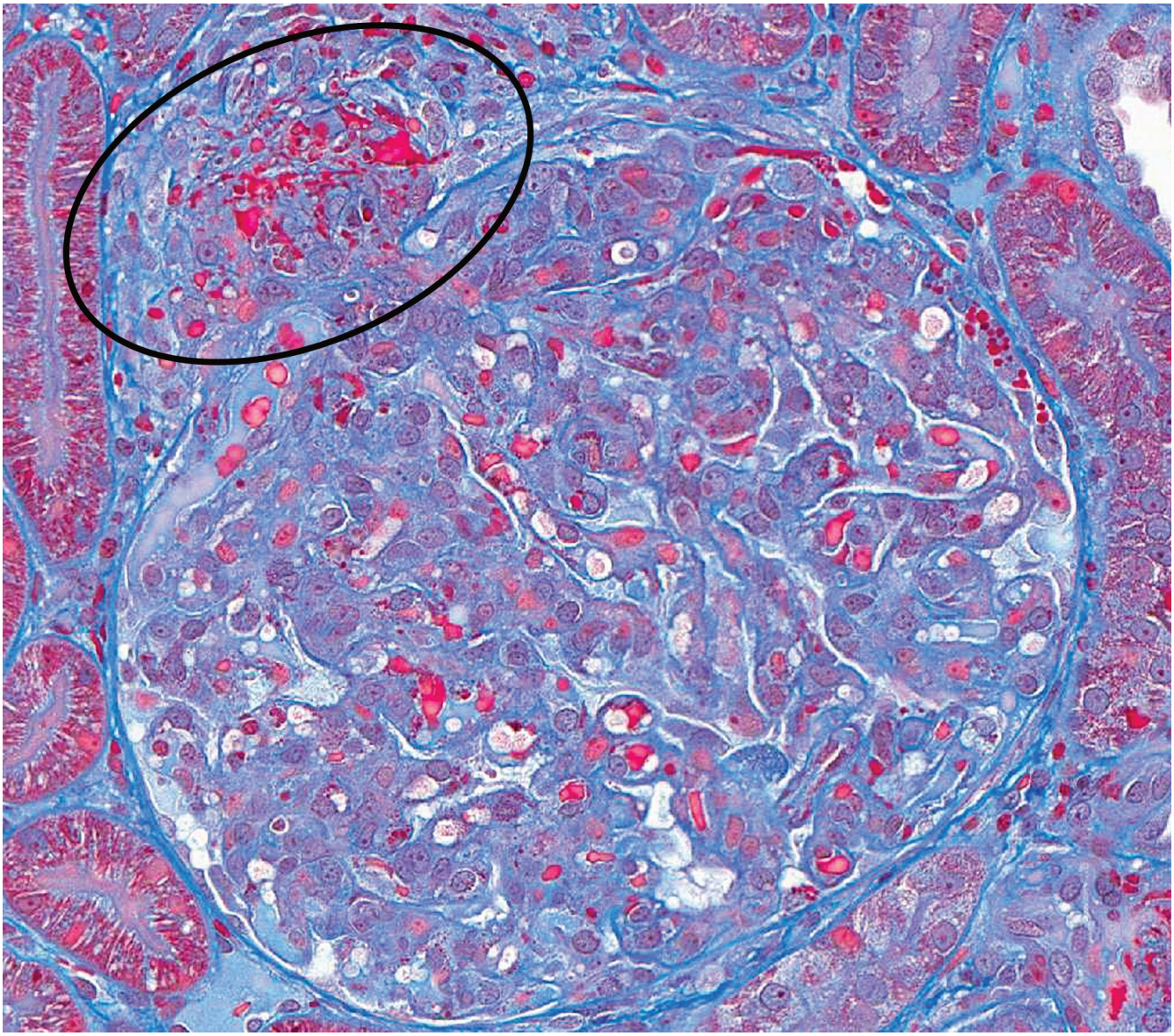

FIG.5C (MT): In this stain, the fibrinoid degeneration of the arteriole is easily seen as red material in the wall (circled). This stain also enable visualization of the fragmented red cells in the wall.

FIG.5D (JMS): In this stain, the fibrinoid degeneration of the arteriole is easily seen (circled).

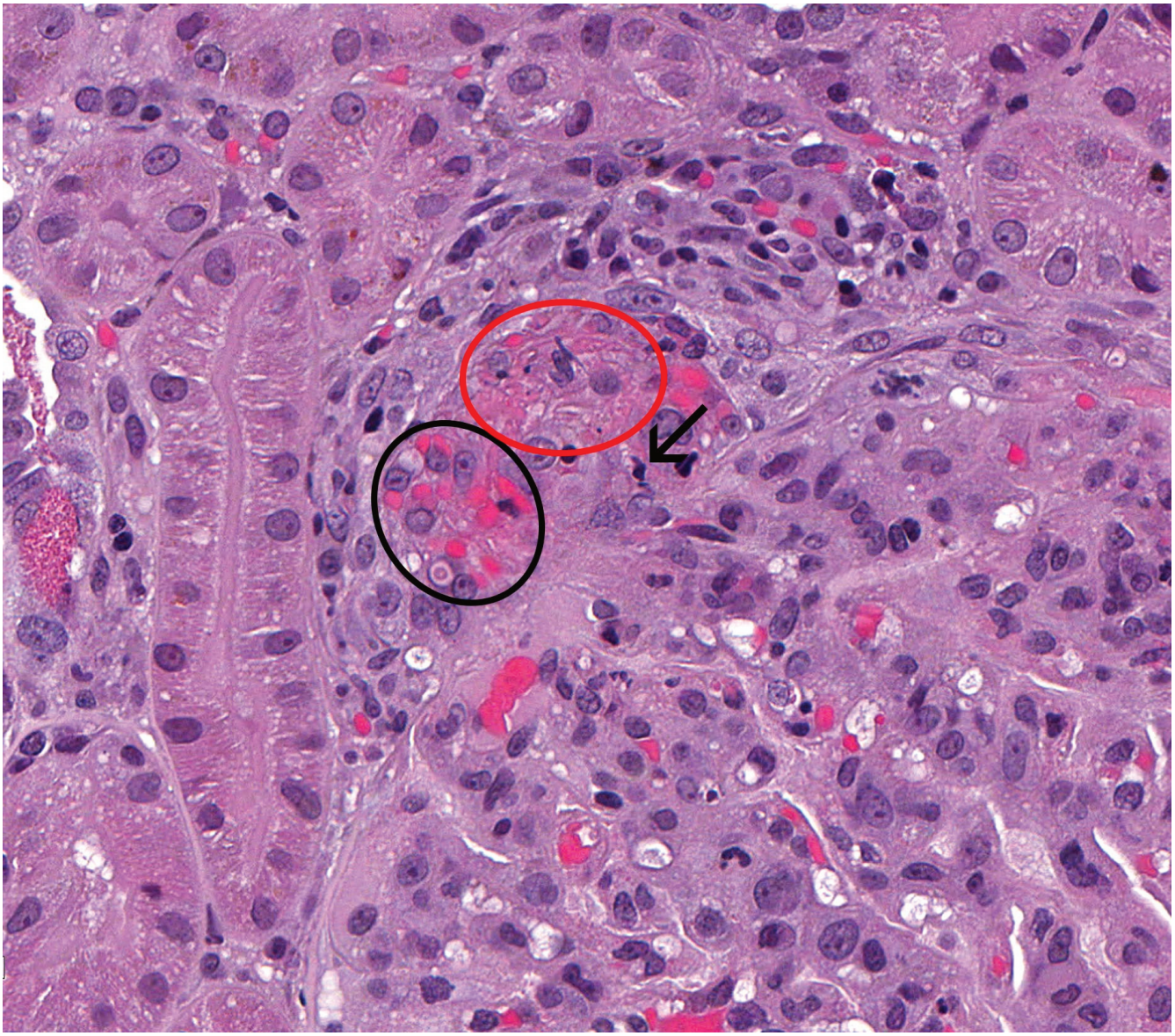

FIG.5E (HE): Higher magnification of FIG.5A. Erythrocytes have been pushed into the wall of the afferent arteriole (black circle) and there is fibrinoid degeneration of the artertiolar wall (red circle). Pyknotic nuclear debris is also present in the wall (arrow).

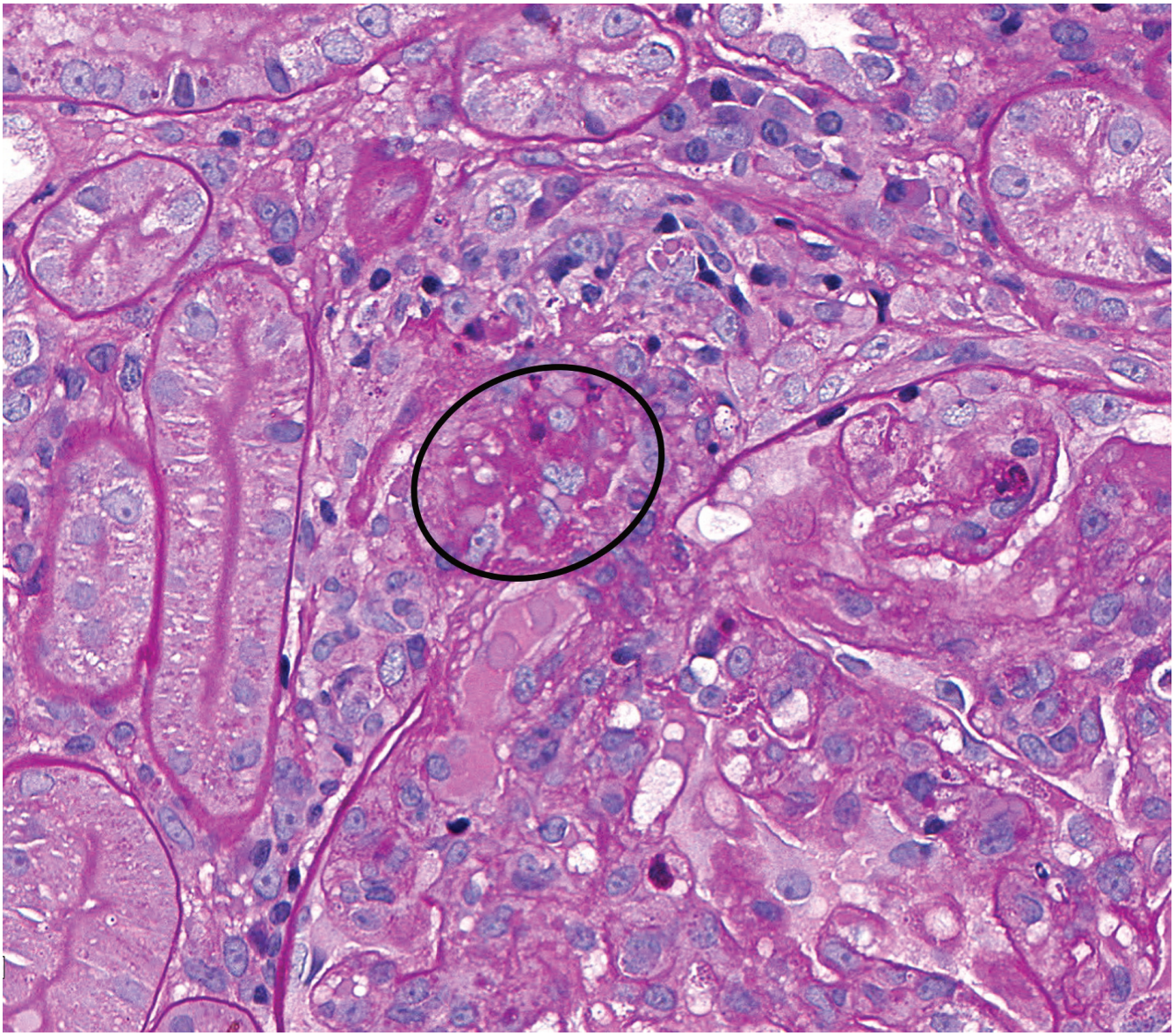

FIG.5F (PAS): Higher magnification of FIG.5B. In this stain, the fibrinoid degeneration of the arteriole is easily seen as fuschinophilic material in the wall (circled).

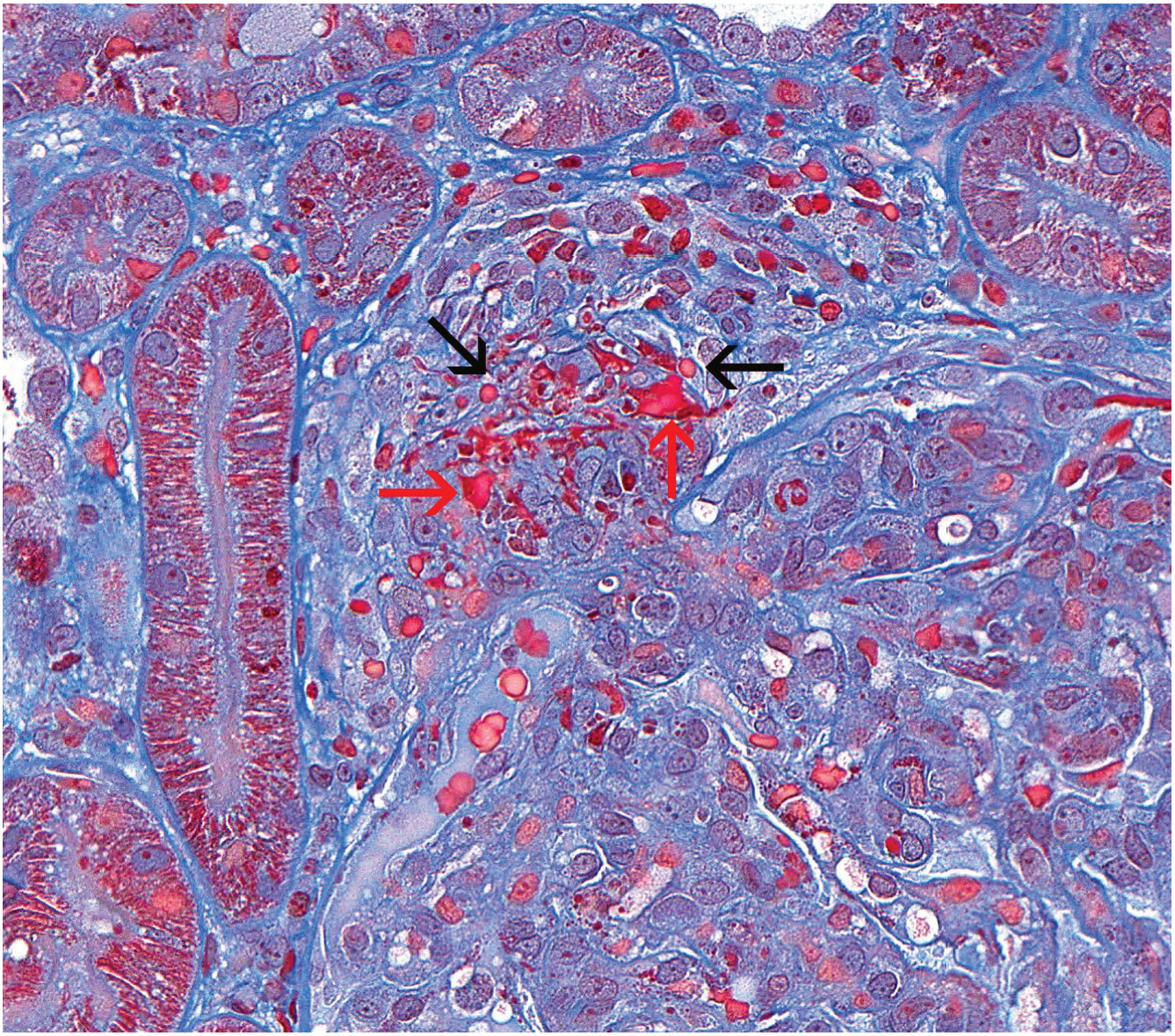

FIG.5G (MT): Higher magnification of FIG.5C. The fibrinoid necrosis can be seen as red material (red arrows), whereas there are also erythrocytes in the arteriolar wall (black arrows).

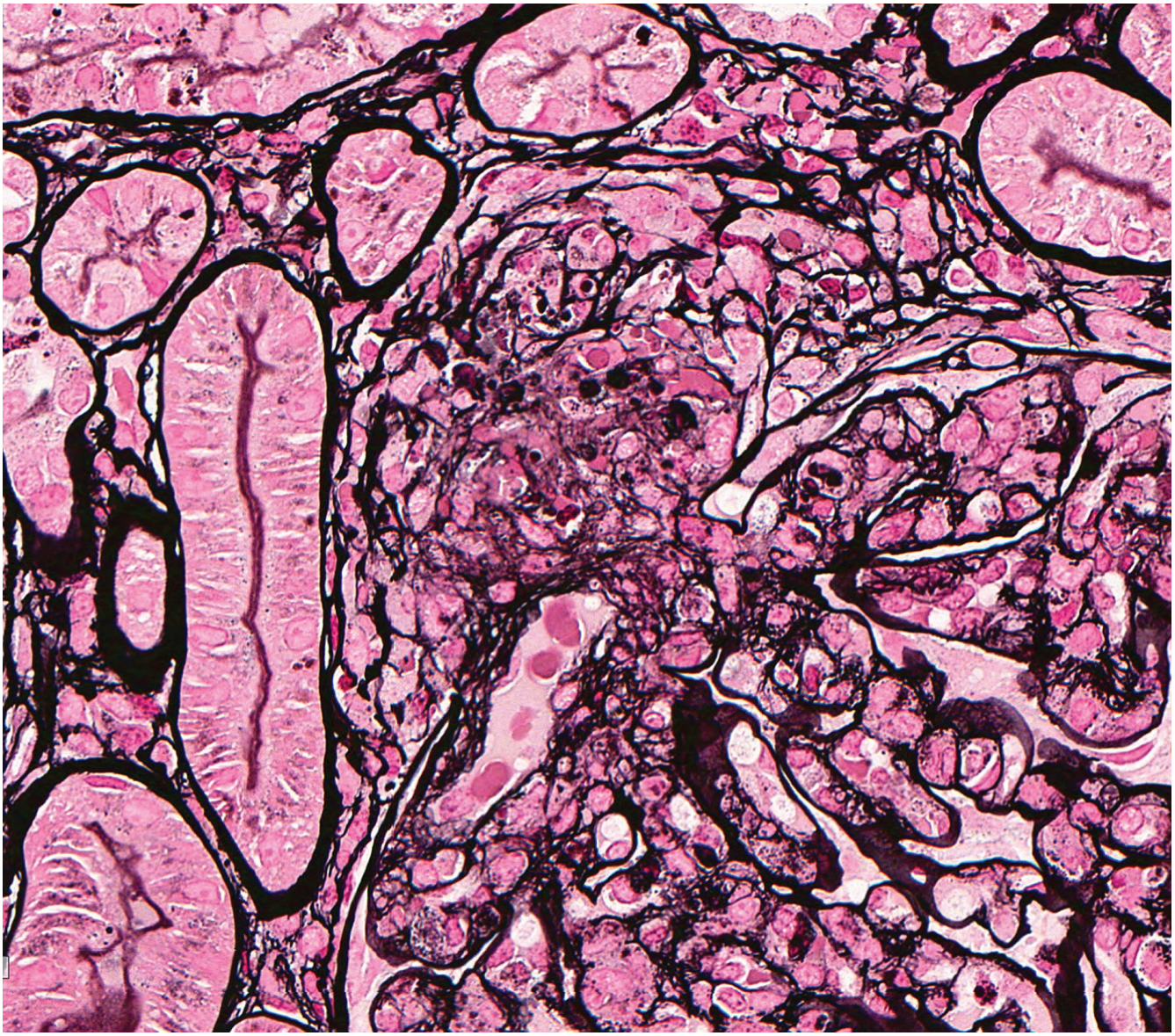

FIG.5H (JMS): Higher magnification of FIG.5D. The silver stain demonstrates the destruction of the

basement membrane of the afferent arteriole.

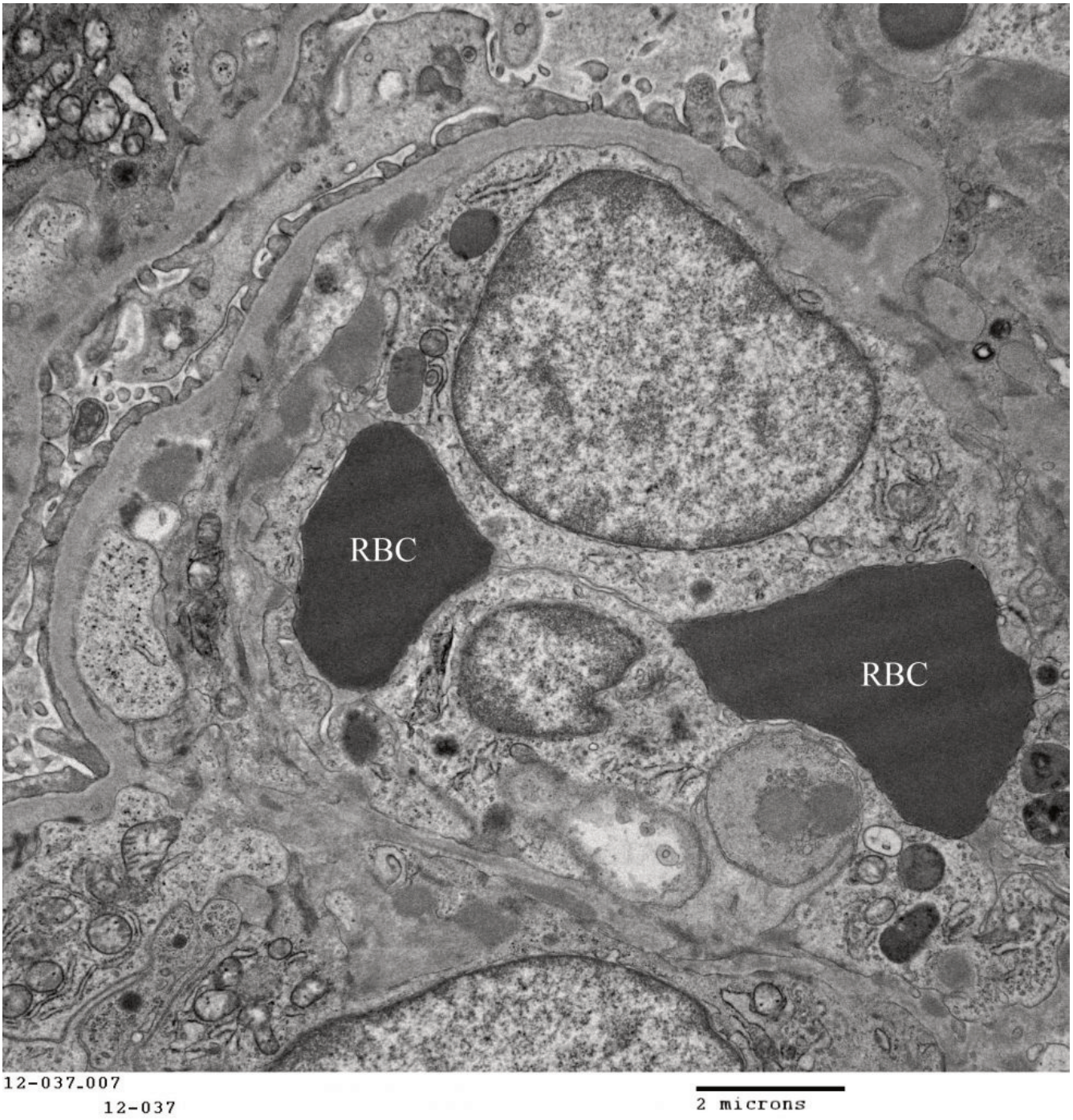

FIG.5I (TEM): Endothelial cells are swollen, leading to loss of fenestrae and distortion of circulating red blood cells (RBC). There are small electron dense deposits in subendothelial and intramesangial regions.

An interactive or media element has been excluded from this version of the text. You can view it online here:
https://ohiostate.pressbooks.pub/vetrenalpathatlas/?p=408

FIG.5J (TEM): Colorized version of above TEM. Green: GBM; Yellow: Endothelial cell; Pink: Podocyte; Blue: Mesangium.

Tubular, Interstitial and Vascular Pathology seen with Glomerular Diseases

- Tubular, interstitial and vascular injury often accompanies glomerular disease. In this context these three compartments should be carefully evaluated because the lesions that develop participate in the development of renal disease and can influences the clinical outcome. The morphological changes observed in the tubular, interstitial and vascular compartments are nonspecific and can also be recognized in renal diseases that do not have glomerular lesions as a component.
- The development of tubular lesions associated with glomerular disease depends on different factors.
    - Post glomerular blood flow can be compromised in glomerular disease, which can lead to tubular and interstitial ischemia. Also, post glomerular blood can contain mediators arising from glomerular inflammation and immune-mediated hypersensitivity reactions, *e.g.*, complement components. These mediators can initiate signal transduction pathways in tubular cells that generate chemotactic factors towards inflammatory cells and growth factors promoting fibrosis.
    - Excess tubular reabsorption of albumin can have similar effects. In addition, signaling cascades leading to cell death by apoptosis can be activated.
    - Vascular changes most often observed are due to the effects of hypertension on the vascular wall.
- The main tubular lesions that accompany glomerular disease are those associated with acute tubular injury; lesions in the interstitium are an increase in the interstitial matrix and inflammation. Vascular changes are usually associated with hypertension.
- Diagnosis of tubular, interstitial and vascular disease is usually by light microscopy with the aid of special histochemical methods: PAS, JMS and a trichrome stain. Transmission electron microscopy and immunofluorescence often are not required but may be useful ancillary tests.
- Terminology
    - Protein casts are eosinophilic with HE stain and magenta with the PAS reaction. PAS positive staining is attributed to uromodulin (Tamm-Horsfall protein), a mucoprotein, which is secreted into the thick ascending limb of the loop of Henle. This mucoprotein forms the structure of protein casts. The presence of protein casts in the proximal tubular lumina suggests that there is distal tubular blockage.
    - Interstitial amyloid is recognized as patchy deposits with the appearance of hyaline when stained with HE. It’s presence is confirmed by visualizing apple-green birefringence when Congo Red stained tissue sections are polarized. Interstitial amyloid may be observed with or without glomerular involvement.
    - Vasculature

- Vascular lesions in dogs might involve the renal arteries, arcuate arteries, intralobular arteries or the small arterial branches off of the intralobular arteries. These vessels might be sclerotic (e.g. arteriosclerosis) or have hyalinosis.
- Narrowing of the arteriolar lumens (afferent and efferent) can be due to hyperplastic arteriolosclerosis (not to be confused with arteriosclerosis or atherosclerosis) or hyalinosis.
- The sclerosis lesion is due to thickening of the smooth muscle wall, often resulting in an onion skinned appearance.
- Hyalinosis (at any level of the vascular tree) stains PAS – positive. It accumulates subendothelially, may extend into the media, and represents the accumulation of plasma-derived substances including various immunoglobulins, complement components especially C3, and fibrinogen.
- Fibrinoid necrosis of vessel walls associated with glomerular disease is rarely reported in the dog but has been reported in the condition known as cutaneous and renal glomerular vasculopathy. In this condition, acute kidney injury is attributed to thrombotic microangiopathy (TMA). The term ‘fibrinoid’ refers to the bright pink smudgy appearance of the vessel wall. This material morphologically looks like fibrin, but is mainly composed of necrotic debris, immune complexes and complement.

Clinical Features of Tubulointerstitial Damage in Proteinuric Dogs

- The kidneys are composed predominantly of tubulointerstitium (TI). Therefore, renal function as determined by glomerular filtration rate (GFR) is impacted more by TI lesions than glomerular lesions, and the severity of damage to the tubulointerstitial compartment is most associated with GFR regardless of the inciting disease process. For instance, in cases of glomerular disease, observation of tubular atrophy and interstitial fibrosis and inflammation will likely be associated with decreased GFR, reflected by azotemia or inappropriately high creatinine concentration for the patient. These GFR markers typically increase corresponding to the severity of the lesions. Conversely, if no lesions are observed in the TI compartment, clinical evidence of decreased GFR is less likely. Because TI lesions can be patchy, the correlation of biopsy findings with GFR assumes the biopsy is representative of the kidneys as a whole.
- Hypertension is commonly observed in patients with kidney disease and can be both a contributor to and result of disease progression. Vascular lesions (e.g., arteriolosclerosis, striped pattern of interstitial fibrosis and tubular atrophy) are often associated with hypertension , supporting that decreasing the

blood pressure in these patients is important in mitigating disease progression.

- Tubular protein casts are commonly observed with glomerular disease, and these may correspond with the observation of hyaline (and/or other) casts in the urine. Glomerular proteinuria should be present in these cases.
- Although rare, RBC casts are typically associated with active glomerulonephritis accompanied by a decrease in GFR. If red blood cell (RBC) casts are seen histologically, one might expect their presence on a urine sediment.
- In cases of thrombotic microangiopathy, common clinical findings include: azotemia, thrombocytopenia, hemolytic anemia (with presence of schistocytes), proteinuria, and pigmenturia . Other common findings include hyperbilirubinemia, hypoalbuminemia, and hypertension.
- Tubular injury, as indicated by a variety of lesions described in this chapter, can contribute to the proteinuria observed in patients with glomerular disease. However, this contribution is typically minimal. Evaluation of urine proteins using gel electrophoresis reveals that the majority of dogs with glomerular disease have proteinuria secondary to both glomerular and tubular damage. While the TI component doesn't usually contribute much to the magnitude of proteinuria, it can indicate significant TI disease.
- Besides proteinuria, other urinary indicators of tubular injury include amino aciduria, normoglycemic glucosuria and ketonuria.
- Sensitive and specific urinary indicators of tubular damage/injury are desired and are being tested on a research basis. None are commercially available at this point in time. However, in the future, it is anticipated that such biomarkers can support ongoing tubular injury.
- An advantage of evaluating the urine for injury markers is that urinary findings are representative of both kidneys in their entirety, whereas a biopsy may not sample the lesion. A major disadvantage, however, is that lower urinary tract disease (e.g., urinary tract infections) can complicate interpretation of such biomarkers.

PROTEIN (HYALINE) DROPLETS are small, round eosinophilic deposits dispersed throughout the cytoplasm of tubular epithelial cells. They can be single or multiple and are best visualized with the PAS reaction.

An interactive or media element has been excluded from this version of the text. You can view it online here:
https://ohiostate.pressbooks.pub/vetrenalpathatlas/?p=456

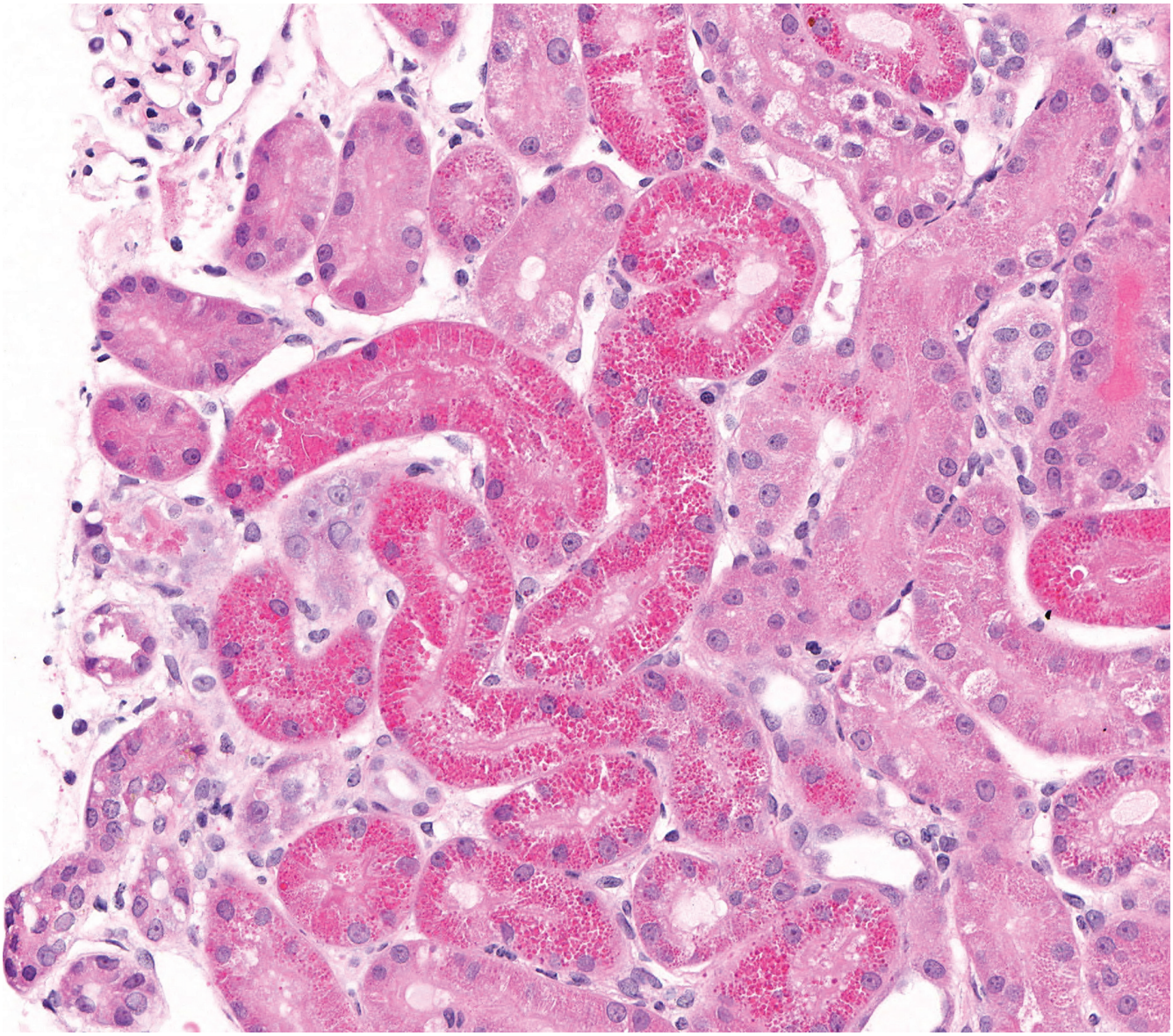

FIG.1A (HE): The epithelial cells lining many proximal tubules have small (1 to 2 micron) eosinophilic protein droplets in their cytoplasm.

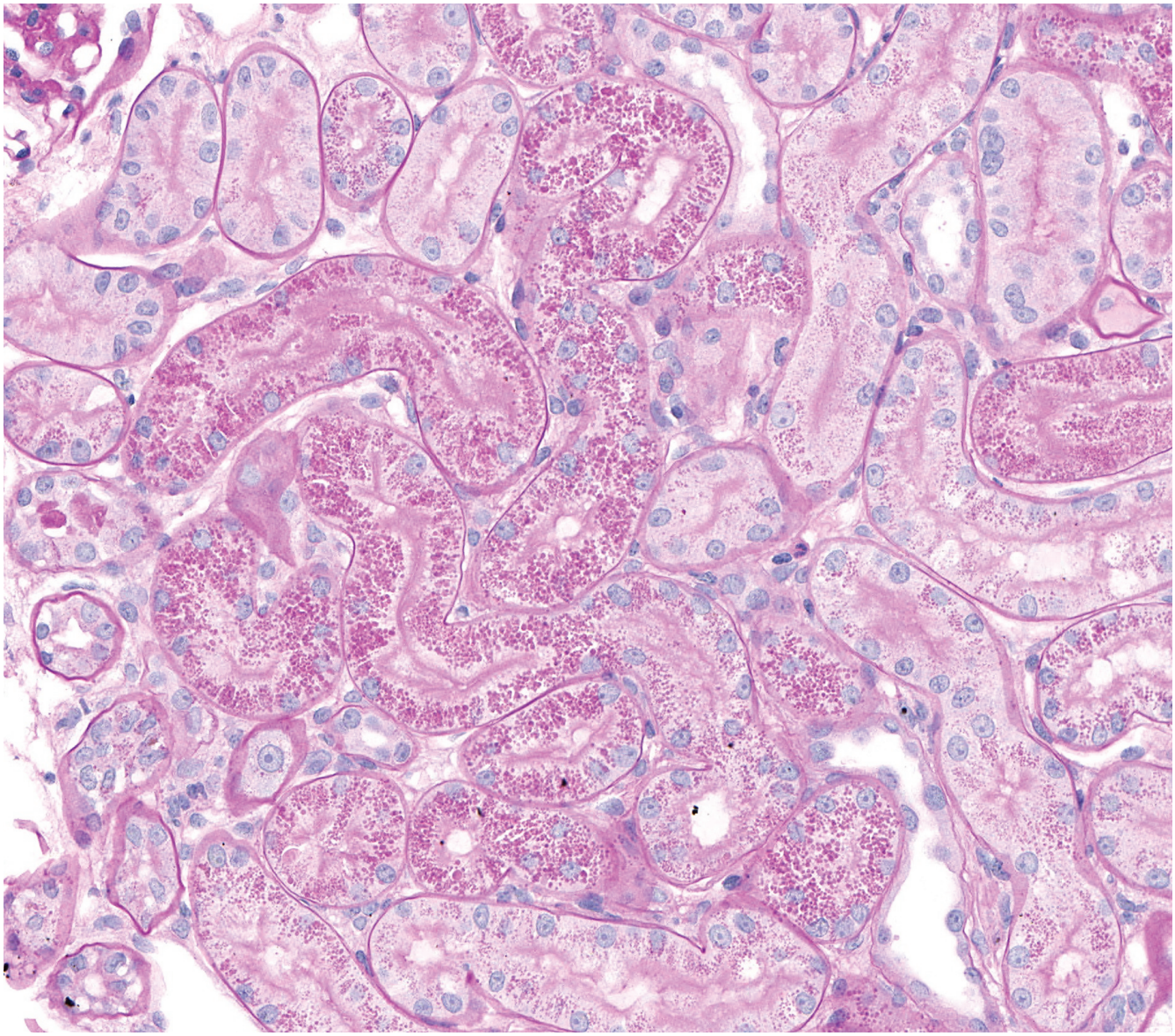

FIG.1B (PAS): The small protein droplets in the tubular epithelial cells are PAS positive.

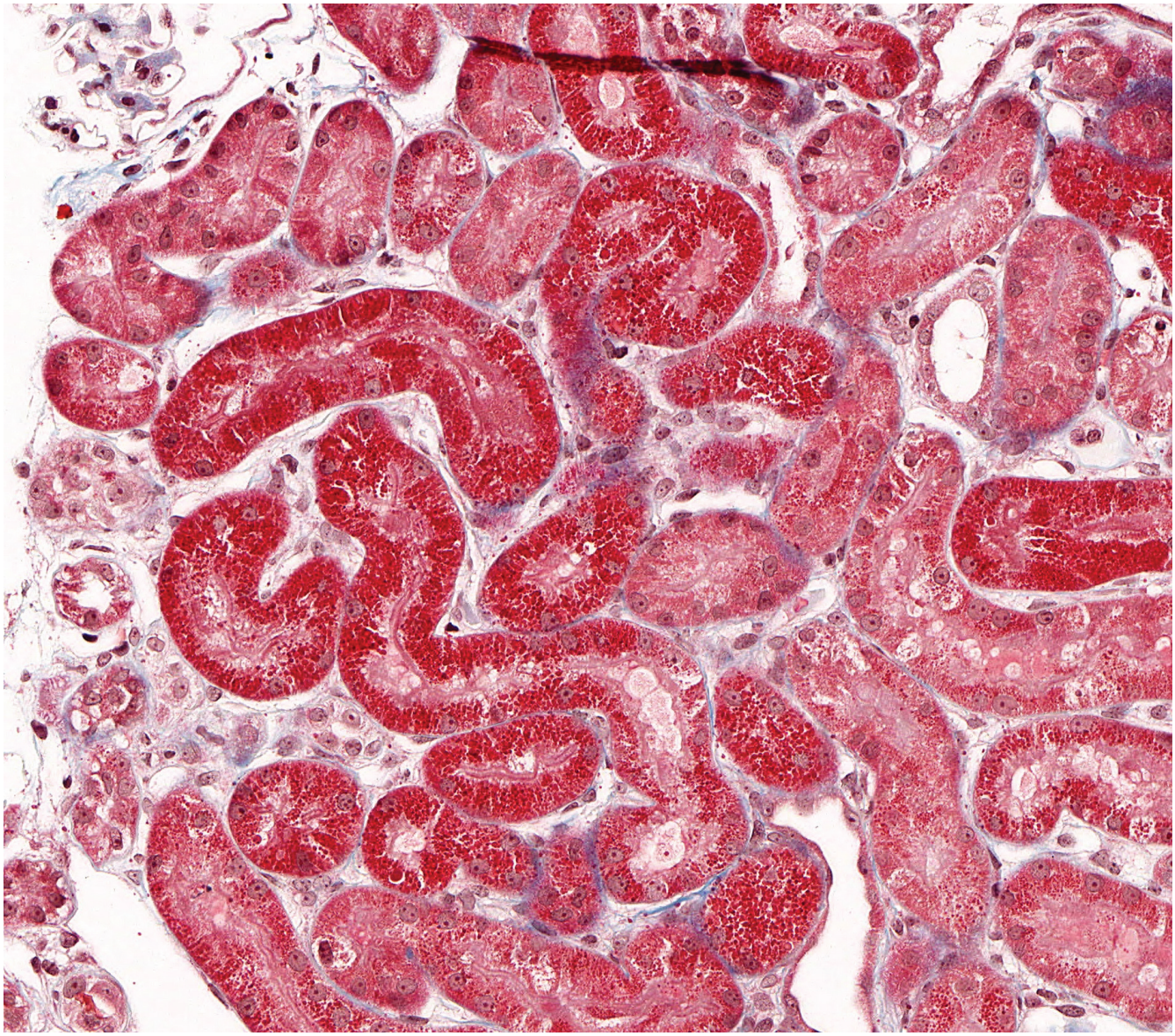

FIG.1C (MT): The small protein droplets in the tubular epithelial cells stain red with trichrome.

LIPID VACUOLES can be observed in nephrotic states. Lipid vacuoles appear as clear, round and variably sized. Lipid vacuolization is normal in the proximal straight tubules of dogs and should be considered abnormal in any other section of the nephron.

An interactive or media element has been excluded from this version of the text. You can view it online here:
https://ohiostate.pressbooks.pub/vetrenalpathatlas/?p=456

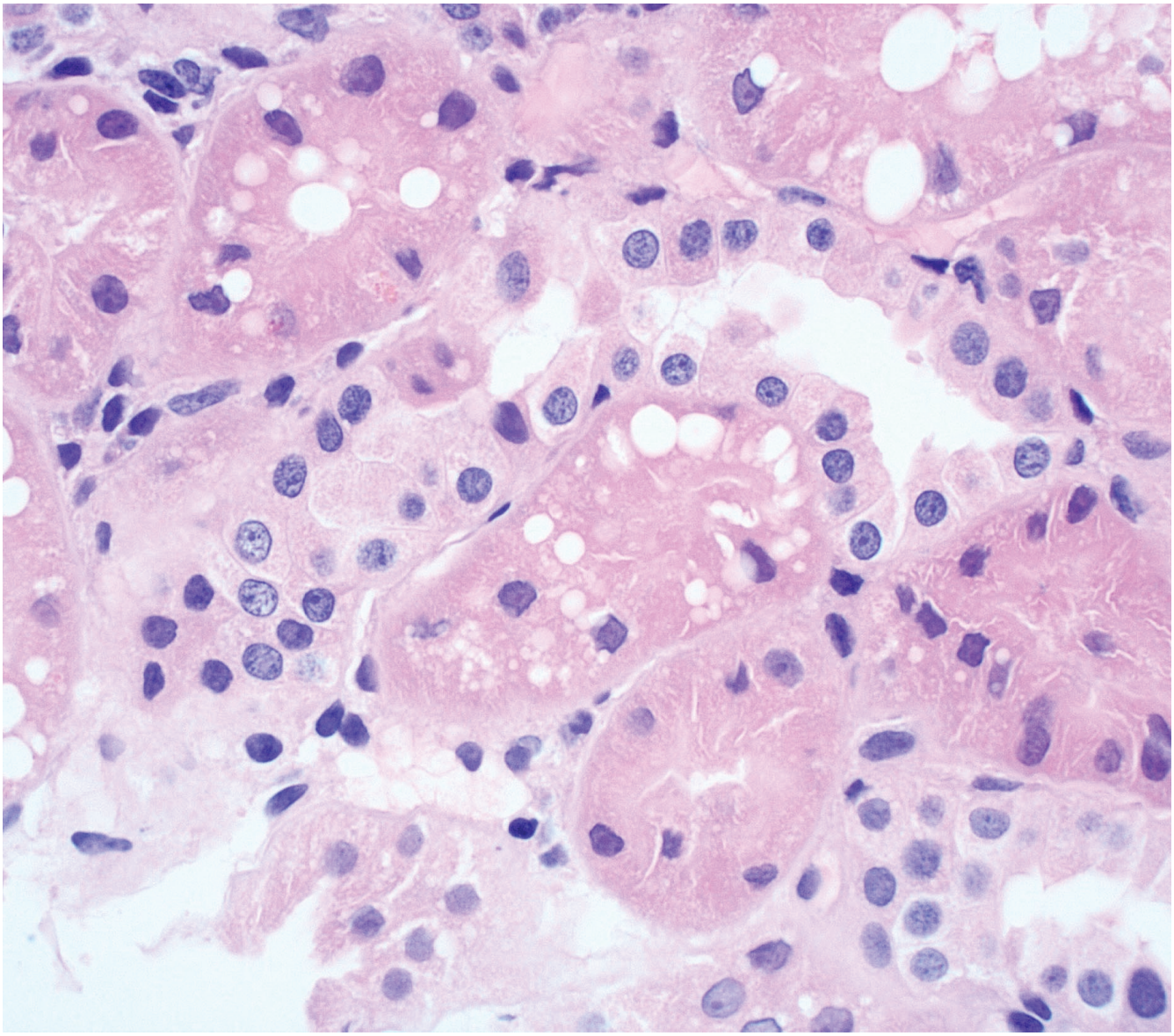

FIG.2A (HE): Many tubular epithelial cells have clear cytoplasmic vacuoles which are lipid.

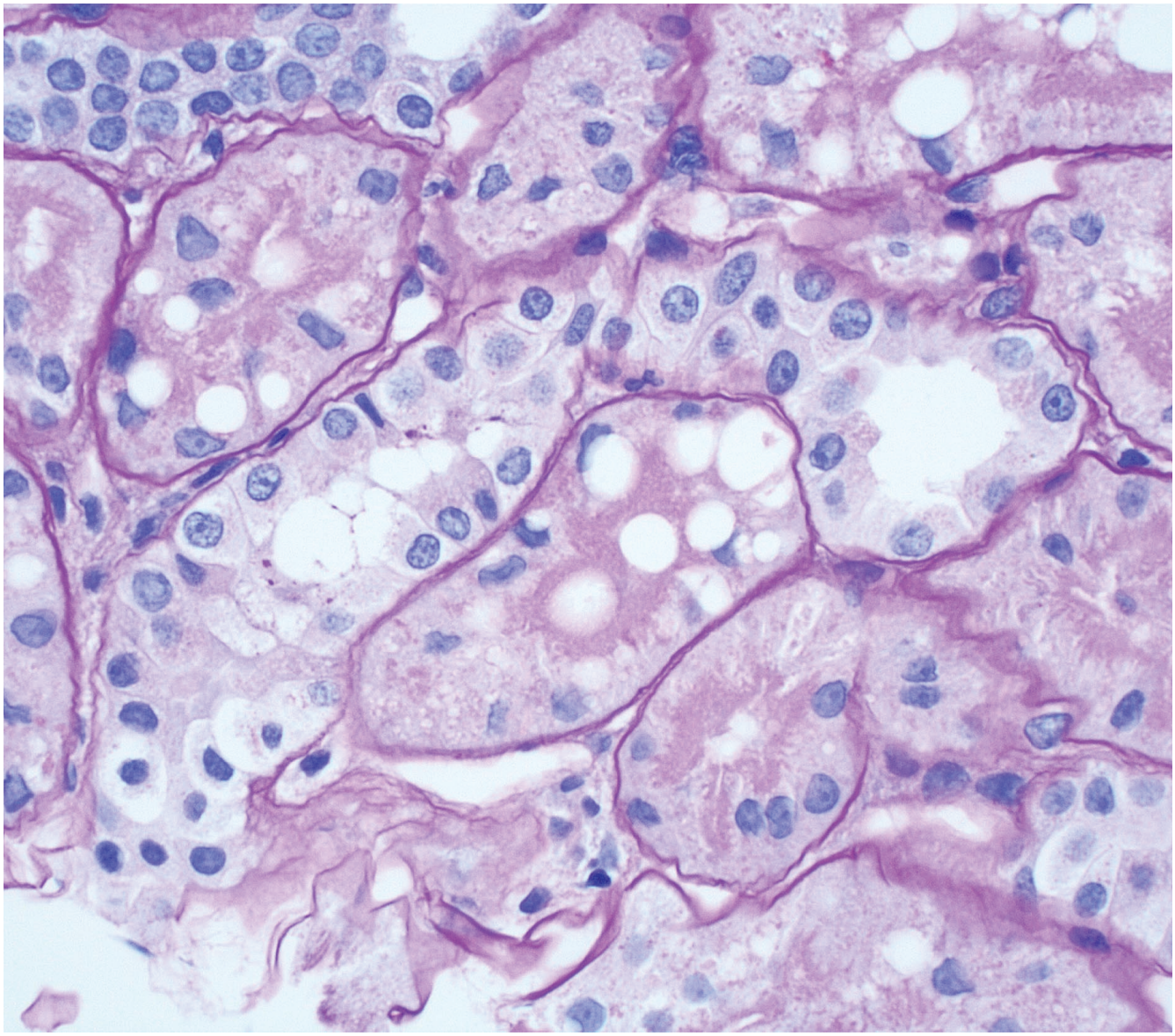

FIG.2B (PAS): The cytoplasmic droplets are predominantly in the proximal tubular epithelial cells with the prominent PAS positive brush border.

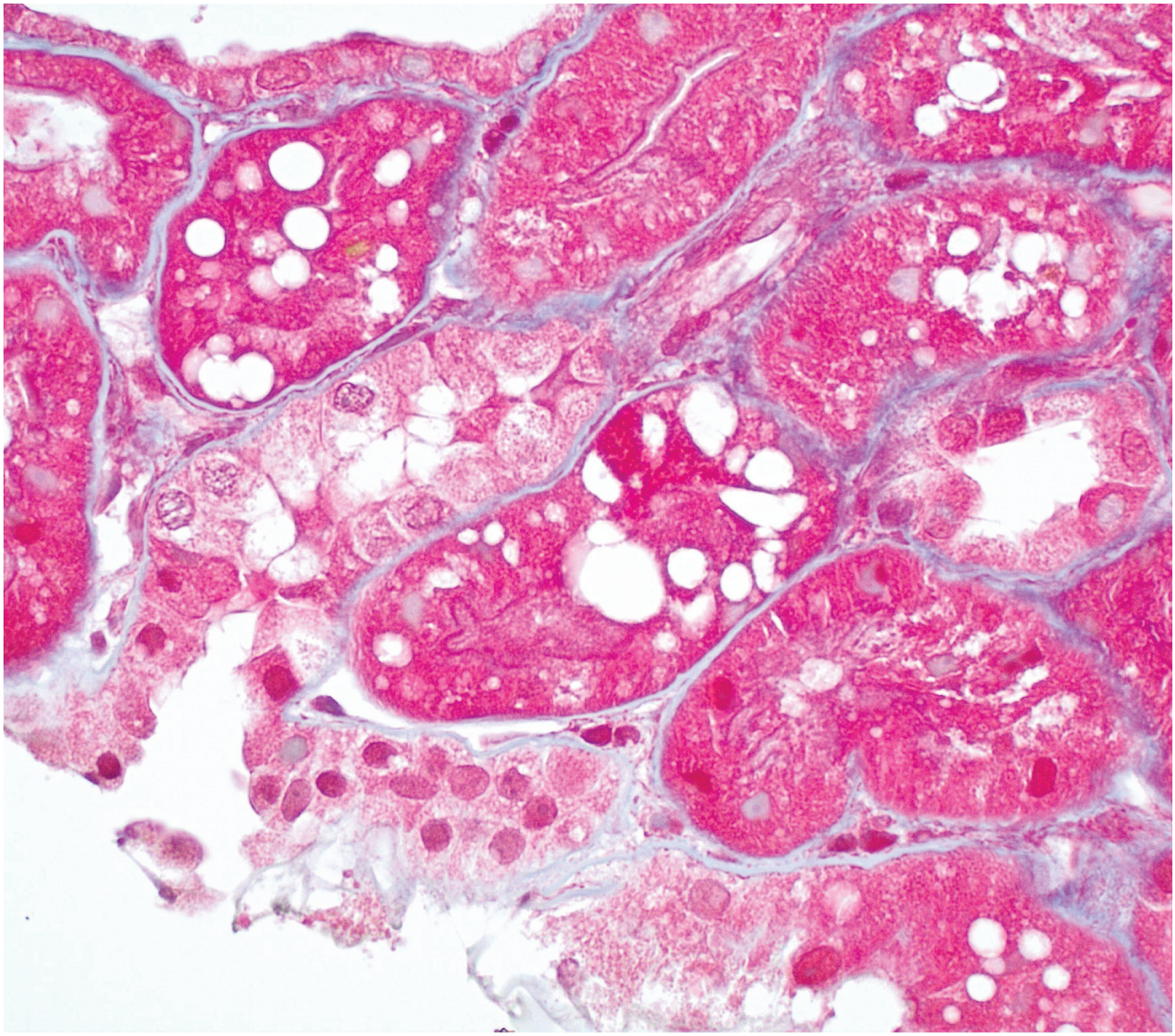

FIG.2C (MT): The clear vacuoles are located in proximal tubules.

ISOMETRIC VACUOLIZATION refers to fine, uniformly sized, clear vacuoles that fill most or all of the cytoplasm. They often result from the use of carbohydrates as plasma expanders.

An interactive or media element has been excluded from this version of the text. You can view it online here:
https://ohiostate.pressbooks.pub/vetrenalpathatlas/?p=456

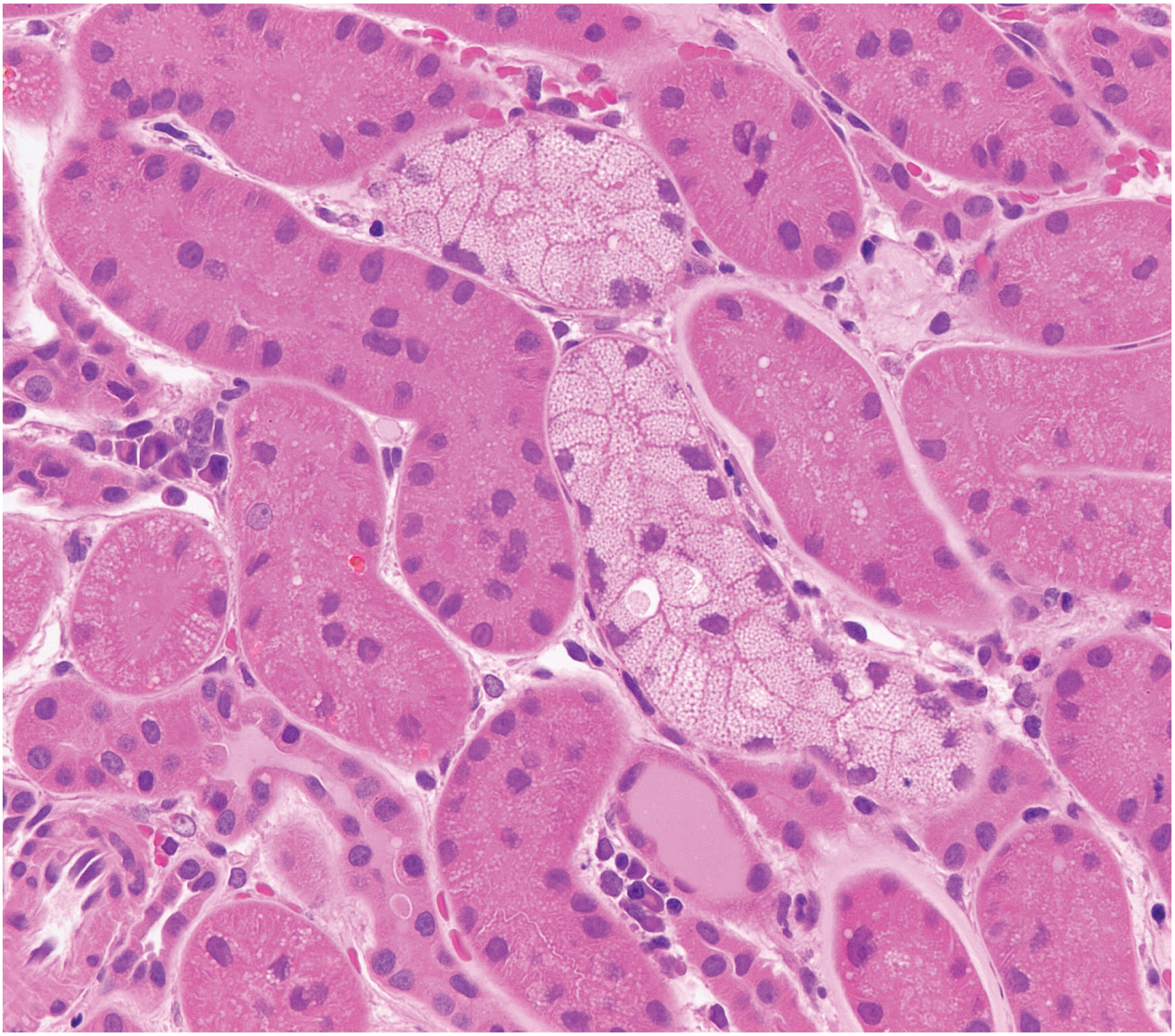

FIG.3A (HE): Two tubules are lined by epithelial cells with myriad small (1-2 micron) discrete vacuoles all of similar size.

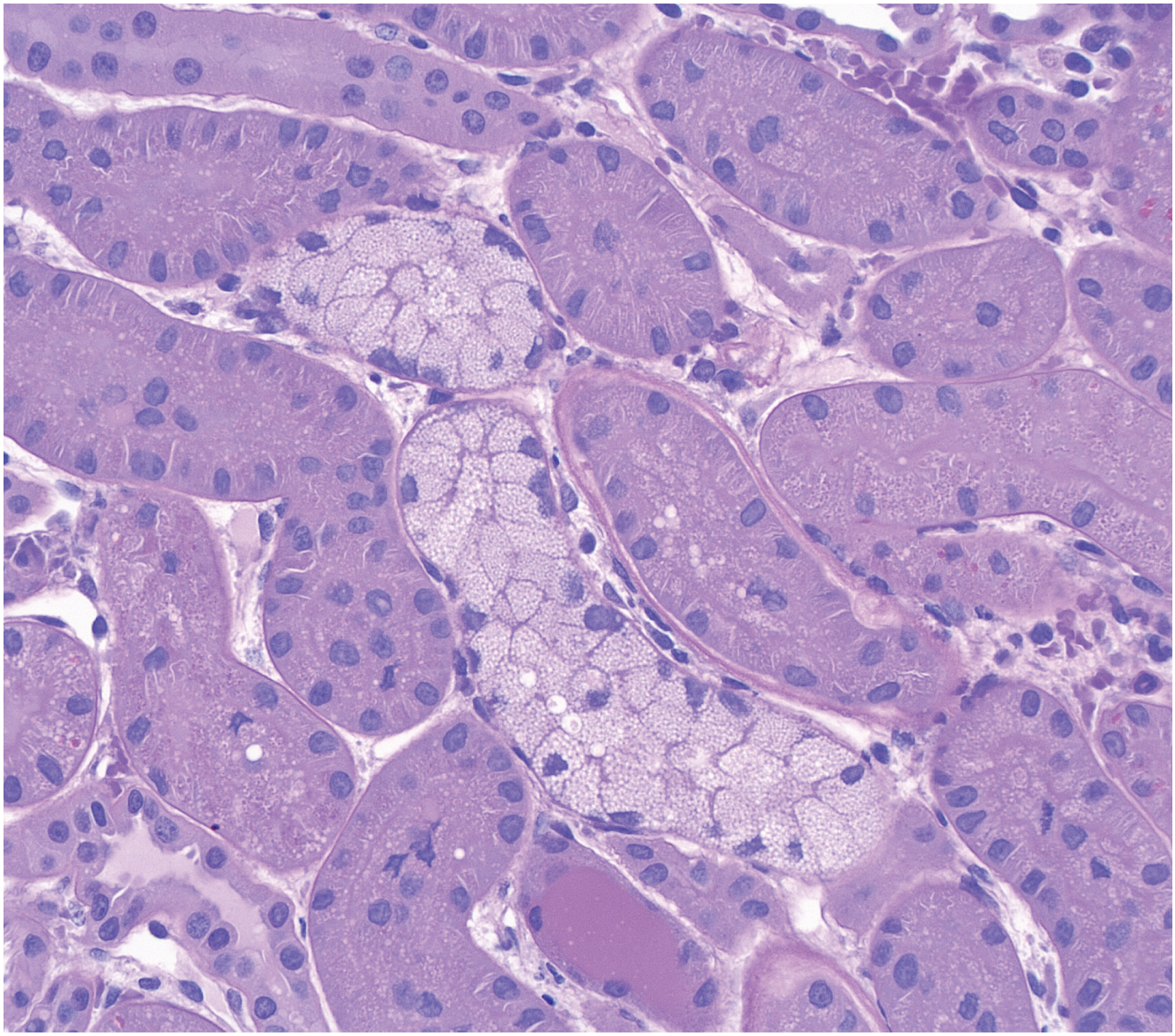

FIG.3B (PAS): This stain enables one to clearly see the discrete, similarly sized vacuoles.

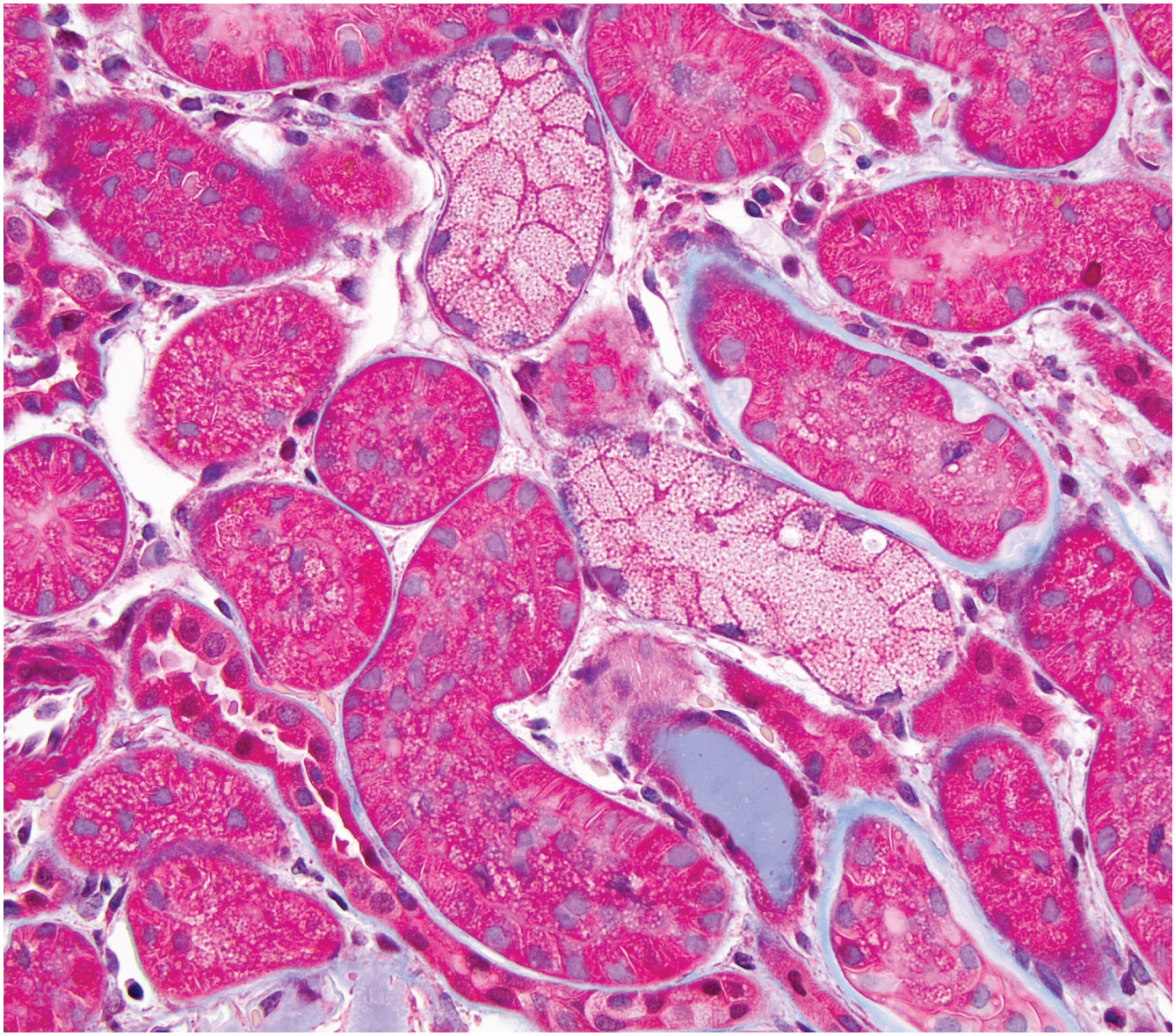

FIG.3C (MT): Other tubules in this field also have vacuoles but their cytoplasm is not as distended as the tubules with isometric vesiculation.

TUBULAR SIMPLIFICATION refers to a thinning of the tubular epithelium. This is the sequel of individual cell necrosis/apoptosis and represents the spreading and thinning of neighbor cells to cover the basement exposed by sloughed dead cells. The term attenuation is also used to describe this change.

An interactive or media element has been excluded from this version of the text. You can view it online here:
https://ohiostate.pressbooks.pub/vetrenalpathatlas/?p=456

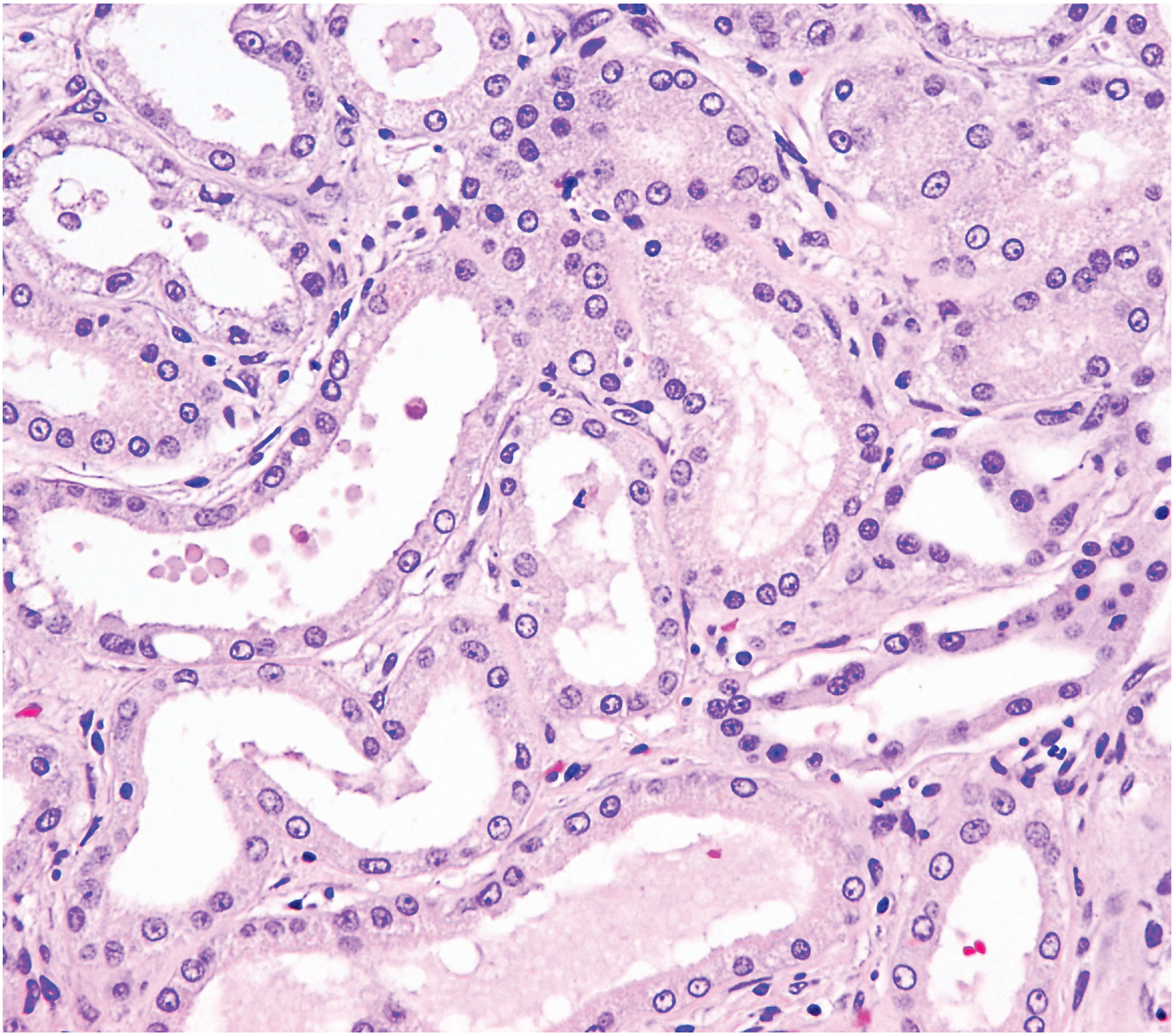

FIG.4A (HE): Tubules are lined by cuboidal instead of columnar epithelium and some tubular lumens contains sloughed cellular debris.

An interactive or media element has been excluded from this version of the text. You can view it online here:
https://ohiostate.pressbooks.pub/vetrenalpathatlas/?p=456

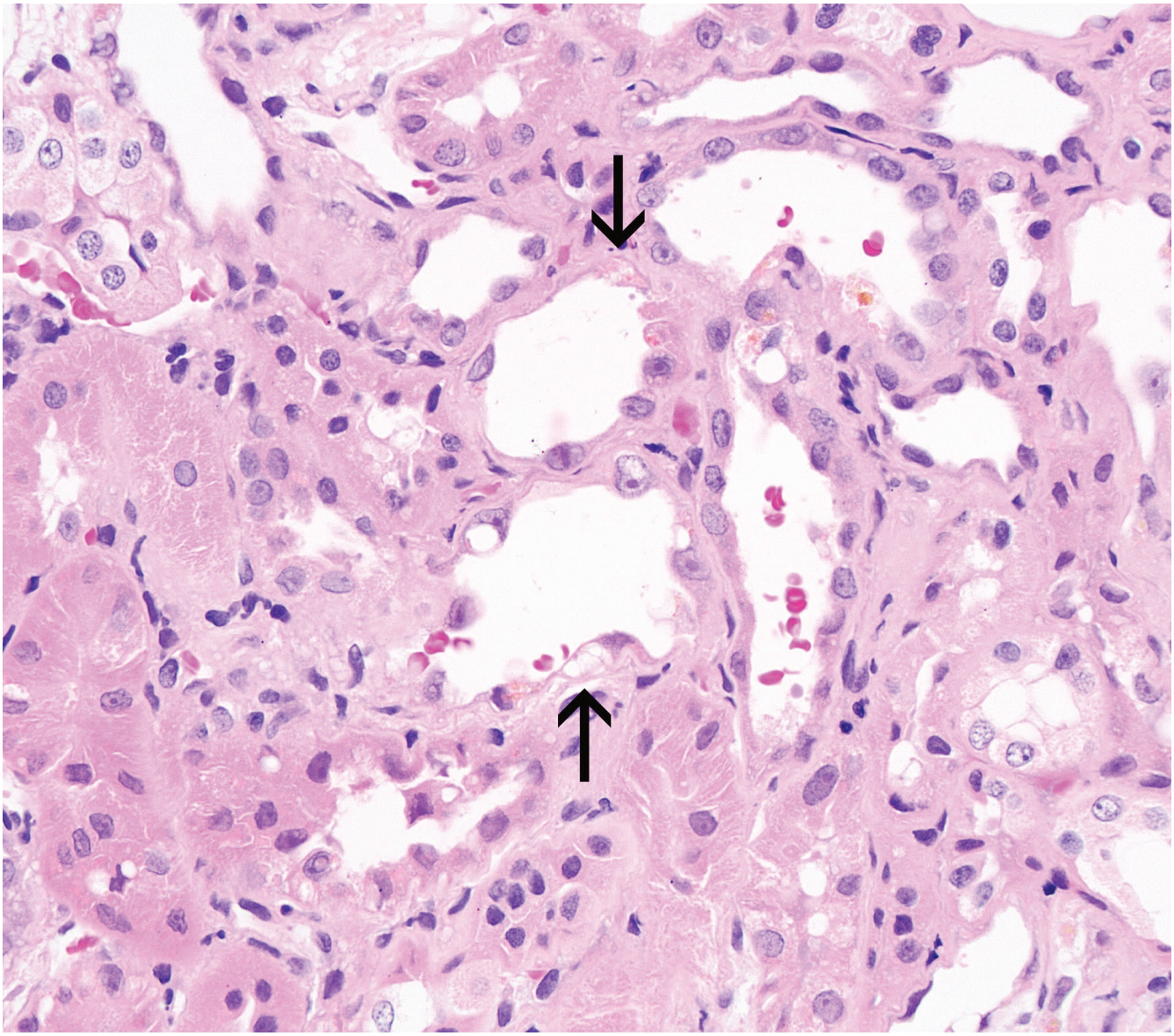

FIG.4B (HE): Tubules are lined by flattened epithelial cells (arrows), many of which contain a large cytoplasmic vacuole, a nucleus and minimal cytoplasm

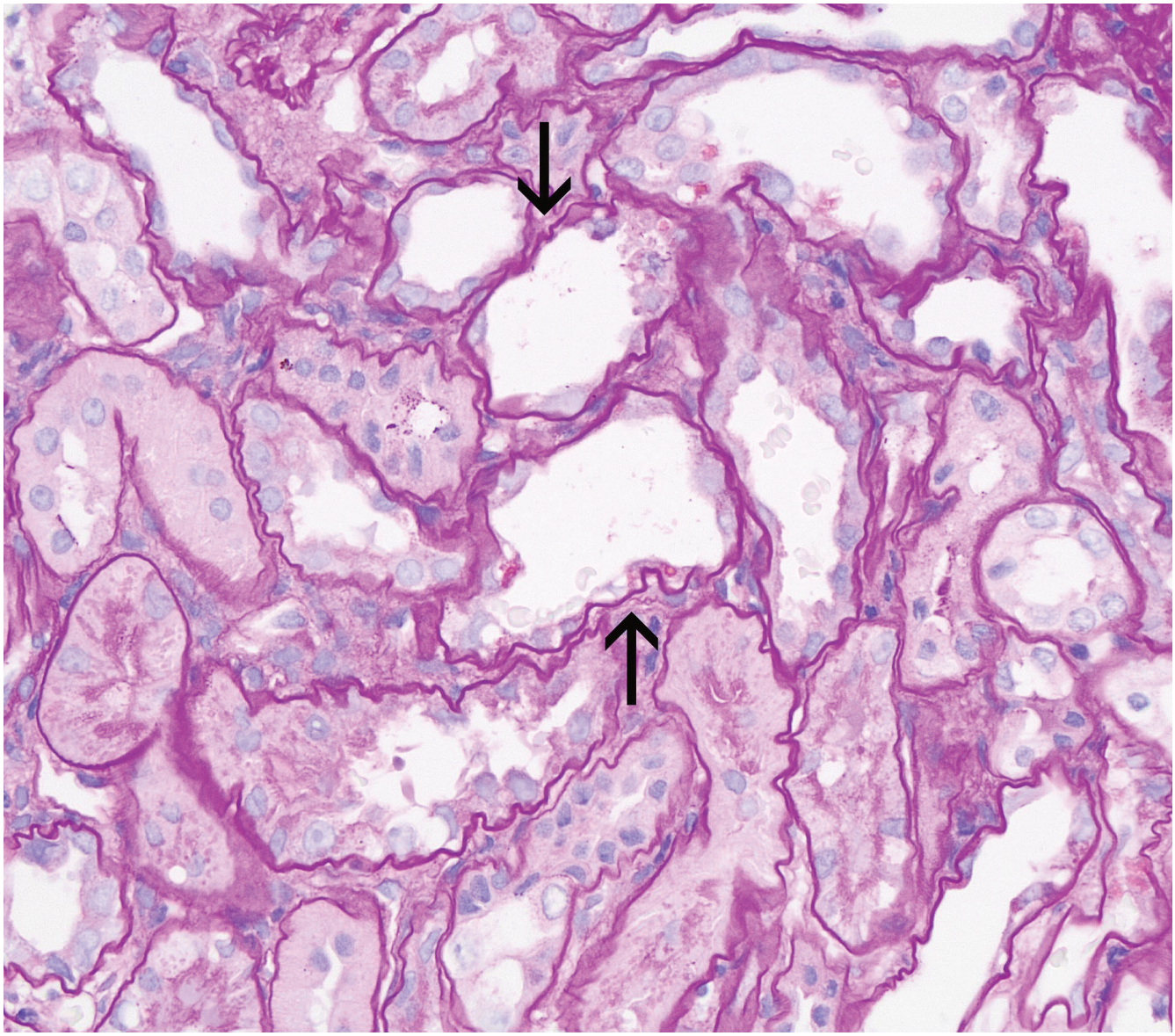

FIG.4C (PAS): This stain demonstrates that many tubules in addition to injured ones (arrows) lack a PAS positive brush border.

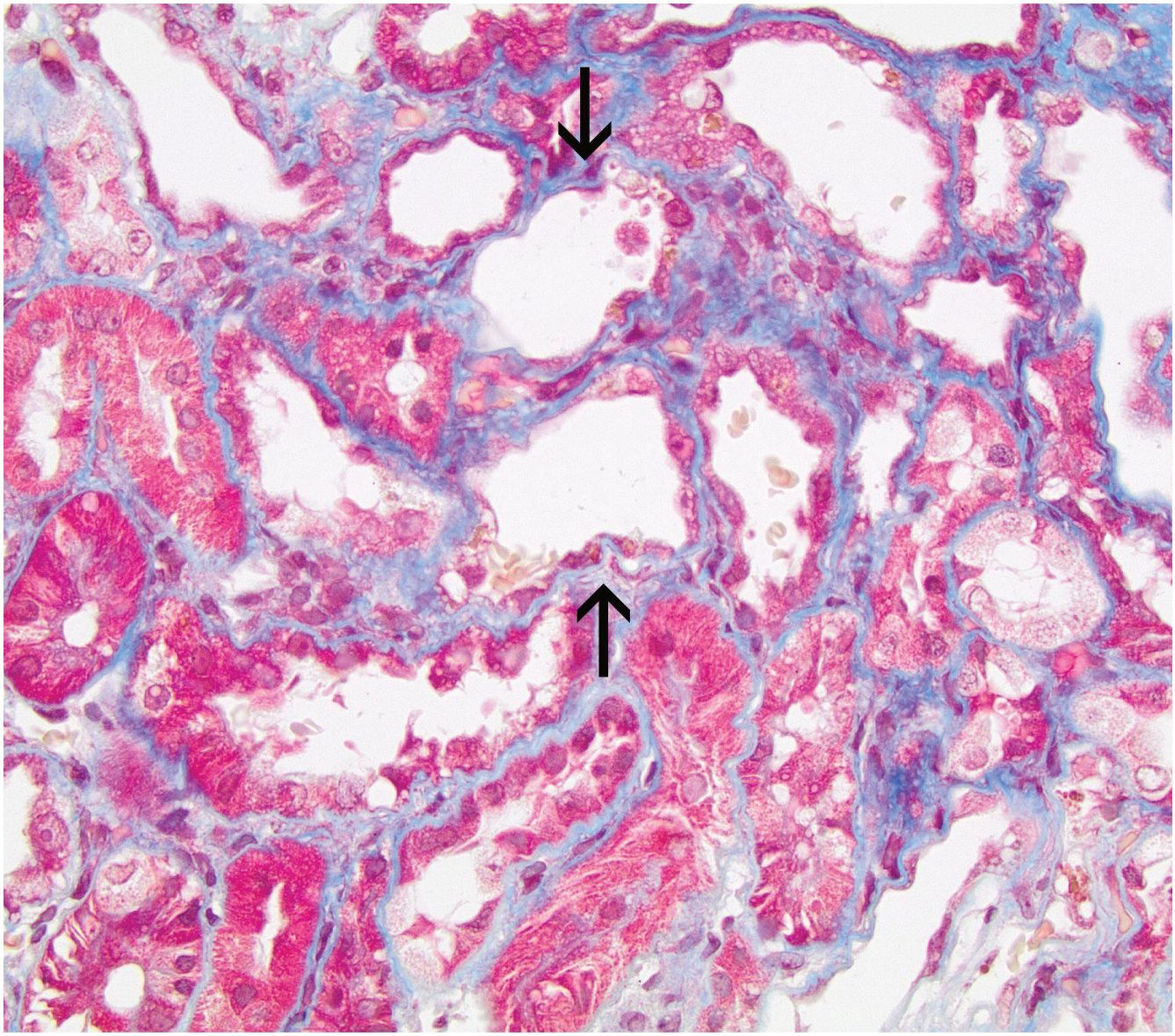

FIG.4D (MT): The simplified tubules have minimal cytoplasm resulting in an irregular shape of the tubular lumens (arrows). There is minimal to mild interstitial fibrosis.

LOSS OF THE APICAL BRUSH BORDER is another feature of tubular simplification and represents early tubular injury. The brush border is visualized on the apical surface of proximal tubular epithelium with the PAS reaction.

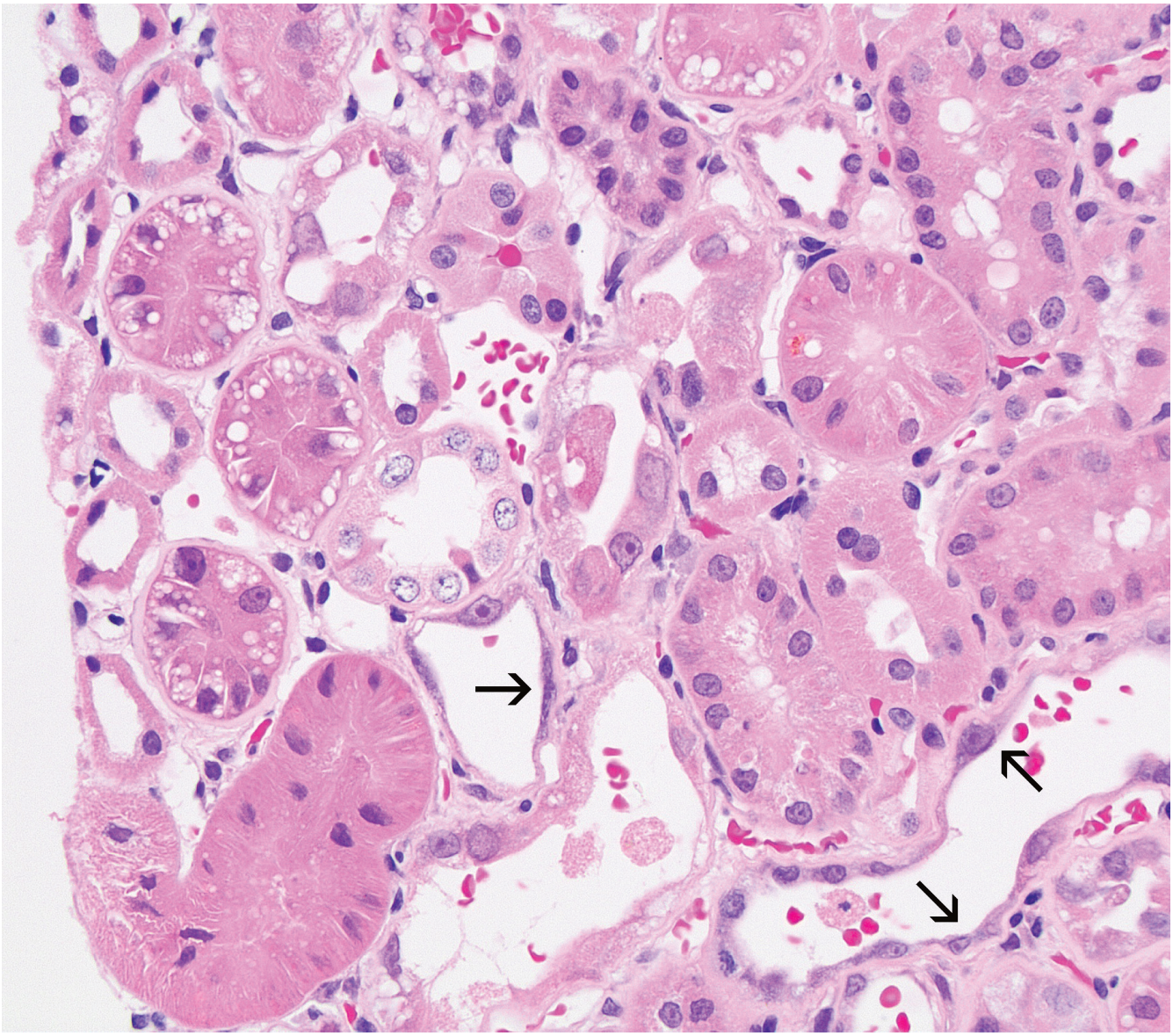

FIG.4E (HE): Many tubules lack a brush border. Some epithelial cells have stretched to cover the tubular basement membrane (arrows) and a few cells are karyomegalic. Other examples of injury include singly necrotic epithelial cells in tubular lumens and cytoplasmic vacuolation.

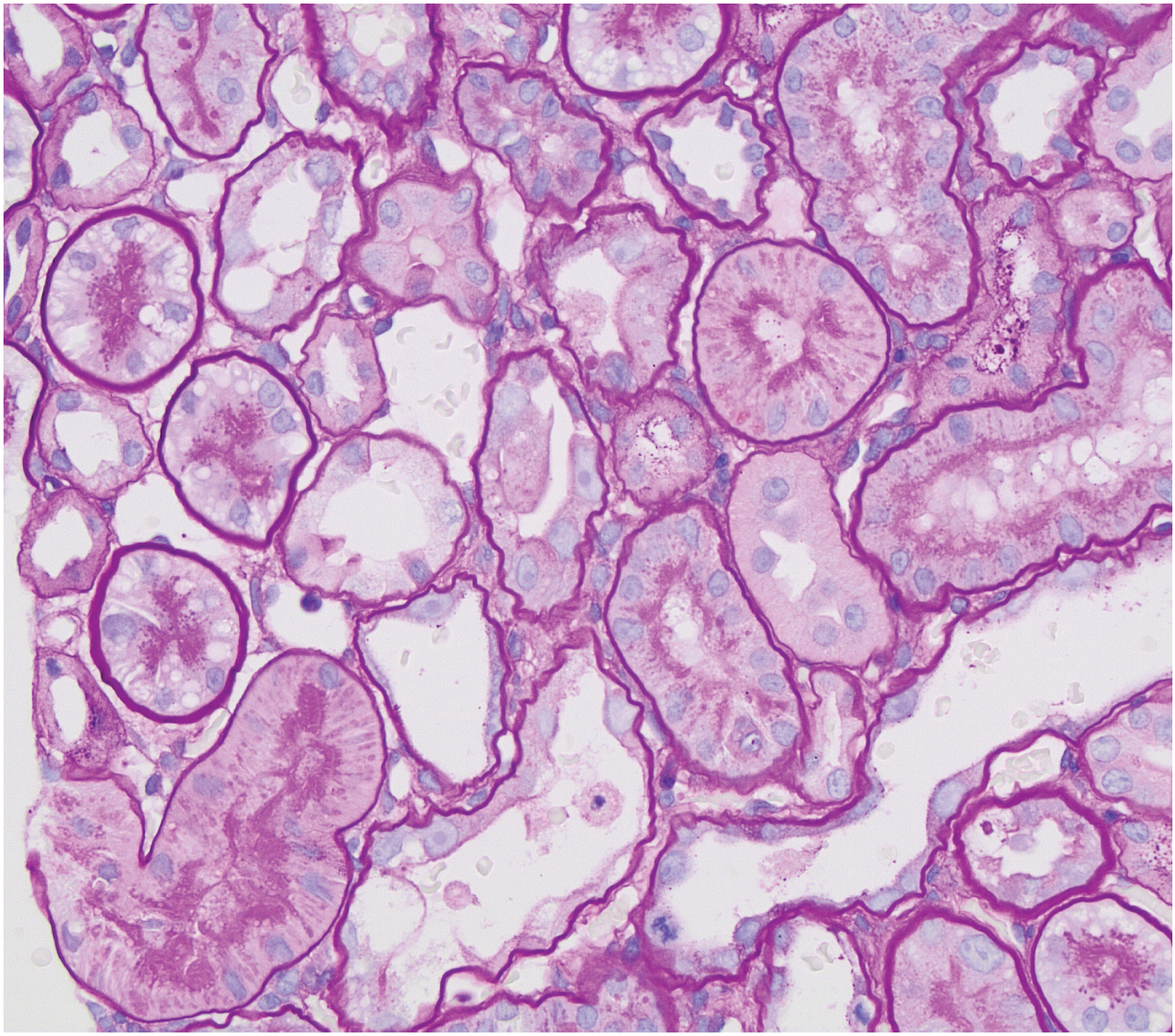

FIG.4F (PAS): Many tubules lack a PAS positive brush border but some maintain theirs. Patchy injury such as this, wherein some tubular segments are damaged and others are not, is typical.

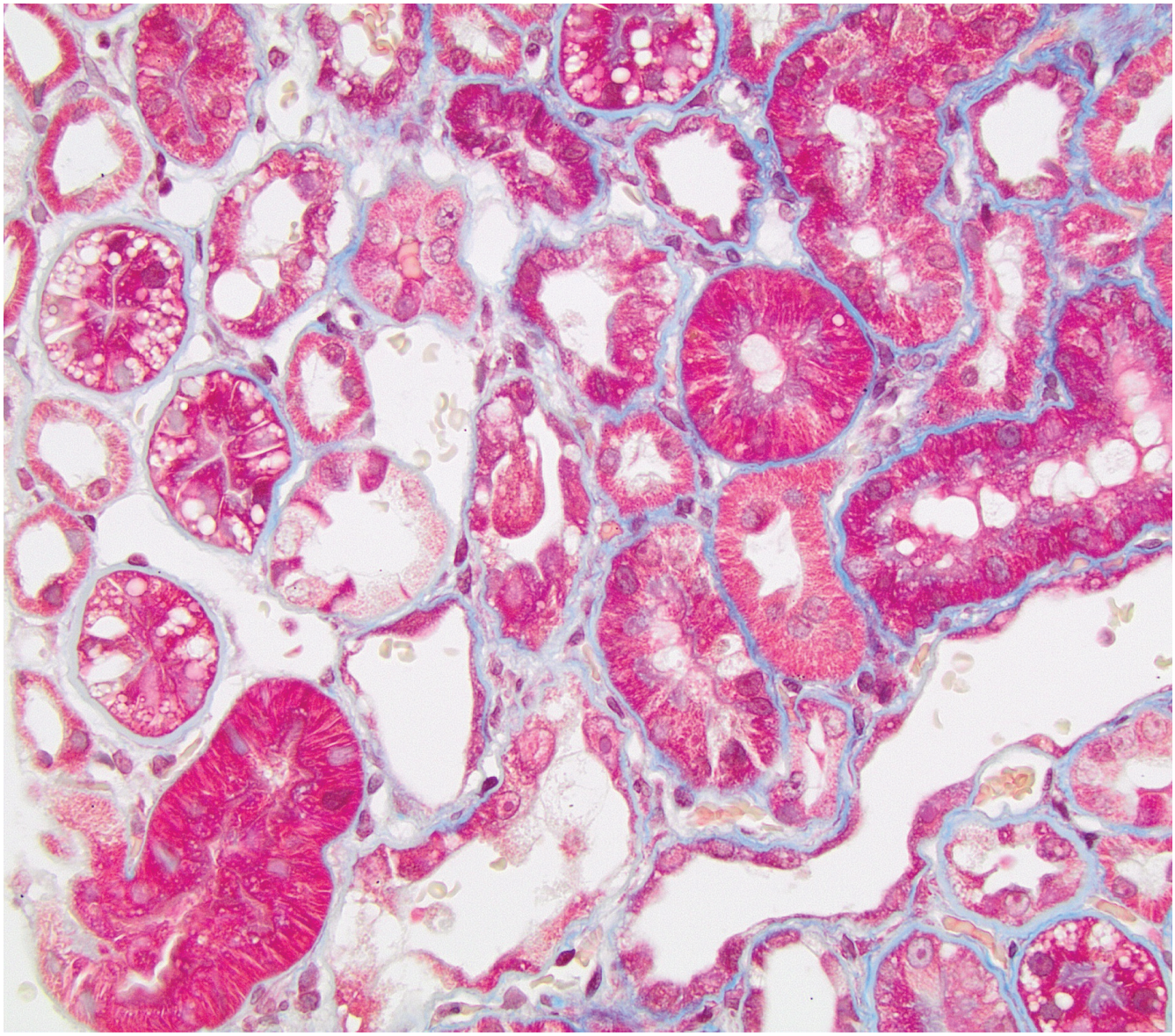

FIG.4G (MT): Tubular epithelial simplification and loss of the brush border is also evident with MT. There is minimal interstitial fibrosis.

SINGLE CELL NECROSIS / APOPTOSIS is the presence of individual dead cells in the tubular epithelium. These cells are most easily identified by the presence of nuclear changes characteristic of dead cells: pyknosis, karyorrhexis and karyolysis. Individual dead cells may also be free in the lumen.

An interactive or media element has been excluded from this version of the text. You can view it online here:
https://ohiostate.pressbooks.pub/vetrenalpathatlas/?p=456

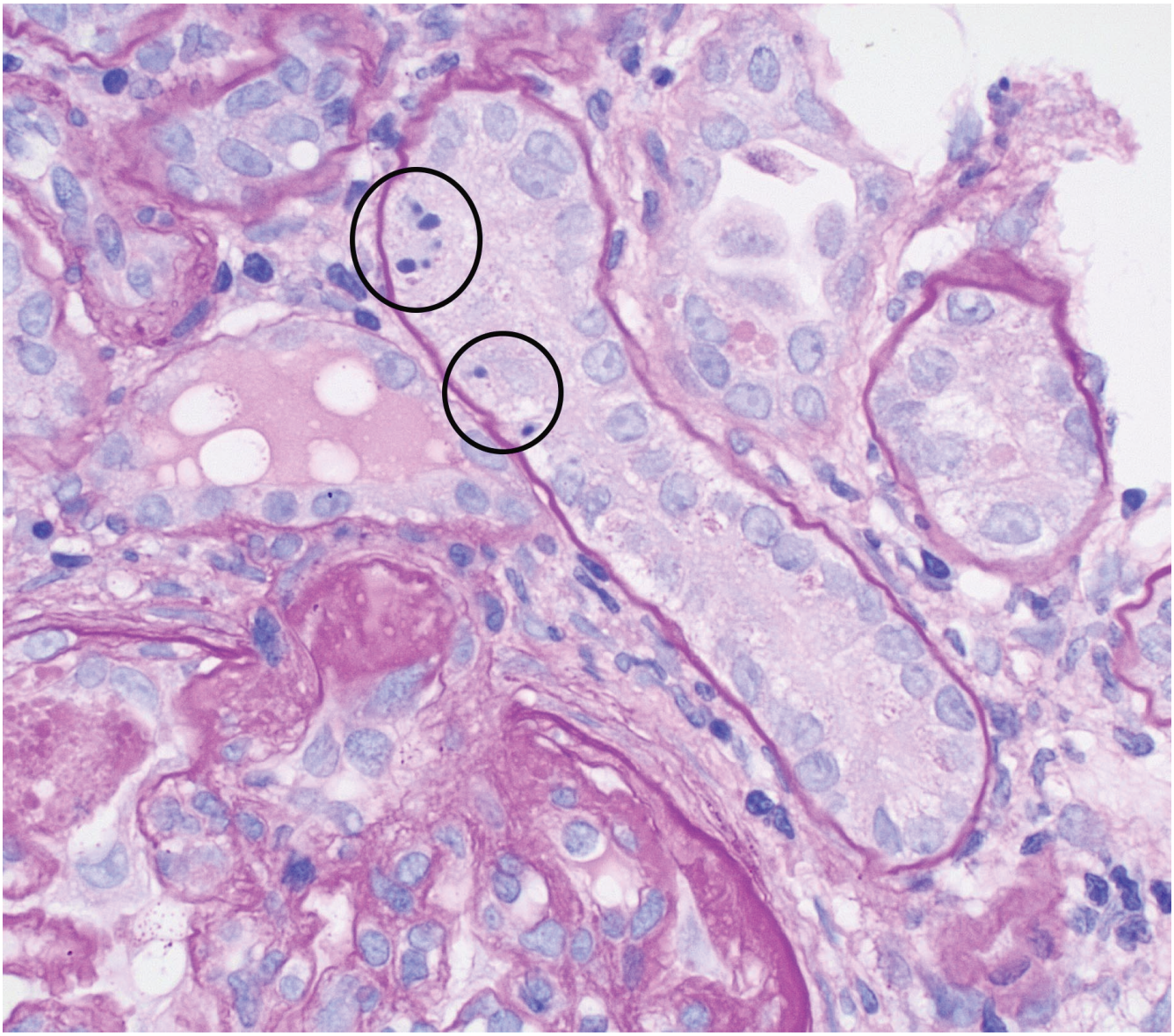

FIG.5A (PAS): This tubule has 3 cells with pyknotic nuclei (circled) indicative of single cell death (likely apoptosis). There is also a portion of a glomerulus in the lower left corner with hyalinosis of the vascular pole.

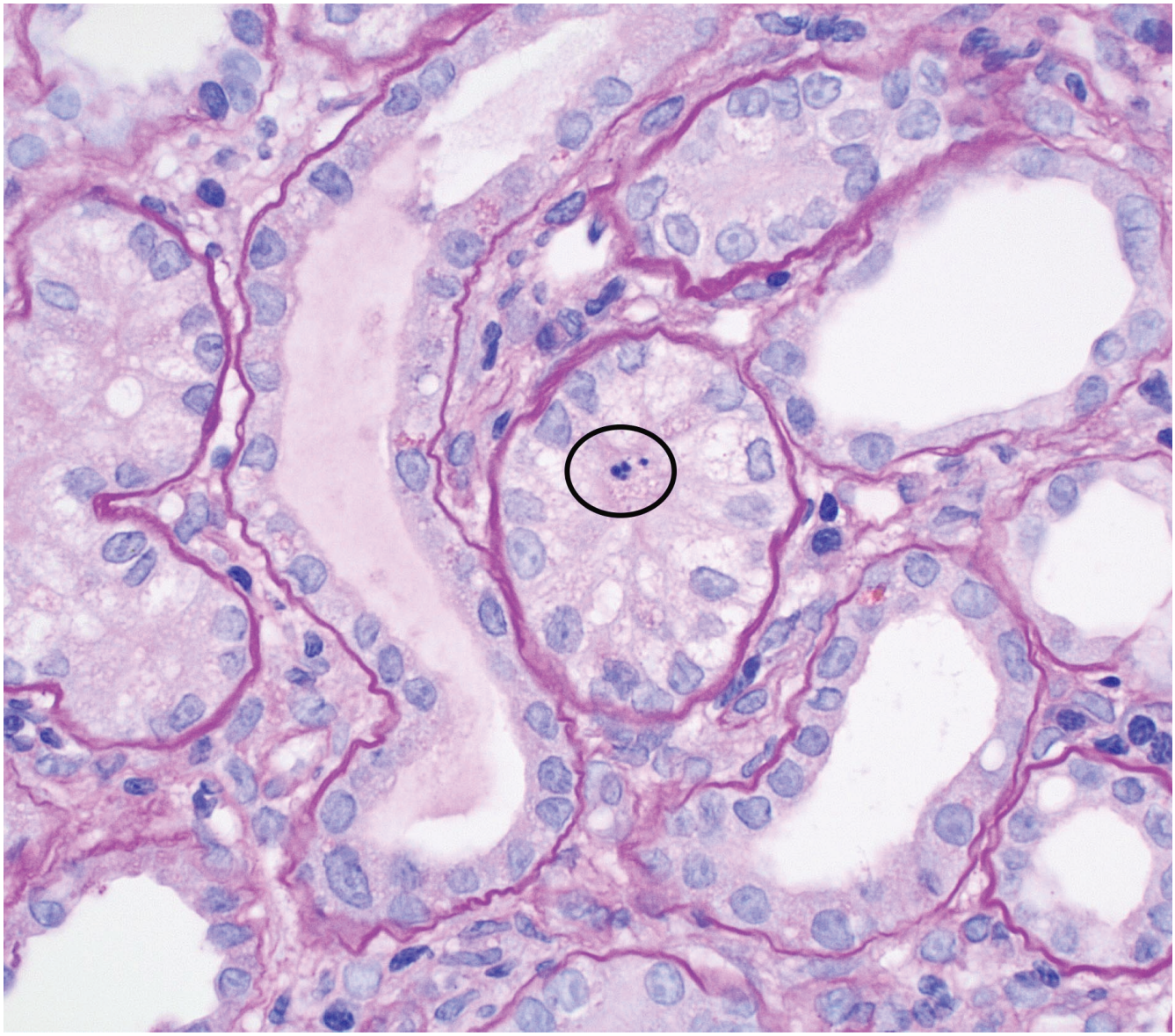

FIG.5B (PAS): This tubule has a cell with pyknotic nuclei (circled) indicative of single cell death. The other tubules in this field are characterized by loss of the apical brush border.

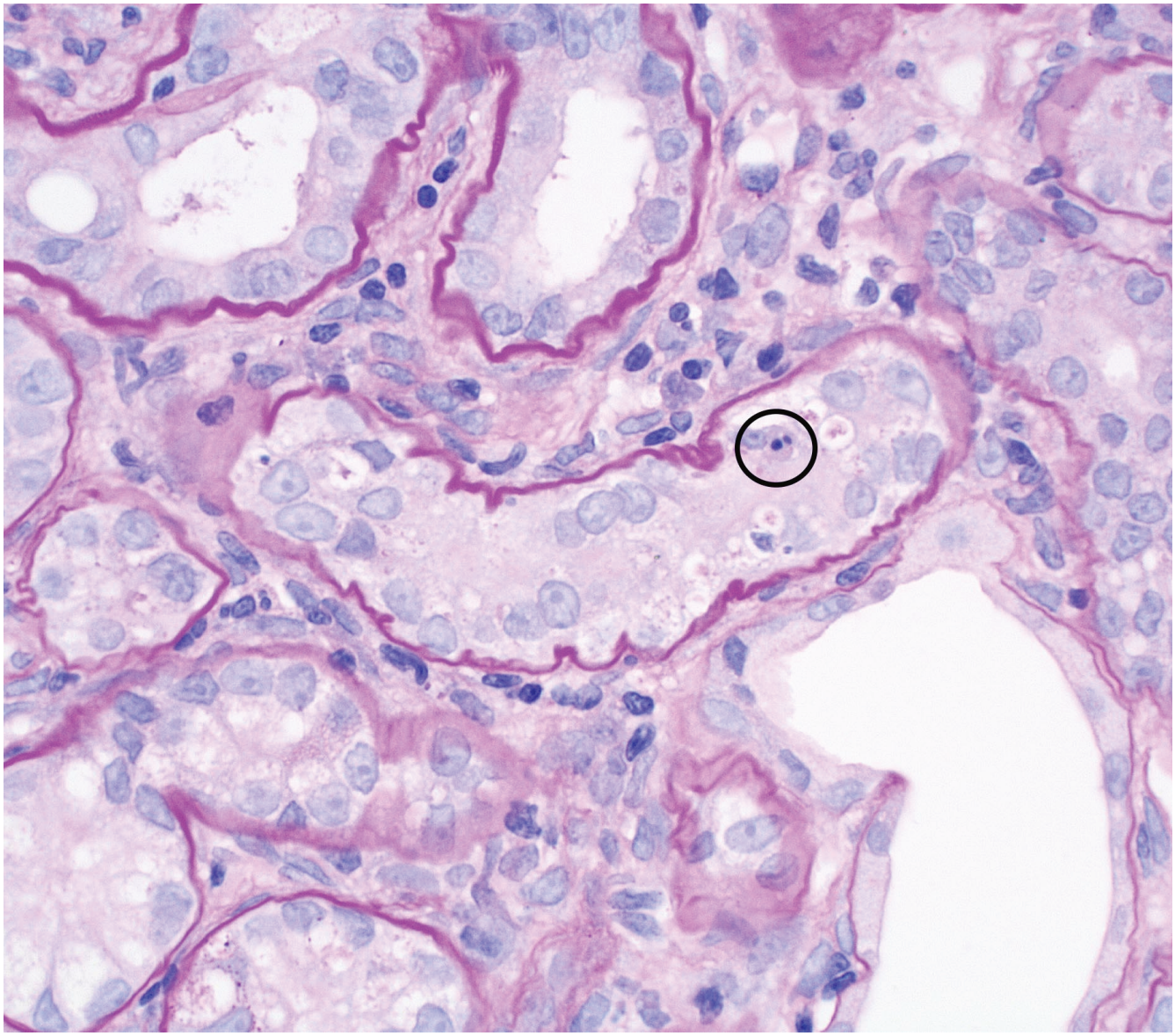

FIG.5C (PAS): This tubule also had a pyknotic epithelial cell (circled) and the remaining nuclei vary from closely crowded to absent. Most tubular basement membranes are mildly wrinkled. Other tubules are characterized by loss of the apical brush border.

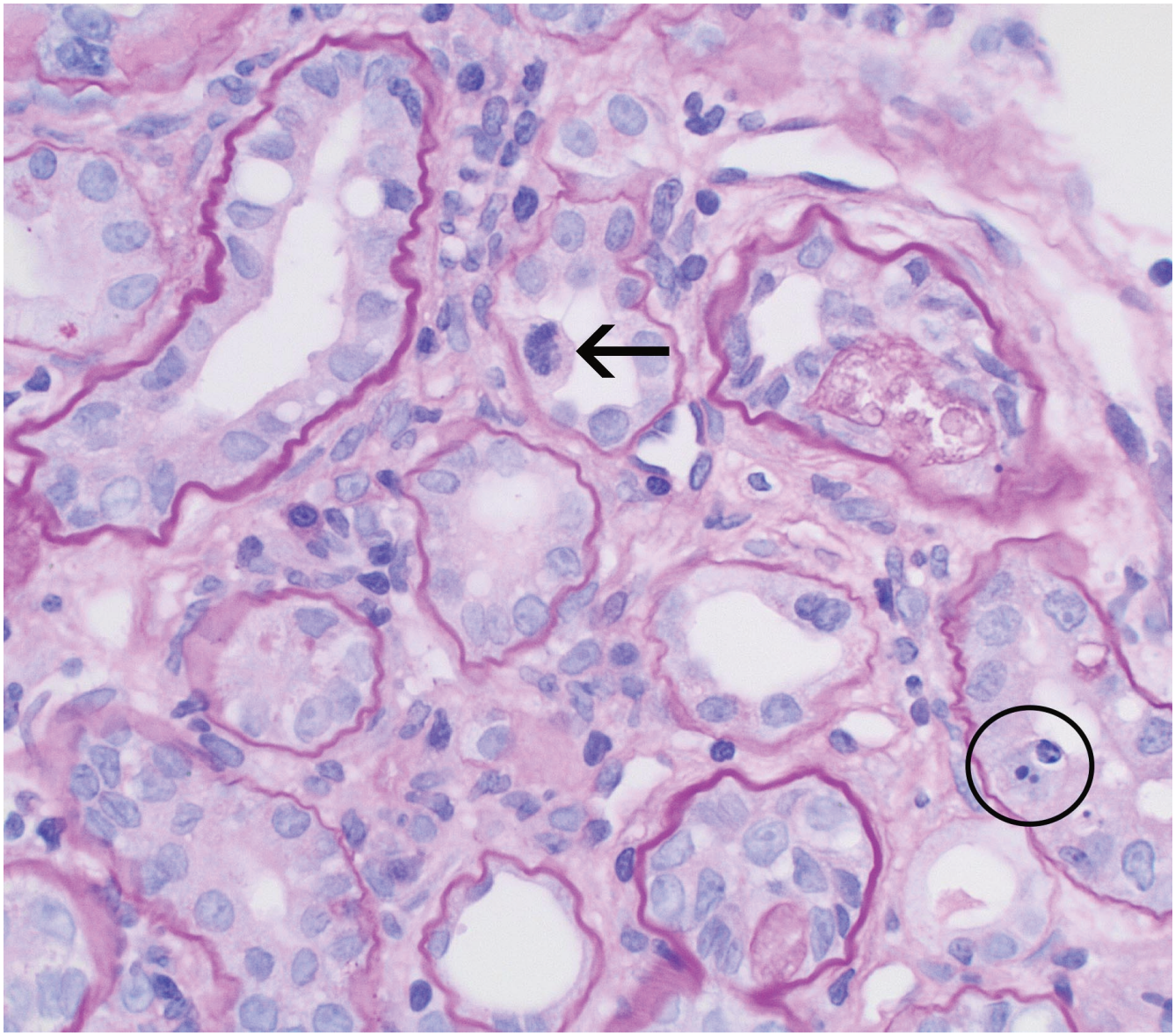

FIG.5D (PAS): This tubule has 2 cells with pyknotic nuclei (circled), whereas mitotic figures are also observed (arrow) indicating tubular epithelial regeneration. Tubular basement membranes are mildly wrinkled.

ERYTHROCYTE CASTS (RED BLOOD CELL CASTS /RBC CASTS) suggest an acute glomerulonephritis or trauma to the kidney. When passed into the urine they can be a non-invasive way to detect activity of a glomerular disease; however, RBC casts are more often used a biomarker in humans than in dogs.

An interactive or media element has been excluded from this version of the text. You can view it online here:
https://ohiostate.pressbooks.pub/vetrenalpathatlas/?p=456

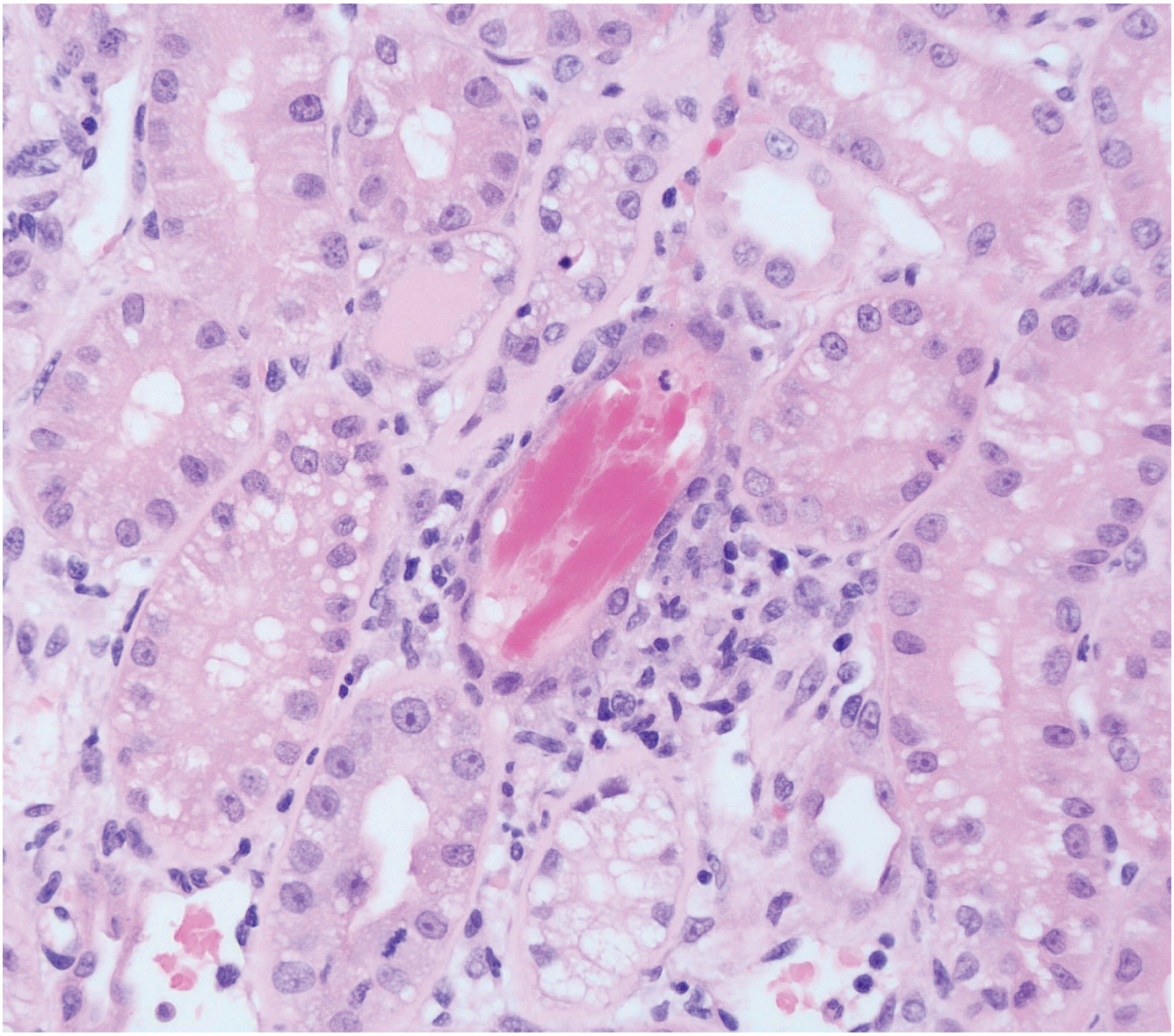

FIG.6A (HE): This tubule contains linear red to pink casts (RBC casts), which indicate that the glomerular capillary walls have been damaged, allowing passage of erythrocytes though the glomerular filtration barrier. Once in the tubular lumens, they are often degraded and mixed with proteins such as Tamm Horsfall mucoprotein.

An interactive or media element has been excluded from this version of the text. You can view it online here:
https://ohiostate.pressbooks.pub/vetrenalpathatlas/?p=456

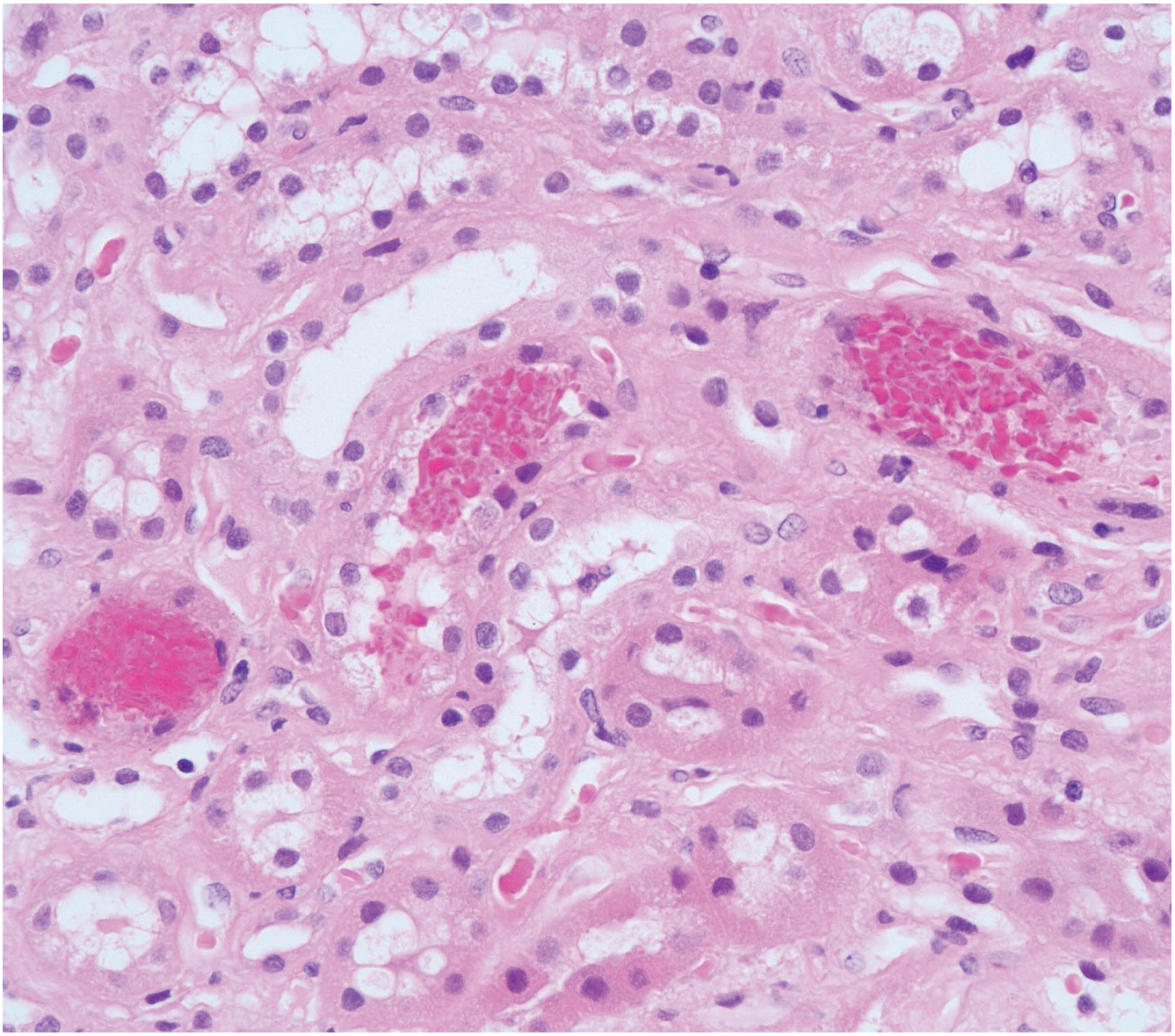

FIG.6B (HE): Sometimes, the red blood cells in tubular lumens appear as short polyhedral structures (compare to FIG 6A).

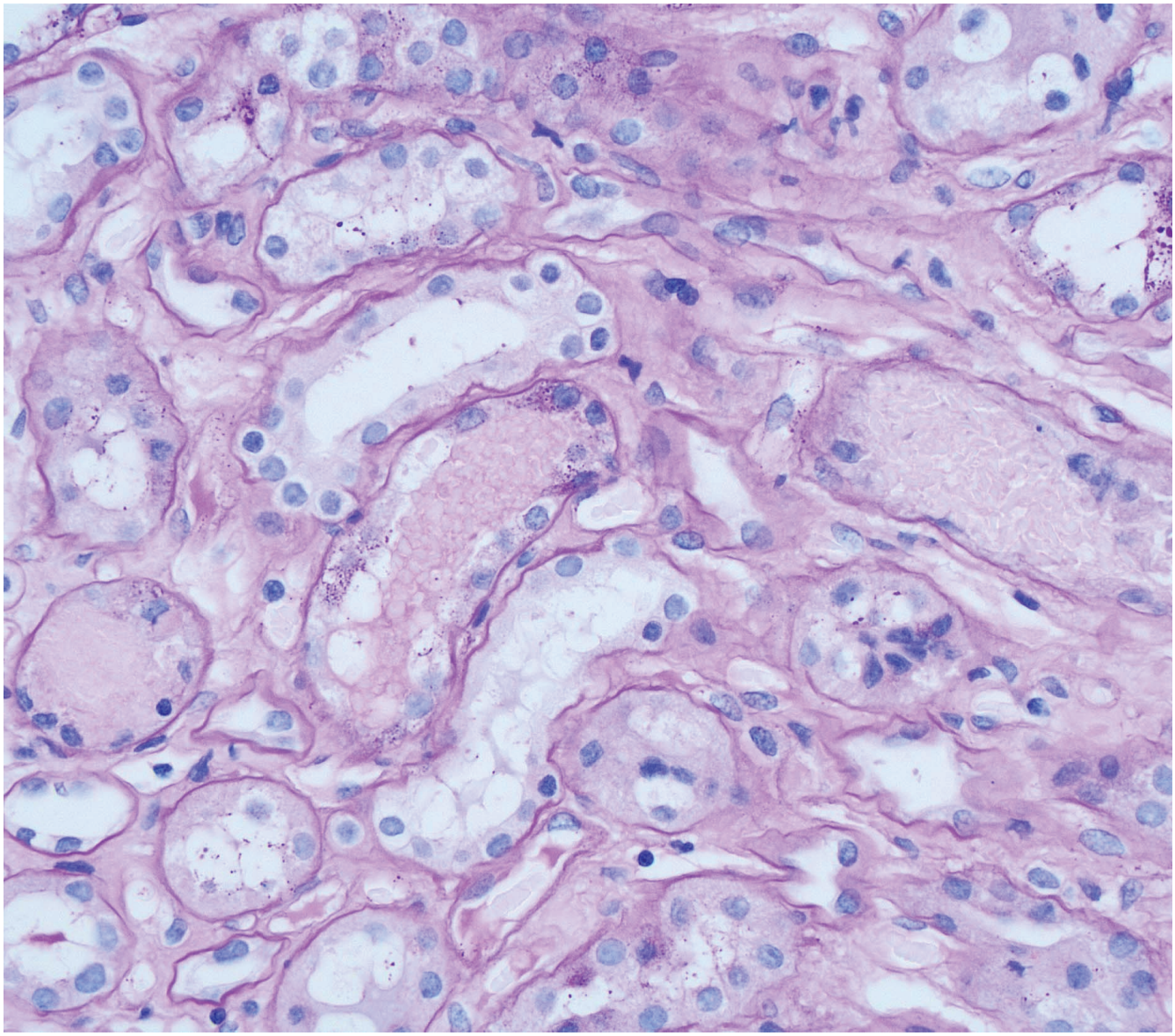

FIG.6C (PAS): Red blood cell casts should be pale pink when stained with PAS, compared to proteins casts which are often brighter pink.

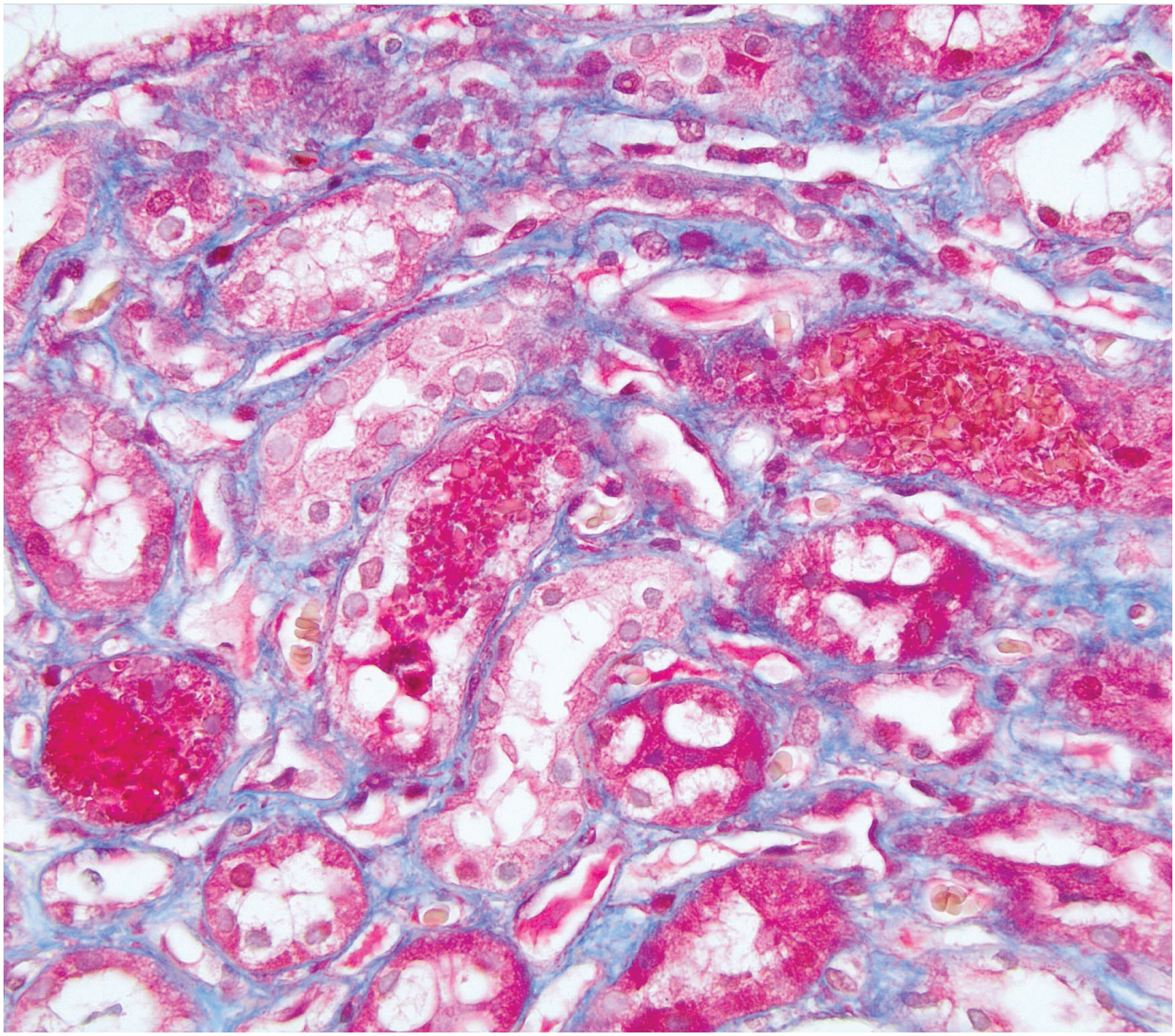

FIG.6D (MT): With MT, the erythrocytes are bright red to orange.

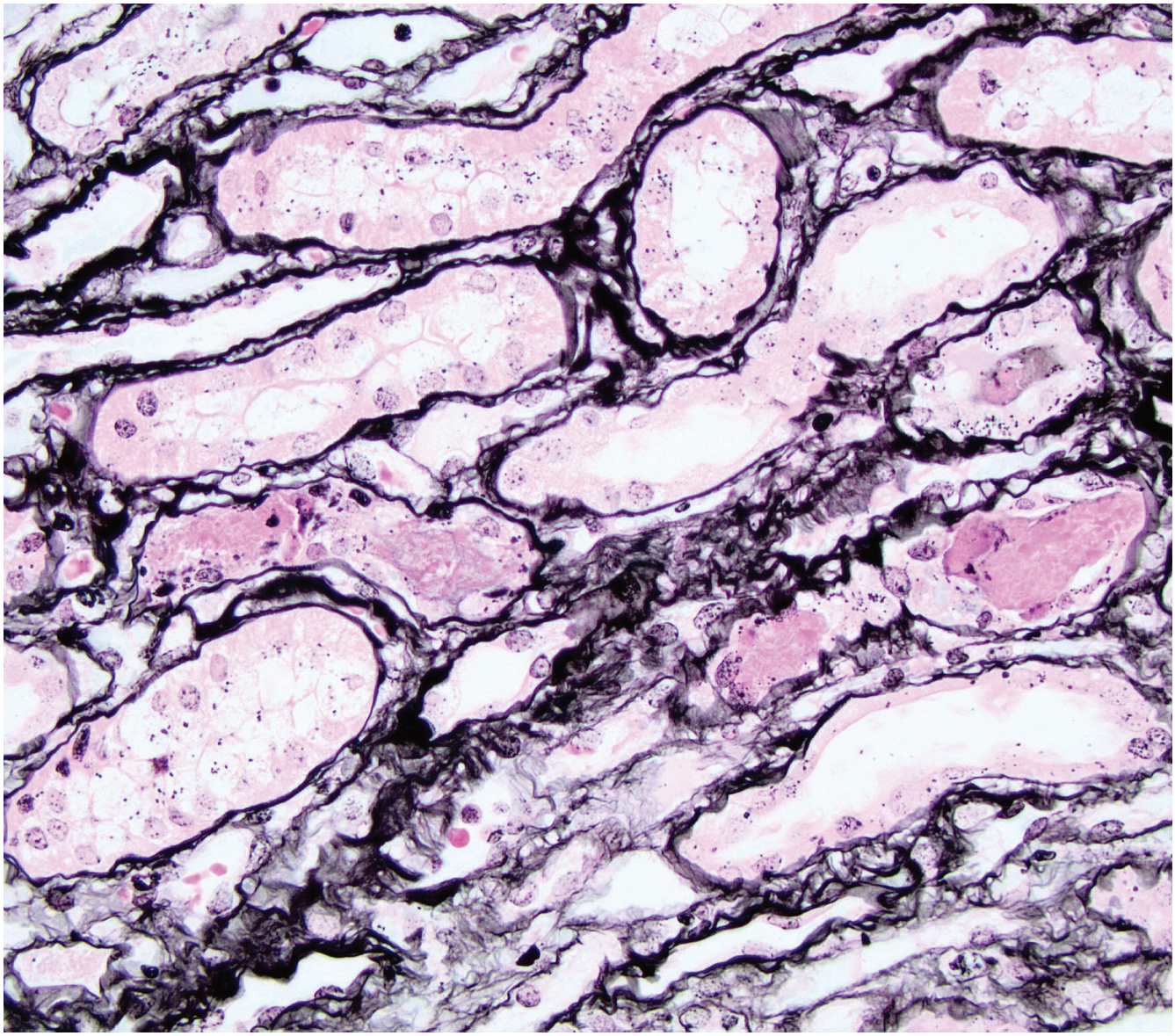

FIG.6E (JMS): Red blood cells do not take up silver so they are usually the color of the counterstain, in this case pink.

INTERSTITIAL INFLAMMATION is typically composed of lymphocytes and plasma cells. Macrophages may also be present, while neutrophils are not usually seen when the inflammation is secondary to glomerular disease.

An interactive or media element has been excluded from this version of the text. You can view it online here:
https://ohiostate.pressbooks.pub/vetrenalpathatlas/?p=456

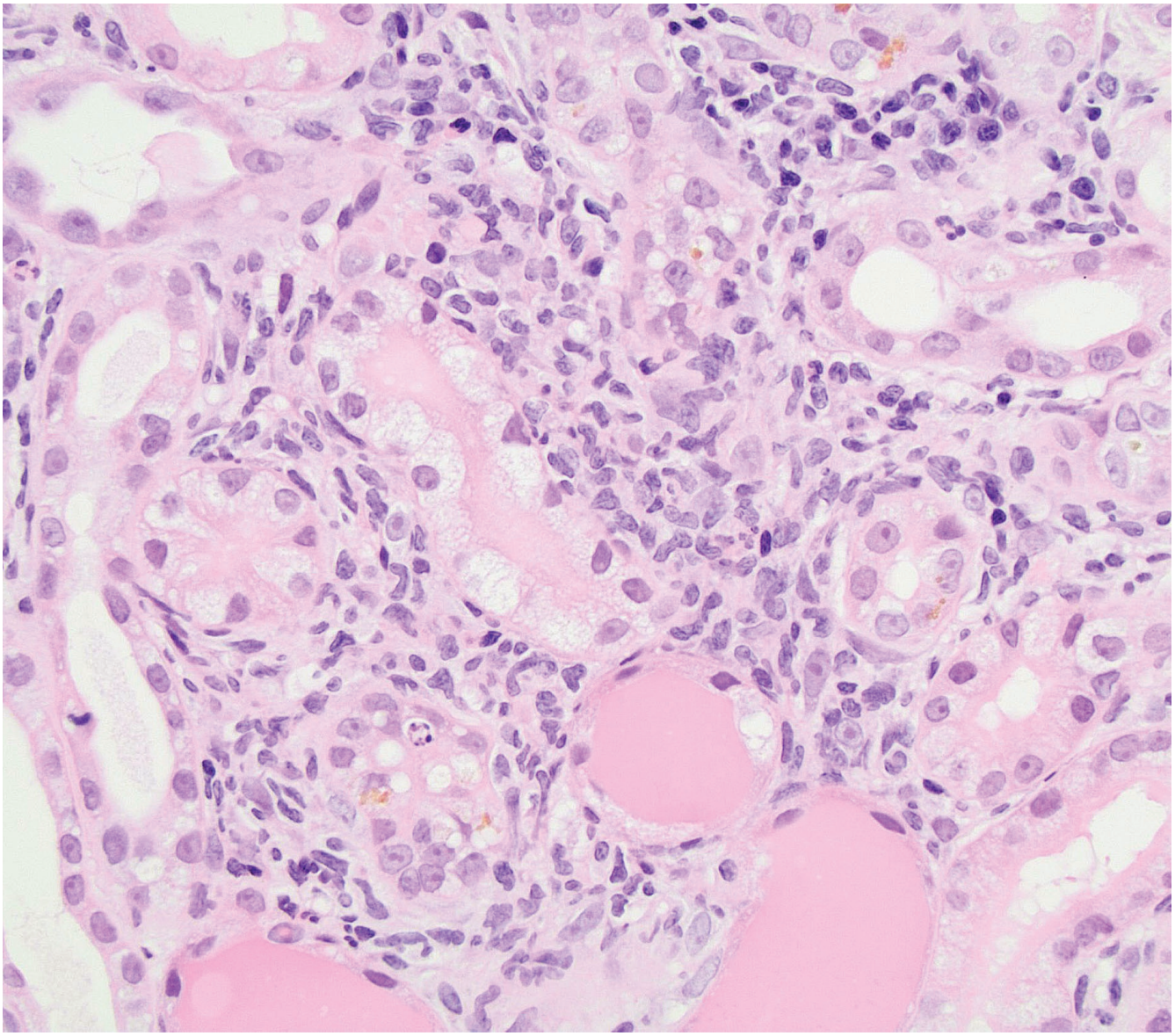

FIG.7A (HE): Tubules are moderately separated by mixed inflammatory infiltrates including lymphocytes, macrophages, plasma cells and neutrophils. There is also associated cytoplasmic vacuolization, cell necrosis, tubular attenuation, and large protein casts.

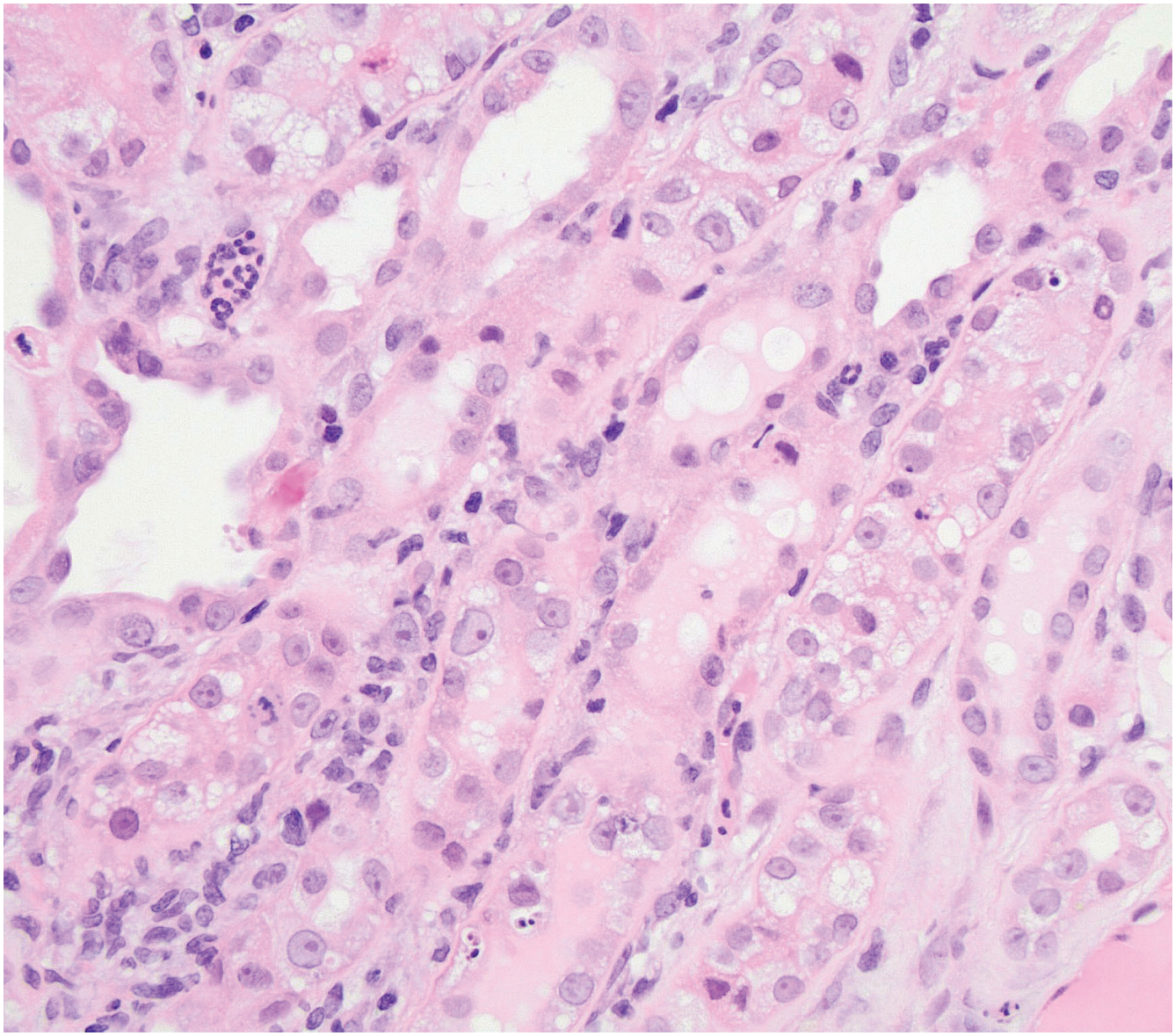

FIG.7B (HE): Neutrophils frequently surround degenerating tubules and sometimes are found in small aggregates. Tubular degeneration is characterized by loss of the brush borders, have swollen vacuolated cytoplasm and often contained sloughed pyknotic cells.

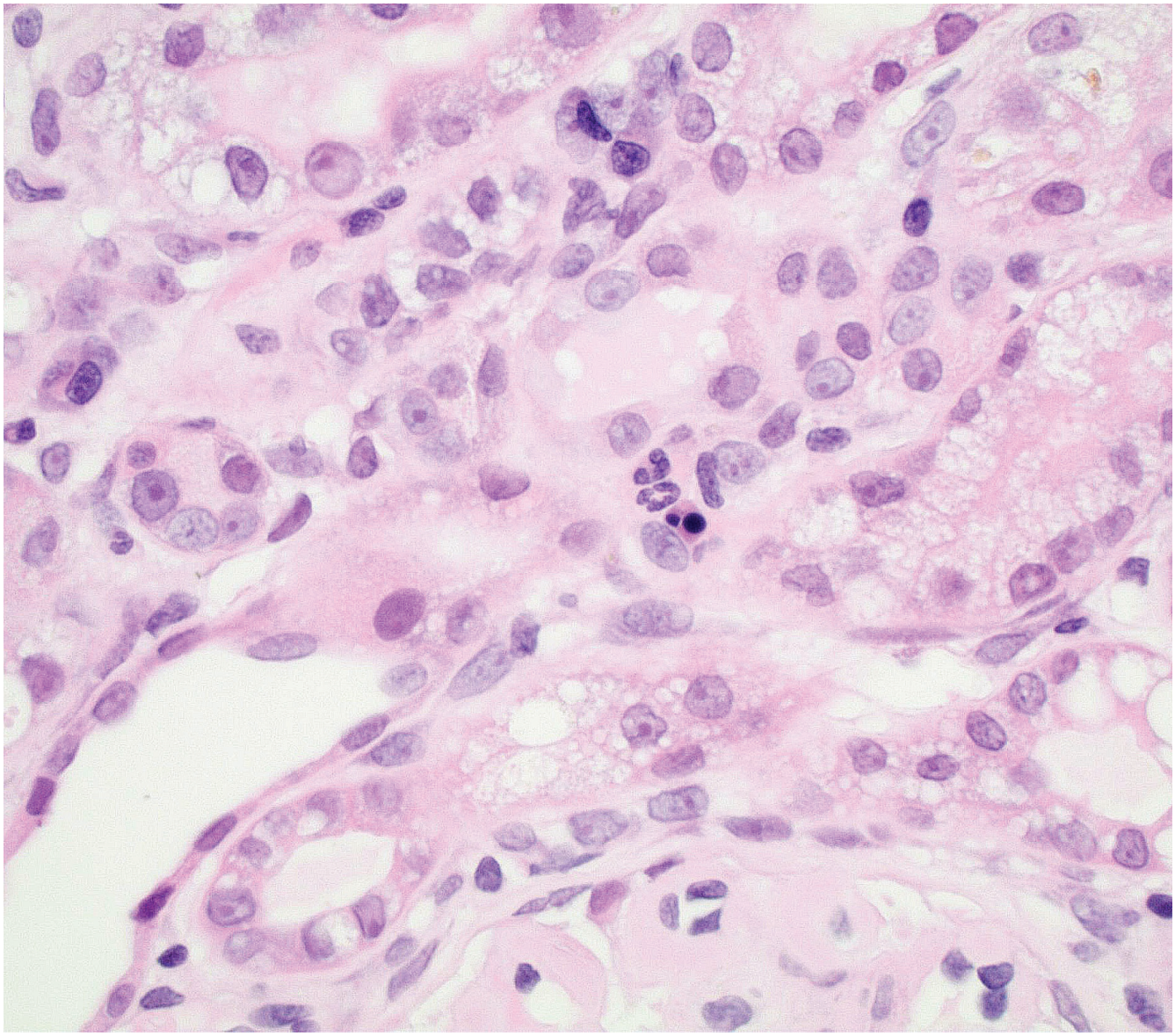

FIG.7C (HE): A few neutrophils and a pyknotic cell are adjacent to a degenerating tubule.

An interactive or media element has been excluded from this version of the text. You can view it online here:
https://ohiostate.pressbooks.pub/vetrenalpathatlas/?p=456

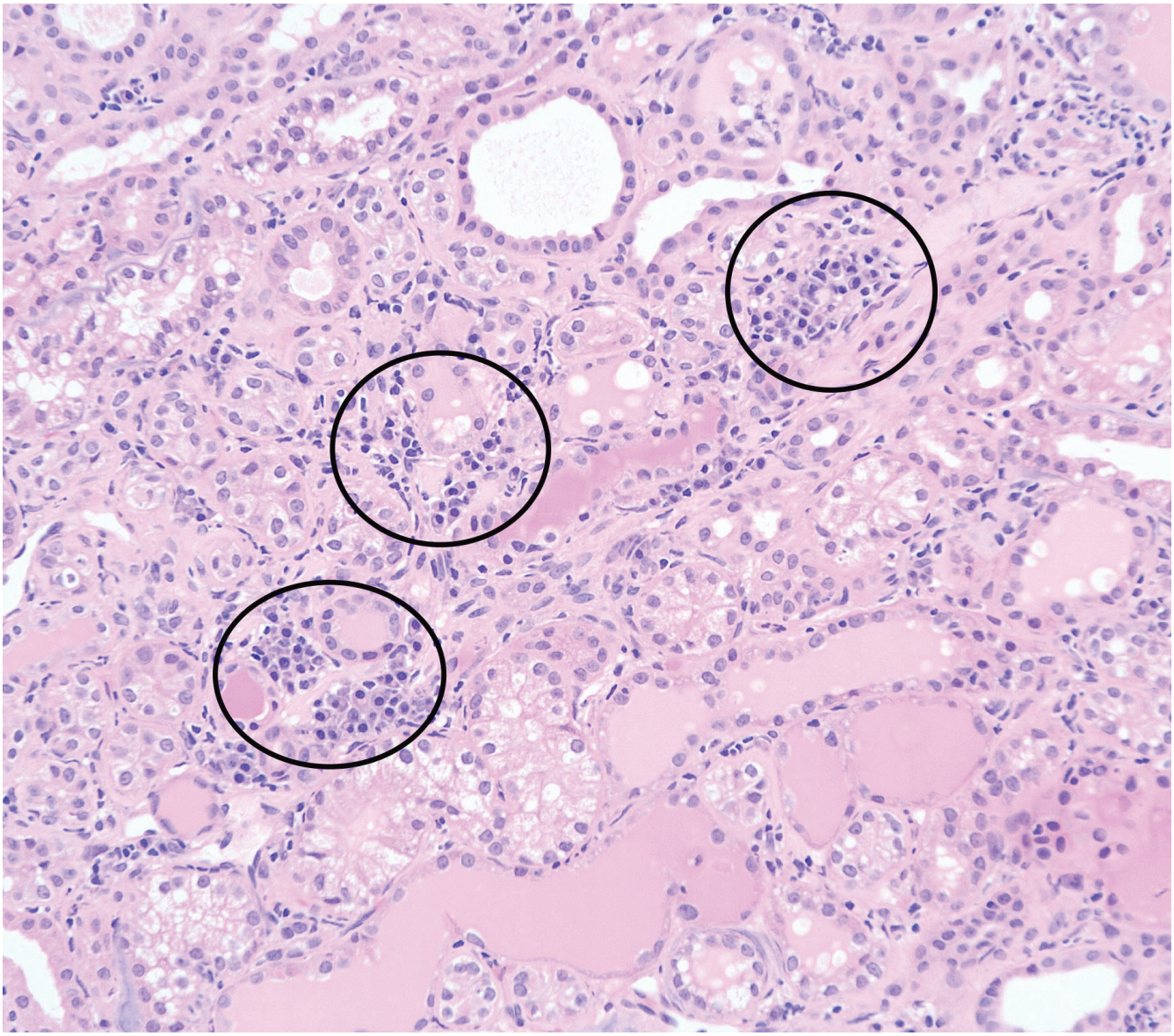

FIG.7D (HE): Individual and small aggregates of 10 to 20 lymphocytes and plasma cells are scattered throughout the interstitium (circled). Tubules are dilated and many contain protein casts.

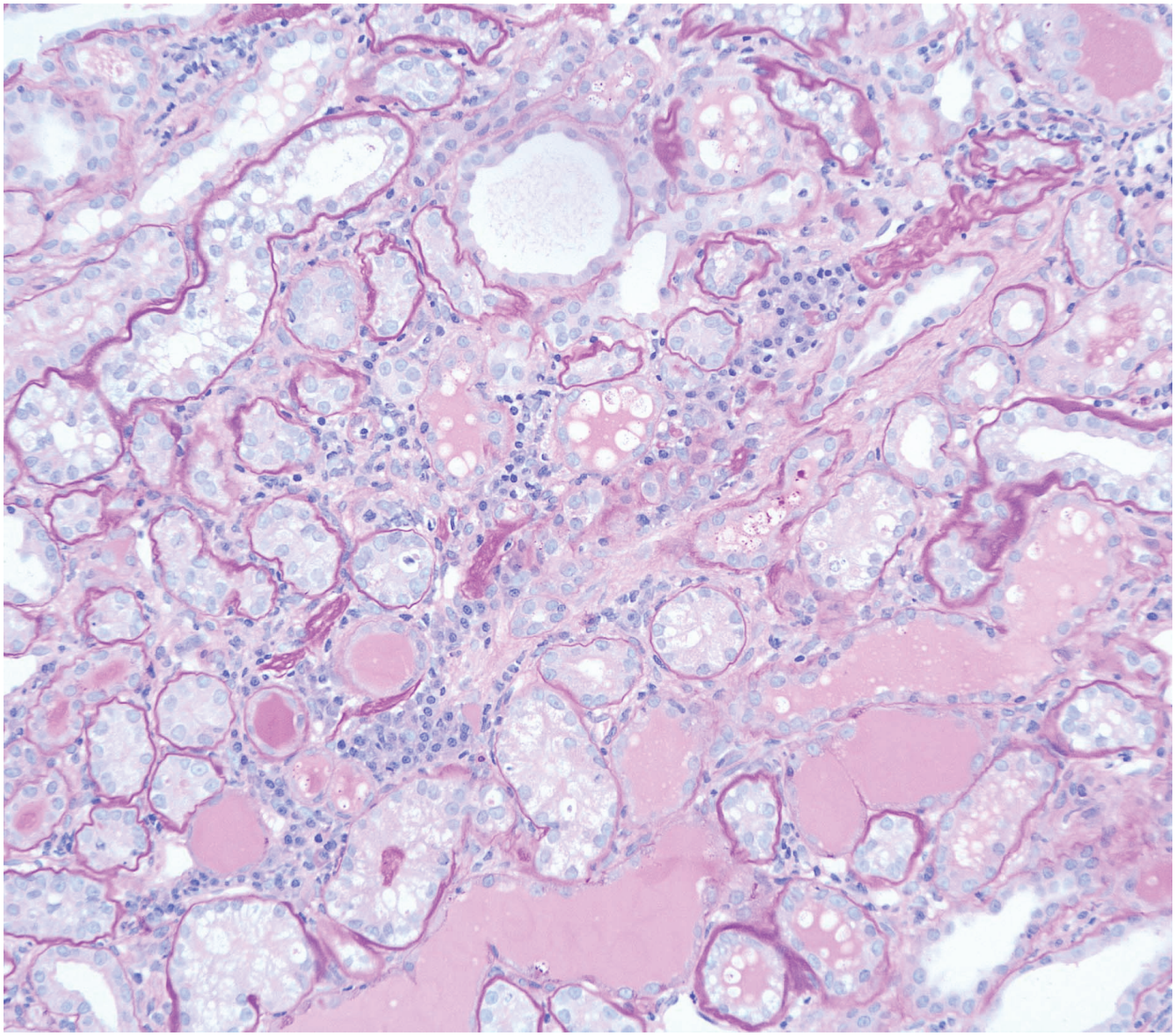

FIG.7E (PAS): It is more difficult to discern plamsa cells from lymphocytes with the PAS stain; however, this stain highlights the protein casts and demonstrates that there are atrophic tubules with wrinkled basement membranes hidden within the inflammatory aggregates.

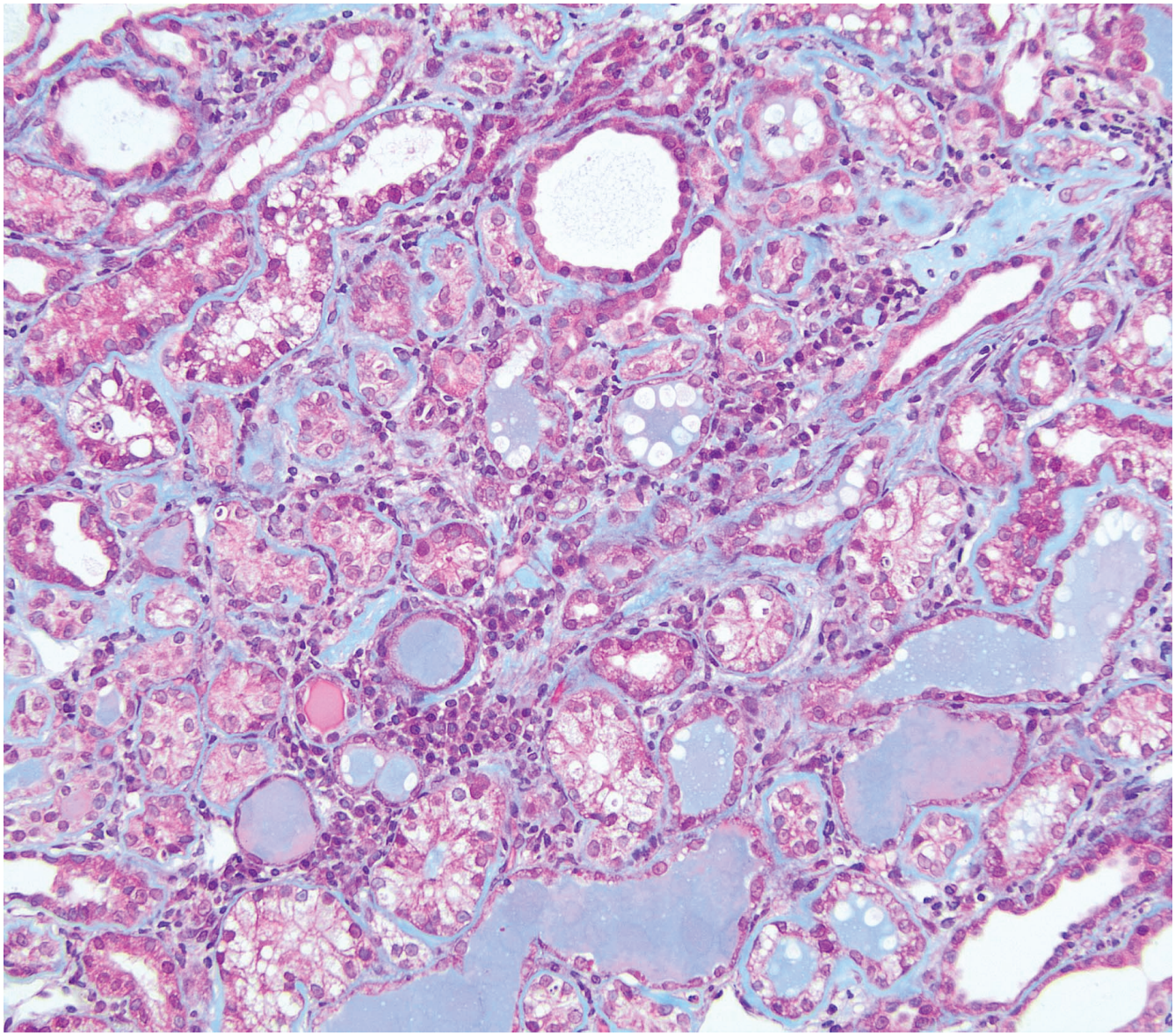

FIG.7F (MT): Similar to the PAS stain, discerning plasma cells from lymphocytes is difficult with MT. This stain shows that there is only minimal interstitial fibrosis and that separation of tubules is due to the interstitial inflammation and the thickened, atrophic tubules with wrinkled basement membranes.

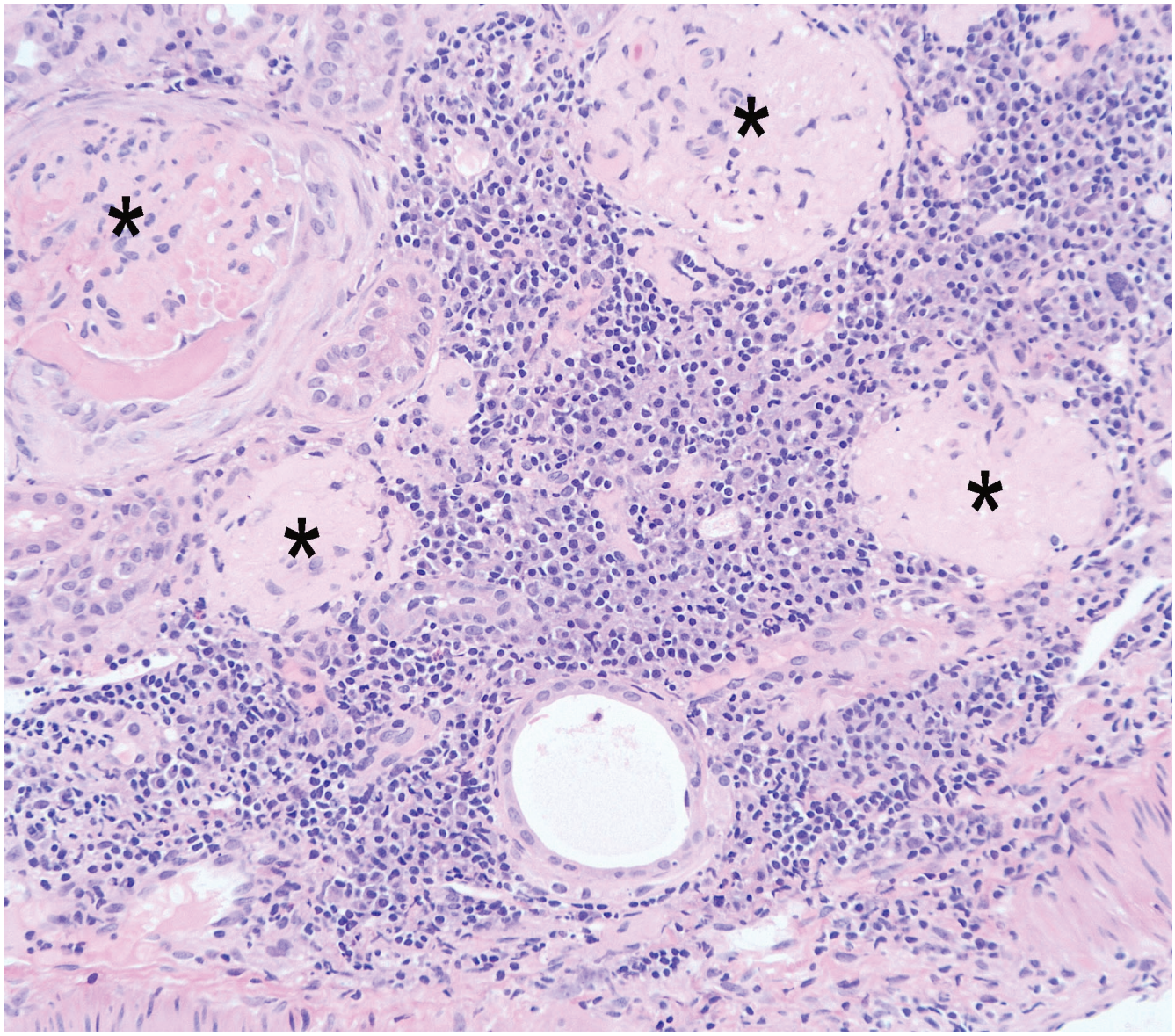

FIG.7G (HE): In some regions of the biopsy from the same patient as FIG.7A-C, there are larger regions of severe lymphoplasmacytic inflammation which replace tubules. The glomeruli in these regions are globally sclerotic (*).

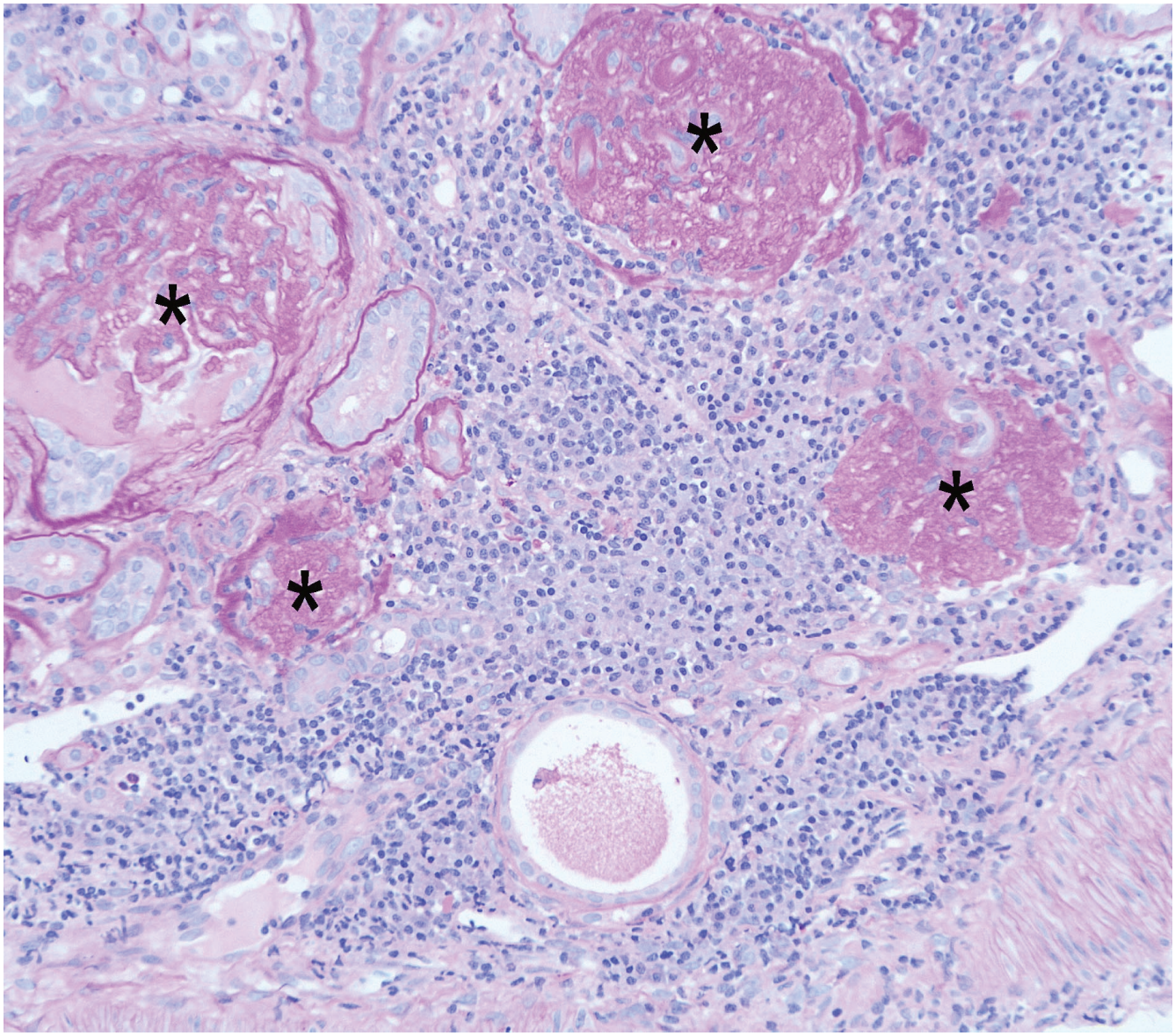

FIG.7H (PAS): The globally sclerotic and obsolescent glomeruli (*) sometimes are hypocellular meshworks of basement membrane material and the glomerulus at the right side of the image is no longer surrounded by a Bowman's capsule. There are few small remnants of tubular basement membranes from atrophic tubules scattered throughout the inflammation.

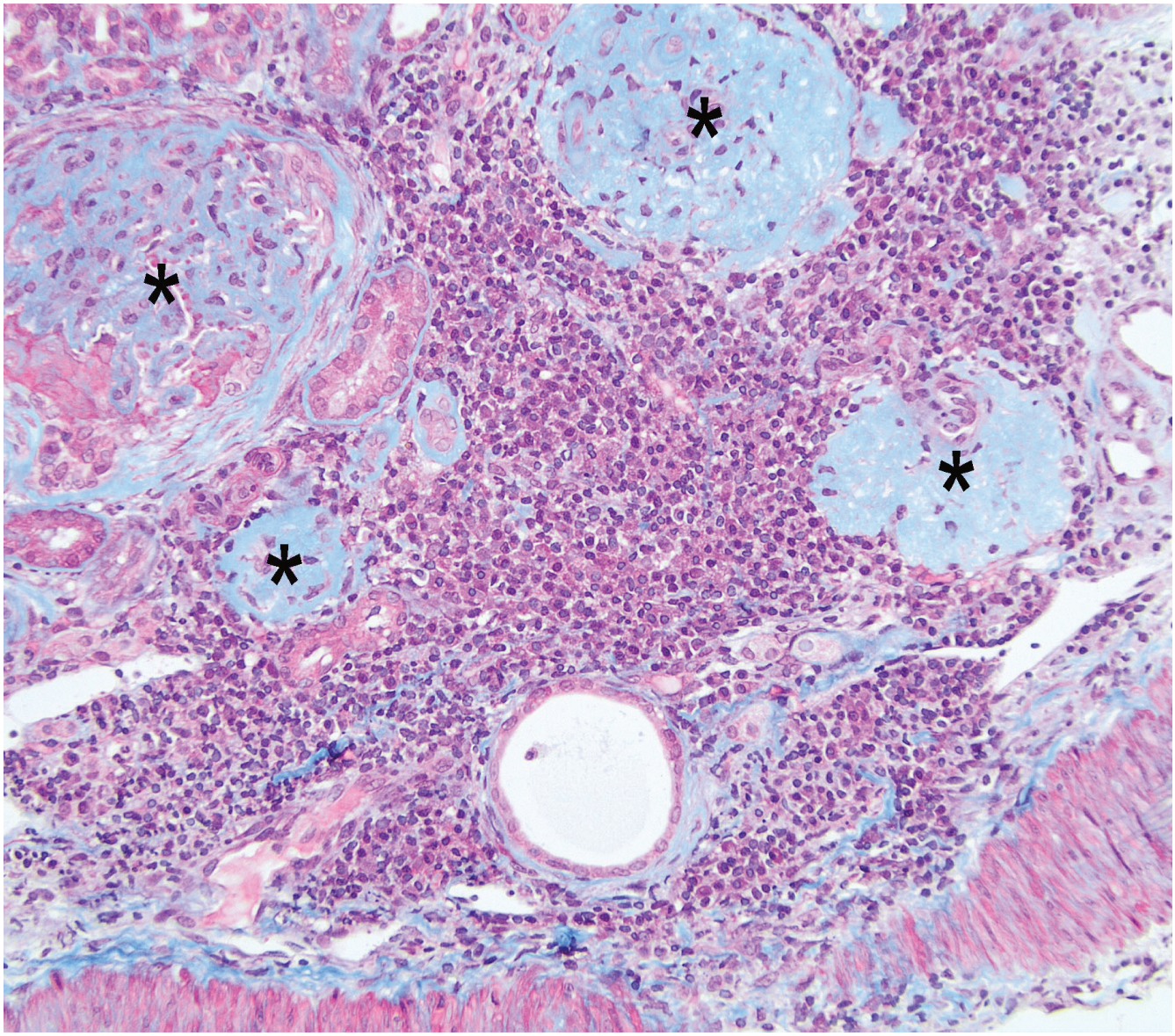

FIG.7I (MT): The MT demonstrates that the replacement of tubules is due to interstitial inflammation and minimal interstitial fibrosis. The globally sclerotic and obsolescent glomeruli (*) are meshworks of basement membrane collagen.

INTERSTITIAL EDEMA is observed as a separation of tubules with rarefaction of the interstitial matrix. The interstitial fluid will stain faintly with trichrome stains whereas it will be dense blue if fibrosis

An interactive or media element has been excluded from this version of the text. You can view it online here:
https://ohiostate.pressbooks.pub/vetrenalpathatlas/?p=456

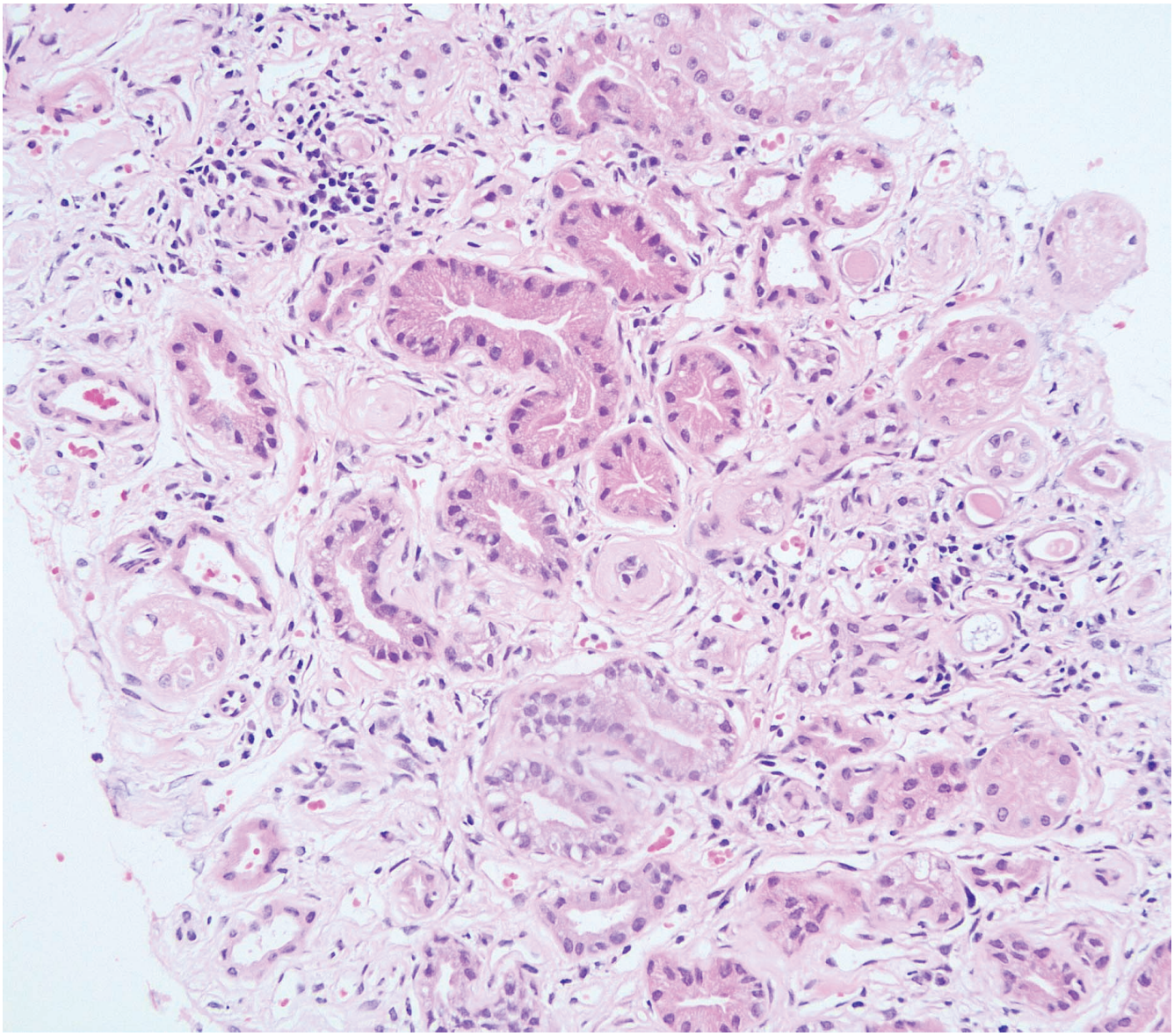

FIG.8A (HE): The interstitium is expanded and tubules are moderately separated; however, it is difficult to discern the type of expansion by HE. Therefore, the MT is required to discern how much of the expansion is collagen as opposed to edema.

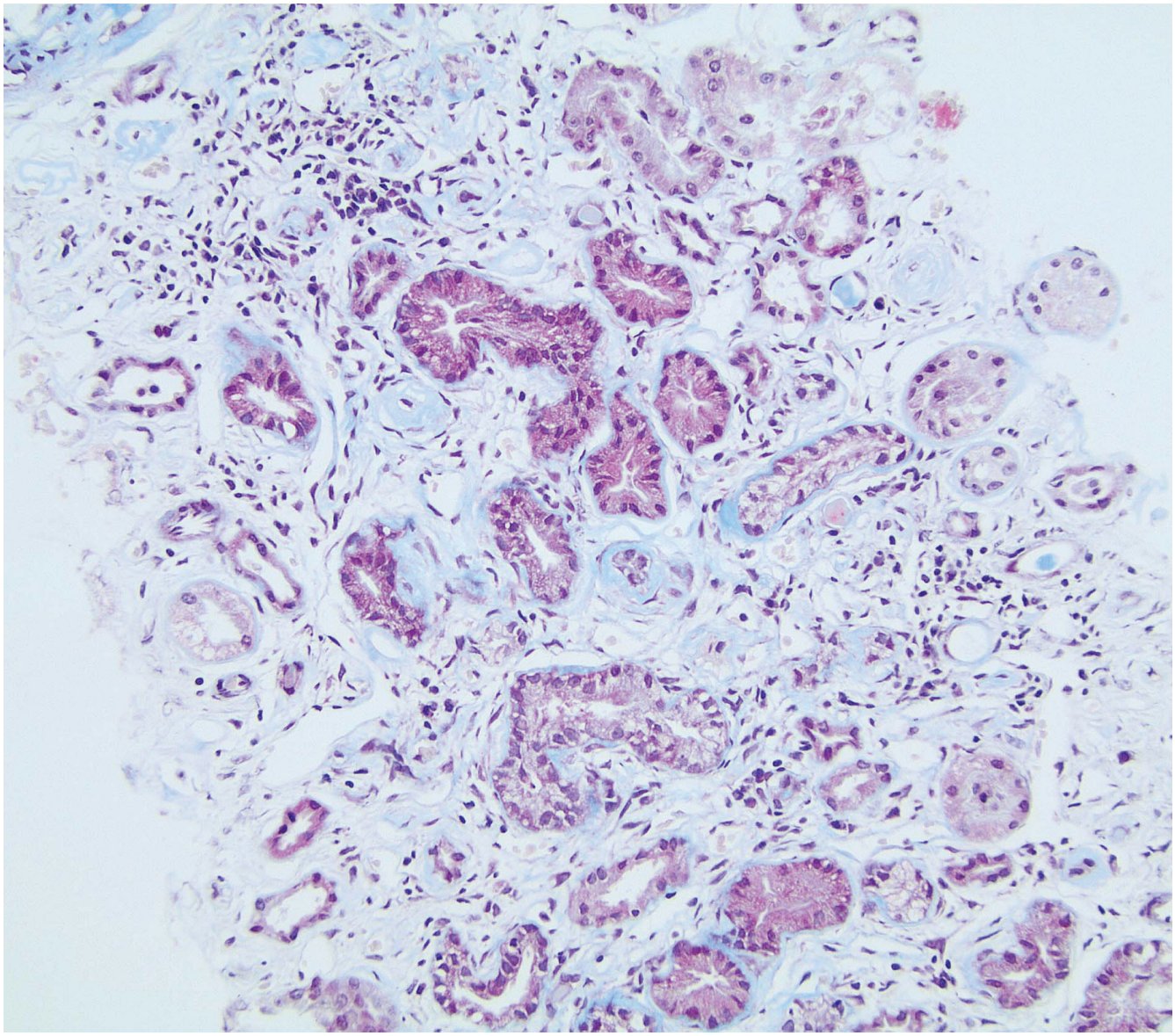

FIG.8B (MT): The MT of this same area delineates the interstital collagen (pale blue) from the tubular basement membrane collagen which is a brighter blue.

GLOMERULAR TUBULARIZATION refers to a lesion in which the parietal epithelium lining Bowman's capsule has a cuboidal to columnar morphology, as opposed to squamous. The cause is unknown and might represent replacement of lost squamous parietal epithelial cells by spreading of proximal tubular epithelium. Alternatively, it might be a reactive / metaplastic response of the original squamous parietal epithelium.

An interactive or media element has been excluded from this version of the text. You can view it online here:
https://ohiostate.pressbooks.pub/vetrenalpathatlas/?p=456

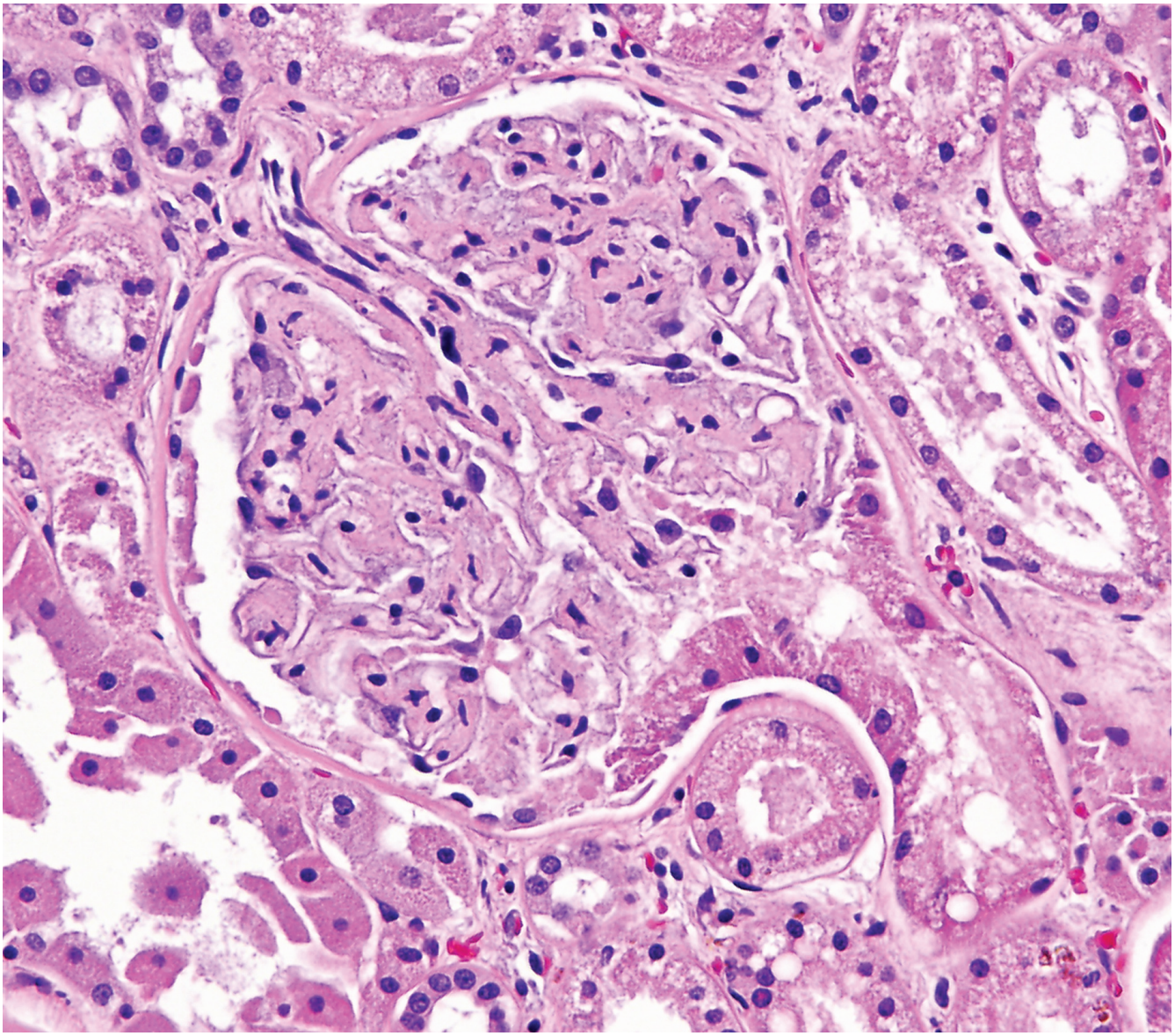

FIG.9A (HE): At the tubular pole, the parietal epithelium has changed from squamous to cuboidal columnar and it is continuous with the proximal tubular epithelium.

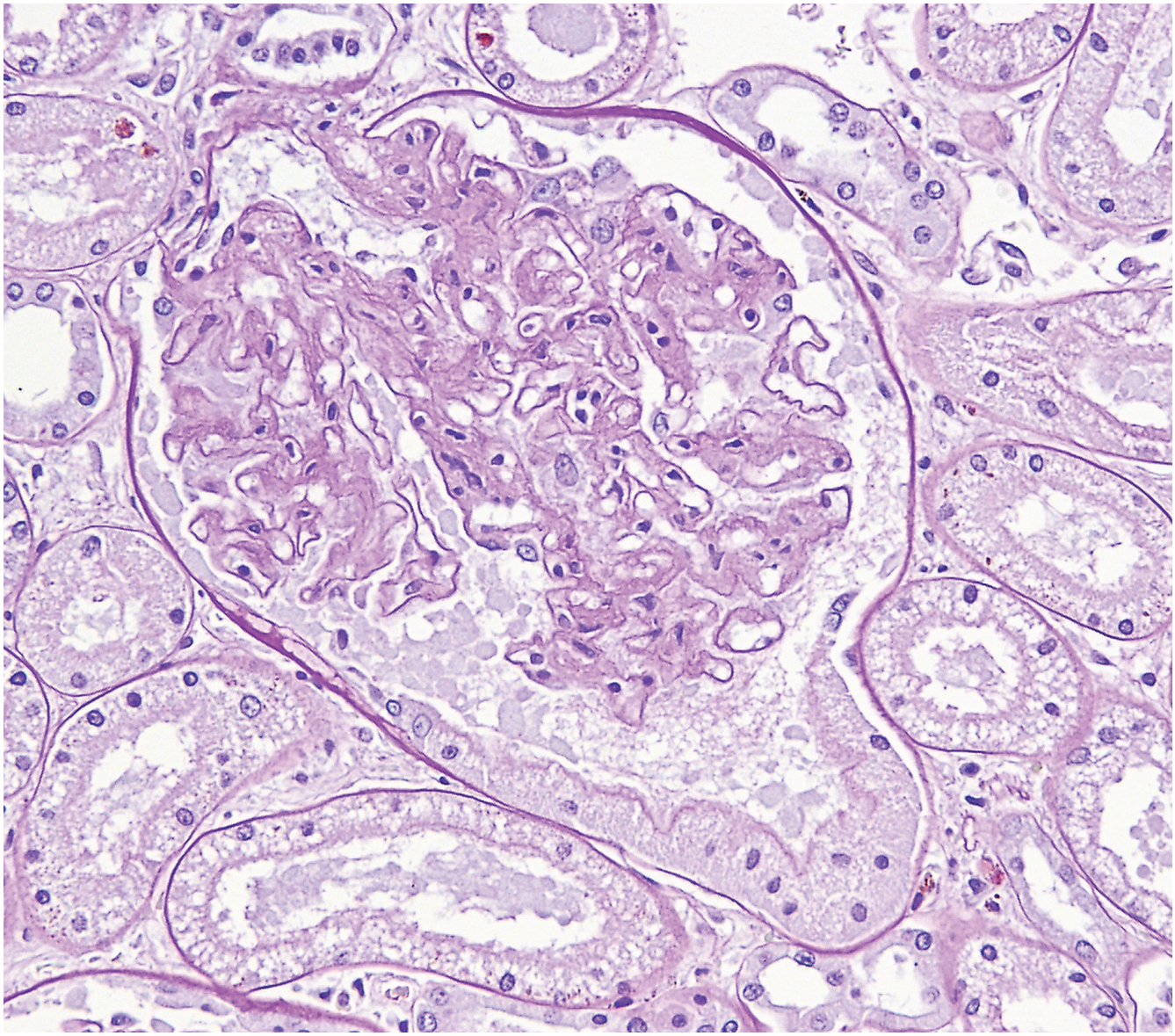

FIG.9B (PAS): The PAS stain of the same glomerulus demonstrates the presence of an apical brush border the parietal epithelial cells.

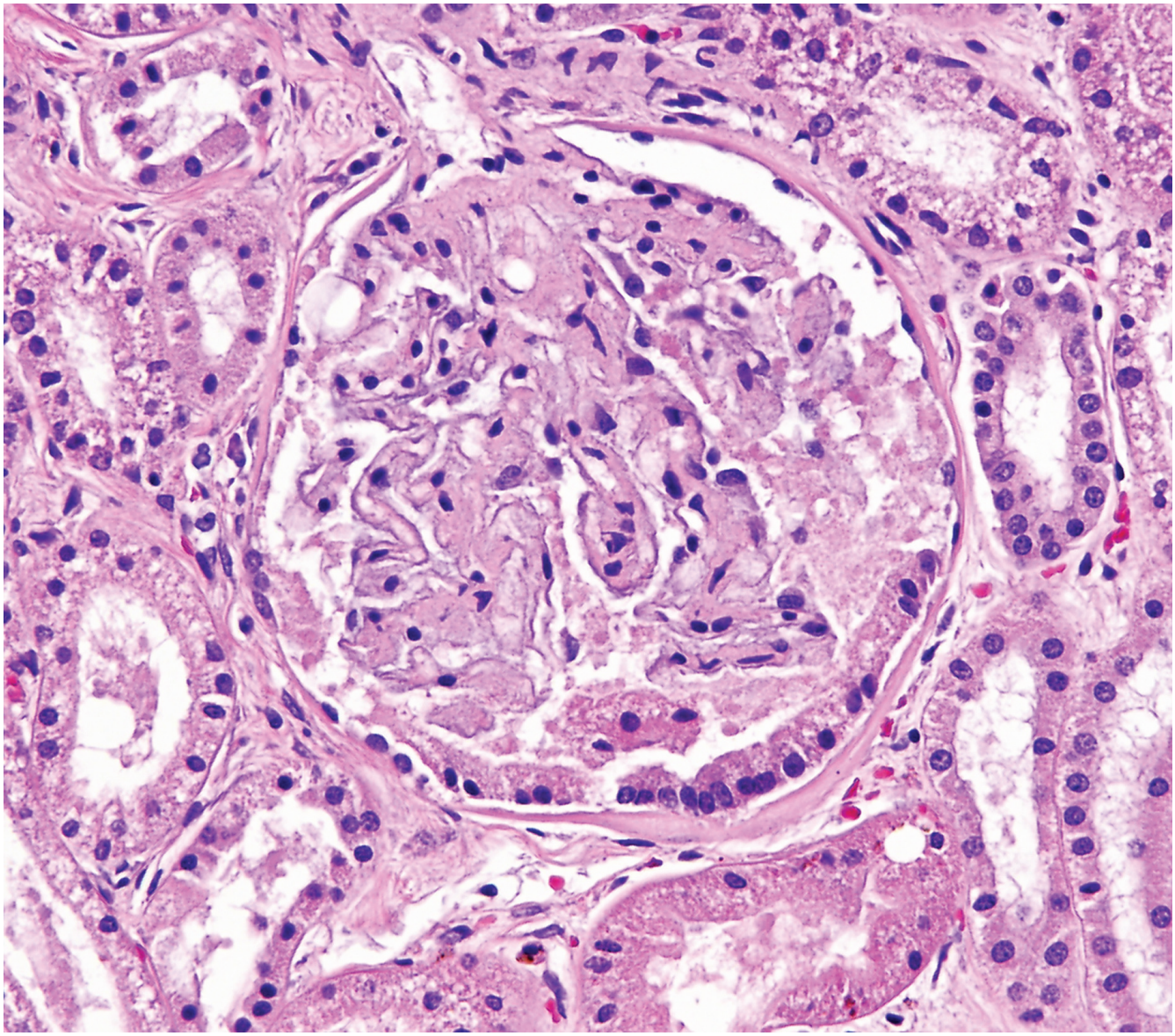

FIG.9C (HE): A different glomerulus from the same patient also demonstrates this lesion. The nuclei are basally located, similar to what is expected in proximal tubules.

TUBULAR MINERALIZATION can be seen in proteinuric dogs with severe azotemia and associated hyperphosphatemia with or without hypercalcemia.

An interactive or media element has been excluded from this version of the text. You can view it online here:
https://ohiostate.pressbooks.pub/vetrenalpathatlas/?p=456

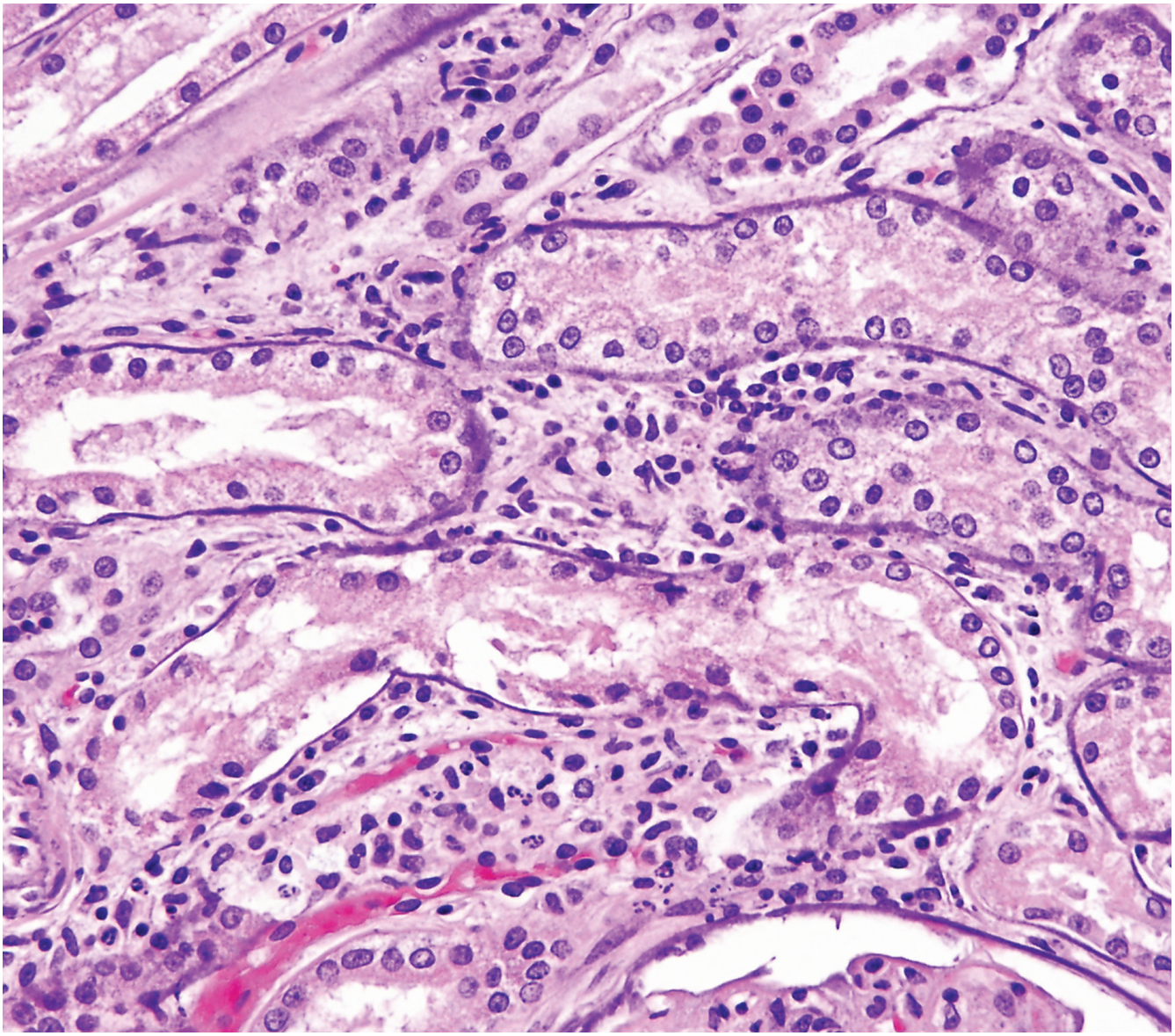

FIG.10A (HE): The mineral is basophilic and encircles all tubules as well as Bowman's capsule basement membrane (lower right of image). There is also moderate interstitial inflammation.

An interactive or media element has been excluded from this version of the text. You can view it online here:
https://ohiostate.pressbooks.pub/vetrenalpathatlas/?p=456

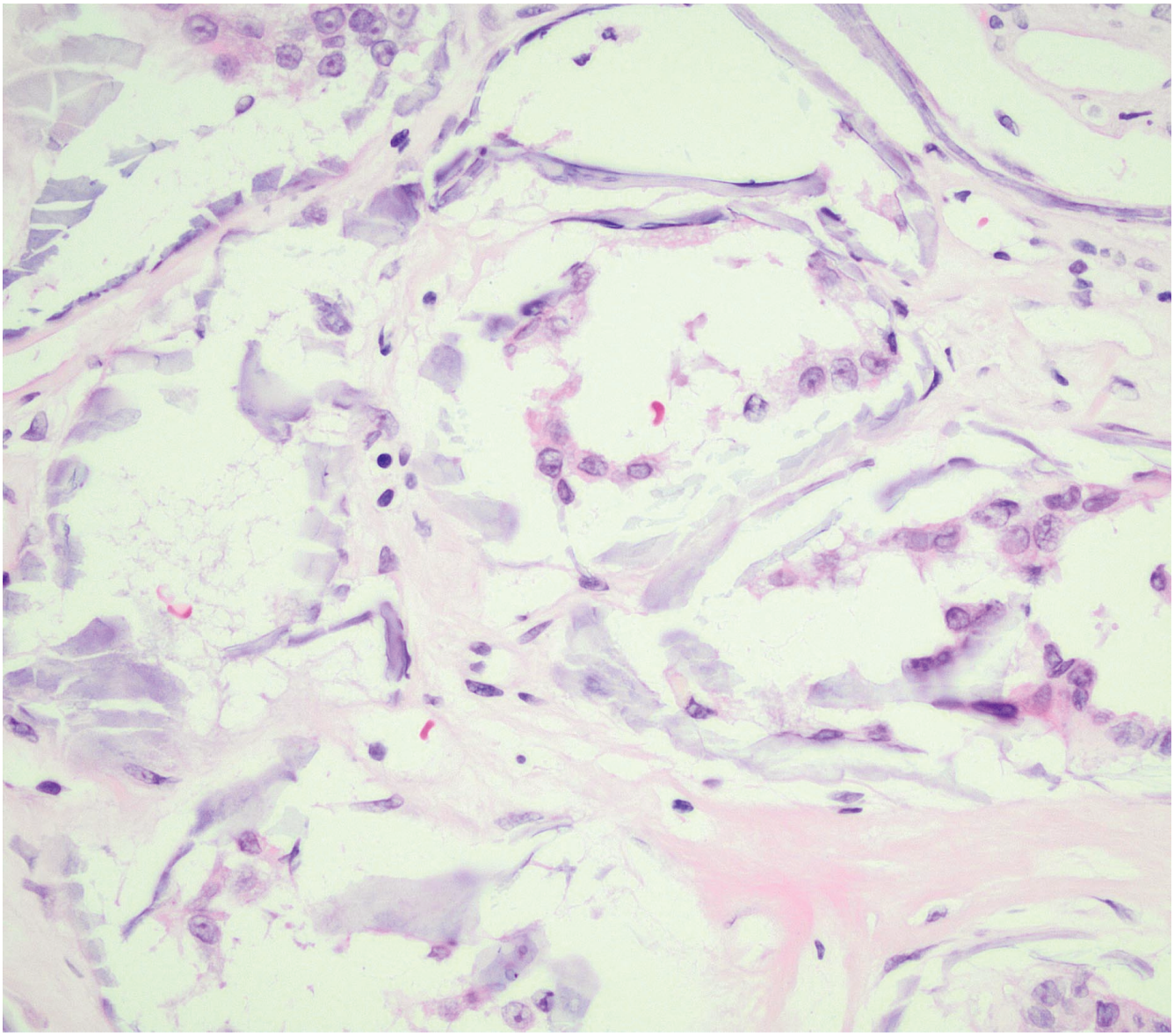

FIG.10B (HE): With mineralization of tubular basement membranes, there is often disruption / fracturing of the tissue during slide sectioning.

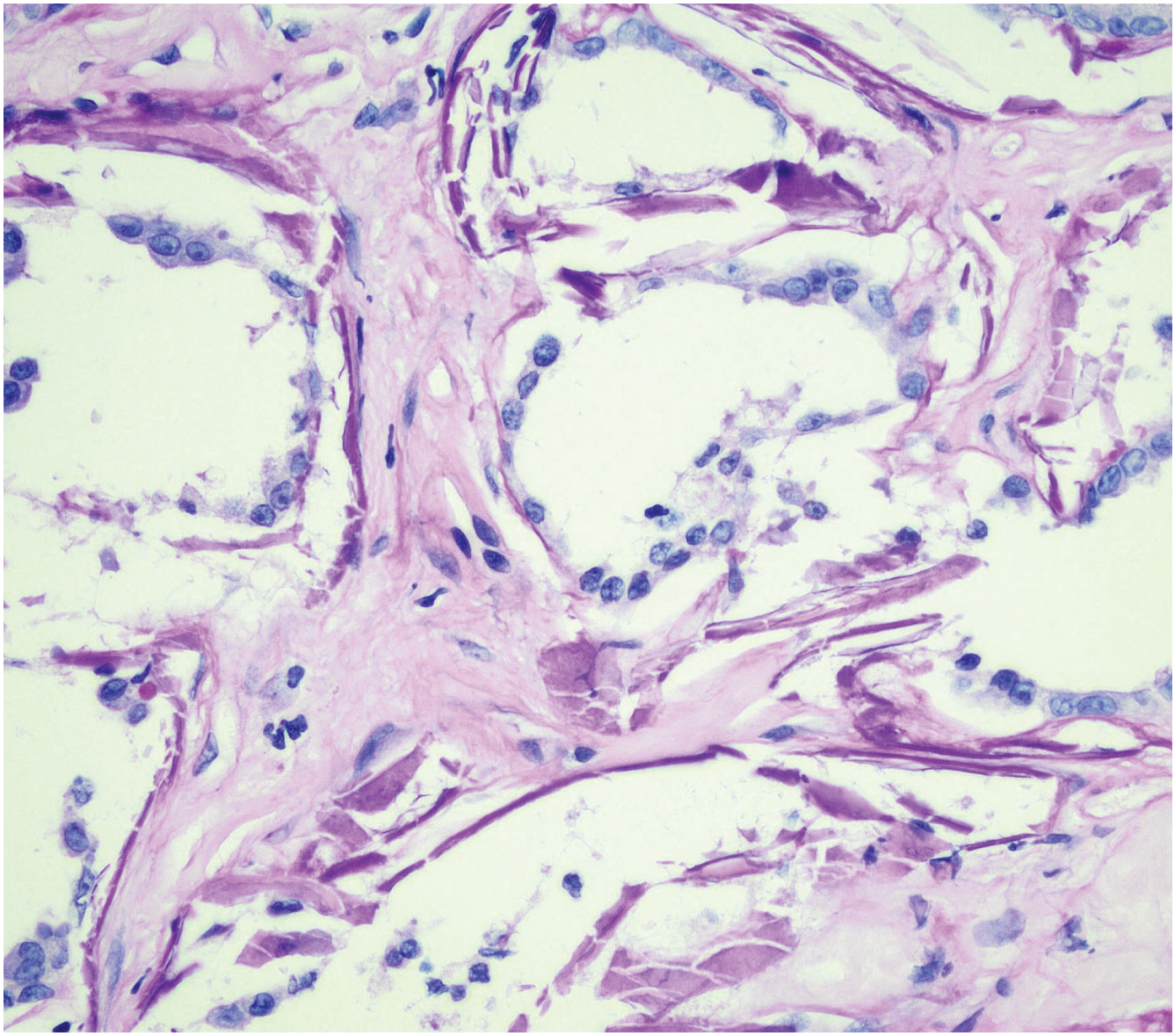

FIG.10C (PAS): With the PAS stain, the mineral is bright pink / magenta.

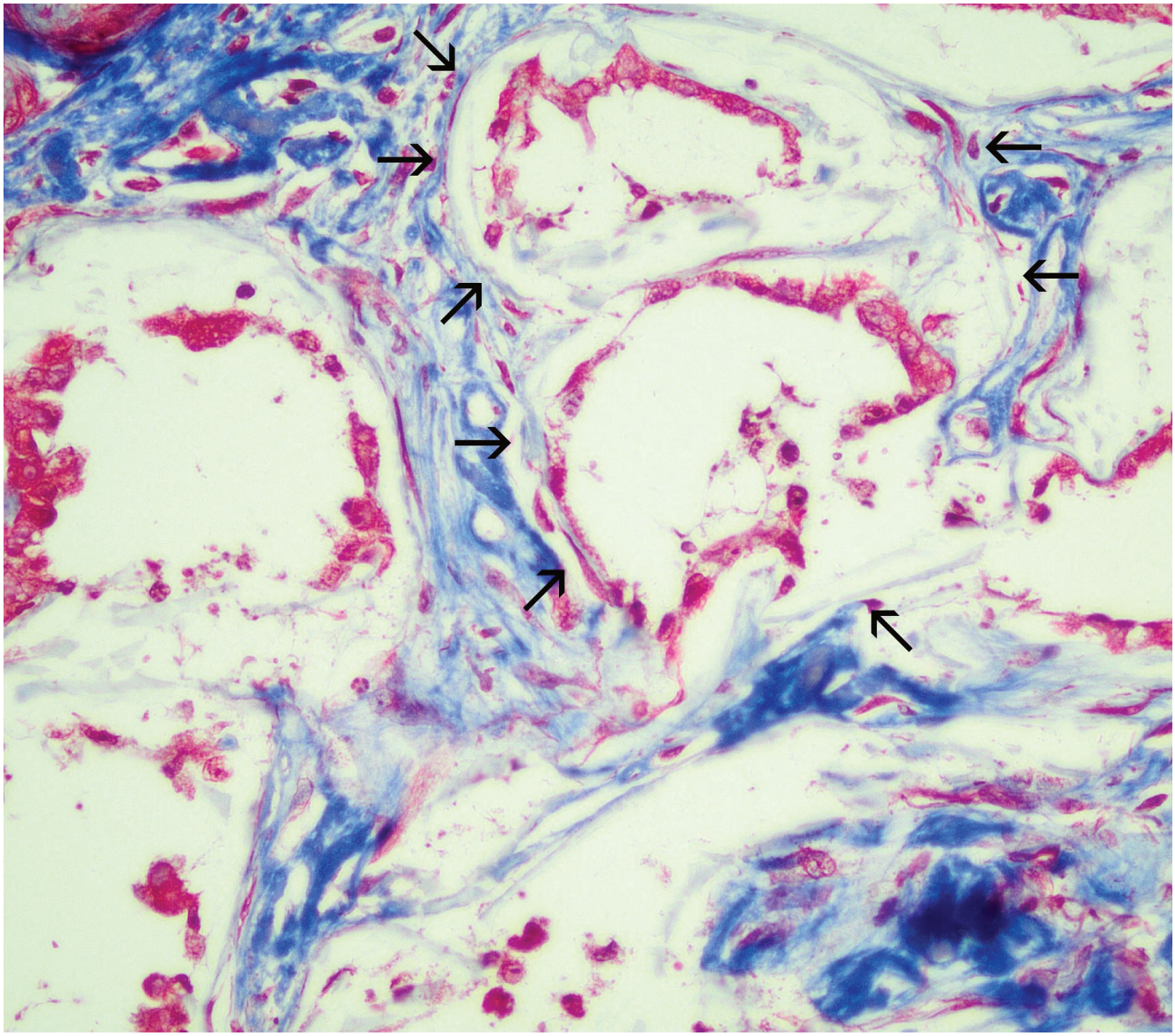

FIG.10D (MT): Note the dense interstitial fibrosis surrounding the tubules with pale blue mineralization of the basement membranes (arrows).

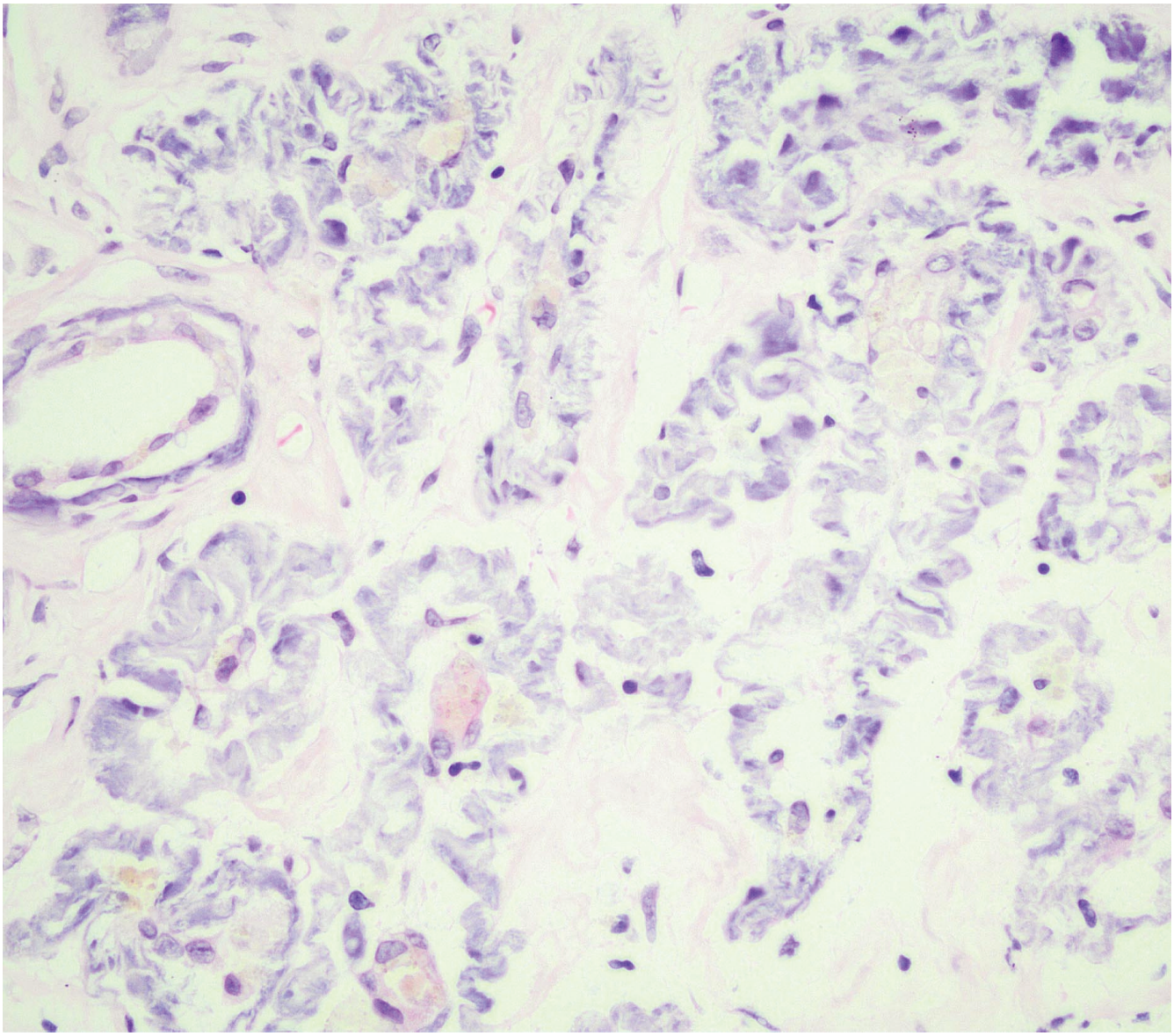

FIG.10E (HE): There is basophilic mineralization of wrinkled basement membranes surrounding atrophic tubules.

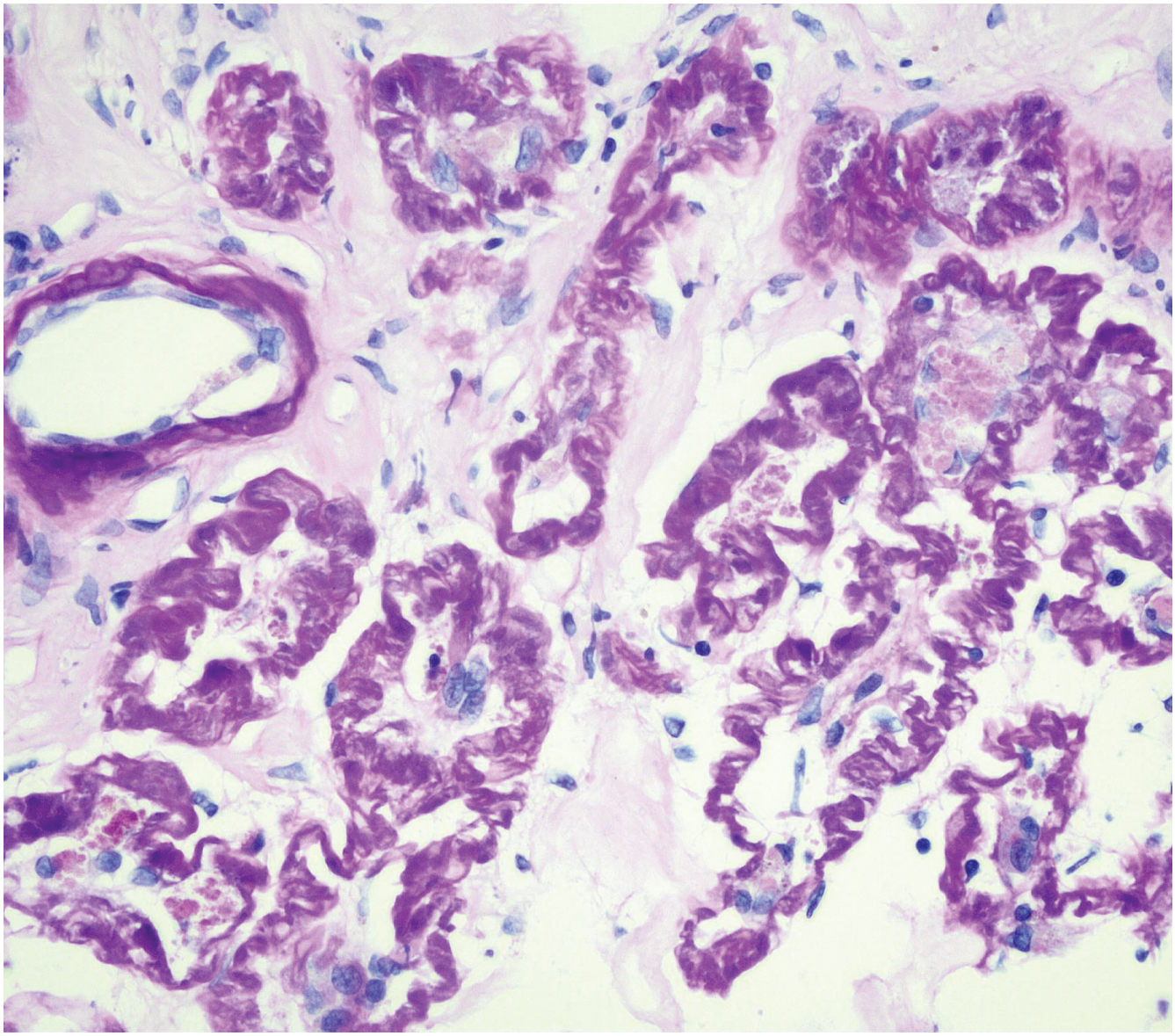

FIG.10F (PAS): This stain highlights the wrinkled, thickened basement membranes.

TUBULAR ATROPHY is observed along with interstitial fibrosis and is an outcome of tubular injury. It is best observed with basement membrane stains as tubular basement membranes are often wrinkled and thicken with atrophy. Tubular epithelial cell size is also reduced or non-existent. Varying degrees of **INTERSTITIAL FIBROSIS** is often seen surrounding the atrophic tubules.

An interactive or media element has been excluded from this version of the text. You can view it online here:
https://ohiostate.pressbooks.pub/vetrenalpathatlas/?p=456

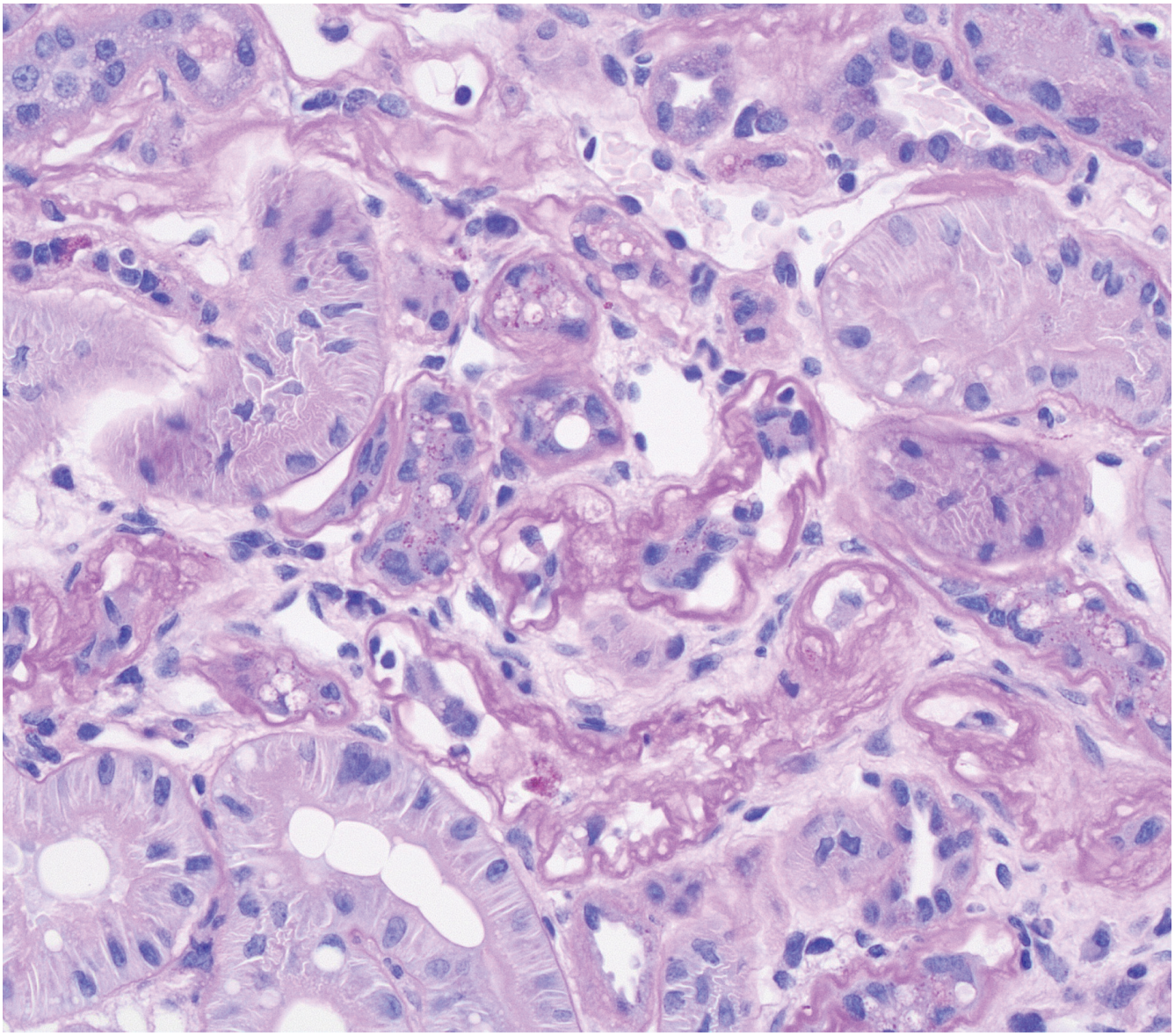

FIG.11A (PAS): The PAS stain emphasizes the wrinkling and multi-lamination of the basement membranes of the atrophied tubules. There is mild interstitial fibrosis.

An interactive or media element has been excluded from this version of the text. You can view it online here:
https://ohiostate.pressbooks.pub/vetrenalpathatlas/?p=456

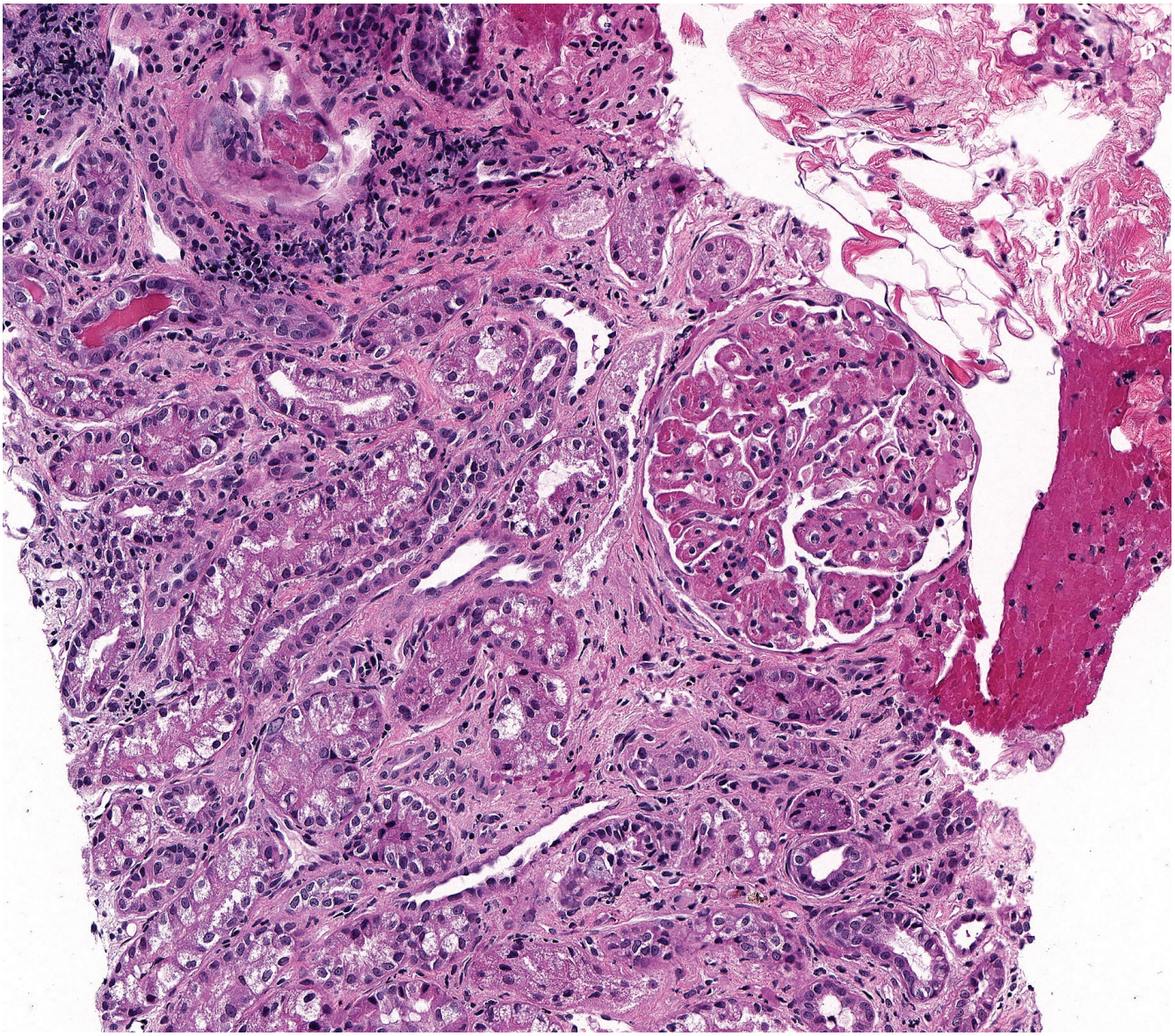

FIG.11B (HE): There is mild to moderate fibrosis in between the tubules, many of which are undergoing atrophy. The glomerulus demonstrates a membranoproliferative pattern and the patient had immune complex mediated membranoproliferative glomerulonephritis.

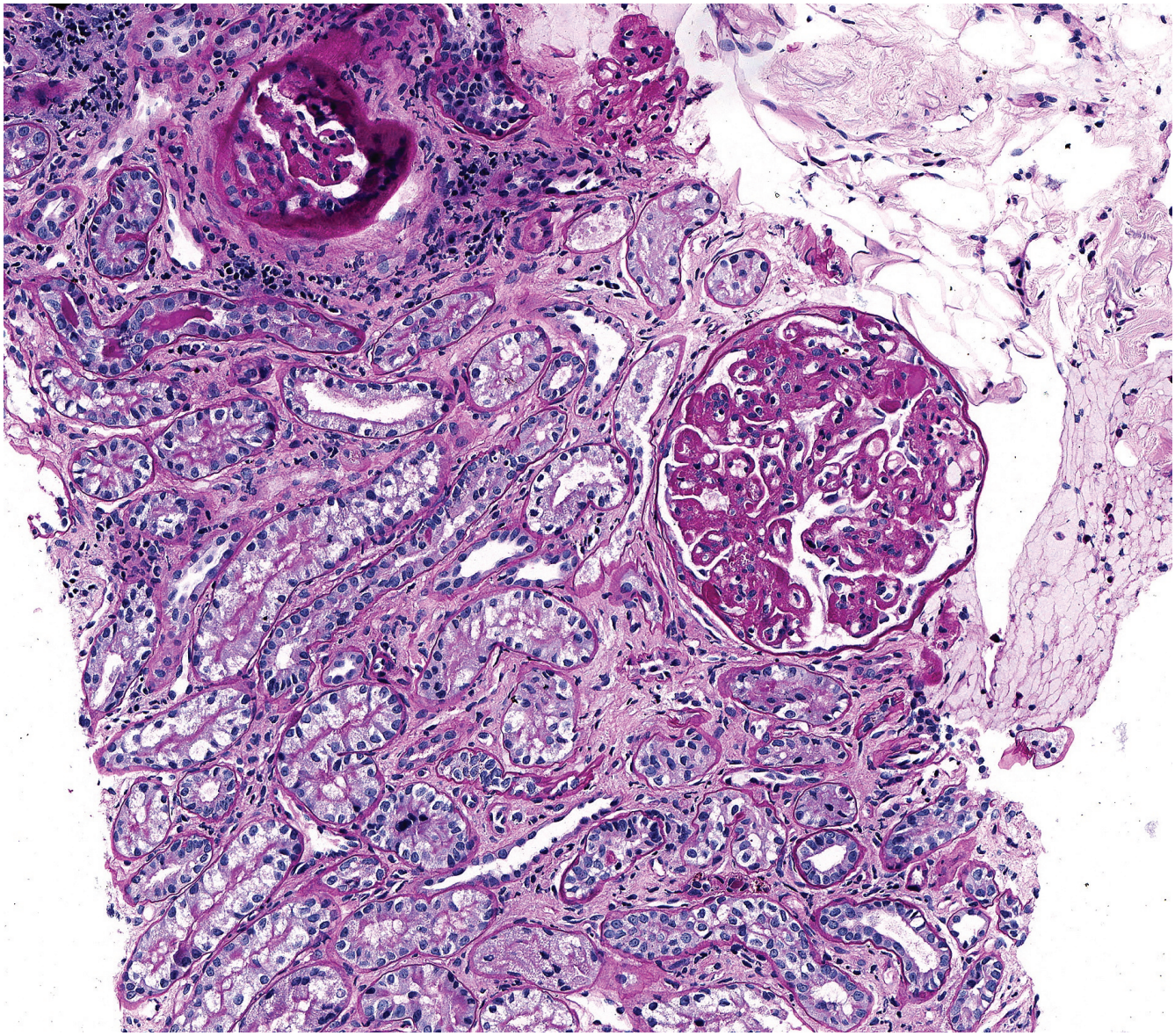

FIG.11C (PAS): This stain enables the differentiation of the atrophic tubular basement membranes from the increased amounts of interstitial collagen.

ARTERIAL / ARTERIOLAR HYALINOSIS is histologically characterized by homogeneous, pink thickening of the walls of arteries and arterioles with loss of structural detail, and with narrowing of the vascular lumen. The term 'hyalin' denotes a glassy appearance to distinguish it from the more granular / fibrillar appearance of vascular fibrinoid necrosis.

An interactive or media element has been excluded from this version of the text. You can view it online here:
https://ohiostate.pressbooks.pub/vetrenalpathatlas/?p=456

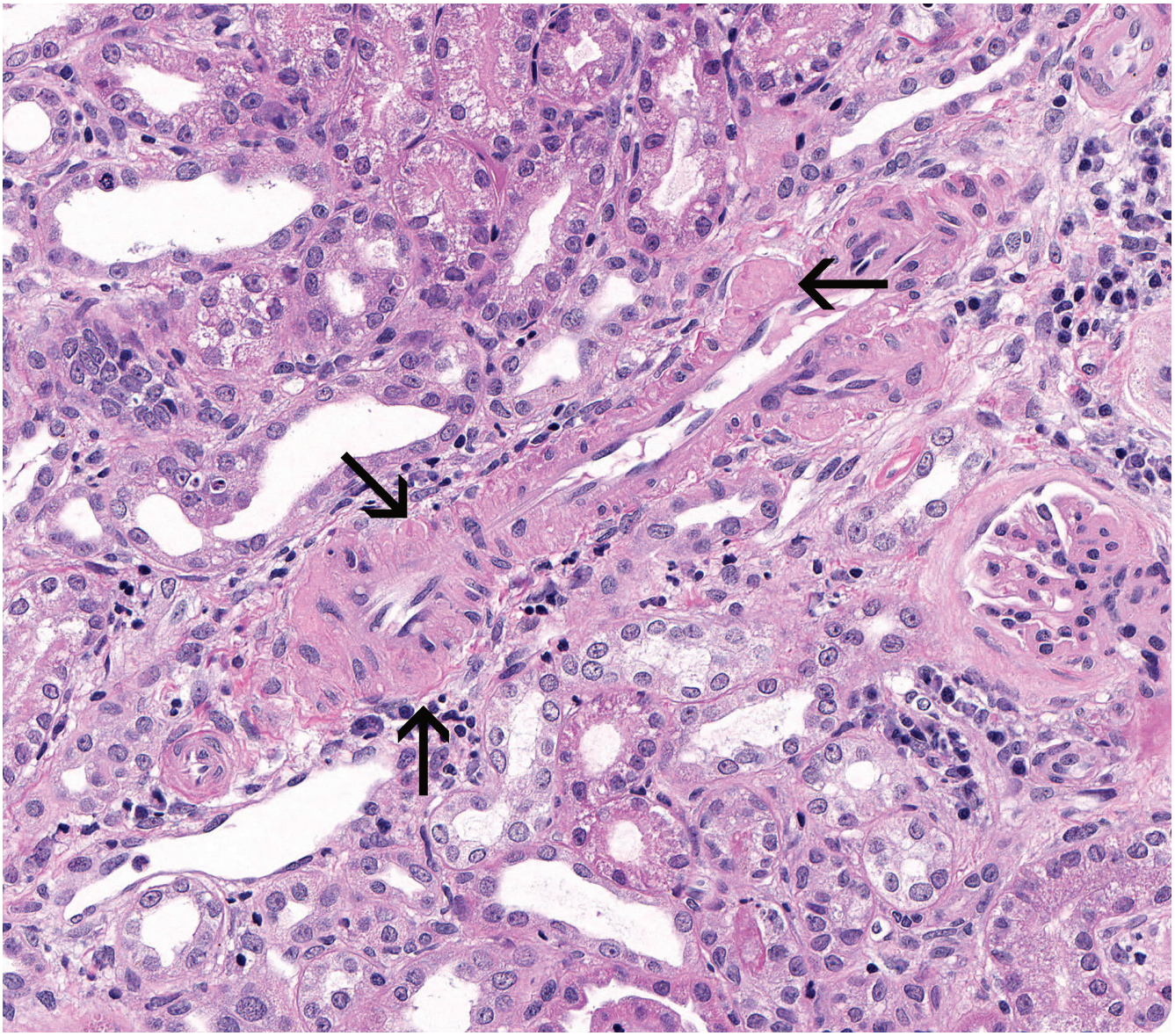

FIG.12A (HE): There are small nodular expansions of the smooth muscle wall of this intralobular caliber artery. Hyalinosis can sometimes be a subtle lesion and difficult to detect on HE slides.

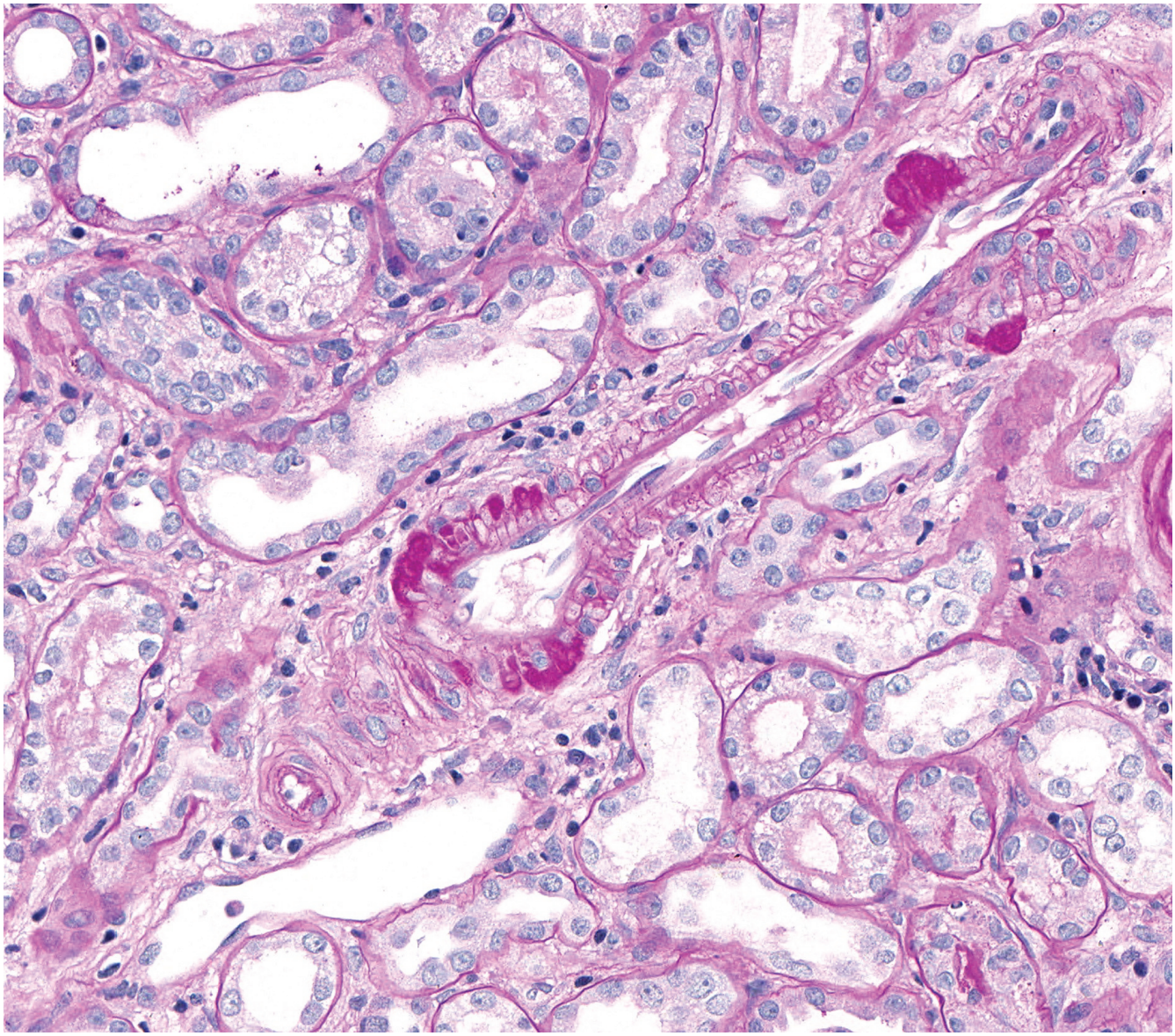

FIG.12B (PAS): Hyalinosis is much easier to see with the PAS stain as dark pink to magenta nodular expansions of the arterial wall.

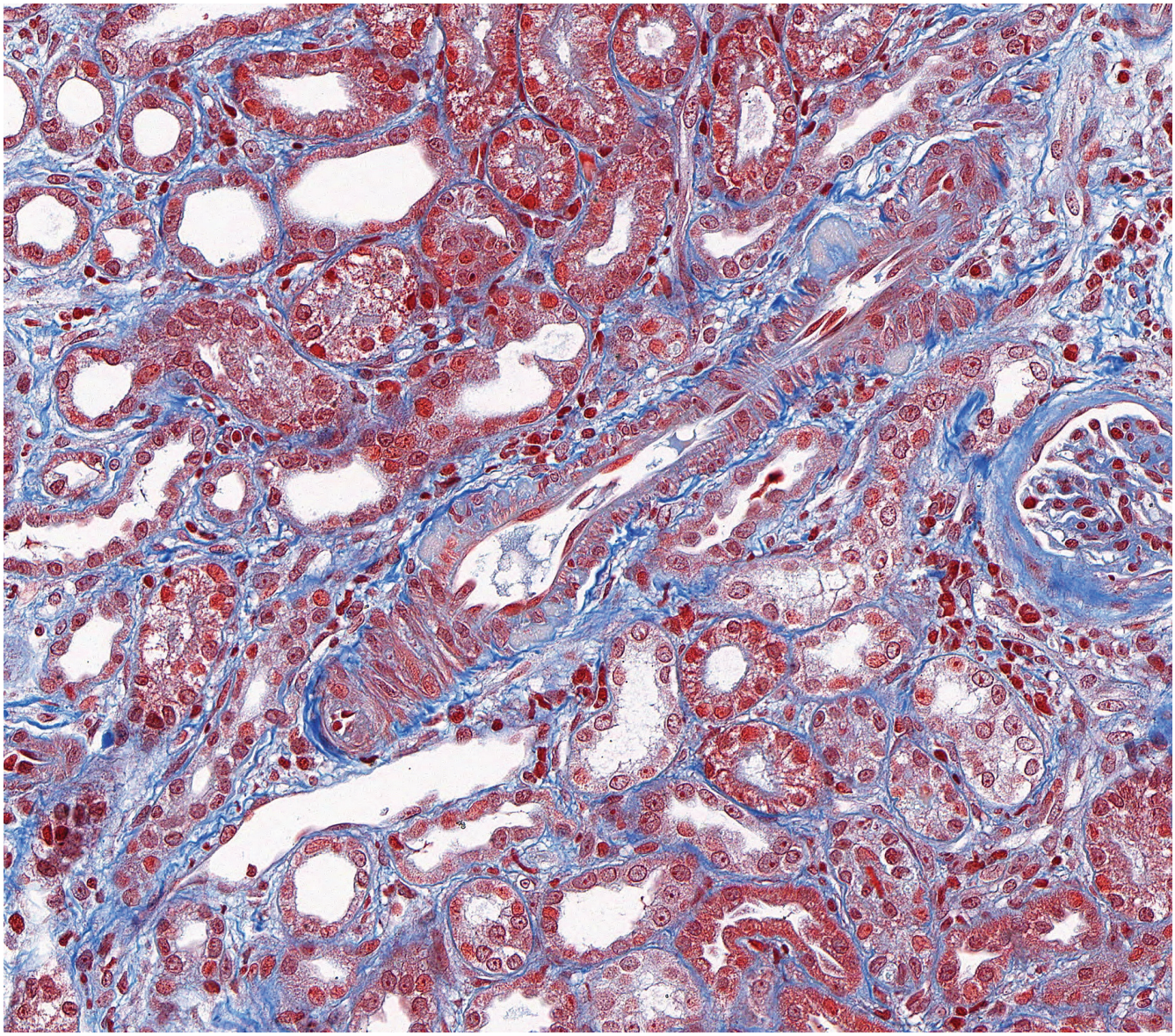

FIG.12C (MT): With MT, the hyalinosis is usually pale peach to orange.

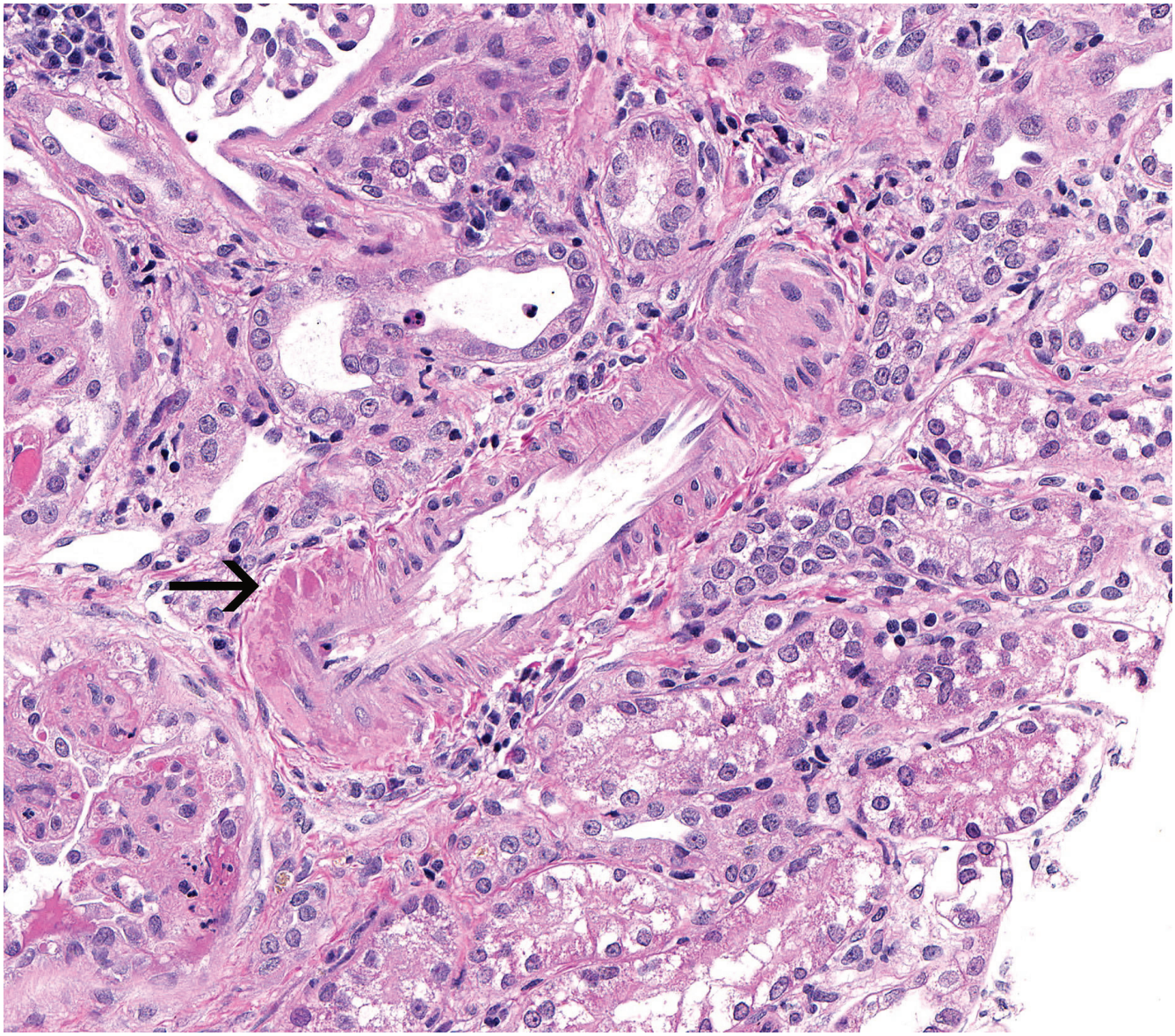

FIG.12D (HE): There are small foci of pink hyalinosis in this artery.

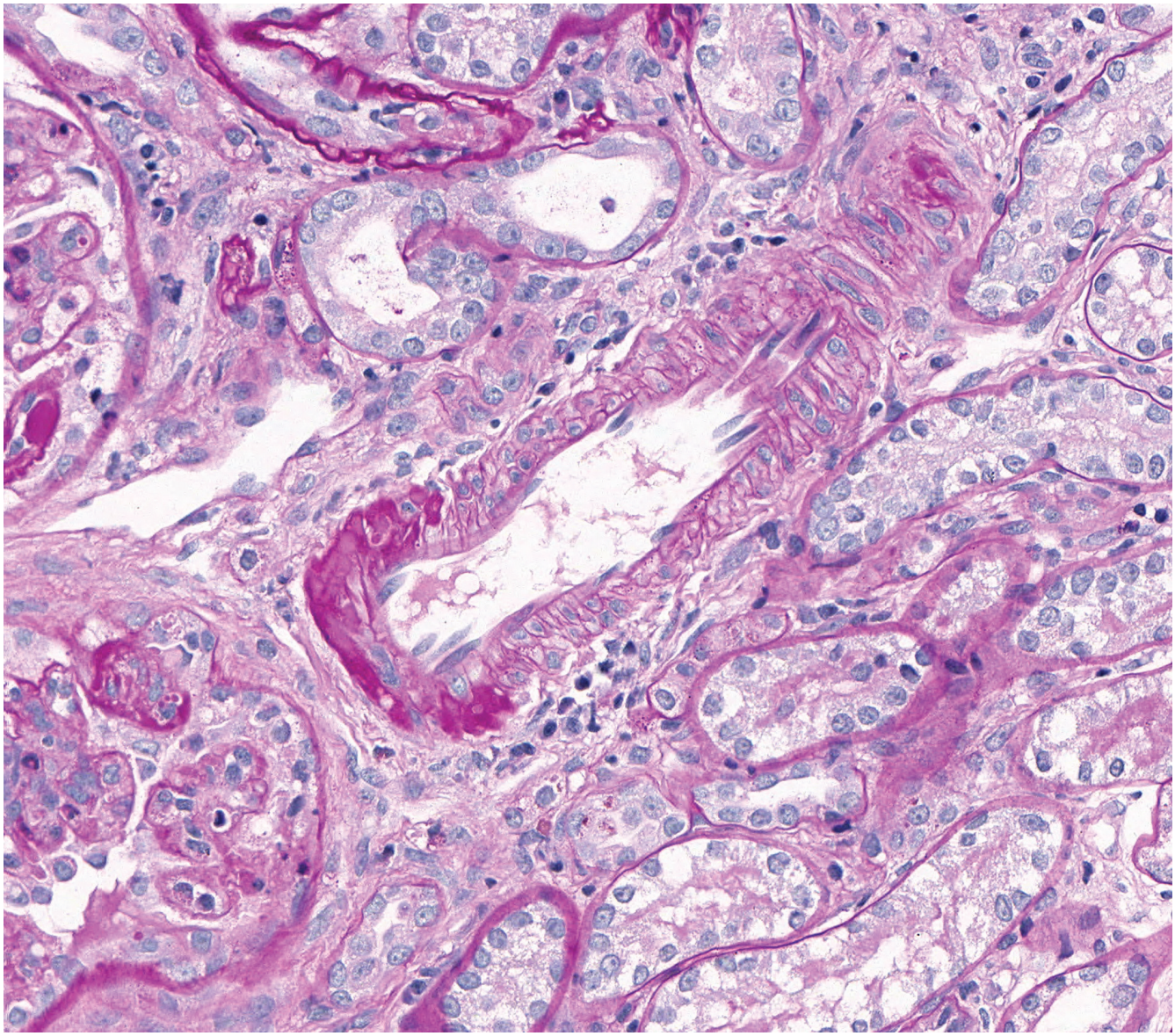

FIG.12E (PAS): Again the PAS method enable easy detection of the hyalinosis in this arterial wall.

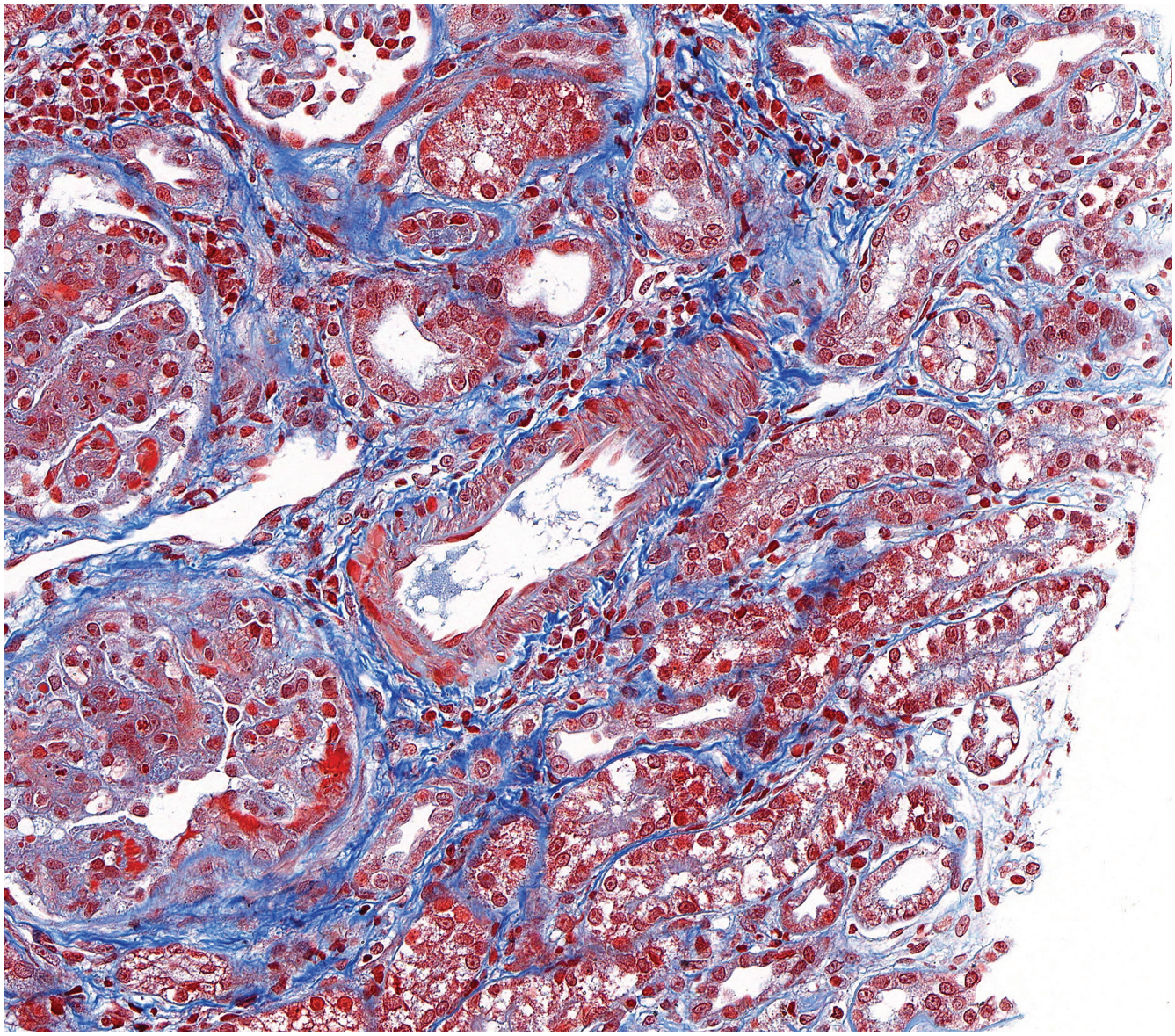

FIG.12F (MT): The hyalinosis of this artery is orange red (compare to Figure 12C).

HYPERPLASTIC ARTERIOSCLEROSIS / ARTERIOLOSCLEROSIS, on the other hand, is histologically seen as a concentric, laminated thickening of arterial and small arteriolar walls, respectively. This lesion has an 'onion skin appearance' with progressive narrowing of the lumina. By transmission electron microscopy, the laminations are shown to consist of smooth muscle cells and thickened and reduplicated basement membranes.

An interactive or media element has been excluded from this version of the text. You can view it online here:
https://ohiostate.pressbooks.pub/vetrenalpathatlas/?p=456

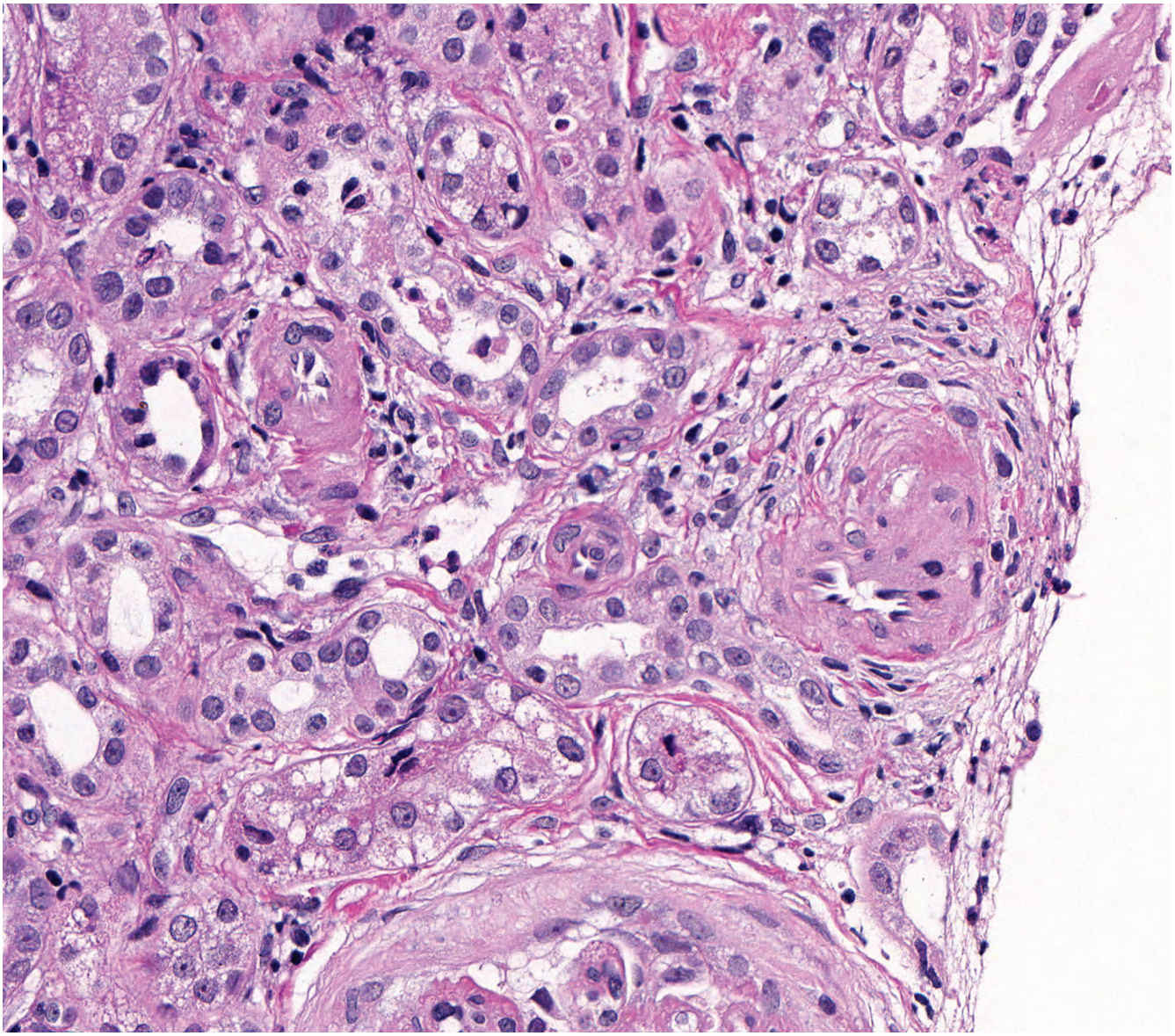

FIG.13A (HE): These small arteries and aterioles are surrounded by mesenchymal cells. By HE, it can be difficult to differentiate the mesenchymal cells encircling the vessels from interstitial fibrosis.

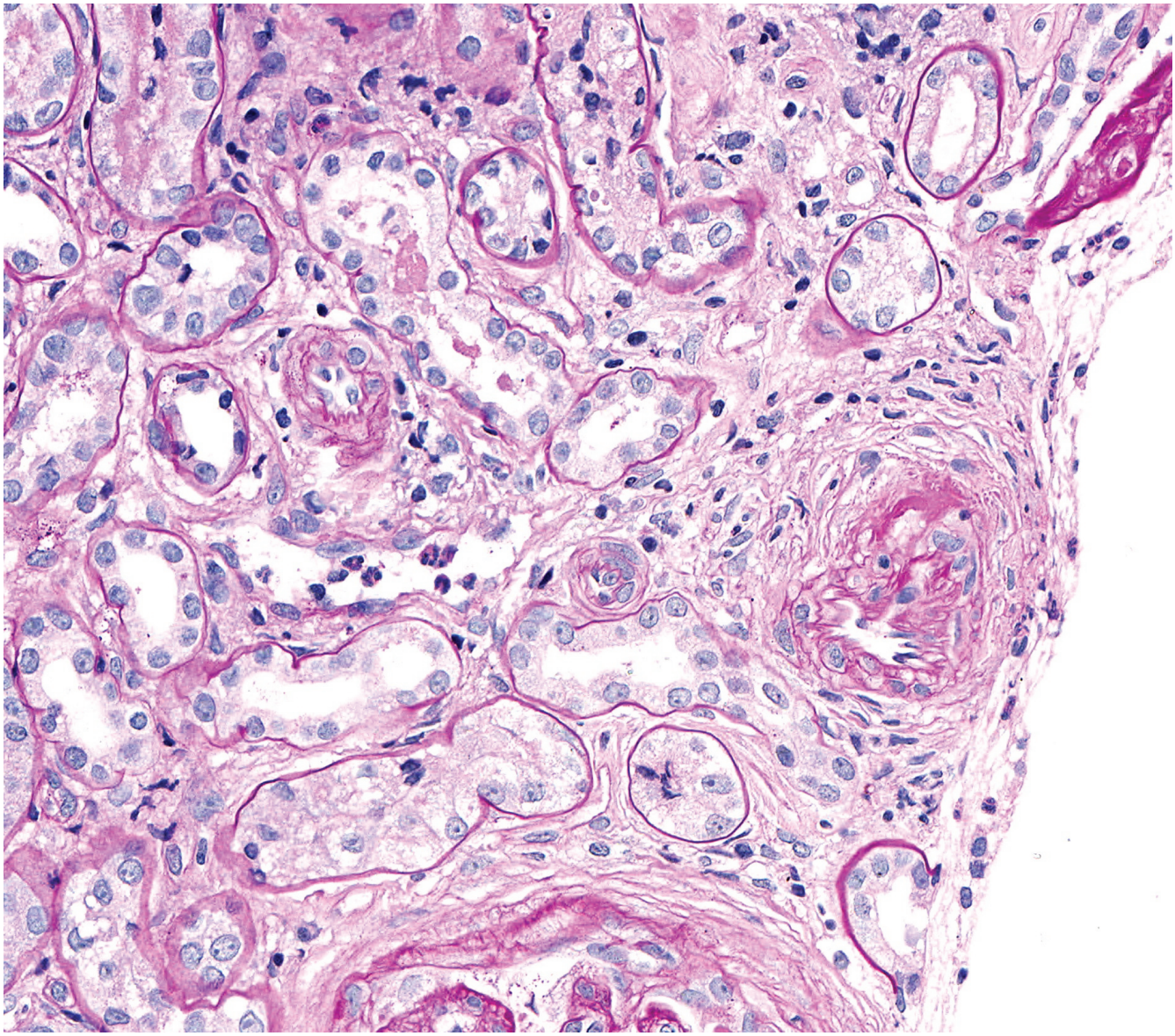

FIG.13B (PAS): PAS highlights the mesenchymal cells with prominent nuceli that encircle the vessels.

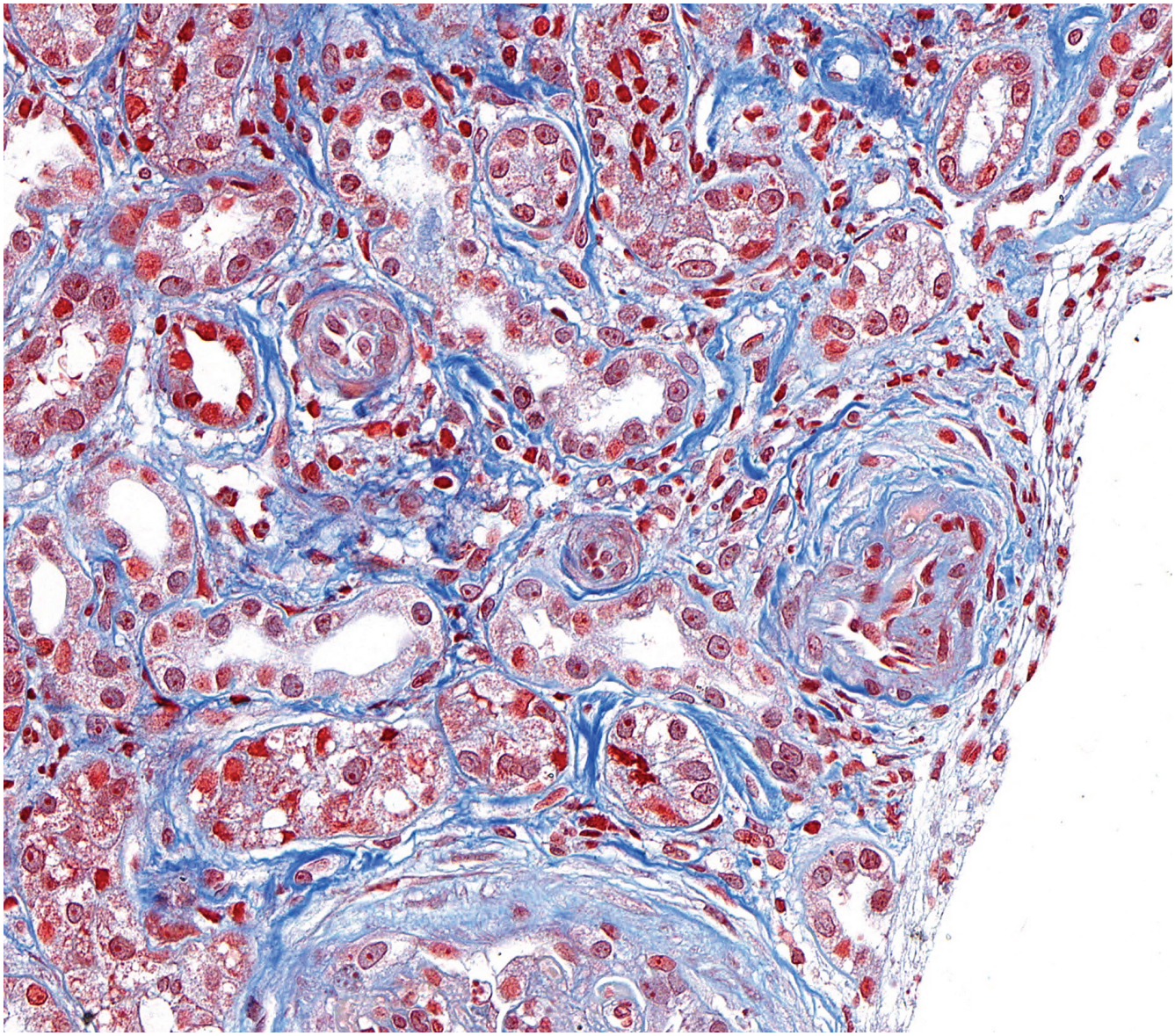

FIG.13C (MT): The onion-skiinned appearance is due to the cells and admixed collagen that encircle the vessels.

FIBRINOID NECROSIS refers to the bright pink smudgy appearance of the vessel wall. This material morphologically looks like fibrin, but is mainly composed of necrotic tissue, immune complexes and complement. When there is nuclear debris associated with the fibrinoid change, the lesion can be called **FIBRINOID ARTERITIS** or **LEUKOCYTOCLASTIC ARTERITIS.**

An interactive or media element has been excluded from this version of the text. You can view it online here:
https://ohiostate.pressbooks.pub/vetrenalpathatlas/?p=456

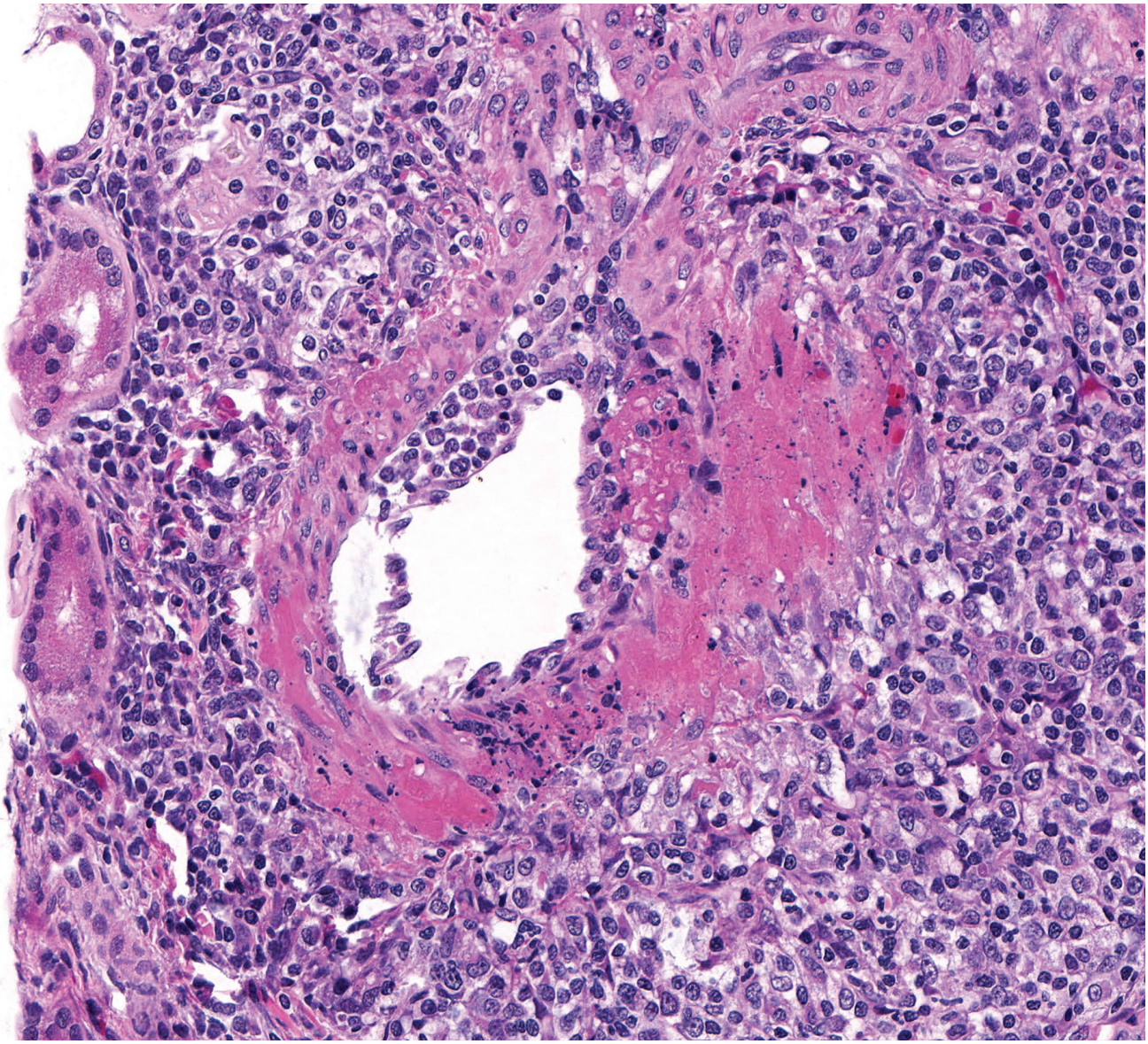

FIG.14A (HE): The entire vessel wall is obscured by smudgy to granular eosinophilic material (fibrinoid change). There is necrosis of the smooth muscle wall and abundant pyknotic nuclear debris.

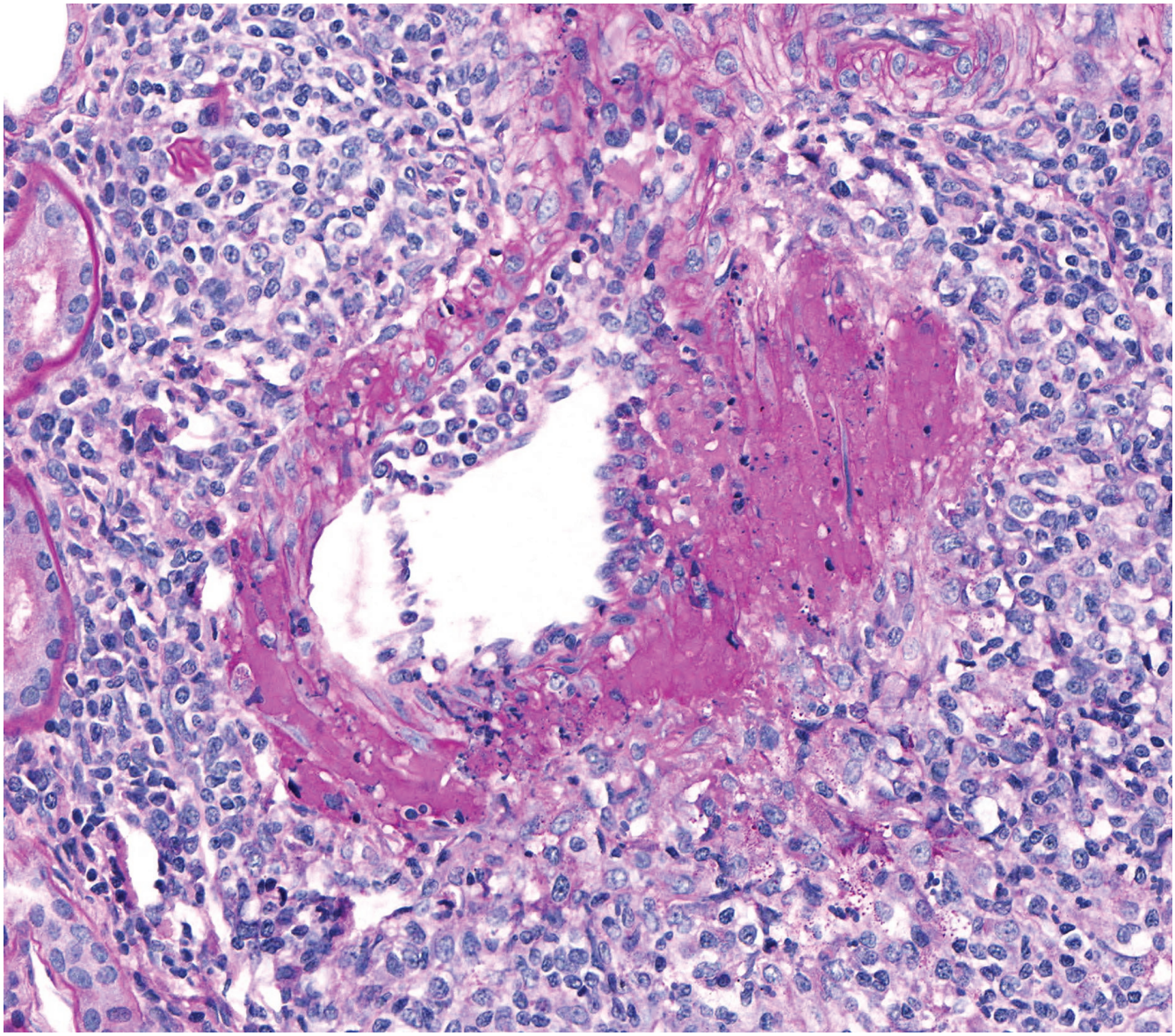

FIG.14B (PAS): With the PAS stain, the fibrinoid change is bright pink. This stain also highlights the accumulation of inflammatory cells beneath the hypertrophied endothelium, further supporting the diagnosis of arteritis in this case.

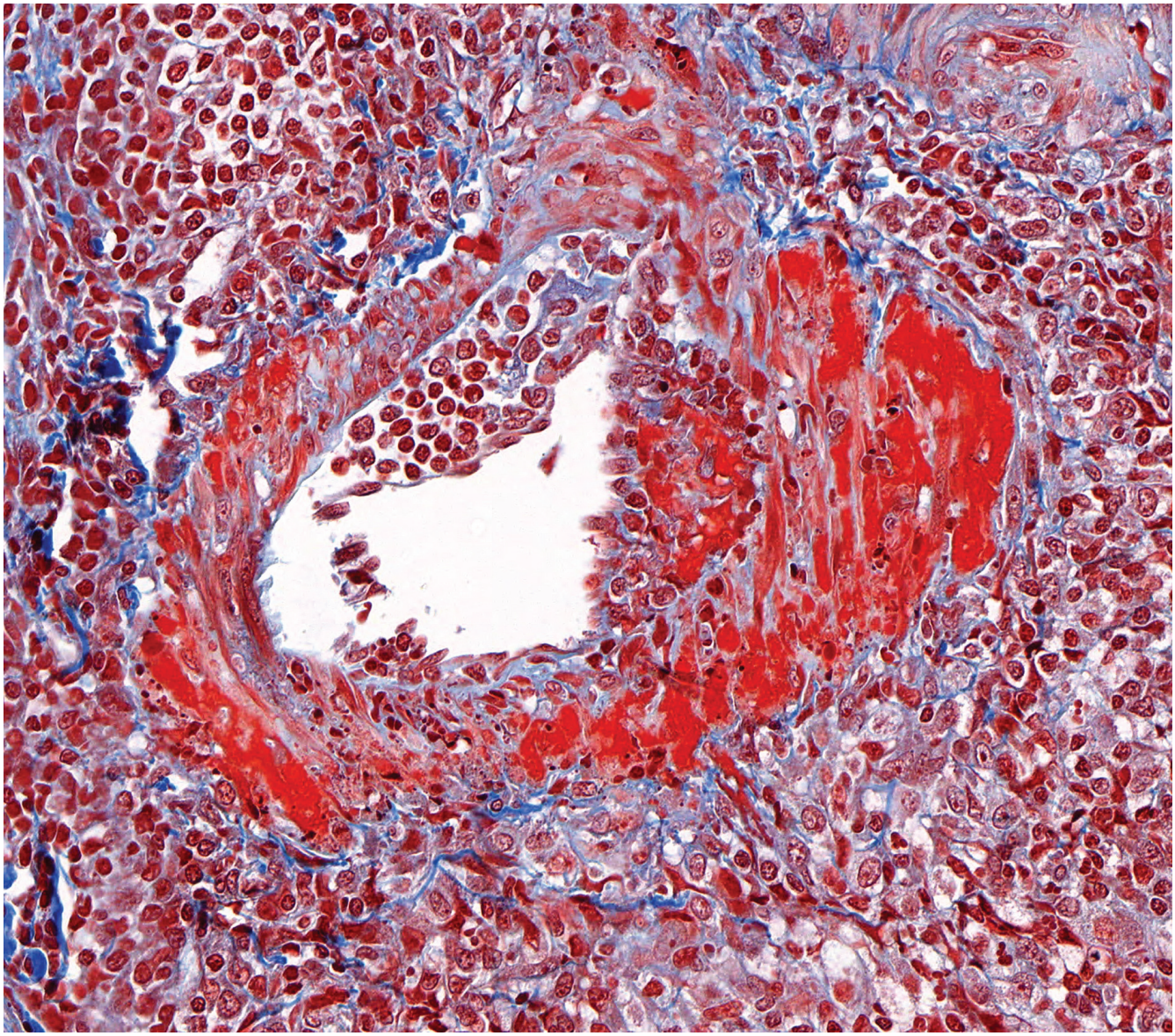

FIG.14C (MT): The fibrinoid material is bright orange to red when stained with MT.

ADDITIONAL TUBULOINTERSTITIAL CHANGES WHICH ARE ARTIFACTUAL OR WITHIN NORMAL LIMITS.

AUTOLYSIS

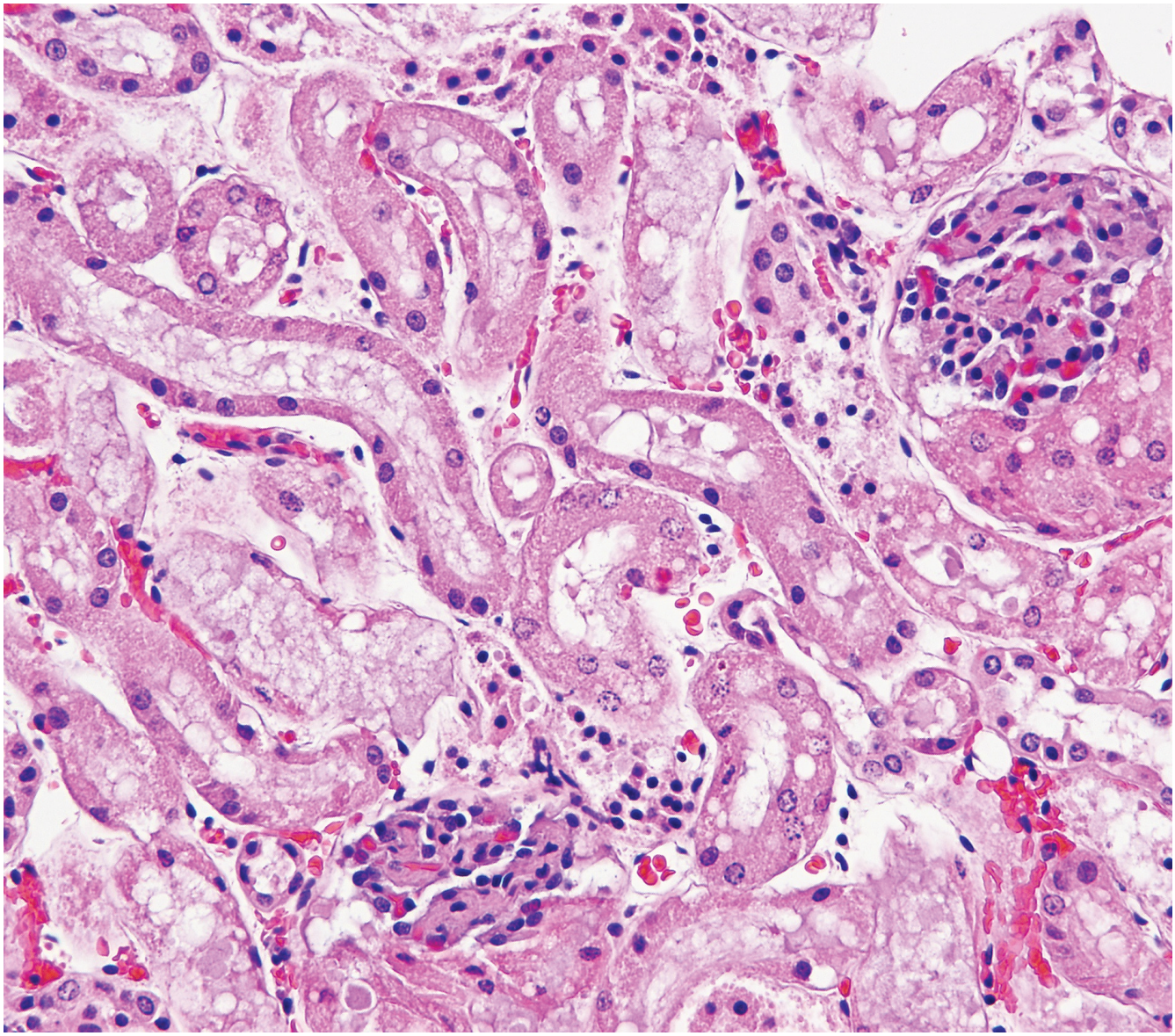

FIG.15A (HE): Tubular epithelial cells have large nuclei with a speckled appearance. They often have circular clear spaces in the cytoplasm and frothy material in tubular lumens. With autolysis, proximal tubular epithelial cells detach and "herniate" into Bowman's space, compressing the glomerular tuft.

NORMAL AMOUNTS OF LIPID WITHIN TUBULAR EPITHELIAL CYTOPLASM

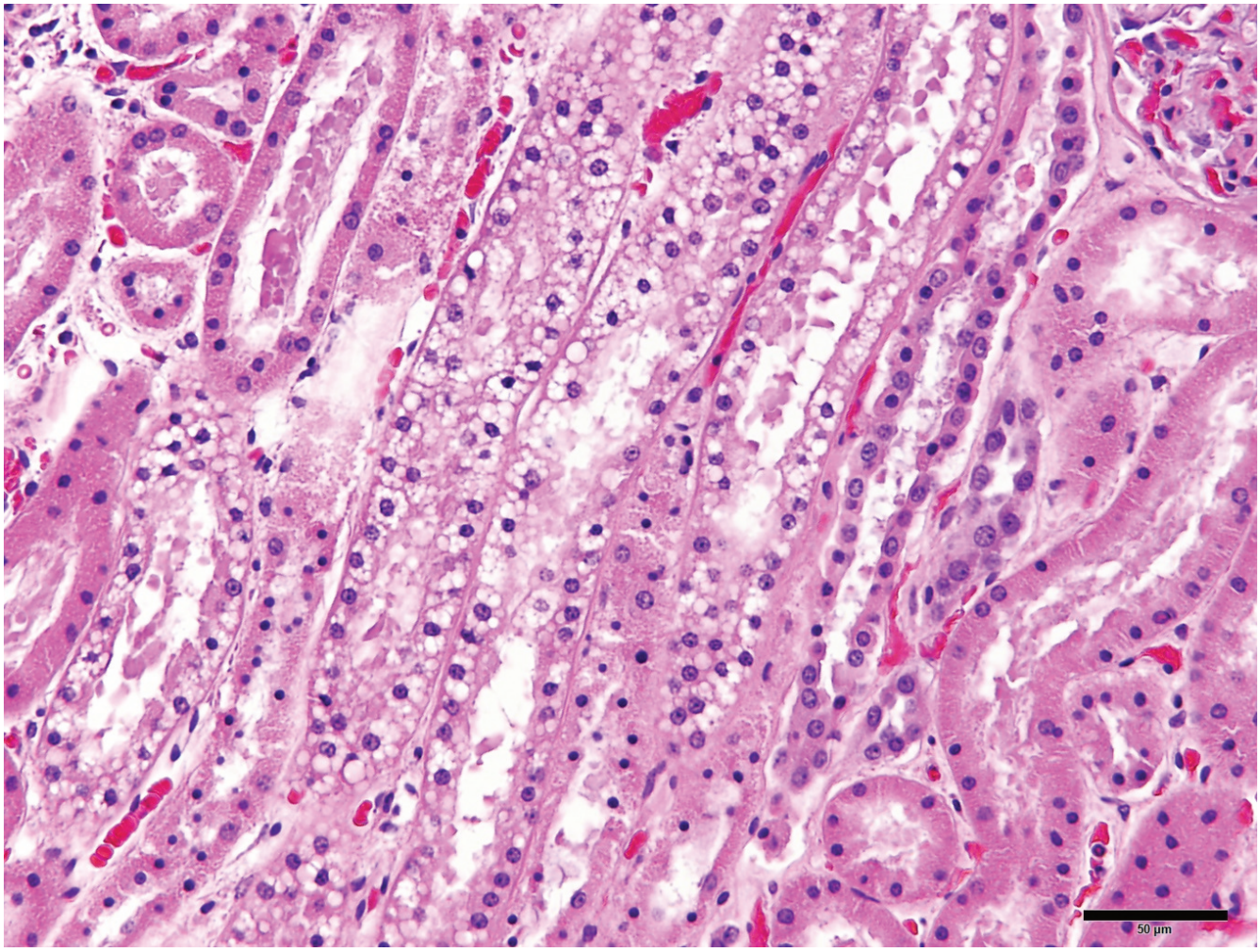

FIG.15B (HE): The tubules in the medullary rays (which contains the straight portion of the proximal tubule) frequently contain lipid in healthy dogs.

TUBULAR EPITHELIAL CYSTS

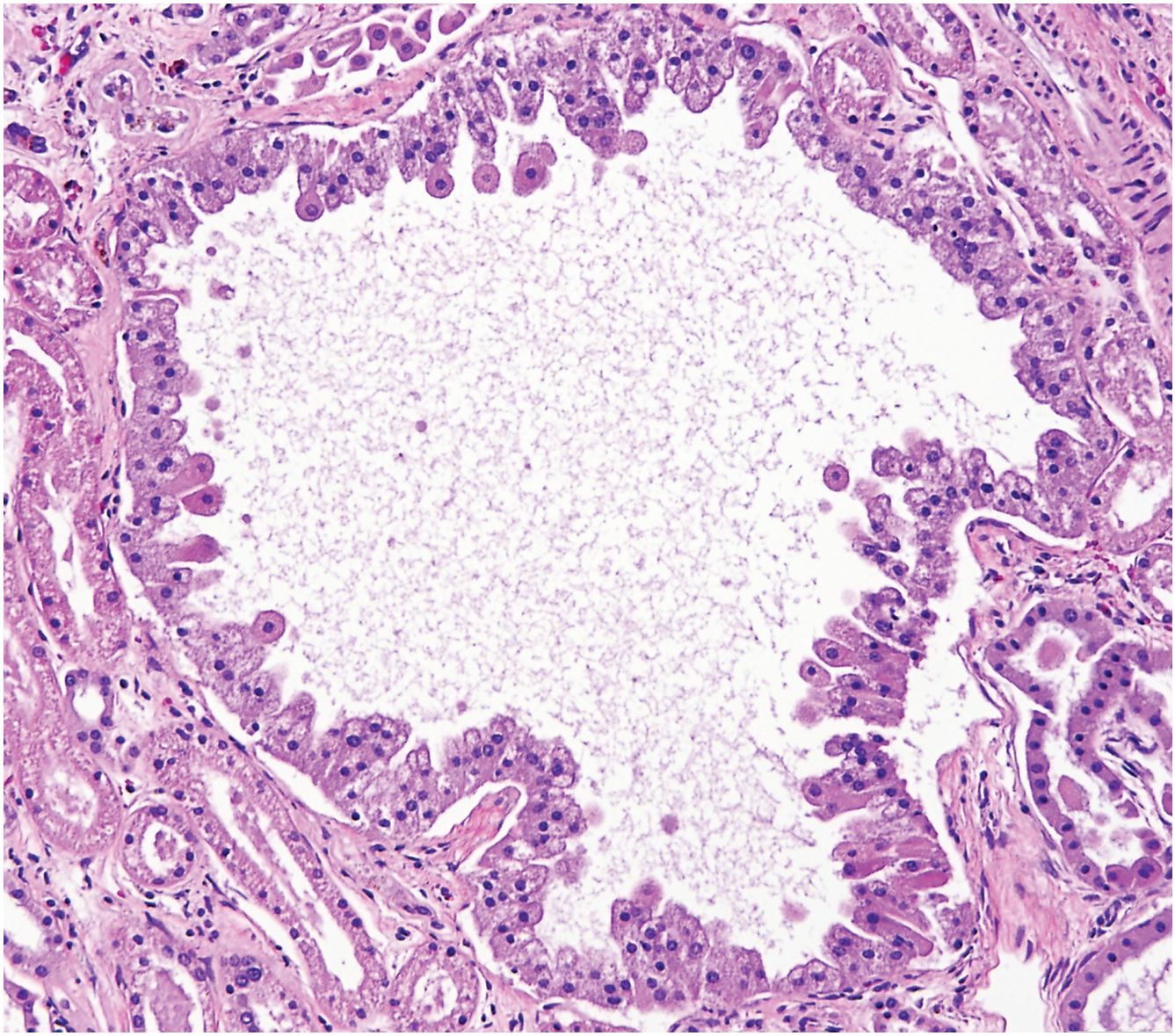

FIG.15C (HE): Marked dilation of tubules is a common finding. Tubular epithelial cells lining the cysts can range from cuboidal to tall columnar to tombstone-shaped (depicted above). Usually tubular cysts are incidental lesions but if they are large or numerous, they can act similarly to other space-occupying masses.

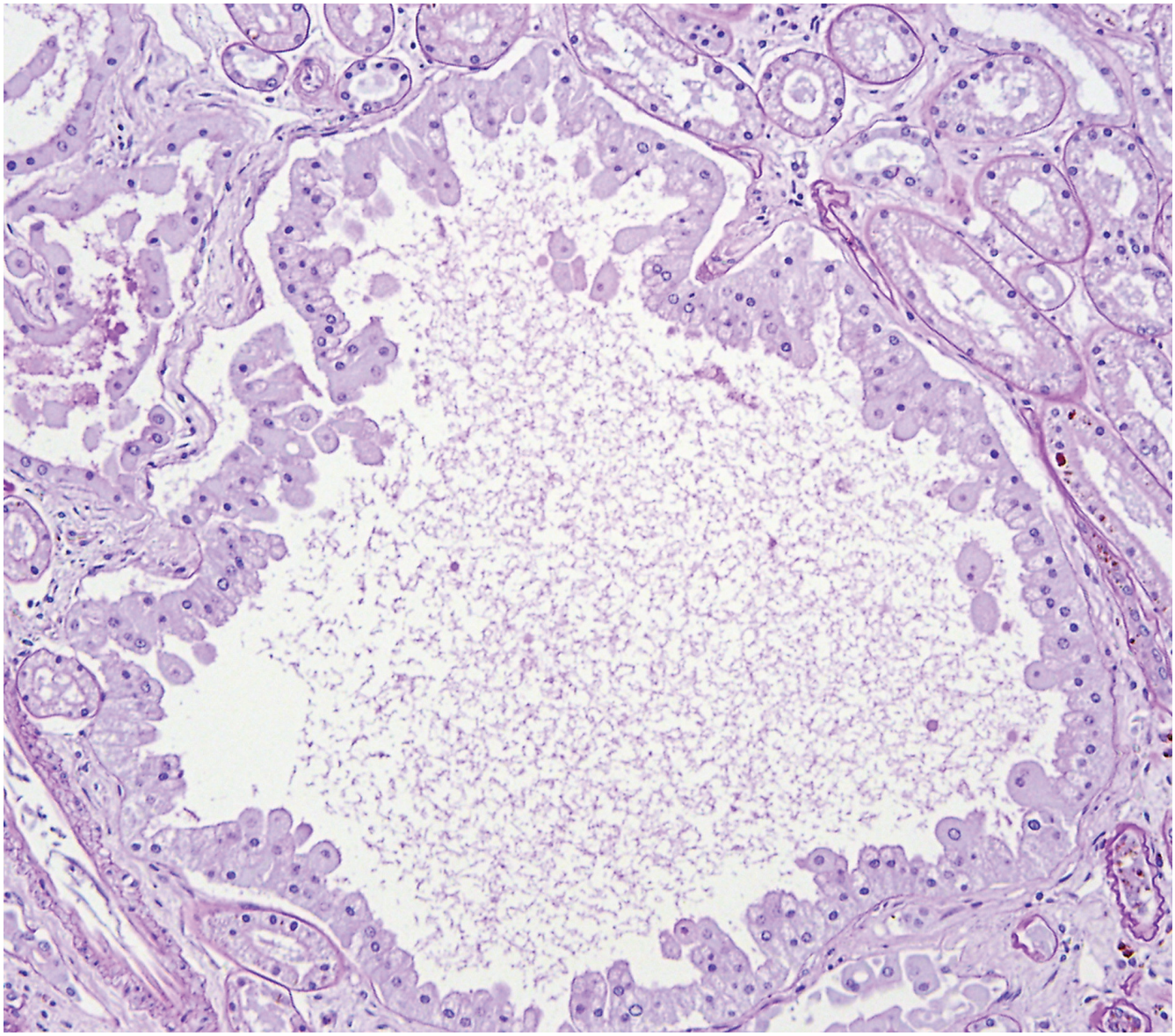

FIG.15D (PAS): PAS stain of the above image.

List of Terms

A

Amyloid:

Extracellular, non-branching fibrils composed of misfolded proteins in a beta pleated sheet conformation, measuring 9-11 nm in diameter. Although many proteins can form these fibrils (as documented in humans), in animals the source is almost always Serum Amyloid A, an acute phase protein synthesized by the liver. Amyloid can be found in glomeruli, interstitium, and vessels. It appears peach to orange with Congo red stain and exhibits apple green birefringence when viewed with polarized light. Additional staining characteristics include: pink with HE, pale pink and waxy with PAS, and mottled blue to orange with MT. Amyloid does not take up silver with the JMS method.

Arteriolosclerosis:

Mural thickening with luminal narrowing of arterioles due to hyperplasia or hyaline.

Azotemia:

Abnormal amounts of nitrogen-containing compounds (specifically creatinine) in the blood. Deviation of blood creatinine may lie within a laboratory's designated normal reference interval but still be considered abnormal for a particular patient. Additional parameters of renal function (e.g. urine specific gravity, presence of proteinuria, etc.) should be assessed concurrently.

B

C

Capillary loop

- Capillary loop remodeling: Loss of the normal smooth, thin contour of peripheral capillary walls due to spikes, holes, or double contours (tram tracks) with silver stain.
- Capillary loop thickening: The walls of peripheral capillary loops are expanded; best visualized by silver and PAS stains. Can be due to both immune complex mediated and nonimmune complex mediated processes.

Casts

- Hyaline (protein) casts: Tubular lumens filled by eosinophilic (HE) and PAS-positive glassy material.
- Cellular casts: Tubular lumens filled with aggregates of cells or cellular debris.

Crescents:

Multilayered accumulation of cells, often admixed with extracellular material, in Bowman's space (i.e. "extracapillary hypercellularity"). Crescents are formed when glomerular capillary loops rupture or Bowman's capsule basement membrane ruptures, allowing inflammatory cells to enter Bowman's space. Over time crescents can modify from being predominantly cells with fibrin (so-called "cellular crescent") to mostly fibrous matrix with fewer cells ("fibrous crescent").

Cystic glomerular atrophy:

See *glomerulocystic atrophy*

D

Diffuse:

Involving greater than 50% of glomeruli.

Double contours:

See *glomerular basement membrane duplication*

Duplication:

See *glomerular basement membrane duplication*

Dysplasia:

See *maldevelopment*

E

Endocapillary hypercellularity:

Increased cellularity internal to the glomerular basement membrane due to circulating leukocytes, endothelial cells, and/or interposed mesangial cells with resulting encroachment or obliteration of peripheral capillary lumens.

Extracapillary hypercellularity:

See *crescents*

F

Fetal glomeruli:

Glomeruli are small, contain few capillaries, and have prominent podocyte precursors lined up along the tuft surface.

Focal:

Involving less than 50% of glomeruli.

Foam cells:

Large finely vacuolated cells (cell unknown) with distinct cell borders that contain sudanophilic (lipid) material.

G

Global:

Involving the entire glomerular tuft.

Glomerular basement membrane (GBM):

Transmission electron microscopy reveals that this is a trilaminar membrane synthesized by predominantly by podocytes with some contribution by the endothelial cells. The layers are lamina rara interna (beneath the endothelium), lamina densa, and lamina rara externa (beneath the podocytes).

GBM Duplication: Thickened glomerular capillary wall with two separated layers of GBM matrix material i.e., ‘tram track’ appearance; best visualized with PAS and JMS.

GBM Holes: Small areas of lucency within the capillary walls; best visualized by silver stain (JMS).

GBM Spikes: Small irregular projections of GBM matrix on the outer aspect (abluminal) of the GBM. Best visualized by silver stain (JMS).

GBM Splitting: Lamellar appearance or basket-weave pattern of GBM with EM.

Glomerulocystic atrophy or glomerular cystic atrophy:

Cystic dilation of Bowman’s capsule with a compressed, atrophic glomerular tuft.

Glomerular lipidosis:

Accumulation of large foam cells in one or more lobules of a glomerular tuft. Foamy cells contain intracytoplasmic vacuoles that are sudanophilic (lipid material) but do not stain with routine methods (HE, PAS, MT and JMS). These cells are also autofluorescent on IF evaluation.

Glomerular thrombi :

Intracapillary acellular, fibrillar (non-glassy) material that stains orange to red on MT and pale pink on PAS.

Glomerulosclerosis:

Increased extracellular matrix leading to obliteration of capillary lumens and consolidation of part or most of the tuft. Sclerotic segments stain pale pink with HE, blue with MT, black (argyrophilic) with JMS, and pink with PAS.

- Hilar glomerulosclerosis: Increased extracellular matrix leading to obliteration of capillary lumens and consolidation *near the vascular pole of the tuft.*
- Tip glomerulosclerosis: Increased extracellular matrix leading to obliteration of capillary lumens and consolidation *near the urinary pole of the tuft.*
- Glomerulosclerosis not at poles: Increased extracellular matrix leading to obliteration of capillary lumens and consolidation which is *not at a polar location.*
- Glomerulosclerosis location undetermined: Increased extracellular matrix leading to obliteration of capillary lumens and consolidation affecting an uncertain portion of the tuft.

H

Holes:

See *Glomerular basement membrane holes*

Hyalinosis:

Glassy eosinophilic (HE) and PAS-positive extracellular material (plasma proteins) that can be found adjacent to glomerular basement membranes, in the mesangium or in vessels.

I

Immune deposits:

Complexes of antigen and antibody that are seen as distinct red granular or nodular structures visible on light microscopy with Masson's trichrome stain along the GBM (usually abluminal, but occasionally visible on the luminal surface). Electron microscopy is required to determine the location of immune complex deposits which are finely granular and electron dense:

- Subepithelial: deposits located between the podocyte and GBM.
- Subendothelial: deposits are located between the endothelium and the GBM.
- Mesangial: deposits are located within the mesangium.
- Paramesangial: deposits are located on the subepithelial surface of the GBM that overlies the mesangium.
- Intramembranous: deposits are within the GBM.

J

K

L

M

Maldevelopment:

Broad term for abnormal nephrogenesis which may include histologic features such as fetal/immature glomeruli, glomerulocystic atrophy, paucity of glomeruli and/or tubules, atypical tubular epithelium, and/or presence of primitive ducts.

Mesangial hypercellularity:

More than three nuclei in close apposition within the mesangial matrix.

Mesangial cell interpositioning:

Extension of cells (presumably mesangial cells) into the peripheral aspect of the capillary loops between the endothelium and GBM or between layers of GBM matrix. This term is used in the context of TEM, whereas "GBM duplication" is often used in the context of LM.

Mesangiolysis:

Disruption of mesangial matrix with subsequent dilatation of capillary lumens.

Myelin figures:

On transmission electron microscopy, these are collection of concentric layers of cell membrane within the cytoplasm of endothelial cells, podocytes, or mesangial cells.

N

O

Obsolescent glomeruli:

Small glomerular remnants composed of residual matrix and few cells.

P

Parietal epithelial cells:

Epithelial cells that line the inner (urinary) surface of Bowman's capsule and have a squamous morphology.

- Parietal cell hyperplasia: Increased numbers of epithelial cells lining Bowman's capsule; cells are crowded and occasionally pile up.
- Parietal cell hypertrophy: Loss of the normal squamous morphology; often have more of a cuboidal appearance.
- Tubularization: Morphologic transformation of parietal epithelium into proximal tubular epithelial phenotype.

Podocyte:

Epithelial cell that sits on the outside (abluminal) surface of the glomerular basement membrane.

- Podocyte foot process effacement: Flattening and spreading of foot processes over the surface of the GBM seen with EM.
- Podocyte hypertrophy: Visceral epithelial cells are enlarged, prominent and easily discernible.
- Podocyte hyperplasia: Visceral epithelial cells are increased in number and form clusters in Bowman's space; rare lesion.
- Podocyte microvillous transformation: Formation of numerous podocyte cell membrane protuberances usually on the cell surface facing the urinary space.
- Podocyte protein droplets: Small round eosinophilic (HE) and PAS-positive (ie, proteinaceous) cytoplasmic globules in epithelial cells.

Proteinuria:

General term for protein in the urine. Renal proteinuria results from loss of selective glomerular filtration and/or impaired reabsorption of filtrate. Persistent renal proteinuria is typically an indication of some degree of renal dysfunction/injury.

Q

R

S

Segmental:

Involving part of the glomerular tuft.

Spikes:

See glomerular basement membrane spikes

Synechiae:

Adhesion between the glomerular tuft and Bowman's capsule.

T

Tubular atrophy:

Tubule with thickened and/or wrinkled basement membrane and simplification or loss of tubular epithelium.

Tubular epithelial cell

- Vesiculation: Variably-sized clear vacuoles in tubular cell cytoplasm.
- Isometric vesiculation: Small equal-sized clear vacuoles in tubular cell cytoplasm.
- Protein droplets: Small round eosinophilic (HE) and PAS-positive (ie, proteinaceous) cytoplasmic globules in tubular epithelial cells.
- Pigment: coarse cytoplasmic granules of material having intrinsic color (eg, lipofuscin, bile, iron, copper).

Tubuloreticular inclusions:

Clusters of ~20 nm tubular/circular structures within the cytoplasm of endothelial or mesangial cells; uncommon in animals.

U

V

W

Wrinkling:

Folding of the GBM within capillary loops, often associated with areas of cellular interpositioning.

X

Y

Z

Publication Version

The current version of The Altas of Renal Lesions in Proteinuric Dogs is 1.0. The list of previous versions and respective date of publishing is below.

1.0 (4/27/2018)