

# Human Anatomy Lab Manual



# Human Anatomy Lab Manual

*MALGOSIA WILK-BLASZCZAK*

*KEVIN ALFORD, ANDREA CAMPO-VELEZ, AND VICTORIA DORCH*

MAVS OPEN PRESS  
ARLINGTON



*Human Anatomy Lab Manual* by Malgosia Wilk-Blaszczak is licensed under a Creative Commons Attribution 4.0 International License, except where otherwise noted.

Images are individually licensed as noted in the back matter.

# Contents

About the Publisher Mavs Open Press	ix
Accessibility Statement Mavs Open Press	xi
About This Project	xiii
Acknowledgments	xv
Part I. Lab 1: Anatomical Language	
Lab 1: Anatomical Language	3
1. Pre-Lab 1	4
2. Lab Activities	9
3. Post-Lab 1 Questions	14
Part II. Lab 2: Bones and Bone Markings	
Lab 2: Bones and Bone Markings	17
4. Pre-Lab 2	19
5. Lab Activities	28
6. Post-Lab 2 Questions	36
Part III. Lab 3: Spinal Cord and Spinal Nerves	
Lab 3: Spinal Cord and Spinal Nerves	41
7. Pre-Lab 3	42
8. Lab Activities	45
9. Post-Lab 3 Questions	49
Part IV. Lab 4: Brain and Cranial Nerves	
Lab 4: Brain and Cranial Nerves	53
10. Pre-lab 4	55
11. Lab Activities	59
12. Post-Lab 4 Questions	64

Part V. Lab 5: Special Senses

Lab 5: Special Senses	69
13. Pre-lab 5	71
14. Lab Activities	76
15. Post-Lab 5 Questions	82

Part VI. Lab 6: Respiratory System

16. Lab 6: Respiratory System	87
17. Pre-Lab 6	88
18. Lab Activities	92
19. Post-Lab 6 Questions	97

Part VII. Lab 7: The Cardiovascular system

20. Lab 7: The Cardiovascular system	101
21. Pre-lab 7	102
22. Lab Activities	113
23. Post-Lab 7 Questions	122

Part VIII. Lab 8: Digestive System

24. Lab 8: Digestive System	127
25. Pre-Lab 8	128
26. Lab Activities	136
27. Post-Lab 8 Questions	143

Part IX. Lab 9: Urinary and Reproductive Systems

28. Lab 9: Urinary and Reproductive Systems	147
29. Pre-lab 9	149
30. Lab Activities	158
31. Post-Lab 9 Questions	165

Part X. Lab 10: The Muscular and Integumentary systems

Lab 10: The Muscular and Integumentary systems	169
32. Pre-Lab 10	170
33. Lab Activities	179
34. Post-Lab 10 Questions	185

Part XI. Vocabulary

35. Vocabulary	189
Image Credits	217
Links by Chapter	220
Accessibility Rubric	221
Mavs Open Press	
Errata and Versioning History	224
Mavs Open Press	





# About the Publisher

MAVS OPEN PRESS

## About Mavs Open Press

Creation of this resource was supported by Mavs Open Press, operated by the University of Texas at Arlington Libraries (UTA Libraries). Mavs Open Press offers no-cost services for UTA faculty, staff, and students who wish to openly publish their scholarship. The Libraries' program provides human and technological resources that empower our communities to publish new open access journals, to convert traditional print journals to open access publications, and to create or adapt open educational resources (OER). Resources published by Mavs Open Press are openly licensed using Creative Commons licenses and are offered in various e-book formats free of charge. Optional print copies may be available through the UTA Bookstore or can be purchased through print-on-demand services, such as Lulu.com.

## About OER

OER are free teaching and learning materials that are licensed to allow for revision and reuse. They can be fully self-contained textbooks, videos, quizzes, learning modules, and more. OER are distinct from public resources in that they permit others to use, copy, distribute, modify, or reuse the content. The legal permission to modify and customize OER to meet the specific learning objectives of a particular course make them a useful pedagogical tool.

## About Pressbooks

Pressbooks is a web-based authoring tool based on WordPress, and it is the primary tool that Mavs Open Press (in addition to many other open textbook publishers) uses to create and adapt open textbooks. In May 2018, Pressbooks announced their *Accessibility Policy*, which outlines their efforts and commitment to making their software accessible. Please note that Pressbooks no longer supports use on Internet Explorer as there are important features in Pressbooks that Internet Explorer doesn't support.

The following browsers are best to use for Pressbooks:

- Firefox
- Chrome
- Safari
- Edge

## About the Print Version

This publication was designed to work best online and features hyperlinks in the text. We have retained the blue font for hyperlinks in the print version to make it easier to find the URL in the “Links by Chapter” section at the back of the book.

## Contact Us

Information about open education at UTA is available online. If you are an instructor who is using this OER for a course, please let us know by filling out our OER Adoption Form. Contact us at [pressbooks@uta.edu](mailto:pressbooks@uta.edu) for other inquires related to UTA Libraries publishing services.

# Accessibility Statement

MAVS OPEN PRESS

UTA Libraries believe education needs to be available to everyone, which means supporting the creation of free, open, and accessible educational resources. We are actively committed to increasing the accessibility and usability of the OER we produce.

## Accessibility Features

The web version of this resource has been designed with accessibility in mind by incorporating the following features.

- It has been optimized for people who use screen-reader technology.
  - all content can be navigated using a keyboard.
  - links, headings, tables are formatted to work with screen readers and images have alt tags (coming soon).
- Information is not conveyed by color alone.
- Font may be resized from the tab on the top right of the screen.

## Other File Formats

In addition to the web version, this book is available in a number of file formats, including PDF, EPUB (for eReaders), MOBI (for Kindles), and various editable files. These formats can be retrieved from the “Download this book” drop-down menu on the book’s home page.

## Known Accessibility Issues

The rubric used to evaluate this resource for accessibility is included in the publication’s back matter. While we strive to make our resources as accessible and as usable as possible, we might not always get it right. Any issues we identify will be listed below.

### List of Known Accessibility Issues

---

Location of issue	Need for improvement	Timeline	Workaround
-------------------	----------------------	----------	------------

---

If you encounter problems accessing this resource, please contact us at [pressbooks@uta.edu](mailto:pressbooks@uta.edu) to let us know so we can address the issue.

Please include the following information:

- The location of the problem by providing a web address or page description
- A description of the problem
- The computer, software, browser, and any assistive technology you are using that can help us diagnose and solve your issue
  - e.g., Windows 10, Google Chrome (Version 65.0.3325.181), NVDA screenreader

This statement was last updated on October 8, 2018. It was modified from the *BCcampus Open Education Accessibility Toolkit – 2nd Edition* by Amanda Coolidge, Sue Doner, Tara Robertson, and Josie Gray and is used under a CC BY 4.0 International License.

# About This Project

## Overview

This is a lab manual for a college-level human anatomy course (BIOL 3446 at UTA). Despite the abundance of information readily available via Google, the mastery of anatomy requires a fair amount of *memorization* for quick recall. The activities in this manual encourage students to engage with new vocabulary in many ways, including grouping key terms, matching terms to structures, recalling definitions, and written exercises.

As the majority of college campuses do not have easy access to a cadaver, most of the activities in this manual utilize anatomical models. Also included are several dissections of animal tissues, and a significant amount of histological examinations.

Each unit includes both pre- and post-lab questions and six lab exercises designed for a classroom where students move from station to station during a three-hour period. Effort was put into equalizing the time required to perform each lab exercise, to facilitate class flow. The vocabulary terms used in each unit are listed at the end of the manual and serve as a checklist for practicals.

## Creation Process

When Malgosia Wilk-Blaszczak began teaching human anatomy at UTA she realized that while there are many commercially available manuals which incorporate a lot of human physiology, none of them focus solely on anatomy. She decided to create a manual for anatomy labs that could fill that void. The first version of this work was created and used in anatomy labs at UTA.

The idea of publishing the lab manual as an OER came to her courtesy of Michelle Reed, Open Education Librarian at UTA. To make this leap to an open platform, she enlisted the help of some of her best students. In Fall 2017, one year prior to the publication of this work, Wilk recruited a group of three excellent undergraduate teaching assistants. These students worked with UTA Libraries to identify openly licensed images and incorporate them into the text. Libraries' staff assisted in migrating the resource to Pressbooks, where it could be easily exported into a variety of formats. Furthermore, we conducted student surveys to gather feedback. Wilk's teaching assistants have always been an important part of her pedagogy. With their assistance, she was able to complete and openly publish this anatomy lab manual. The students put in the hard work to change all illustrations to Creative Commons licensed images and ensure proper attribution of all the images used. The student contributors, Kevin Alford, Andrea Compo-Valez, and Victoria Dorch, now alumni, reviewed and edited the resource, and are listed as co-authors of this manual.

Ultimately, open manuals reduce the cost to students while customizing the information and visuals required for class. In addition, the digital copy of the manual allows students to access homework and exercises wherever they are and is easily obtainable on the first day of class. Open manuals are also dynamic works that can be adapted to suit the needs of other institutions or groups that wish to explore the topic but do not have a solid framework to do so. The resulting OER is being piloted in human anatomy labs in Fall 2018 and will be revised following the pilot period with input from current students and lab instructors. It is our hope that this extension of Wilk's class will open the door to connecting our courses to broader collaborations and student input.

## About the Author

Dr. Malgosia Wilk-Blaszczak has taught human anatomy and human physiology courses for 30 years to medical and nursing students, and currently to undergraduate students at University of Texas at Arlington. She holds an M.D. and a Ph.D. in Neuroscience from the Warsaw Medical University. Ever since she discovered her father's anatomical fold-out "manikin" as a child, Dr. Wilk has been enamored by all aspects of the human body. In addition to teaching, she loves old medical illustration and never misses the chance to see them in museums when she travels.



*In the International Museum of Surgical Science, Chicago, IL*

# Acknowledgments

## Author's Note

I would like to dedicate this section to all my undergraduate teaching assistants, past and present. Every semester, I pick the most gifted students from previous semesters to serve as teaching assistants. I appreciate your commitment, passion, and hard work, but most of all, the amazing times we have had together. Special thanks to Clint Hassell and Natalie Winter who have served as my teaching assistants for many semesters, and have been good friends ever since. You have always done more than what was expected, and have given so much of your time and effort to support students to really grow and surprise us.

## Lead Author

Malgosia Wilk-Blaszczak, M.D., Ph.D. – Professor of Instruction, University of Texas at Arlington

## Contributors

Kevin A. Alford, B.S. – University of Texas at Arlington alumnus  
Andrea Campo-Velez, B.S. – University of Texas at Arlington alumna  
Victoria Dorch, B.S. – University of Texas at Arlington alumna

## Additional Thanks to...

Michelle Reed and Thomas Perappadan of UTA Libraries for assisting in the publication of this resource.

Jodi Wiley, B.S, UTA alumna, for creating and formatting class handouts that became the foundation for this OER.

Bradford Dimos, UTA graduate student, and Collin Funkhouser, UTA alumnus, for class-testing the previous version of this resource.

## About the Cover

Kyle Pinkos, UTA Libraries' Marketing Coordinator, designed the cover for this OER. The images used are in the public domain. Featured images, from *Ontleding Des Menschelyken Lichaams* by Govard Bidloo, are available from the U.S. National Library of Medicine.





PART I

# LAB I: ANATOMICAL LANGUAGE



# Lab I: Anatomical Language

## Measurable Outcomes

- Understand what the standard anatomical position is.
- Correctly identify a given plane by its correct name.
- Relate different structures of the body using the directional terms provided.
- Correctly identify the anatomical regions of the body.
- Demonstrate how to properly focus histology slides and identify key structures.
- Demonstrate an adequate understand of the material in this section.

## Background

A solid foundation is essential when learning any new skill. Understanding anatomical directions, articulations, planes, and regions are the foundation for learning anatomy.

The standard anatomical position of the human body is facing towards the observer, legs hip-width apart, feet facing forward, arms out slightly at either side with palms facing forward. When determining a structure's relative position, be sure to use this frame of reference. For example, it can be easy to confuse which side is the anterior aspect of the hands, therefore, one might incorrectly assume that the thumb is medial to the little finger. Remember, the anterior aspect of the hand is the palm, therefore the thumb is furthest from the center of the body and is lateral.

The archetypal body planes are frontal, sagittal and transverse planes. The frontal plane splits the body into anterior and posterior halves. The sagittal plane splits the body into left and right halves. The transverse plane splits the body into superior and inferior (top and bottom) halves. It is important to be able to identify a given plane so that you can orient yourself when a specimen, model or diagram is depicted a certain way. This same reasoning applies to the necessity of understanding directional terms such as anterior, inferior, distal and medial. It is recommended that you read the content prior to attending lab to make the most of your time.

**Vocabulary for Anatomical Language on page(s) 160-161.**

# I. Pre-Lab I

(5 points)

Last Name: \_\_\_\_\_ First Name: \_\_\_\_\_

## Instructions:

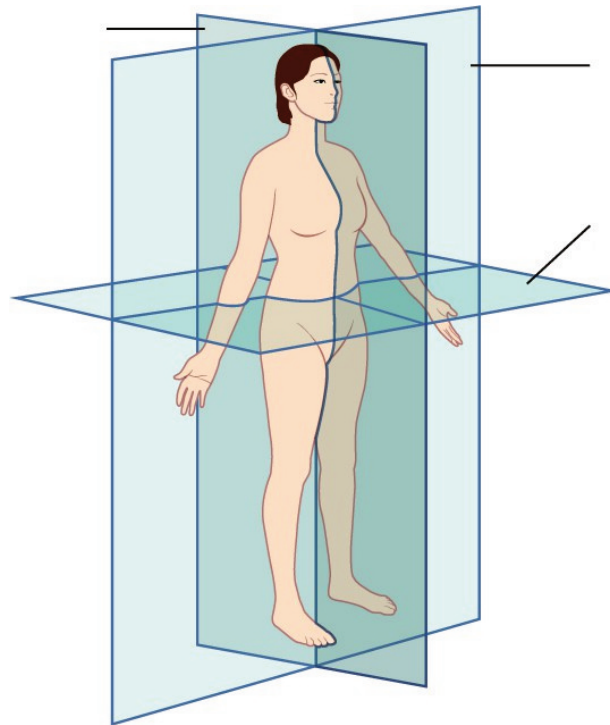
Fill in the table below with the appropriate terms. Note: For this lab only, you may use any anatomical structure of the human body to fill in the table.

For the remaining pages of the prelab, label the designated planes, regions, and directions.

(1 point)

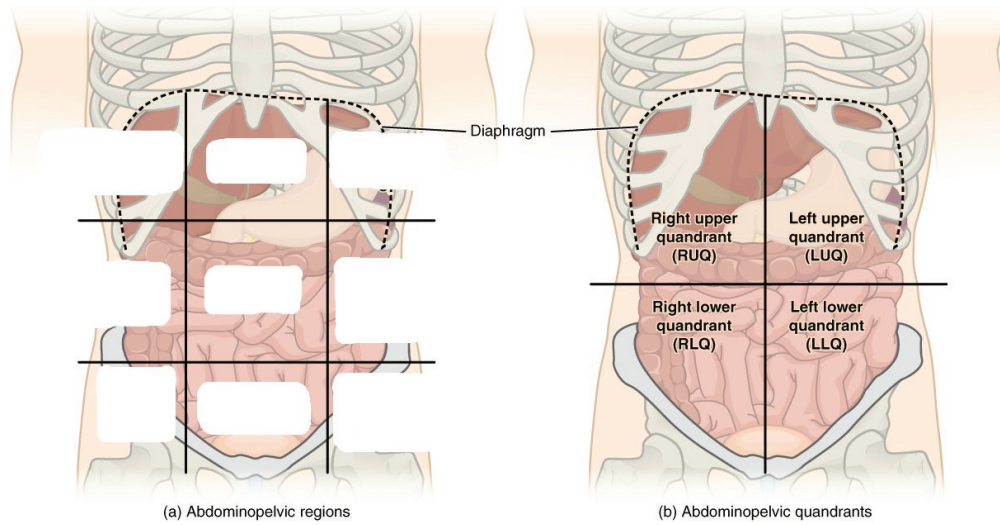
Name of a structure	is	directional term	to	Name of the second structure
forearm	is	proximal	to	hand
head	is	superior	to	
	is	inferior	to	tibia
breast	is	anterior	to	
	is	distal	to	upper arm
brain	is	medial	to	
	is	lateral	to	trunk

**Label the planes of the body. (1 point)**



Planes of Body

**Label all nine regions of the abdomen. (1 point)**

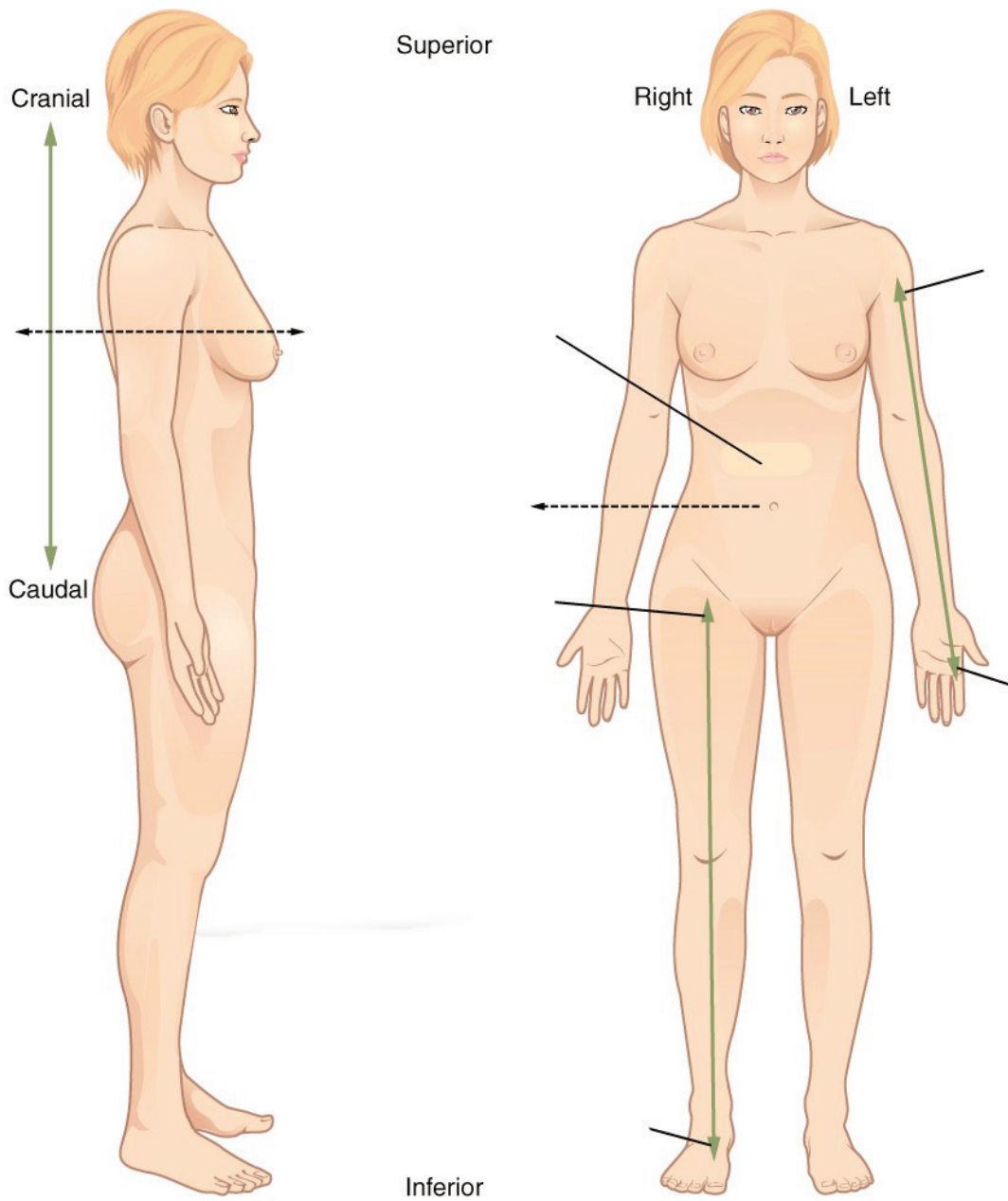


(a) Abdominopelvic regions

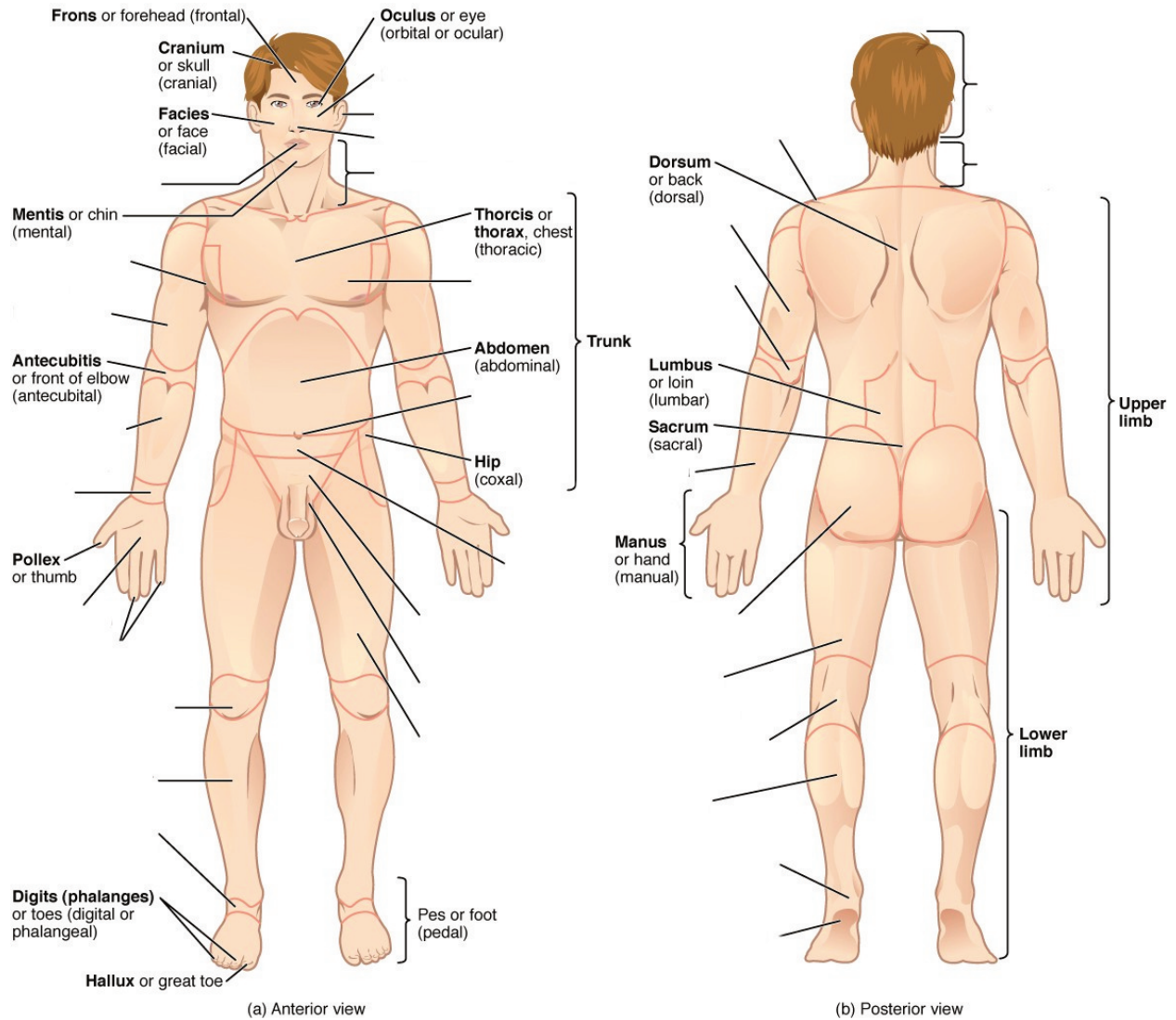
(b) Abdominopelvic quadrants



Label the anatomical directions designated by the lines and arrows. (1 point)



**Label the regions of the body. (1 point)**





## 2. Lab Activities

For this lab only, there will be three stations for each group to cycle through, stations one, two and three; stations four, five and six will mirror these stations for this lab only. A list of words is provided below that you are expected to identify, learn, and label on the models provided. You must use all the words provided. Using the colored tape provided, write the number that corresponds to the organ/structure and place it on your model. When complete, notify your TA so they may check your work.

Note: Do not simply label the models, it is crucial that you understand how to apply all of these terms in each system, for the rest of the semester!

For each additional station, directions will be provided for the particular activity.


### Stations One and Six: Histology

This is an advanced biology class, therefore you all likely have experience with microscopes. However, use these stations to refresh your memory of proper microscope etiquette, how to focus on a slide, and identify key features. For the remainder of this class, you will be expected to identify various tissues under the microscope. Be sure to ask your TA for assistance, and remember taking a picture of the slide to study later is not helpful if you don't take the time to study it in lab and understand which aspects are most important.


Basic instructions for use:

- Turn on the microscope. Move the stage down to its lowest setting and adjust the iris diaphragm until it allows the least amount of light in.
- Put the slide in position on the stage and be sure to start with the 5x objective to view it. While looking through the eyepiece, use the stage controls to move the specimen in line with the objective.
- Using the coarse adjustment knob, bring the stage up until you can see the specimen. Remember, it will not be in focus! If you bring the stage up too high, then switching to a higher objective, may touch the slide, scratch the lens, or even break the slide. Instead, use the fine adjustment knob to clarify the image and the iris diaphragm to allow as much light in as needed.
- Once the 5x is in focus, you can move to the next objective. Use the fine adjustment knob to focus before moving to the next objective. Do NOT touch the coarse adjustment knob.
- When you finish using the microscope, move the 5x objective to the start position and move the stage back down to its lowest position.

Sketch the slides available for today's lab and indicate the magnitude at which you are observing/sketching. Be sure to identify, include, and label your sketch with the corresponding structures listed beneath each slide. Use the images provided to guide you through this process.


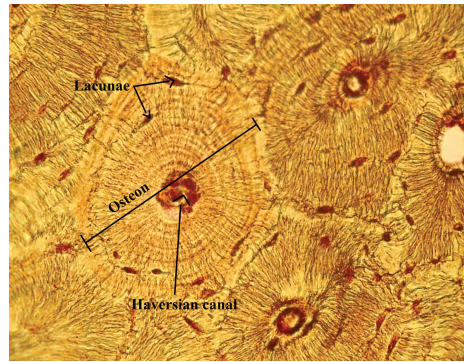
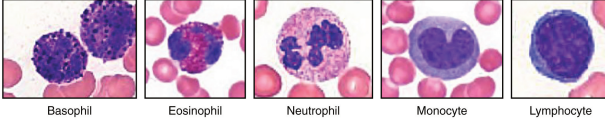


**Monocyte**




**Compact Bone**

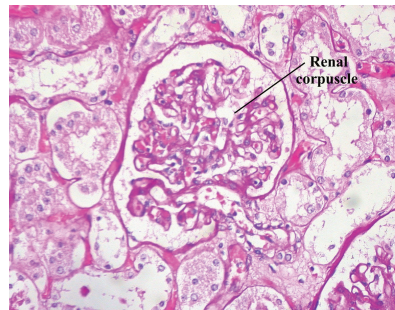
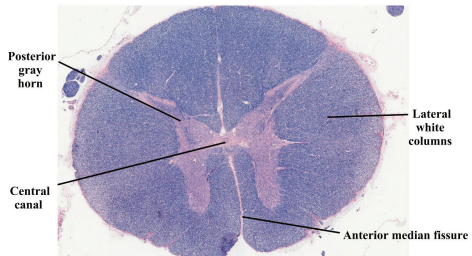
Key



**Spinal Cord**



**Kidney**



## Stations Two and Five: The Basics

The terms in the following tables are important in understanding the relationship between different organs and structures of the body. Using the models and diagrams in your atlas, learn how to identify the different body planes and the appropriate use of directional terms. When trying to understand body movements, it is helpful to act them out yourself.

Label the torso models of this station with the number that corresponds to the appropriate regions of the abdominal cavity using the colored tape. When you are finished, ask your TA to check your labeling. Before leaving the station, remove all of the labels you have placed on the model. Note the locus of each organ within each region.

### Body Planes

#1 frontal	#2 transverse	#3 sagittal
------------	---------------	-------------

### Directional Terms

#4 anterior	#7 inferior	#10 proximal	#13 superficial
#5 posterior	#8 lateral	#11 distal	#14 parietal
#6 superior	#9 medial	#12 deep	#15 visceral

## Abdominal Regions

#16 right hypochondriac region	#19 right lumbar region	#22 right iliac region
#17 epigastric region	#20 umbilical region	#23 hypogastric region
#18 left hypochondriac region	#21 left lumbar region	#24 left iliac region

### Stations Three and Four: Regions of the Body

Label the models of this station with the number that corresponds to the appropriate structure of the peripheral nervous system using the colored tape. When you are finished, ask your TA to check your labeling. Before leaving the station, remove all the labels you have placed on the model.

## Anatomical Regions

#1 cephalic	#11 brachial	#21 abdominal	#31 femoral
#2 cranial	#12 cubital	#22 hepatic	#32 patellar
#3 ocular (orbital)	#13 antecubital	#23 renal	#33 popliteal
#4 auricular (otic)	#14 olecranal	#24 umbilical	#34 crural
#5 buccal	#15 antebrachial	#25 lumbar	#35 sural
#6 nasal	#16 carpal (carpus)	#26 pelvic	#36 tarsal (tarsus)
#7 oral	#17 palmar	#27 inguinal	#37 calcaneal
#8 cervical	#18 digital (phalangeal)	#28 pubic	#38 pedal
#9 acromial	#19 thoracic	#29 sacral	#39 plantar
#10 scapular	#20 mammary	#30 gluteal	

## Common Anatomical Features

The following terms are useful to know and understand as they will reappear throughout this course.

#40 process	#45 sulcus	#50 facet	#54 septum
#41 tuberosity	#46 gyrus	#51 fossa	#55 raphe
#42 condyle	#47 foramen	#51 fundus	#56 ampulla
#43 epicondyle	#48 foramina	#52 hilum	
#44 fissure	#49 meatus	#53 isthmus	

### 3. Post-Lab 1 Questions

(2 points)

Last Name: \_\_\_\_\_ First Name: \_\_\_\_\_

1. Give the name of the anatomical region to which each of the following structures belongs. (0.5 points)
  - a. Elbow
  - b. Back of the knee
  - c. Belly button
  - d. Heel
  - e. Back of the neck
  
2. Determine which body plane is described by each of the following scenarios. (0.5 points)
  - a. If the human body were split into left and right halves.
  - b. If the human body were split into anterior and posterior halves.
  - c. If the human body were split into superior and inferior halves
  
3. There are nine abdominal regions. Name the three consecutive regions that run down the center of the abdomen. (0.5 points)
  
  
4. Fill in the blanks with the correct anatomical direction. (0.5 points)
  - a. Phalanges (fingers) are \_\_\_\_\_ to the carpals (wrist).
  - b. The tibia (medial bone of the lower leg) is \_\_\_\_\_ to the femur (large bone of the thigh).
  - c. The sural region is \_\_\_\_\_ to the crural region.
  - d. The left and right iliac regions are \_\_\_\_\_ to the hypogastric region of the abdominal cavity.
  - e. The nose is \_\_\_\_\_ to the ears.
  - f. The abdomen is \_\_\_\_\_ to the back.

PART II

## LAB 2: BONES AND BONE MARKINGS





# Lab 2: Bones and Bone Markings

## Measurable Outcomes

- Determine if a given bone is part of the axial or appendicular skeleton.
- Ascertain the major bones of the skull, as well as any markings or unique features, the regions of the vertebral column, parts of a typical vertebra, along with the other bones and features of the axial skeleton.
- Identify the bones of the appendicular skeleton and their unique features.
- Designate bones as either left or right when applicable. Examples include the ulna, humerus, femurs, scapulas, and clavicles.
- Understand how different bones fit together and articulate. Demonstrate this by assembling different regions of the body using the bones provided.
- Differentiate compact, spongy and dry bone histology slides. This includes identifying the unique characteristics of each.
- Demonstrate an adequate understand of the material in this section.

## Background

The skeletal system is the primary structural organ system of the body. Many people think of the skeletal system as being static in that it is unchanging, however, this is not the case. Bones, like other organ systems, have specialized cells which allow them to perform a variety of essential tasks. Osteoblast are responsible for secreting the bony matrix necessary for bone formation. Osteoclast, meanwhile, are large multinucleated cells responsible for the dissolution and reabsorption of bone. It is made mostly of collagen, which gives bone its soft framework, and calcium phosphate which adds strength and hardness to the structure. It is divided into the axial and the appendicular skeleton. The *axial skeleton* consists of the skull, hyoid bone, vertebral column, sternum, and ribs. Whereas the *appendicular skeleton* consists of the clavicle, scapula and the rest of the upper and lower limbs. Without the foundational structure of the skeletal system, there would be nothing to support the body and provide points of attachment for muscles. Bones function to protect internal organs, assist body movements, store and release calcium and phosphorous, participate in blood cell production and store fat in the yellow marrow. Bones also function to protect internal organs, assist body movements, and the storage and release of ions such as calcium and phosphorous. Furthermore, long bones contain both hemopoietic (red) and stromal (yellow) marrow which produce red blood cells and fat cells respectively. Each of these cells have specific functions that are key to the development and repair of a bone over time. The two types of bone tissue are compact and spongy bone. *Compact bone* is typically found along the perimeter of bones and makes up the majority of the diaphysis of long bones. It is stronger than spongy bone and provides more stability. Compact bone is made up of circular units called osteons. Osteons are composed of rings called *lamellae* that spiral down into a central canal, known as the *Haversian canal*. This central canal is the passage for nerves, blood vessels, and lymphatics. *Spongy bone*, on the other hand, is typically the deepest layer of a bone's composition. It is made of trabeculae which give spongy bone its characteristic lighter weight. There are five classifications of bones

based on their shape, long bones, short bones, flat bones, irregular bones and sesamoid bones. The shape and composition of each bone allow them to function as mentioned above.

**Vocabulary for Bones and Bone Markings on page(s) 161-162.**

# 4. Pre-Lab 2

(5 points)

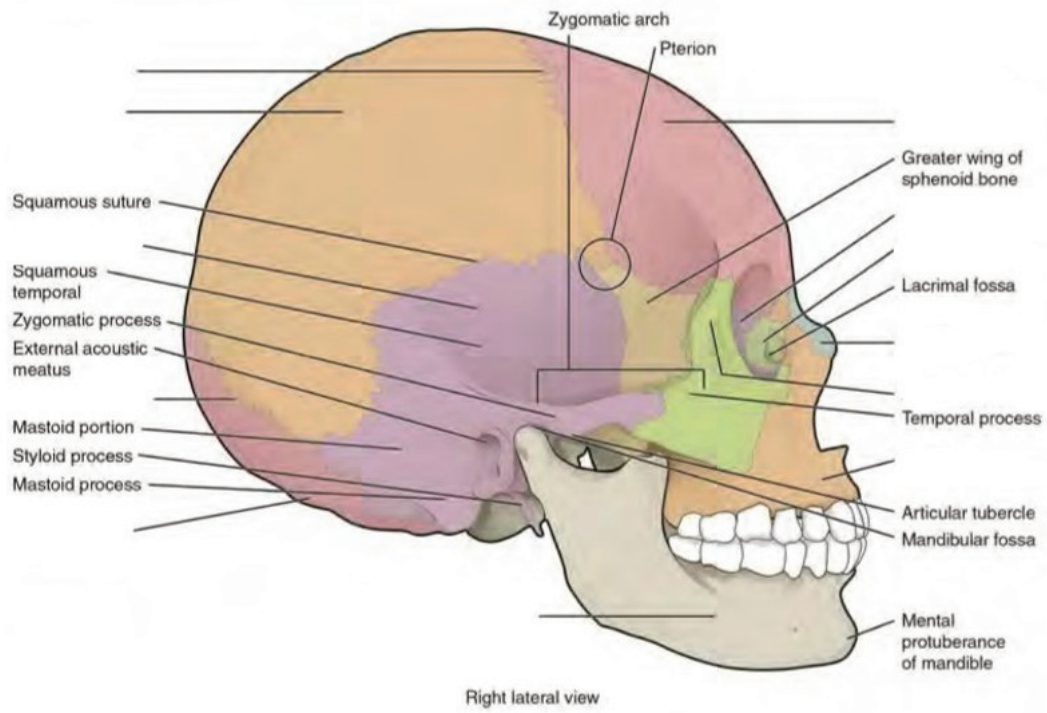
Last Name: \_\_\_\_\_ First Name: \_\_\_\_\_

## Instructions:

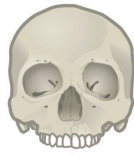Fill in the table with the appropriate terms. For the remaining illustrations, label the structures indicated.  
(1 point)

Name of a structure	is	directional term	to	Name of the second structure
radius	is	proximal	to	ulna
femur	is	superior	to	
	is	inferior	to	thoracic vertebrae
patella	is	anterior	to	
	is	distal	to	metacarpals
tibia	is	medial	to	
	is	lateral	to	sternum

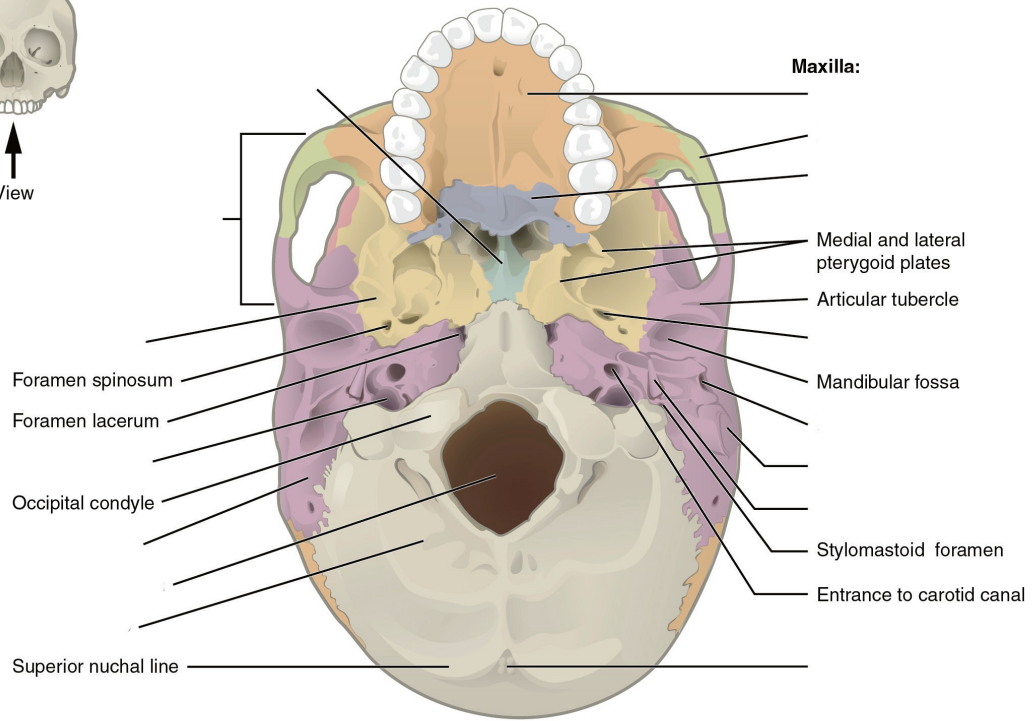
**Label the cranial structures and bones. (0.5 points)**



**Label the cranial bones and special features. (0.5 points)**

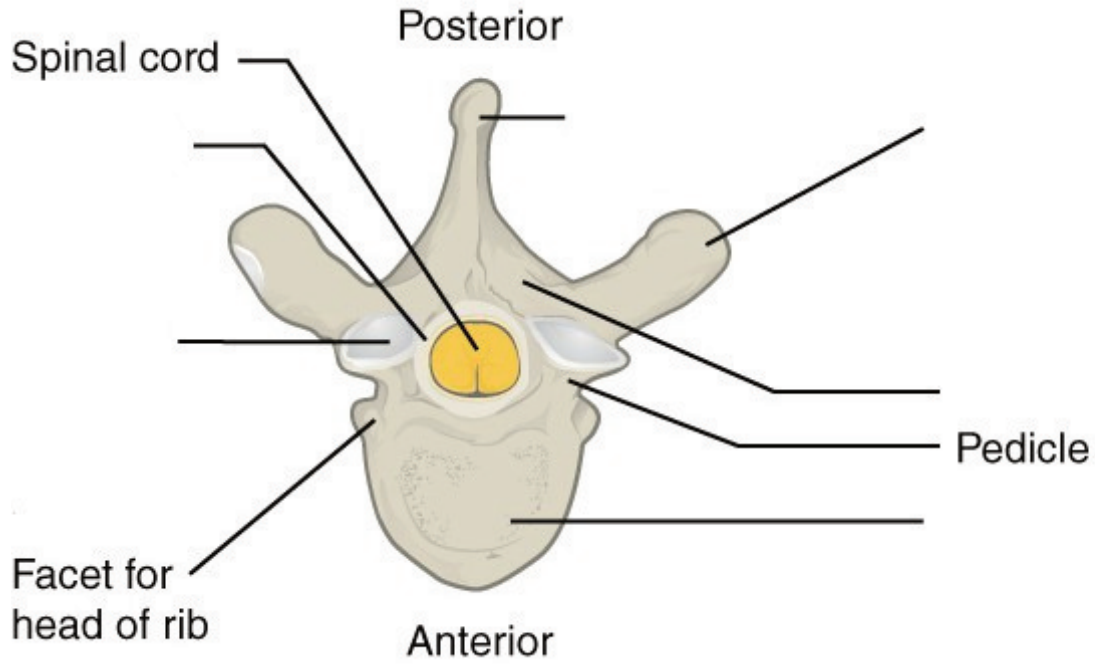


View

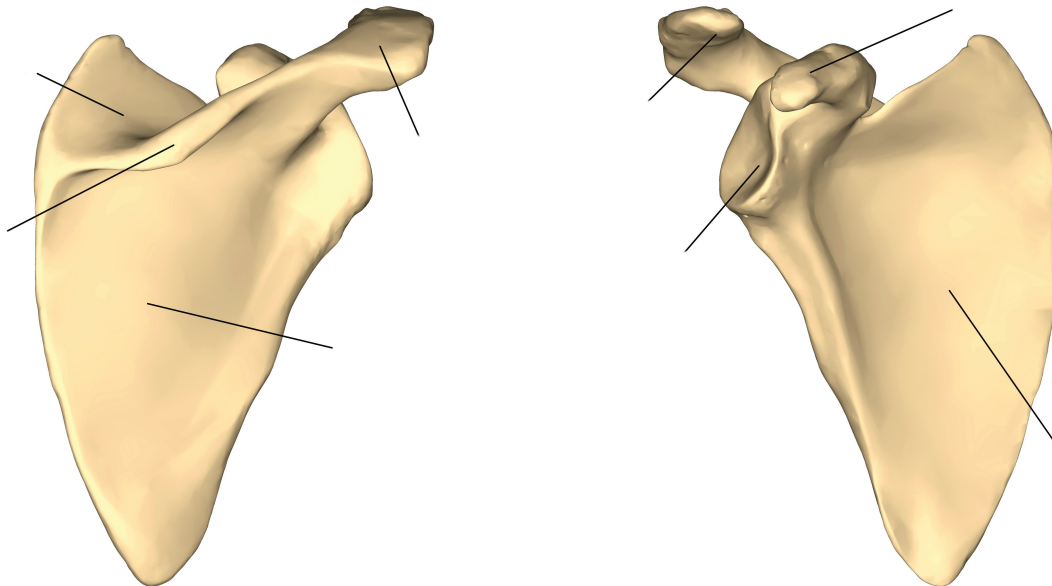


(a) Inferior view

Label the distinctive parts of the vertebra. (0.5 points)

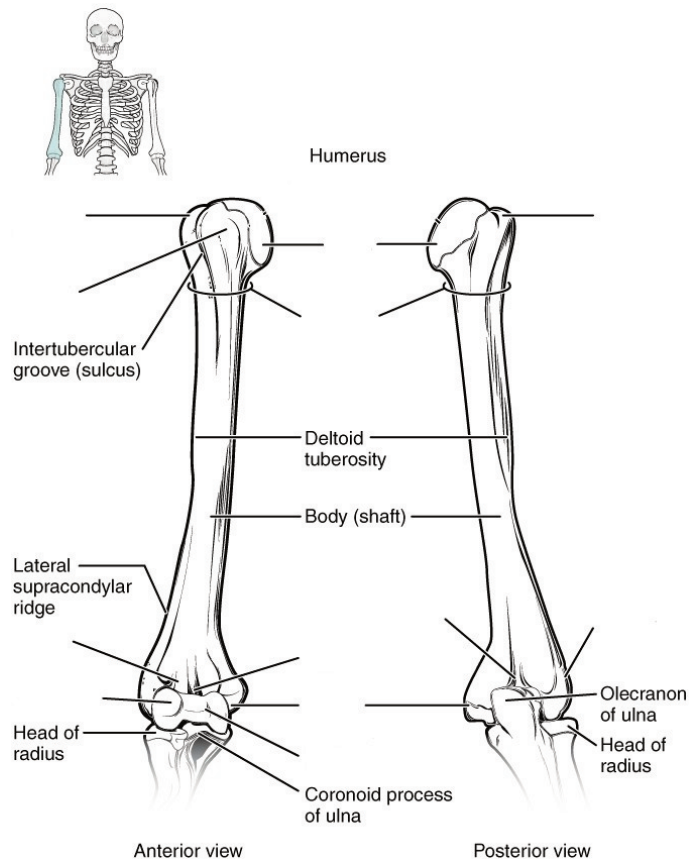


Label the features of the scapula. (0.5 point)



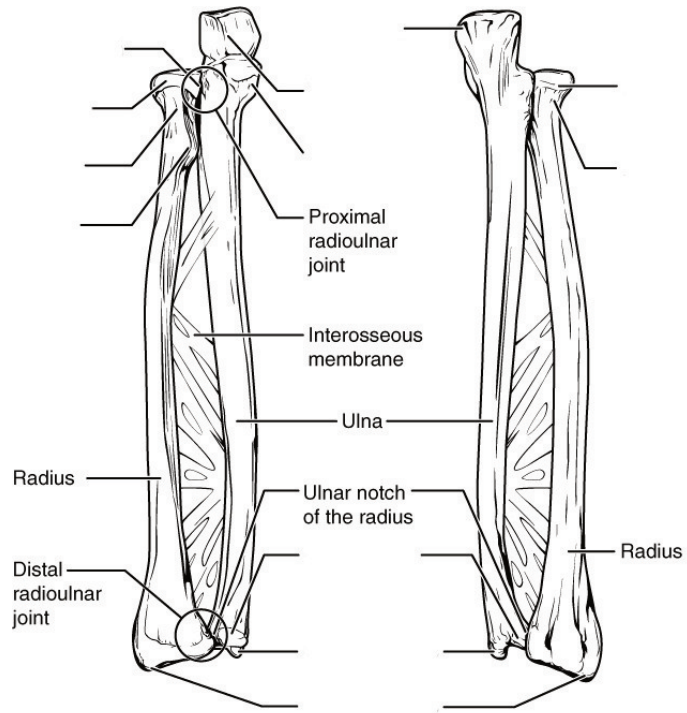


**Label the features of the humerus. (0.5 points)**

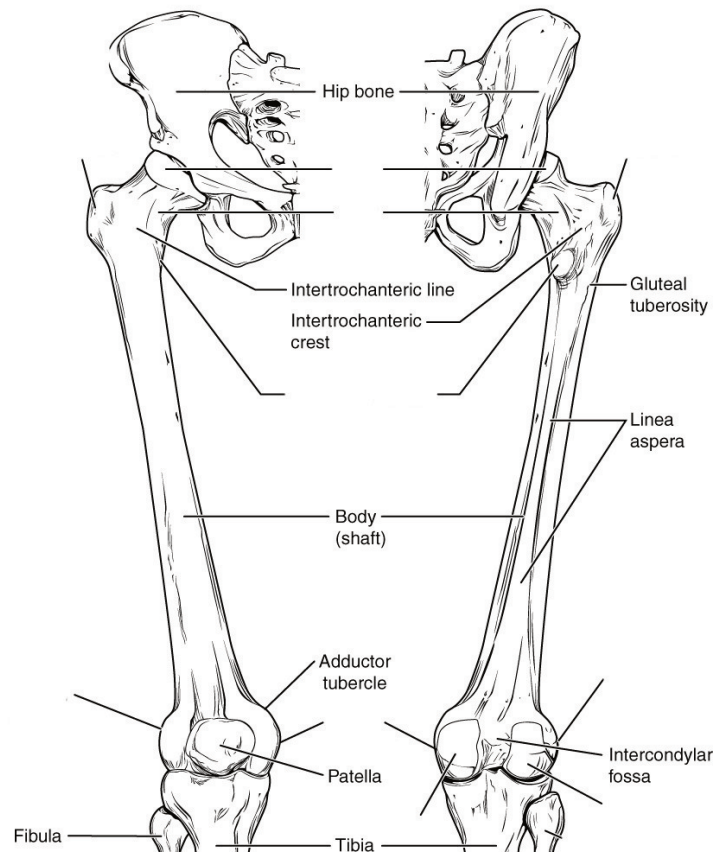


**Label the features of the radius and ulna. (0.5 point)**

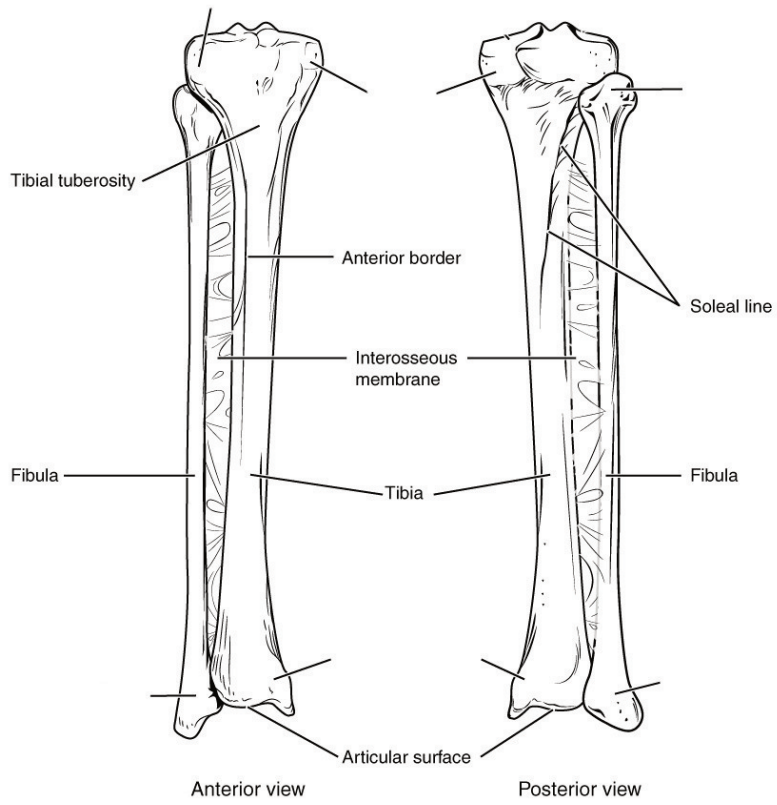




**Label the features of the femur. (0.5 points)**



**Label the features of the tibia and fibula. (0.5 points)**



## 5. Lab Activities

A list of words is provided below that you are expected to identify, learn, and label on the models provided. Note that not all models will have some of the organs/structures, so be sure to find them on an alternate model. You must use all the words provided. Using the colored tape provided, write the number that corresponds to the organ/structure and place them on your model. When complete, notify your TA so they may check your work.

For each additional station, directions will be provided for the activity.

### Station One: Skull

Label the models of this station with the number that corresponds to the appropriate structure of the peripheral nervous system using the colored tape. When you are finished, ask your TA to check your labeling. Before leaving the station, remove all the labels you have placed on the model.

Note: For the following structures, be able to differentiate between left and right halves when applicable.

### Bones of Skull

#1 frontal bone	#5 ethmoid bone	#9 zygomatic bone	#13 superior nasal conchae
#2 parietal bone	#6 sphenoid bone	#10 nasal bone	#14 middle nasal conchae
#3 temporal bone	#7 palatine bone	#11 vomer	#15 inferior nasal conchae
#4 occipital bone	#8 maxilla	#12 lacrimal bone	#16 mandible

### Skull Bone Markings

#18 external auditory meatus	#20 styloid process	#22 cribriform plate of ethmoid bone	#24 zygomatic process of temporal bone
#19 mastoid process	#21 external occipital protuberance	#23 olfactory foramina	#25 temporal process of zygomatic bone

## Special Features of Skull

#26 foramen magnum	#28 foramen ovale	#30 coronal suture	#32 lambdoid suture
#27 jugular foramen	#29 sella turcica	#31 sagittal suture	

## Station Two: Axial Skeleton cont.

Label the models of this station with the number that corresponds to the appropriate structure of the peripheral nervous system using the colored tape. When you are finished, ask your TA to check your labeling. Before leaving the station, remove all the labels you have placed on the model.

Note: For the following structures, be able to differentiate between left and right halves when applicable.

## Vertebral Column

#1 hyoid Bone	#4 thoracic region	#7 coccyx
#2 vertebrae	#5 lumbar region	#8 intervertebral foramen
#3 cervical region	#6 sacrum	#9 intervertebral disc

## Parts of Typical Vertebra

#10 body	#12 lamina	#14 transverse process	#16 inferior articular process	#18 facet of inferior articular process
#11 vertebral foramen	#13 spinous process	#15 superior articular process	#17 facet of superior articular process	

## Unique Cervical Vertebrae and Characteristics

#19 bifid spinous process	#21 atlas	#23 dens
#20 transverse foramen	#22 axis	

## Thoracic Cage

#24 sternum	#26 sternal body	#28 ribs
#25 manubrium	#27 xiphoid process	#29 costal cartilage

## Station Three: Limb Assembly

In this station, you will be given a bucket filled with random bones some of which you will use to assemble an arm and a leg. Note below which bucket you are working with. Your assignment is to lay out the bones of each limb in their correct positions relative to each other and determine which bones do not belong to either limb. Additionally, you will need to determine whether each limb is a right or left limb; circle your results below. When you are finished, ask your TA to check whether you have assembled and identified your limbs correctly.


**Bucket #** \_\_\_\_\_

**Upper limb:** Left / Right

**Lower limb:** Left / Right


## Station 4: Histology

Sketch the slides available for today's lab and specify the magnitude at which you are observing/ sketching. Be sure to identify and label your sketch with the corresponding structures listed beneath each slide.



**Compact Bone**

Osteon Lamellae, Lacunae, Volkmann's canals, Haversian canal



**Spongy Bone**

## Station Five: Upper Limbs

Label the models of this station with the number that corresponds to the appropriate structure of the peripheral nervous system using the colored tape. When you are finished, ask your TA to check your labeling. Before leaving the station, remove all the labels you have placed on the model.

Note: For the following structures, be able to differentiate between left and right halves when applicable.

### Clavicle

#1 acromial end of clavicle	#2 sternal end of clavicle
-----------------------------	----------------------------

### Scapula

#3 glenoid cavity	#5 coracoid process	#7 supraspinous fossa	#9 subscapular fossa
#4 acromion	#6 spine of scapula	#8 infraspinous fossa	

### Humerus

#10 head	#13 lesser tubercle	#16 coronoid fossa	#19 lateral epicondyle
#11 neck	#14 trochlea	#17 radial fossa	#20 olecranon fossa
#12 greater tubercle	#15 capitulum	#18 medial epicondyle	

### Ulna

#21 head	#23 trochlear notch	#25 radial notch
#22 olecranon	#24 coronoid process	# 26 styloid process



## Radius

#27 head	#29 radial tuberosity
#28 neck	#30 styloid process

## Hand and Wrist

#31 carpals (8)	#33 phalanges	#35 middle phalanges
#32 metacarpals	#34 proximal phalanges	#36 distal phalanges

## Station Six: Lower Limbs

Label the models of this station with the number that corresponds to the appropriate structure of the peripheral nervous system using the colored tape. When you are finished, ask your TA to check your labeling. Before leaving the station, remove all the labels you have placed on the model.

Note: For the following structures, be able to differentiate between left and right halves when applicable.

### Pelvis

#1 ilium	#3 ischium	#5 pubis	#7 acetabulum
#2 iliac crest	#4 ischial spine	#6 pubic symphysis	

### Femur

#8 head	#11 lesser trochanter	#14 medial condyle
#9 neck	#12 medial epicondyle	#15 lateral condyle
#10 greater trochanter	#13 lateral epicondyle	#16 intercondylar fossa

# 17 patella
--------------

### Tibia

#18 lateral condyle	#19 medial condyle	#20 medial malleolus
---------------------	--------------------	----------------------

### Fibula

#21 head	#22 lateral malleolus
----------	-----------------------

## Foot and Ankle

#23 tarsals (7)	#25 metatarsals	#27 proximal phalanges	#29 distal phalanges
#24 calcaneus	#26 phalanges	#28 middle phalanges	

## 6. Post-Lab 2 Questions

**(3 points)**

Last Name: \_\_\_\_\_ First Name: \_\_\_\_\_

1. Replace the common name of following bones with their corresponding anatomical names. (0.5 points)

- a. Fingers
- b. Hip
- c. Head
- d. Bones of the lower arm
- e. Knee
- f. Ankle
- g. Bone of the thigh
- h. Upper jaw
- i. Lower jaw
- j. Shins
- k. Tailbone
- l. Toes
- m. Collarbone
- n. Shoulder blade

2. Name five bones of the axial and appendicular skeleton. (0.5 points)

- 1.
- 2.
- 3.
- 4.
- 5.
- 1.
- 2.
- 3.
- 4.
- 5.

3. What makes the atlas (C1) and axis (C2) different from the rest of the vertebrae? (0.5 points)
  
  
  
  
  
  
  
  
  
  
4. What is unique about the hyoid bone? (0.5 points)
  
  
  
  
  
  
  
  
  
  
5. When a person is seated on the floor “criss-cross” style, which bones are touching the ground? (0.5 points)
  
  
  
  
  
  
  
  
  
  
6. Name a bone that is inferior (1), superior (2) and medial (3) to the radius. (0.5 points)
  - 1.
  - 2.
  - 3.



PART III

## LAB 3: SPINAL CORD AND SPINAL NERVES





# Lab 3: Spinal Cord and Spinal Nerves

## Measurable Outcomes

- Correctly identify the structures which constitute comprise the spinal cord and its extensions.
- Explain the differences between the meninges.
- Differentiate the spinal plexuses.
- Determine the origin, pathway and target organs of the spinal nerves.
- Classify the structures of the spinal cord on the given histology slides.
- Demonstrate an adequate understand of the material in this section.

## Background

The spinal cord is made of *white matter* encompassed by *gray matter* with a *central canal* running through it that serves as a path for *cerebrospinal fluid (CSF)*. The gray matter is divided into *posterior (dorsal) grey horns* which contain sensory neurons, and *lateral and anterior (ventral) horns* that contain the cell bodies of motor neurons. The surrounding white matter is divided into *anterior (ventral) white columns*, *lateral white columns*, and *posterior (dorsal) white columns*. The *grey commissure* is the gray matter posterior to the central canal where the neurons from either side of the spinal cord crossover. The same principle applies to the *white commissure* which lies anteriorly to the gray matter.

The spinal cord has several layers to protect it from damage. Beginning superficially and working our way deeper, the vertebral column encases the spinal cord and provides a hard shell for protection. Deep to the vertebrae are the meninges, consisting of the *dura mater*, *arachnoid mater*, and *pia mater*. Extensions from the pia mater, the denticulate ligaments, suspend the spinal cord in CSF and act as a shock absorber.

The spinal cord begins at the terminal end of the brain stem and extends to approximately the L1 vertebra adults and L2 vertebrae in children; it is located within the vertebral foramen and is divided into 4 distinct regions. The cervical segment extends from C1 to the C7 vertebrae. The thoracic segment extends from T1 to the T8 vertebrae. The lumbar segment corresponds with T9-T11 vertebrae. Finally, the sacral segment extends from T12 to L2. The *cervical enlargement*, C4-T1, is a bulbous structure from which many neurons of the upper extremities invaginate. Likewise, the *lumbar enlargement*, T9-T12, is a bulbous structure from which neurons that innervate the lower limbs originate.

Note: do not confuse the regions of the spine with the regions of the spinal cord, they are not the same.

There are 31 pairs of spinal nerves: 8 cervical pairs 12 thoracic pairs, 5 lumbar pairs, 5 sacral pairs and 1 coccygeal pair. However, nerves from every other area along the spinal cord do not do this; they first converge in a network called a plexus. With the exception of the thoracic region, nerves of the cervical, brachial, lumbar and sacral regions of the spinal cord branch from a network of nerves known as plexuses.

**Vocabulary for Spinal Cord and Spinal Nerves can be found on page(s) 171-172.**

# 7. Pre-Lab 3

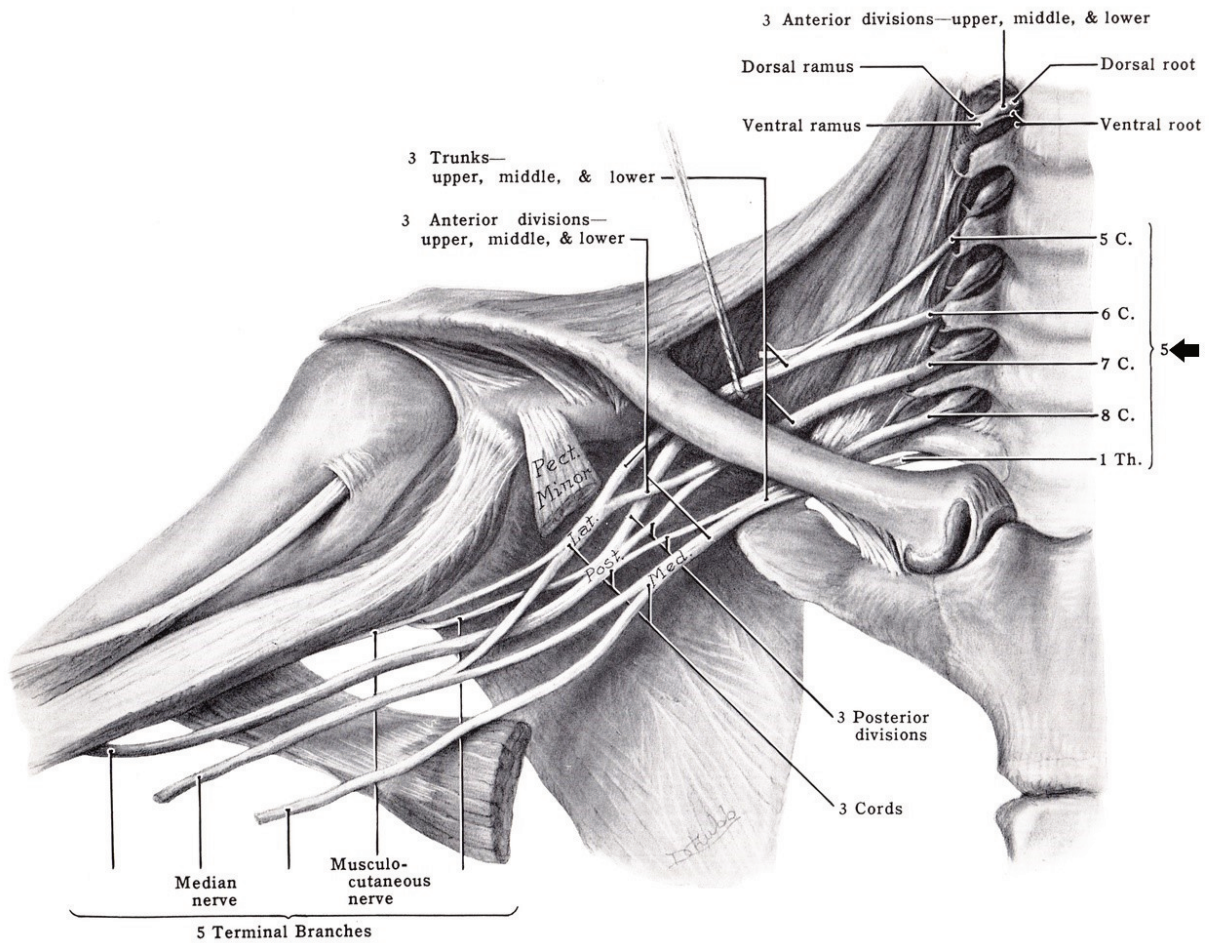
(5 points)

Last Name: \_\_\_\_\_ First Name: \_\_\_\_\_

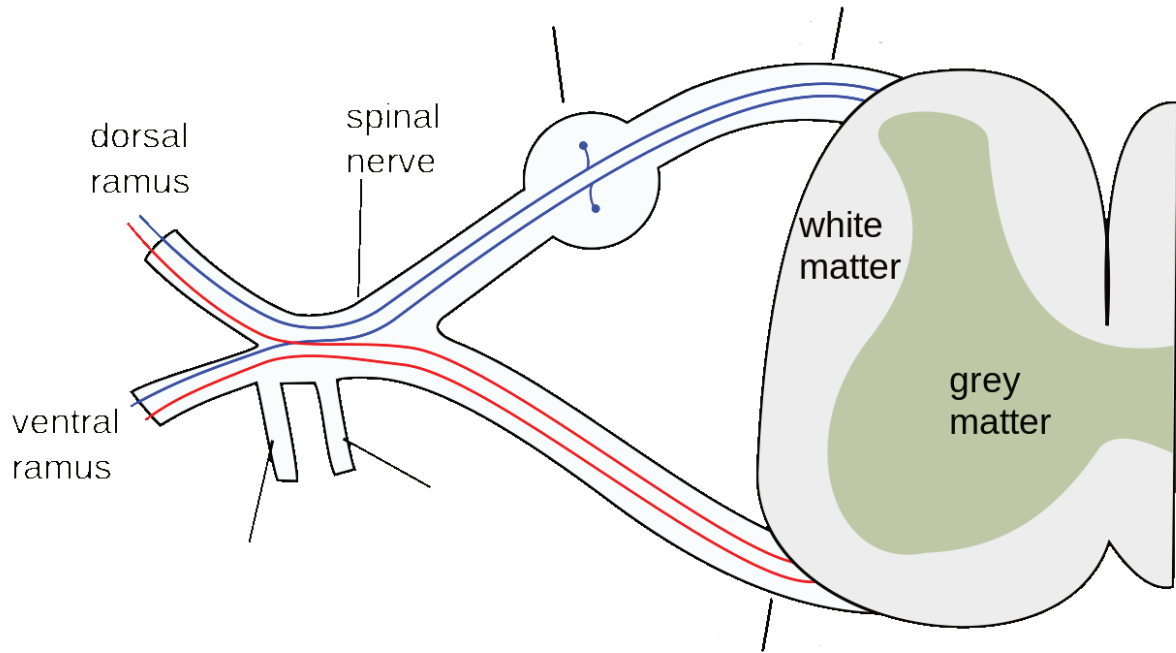
## Instructions:

What region of the spinal cord lacks a nerve plexus? (1 point)

Label the structures of the cervical plexus? (1 point)

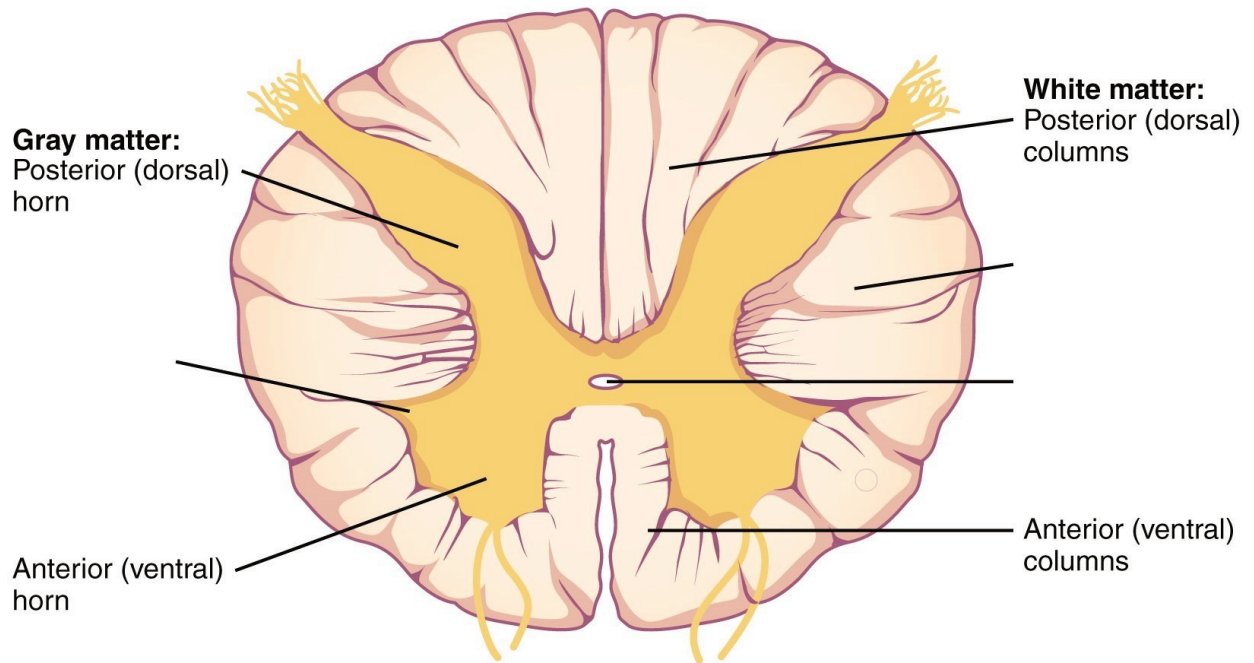


Label the structure of the spinal nerve. (1 point)



Which segment of the spinal cord has the highest white to grey matter ratio; which region has the highest grey matter to white matter? **(1 point)**

Label the following structures of the spinal cord. **(1 point)**



## 8. Lab Activities

A list of words is provided below that you are expected to identify, learn, and label on the models provided. Note that not all models will have some of the organs/structures, so be sure to find them on an alternate model. You must use all the words provided. Using the colored tape provided, write the number that corresponds to the organ/structure and place them on your model. When complete, notify your TA so they may check your work.

For each additional station, directions will be provided for the activity.

### Station One: Spinal Cord

Label the models of this station with the # that corresponds to the appropriate structure of the spinal cord and its protective structures using the colored tape. When you have finished, have your TA check your labeling. Before leaving the station, remove all of the labels you have placed on the model.

Note: For the following structures, be able to differentiate left and right halves when applicable.

#1 vertebral column	#4 dura mater	#7 subarachnoid space	#10 denticulate ligaments	#13 filum terminale
#2 spinal meninges	#5 subdural space	#8 cerebrospinal fluid	#11 spinal cord	#14 cauda equina
#3 epidural space	#6 arachnoid mater	#9 pia mater	#12 conus medullaris	

### Spinal Cord

#15 anterior median fissure	#19 posterior white columns	#23 anterior white commissure	#27 thoracic innervation segment	#31 lumbar enlargement
#16 posterior median sulcus	#20 anterior gray horns	#24 posterior gray commissure	#28 lumbar innervation segment	
#17 anterior white columns	#21 lateral gray horns	#25 central canal	#29 sacral innervation segment	
#18 lateral white columns	#22 posterior gray horns	#26 cervical innervation segment	#30 cervical enlargement	

## Station Two: Spinal Nerves and Cervical Plexus

Label the models of this station with the number that corresponds to the appropriate structure of the peripheral nervous system using the colored tape. When you are finished, ask your TA to check your labeling. Before leaving the station, remove all the labels you have placed on the model.

Note: For the following structures, be able to differentiate between left and right halves when applicable.

### Spinal Nerves

#1 cervical nerve one (C1)	#9 thoracic nerve one (T1)	#17 thoracic nerve nine (T9)	#25 lumbar nerve five (L5)
#2 cervical nerve two (C2)	#10 thoracic nerve two (T2)	#18 thoracic nerve ten (T10)	#26 sacral nerve one (S1)
#3 cervical nerve three (C3)	#11 thoracic nerve three (T3)	#19 thoracic nerve eleven (T11)	#27 sacral nerve two (S2)
#4 cervical nerve four (C4)	#12 thoracic nerve four (T4)	#20 thoracic nerve twelve (T12)	#28 sacral nerve three (S3)
#5 cervical nerve five (C5)	#13 thoracic nerve five (T5)	#21 lumbar nerve one (L1)	#29 sacral nerve four (S4)
#6 cervical nerve six (C6)	#14 thoracic nerve six (T6)	#22 lumbar nerve two (L2)	#30 sacral nerve five (S5)
#7 cervical nerve seven (C7)	#15 thoracic nerve seven (T7)	#23 lumbar nerve three (L3)	#31 coccygeal nerve one (Coc1)
#8 cervical nerve eight (C8)	#16 thoracic nerve eight (T8)	#24 lumbar nerve four (L4)	

### Cervical plexus

Note: When labeling the nerves that exit the cervical plexus, focus on their location, the connections between the nerves of the plexus, and what they innervate. Also note any interesting characteristics you find, for example, which is the longest nerve? Make use of your textbook and atlas during this time.

#32 lesser occipital nerve	#34 transverse cervical nerve	#36 superior root of Ansa cervicalis nerve	#38 phrenic nerve
#33 great auricular nerve	#35 supraclavicular	#37 inferior root of Ansa cervicalis nerve	#39 segmental branches

## Station Three: Brachial Plexus

Label the models of this station with the number that corresponds to the appropriate structure of the peripheral


nervous system using the colored tape. When you are finished, ask your TA to check your labeling. Before leaving the station, remove all the labels you have placed on the model.

Note: When labeling the nerves that exit the brachial plexus, focus on their location, the connections between the nerves of the plexus and what they innervate. Also note any interesting characteristics you find, for example, which is the longest nerve? Make use of your textbook and atlas during this time.

#1 dorsal scapular nerve	#5 musculocutaneous nerve	#9 lower subscapular nerve	#13 medial pectoral nerve
#2 long thoracic nerve	#6 lateral pectoral nerve	#10 axillary nerve	#14 medial cutaneous nerve of arm
#3 nerve to subclavius	#7 upper subscapular nerve	#11 median nerve	#15 medial cutaneous nerve of forearm
#4 suprascapular nerve	#8 thoracodorsal nerve	#12 radial nerve	#16 ulnar nerve


### Station 4: Histology

Sketch the slides available for today's lab and specify the magnitude at which you are observing/ sketching. Be sure to identify and label your sketch with the corresponding structures listed beneath each slide.



**Spinal cord**

Anterior median fissure, Posterior median sulcus, Anterior white columns, Lateral white columns, Posterior white columns, Anterior gray horns, Lateral gray horns, Posterior gray horns, Anterior white horns, Posterior gray commissure, Central canal



**Sympathetic ganglion**

## Station Five: Lumbar Plexus

Label the models of this station with the number that corresponds to the appropriate structure of the peripheral nervous system using the colored tape. When you are finished, ask your TA to check your labeling. Before leaving the station, remove all the labels you have placed on the model.

Note: When labeling the nerves that exit the lumbar plexus, focus on their location, the connections between the nerves of the plexus and what they innervate. Also note any interesting characteristics you find, for example, which is the longest nerve? Make use of your textbook and atlas during this time.

#1 iliohypogastric nerve	#3 genitofemoral nerve	#5 femoral nerve
#2 ilioinguinal nerve	#4 lateral cutaneous nerve of thigh	#6 obturator nerve

## Station Six: Sacral Plexus

Label the models of this station with the number that corresponds to the appropriate structure of the peripheral nervous system using the colored tape. When you are finished, ask your TA to check your labeling. Before leaving the station, remove all the labels you have placed on the model.

Note: When labeling the nerves that exit the sacral plexus, focus on their location, the connections between the nerves of the plexus and what they innervate. Also note any interesting characteristics you find, for example, which is the longest nerve? Make use of your textbook and atlas during this time.

#1 superior gluteal nerve	#4 nerve to quadratus	#7 posterior cutaneous nerve of thigh	#10 tibial median plantar nerve	#13 deep common fibular nerve
#2 inferior gluteal nerve	#5 nerve to obturator internus and superior gemellus	#8 pudendal nerve	#11 tibial lateral plantar nerve	
#3 nerve to piriformis	#6 perforating cutaneous nerve	#9 sciatic nerve	#12 superficial common fibular nerve	



## 9. Post-Lab 3 Questions

**(2 points)**

Last Name: \_\_\_\_\_ First Name: \_\_\_\_\_

1. What is the longest nerve in the body? (0.5 points)
2. In what region(s) of the spinal cord do the nerves which innervate the lower body originate? (0.5 points)
3. The spinal cord is divided into how many segments? List the number of segments in each portion of the spinal column. (0.5 points)
4. List the spinal meninges and the relevant spaces in between, as well as what occupies those spaces. (0.5 points)



PART IV

## LAB 4: BRAIN AND CRANIAL NERVES



# Lab 4: Brain and Cranial Nerves

## Measurable Outcomes

- Complete the dissection of the sheep brain and identify (with a pin) all of the structures of the brain using the corresponding vocabulary list.
- Locate structures of the brain and cranial nerves on the various models in the lab.
- Identify the 12 cranial nerves as well as their target organs.
- Determine the composition of the of the brain from dissections.
- Determine/trace the path of cerebrospinal fluid through the brain.
- Differentiate histology from different regions of the brain.
- Demonstrate an adequate understand of the material in this section.

## Background

The central nervous system entails all neurons of the brain and spinal cord. The brain is the central processing organ of the body and contains 100 billion neurons and a remarkable 1 trillion glial cells. It is estimated that cortical neurons alone consume around 5 billion ATP molecules per second. Whats more, some neurons can have axons that extend several feet. Unlike the spinal cord, the gray and white matter in the brain are arranged in three segments. From deep to superficial, the innermost region is made of gray matter which is surrounded by the myelinated axons of the white matter. The thin layer of the cerebral cortex responsible for higher order cognition is the outermost layer of gray matter. The brain is divided into four major regions, the brainstem, diencephalon, cerebellum, and cerebrum. The brainstem contains the medulla oblongata, pons, and midbrain (which houses the pineal gland). Caudal to the forebrain is the diencephalon, a region which contains the epithalamus, hypothalamus, thalamus and third ventricle.

There are four cavities in the brain called ventricles; here cerebrospinal fluid (CSF) is produced and circulated by ependymal cells and the choroid plexuses. The two largest ventricles lie within each cerebral hemispheres and are known as the lateral ventricles. Cerebrospinal fluid drains from the lateral ventricles, through the interventricular foramen and into the third ventricle. The third ventricle lies between the halves of the thalamus. From here, it flows through the cerebral aqueduct (aqueduct of sylvius) and into the fourth ventricle, which lies between the cerebellum and the pons. Cerebrospinal fluid drains from the fourth ventricle, into the lateral and median apertures and down through the central canal of the spinal cord. Cerebrospinal fluid leaks out through foramina into the subarachnoid space where it is reabsorbed by veins on the surface of the brain and spinal cord.

Like the spinal cord, the brain is protected by three meninx, the dura, arachnoid and pia mater. Unlike the spinal meninges, the cranial dura mater is subdivided into two distinct layers; the periosteal layer, which is the superficial mot layer, and the inner meningeal dura mater. The two dural layers form the superior sagittal sinus which collectively channels venous blood from the brain. The falx cerebri divides the cerebrum into left and right hemispheres, the falx cerebelli divides the cerebellum into left and right hemispheres, and the tentorium cerebelli forms a physical barrier between the cerebrum and the cerebellum.

**Vocabulary for the Brain and Cranial Nerves on page(s) 162-163.**

# 10. Pre-lab 4

(5 points)

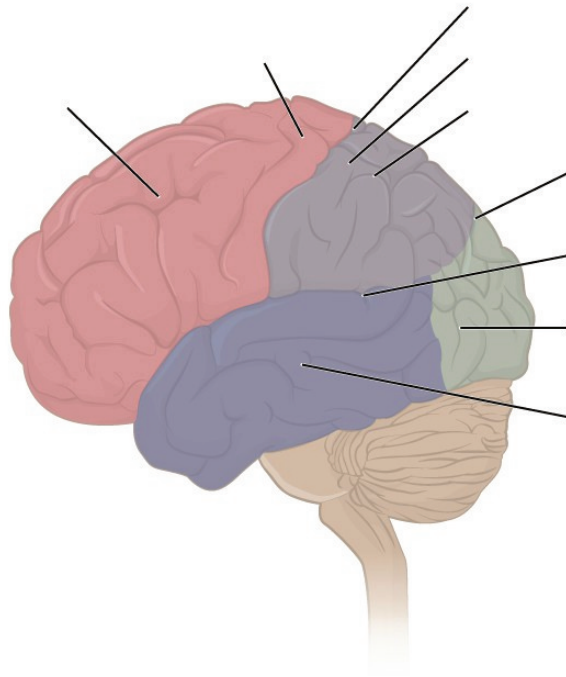
Last Name: \_\_\_\_\_ First Name: \_\_\_\_\_

## Instructions:

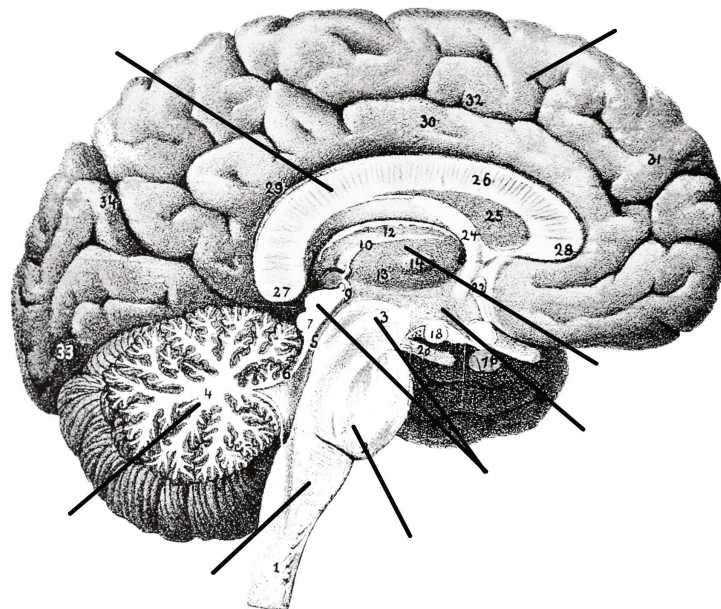
Fill in the table below with the appropriate terms. For the remaining exercises, label the designated structures.  
(1 point)

Name of a structure	is	directional term	to	Name of the second structure
pons	is	anterior	to	cerebellum
corpus callosum	is	superior	to	
	is	inferior	to	hypothalamus
precentral gyrus	is	anterior	to	
	is	superficial	to	diencephalon
interthalamic adhesion	is	medial	to	
	is	superior	to	pons

Label the sulci, gyri, and lobes of the cerebrum. (1 point)



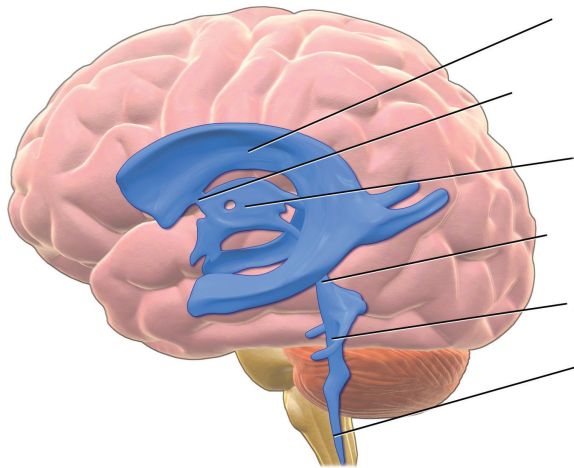
Label the major structures of the brain. (1 point)



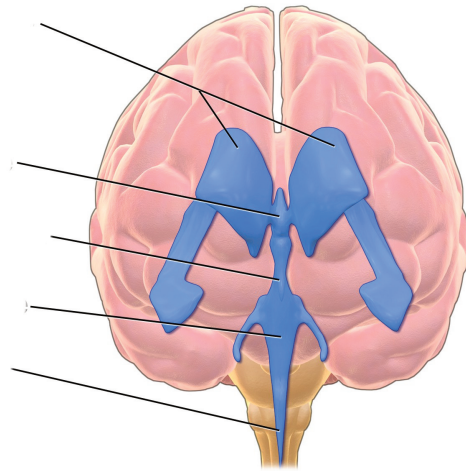




Label the ventricles and passageway of CSF through the brain. (1 point)

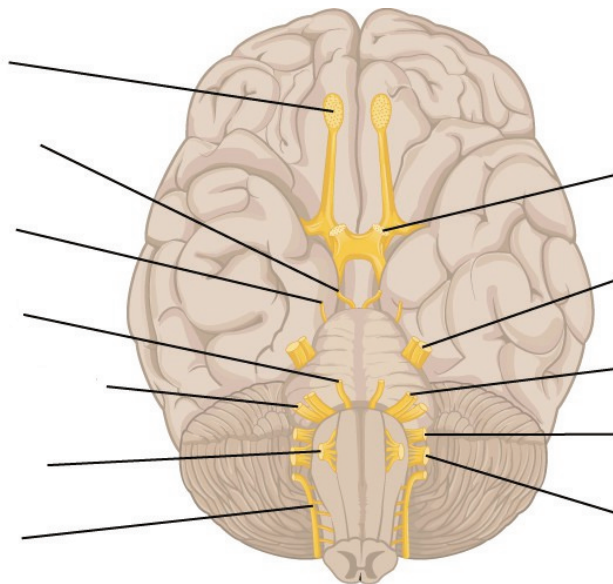


*(lateral view)*



*(anterior view)*

Label the cranial nerves. (1 point)



## II. Lab Activities

A list of words is provided below that you are expected to identify, learn, and label on the models provided. Note that not all models will have some of the organs/structures, so be sure to find them on an alternate model. You must use all the words provided. Using the colored tape provided, write the number that corresponds to the organ/structure and place them on your model. When complete, notify your TA so they may check your work.

For each additional station, directions will be provided for the activity.

### Station One: Brain

Label the models of this station with the number that corresponds to the appropriate structure of the peripheral nervous system using the colored tape. When you are finished, ask your TA to check your labeling. Before leaving the station, remove all the labels you have placed on the model.

Note: For the following structures, be able to differentiate between left and right halves when applicable.

#### Cerebrum

#1 cerebral cortex	#3 temporal lobes	#5 occipital lobe
#2 frontal lobe	#4 parietal lobes	#6 insula

#### Diencephalon

#7 thalamus	#9 mammillary bodies	#11 pineal glands
#8 hypothalamus	#10 epithalamus	

#### Brainstem

#12 midbrain	#14 superior colliculi	#16 cerebral peduncles	#18 medulla oblongata
#13 tectum (corpora quadrigemina)	#15 inferior colliculi	#17 pons	

## Cerebellum

#19 arbor vitae	#21 vermis
#20 folia	#22 cerebellar peduncles

## Other important structures

#23 basal nuclei	#25 fornix	#27 pituitary gland	#29 optic chiasm
#24 corpus callosum	#26 cingulate gyrus	#28 infundibulum	

## Station Two: Unique Features and Pathway of CSF

Label the models of this station with the number that corresponds to the appropriate structure of the peripheral nervous system using the colored tape. When you are finished, ask your TA to check your labeling. Before leaving the station, remove all the labels you have placed on the model.

Note: For the following structures, be able to differentiate between left and right halves when applicable.

## Composition of the Brain

#1 gray matter	#2 white matter
----------------	-----------------

## Superficial Characteristics of the Brain

#3 gyri (convulsions)	#5 sulci	#7 postcentral gyrus	#9 central sulcus	#11 transverse fissure
#4 fissures	#6 precentral gyrus	#8 lateral cerebral sulcus	#10 parieto-occipital sulcus	#12 longitudinal fissure

## Cranial Meninges

These features may not be shown on models, but it is important to be able to identify them in diagrams and on the brains that you will dissect.

#13 dura mater	#15 falx cerebelli	#17 arachnoid mater
#14 falx cerebri	#16 tentorium cerebelli	#18 pia mater

## Ventricles and Associated Structures

Using the terms in the table below, determine the pathway of cerebrospinal fluid.

#19 lateral ventricles	#21 interventricular foramen	#23 cerebral aqueduct (aqueduct of midbrain)	#25 choroid plexuses
#20 septum pellucidum	#22 third ventricles	#24 fourth ventricles	#26 cerebrospinal fluid

## Station Three: Cranial Nerves


Label the models of this station with the number that corresponds to the appropriate structure of the peripheral nervous system using the colored tape. When you are finished, ask your TA to check your labeling. Before leaving the station, remove all the labels you have placed on the model.

While learning the names, corresponding numbers and location of each of the cranial nerves, be sure to connect these to their functions and the structures they innervate.


#1 olfactory nerve (I)	#4 trochlear nerve (IV)	#7 facial nerve (VII)	#10 vagus nerve (X)
#2 optic nerve (II)	#5 trigeminal nerve (V)	#8 vestibulocochlear/ acoustic nerve (VIII)	#11 Accessory/spinal nerve (XI)
#3 oculomotor nerve (III)	#6 abducens nerve (VI)	#9 glossopharyngeal nerve (IX)	#12 hypoglossal nerve (XII)

## Station 4: Histology

Sketch the slides available for today's lab and specify the magnitude at which you are observing/ sketching. Be sure to identify and label your sketch with the corresponding structures listed beneath each slide.



**Cerebrum**



**Cerebellum**

## Station Five: Brain Dissection without Meninges

- Orientate the brain such that the posterior aspect containing the brain stem is facing you. Obtain the scalpel from your kit and place it on the anterior (farthest from you) portion of the longitudinal fissure. Using a scalpel, firmly press down on the brain while simultaneously bringing the scalpel carefully towards you; this makes a clean incision down the sagittal plane of the brain. (**DO NOT make sawing motions with the scalpel.**) Continue to make incisions until you have separated the brain into its two hemispheres.
- Obtain pins from the table and place them into as many structures as you can identify. Your lab TA will come around and ask you to identify the pins you have placed.

\*If you are the last table to use this station, be sure to clean off the dissection kits in the lab sink.

## Station Six: Brain Dissection with Meninges

- The brain you will receive at this station will have the tough, fibrous meninges still surrounding it. Pinch this tissue between your fingers to separate it from the brain. Using the scissors in your dissection kit, carefully make an incision in the tissue until you have created a hole from which to cut. Cut the meninx, make sure that it comes away from the brain without pulling on the brain's outer cortex.
- Once the outermost meninx has been removed orientate the brain such that the posterior aspect containing the brain stem is facing you. Obtain the scalpel from your kit and place it on the anterior (farthest from you) portion of the longitudinal fissure of the brain. Using the scalpel, firmly press down on the brain while simultaneously bringing the scalpel carefully towards you; this makes a clean incision down the sagittal plane of the brain. (**DO NOT make sawing motions with the scalpel.**) Continue to make incisions until you have separated the brain into its two main hemispheres.
- Obtain pins from the table and place them on as many structures as you can identify. Your lab TA will come around and ask you to identify the pins you have placed.

\*If you are the last table to use this station, be sure to clean off the dissection kits in the lab sink.

## 12. Post-Lab 4 Questions

(3 points)

Last Name: \_\_\_\_\_ First Name: \_\_\_\_\_

1. Which of the following structures are not part of the brainstem? (Circle the appropriate response(s)) (0.5 points)

- Cerebral hemisphere
- Cerebellum
- Pons
- Medulla oblongata
- Midbrain
- Diencephalon

2. What are the three primary parts of the diencephalon? (0.5 points)

3. Identify the meningeal (or associated) structures described below: (1 point)

1. Outermost meninx that covers the brain and is composed of tough, fibrous connective tissue
2. Location of CSF production
3. Innermost meninx that covers the brain
4. Structures instrumental in returning cerebrospinal fluid (CSF) to the venous blood in the dural venous sinuses
5. A dural fold separating the cerebrum from the cerebellum

4. Provide the name and number of the cranial nerves involved in each of the following activities, sensations or disorders. (1 point)

1. \_\_\_\_\_ Rotating the head
2. \_\_\_\_\_ Smelling coffee



3. \_\_\_\_\_ Elevating the eyelids; pupillary constriction
4. \_\_\_\_\_ Slowing the heart; swallowing
5. \_\_\_\_\_ Involved in Bell's palsy (facial paralysis); crying
6. \_\_\_\_\_ Chewing food; feeling a toothache
7. \_\_\_\_\_ Listening to music; seasickness
8. \_\_\_\_\_ Secretion of saliva; tasting well-seasoned food
9. \_\_\_\_\_ Involved in "rolling" the eyes (three nerves; provide numbers only)
10. \_\_\_\_\_ Swallowing; speaking (motor only)
11. \_\_\_\_\_ Seeing the PowerPoint during lecture



PART V  
LAB 5: SPECIAL SENSES



# Lab 5: Special Senses

## Measurable Outcomes

- Explain the function of each special sense.
- Identify all of the provided anatomical structures of the special senses on available models.
- Determine the pathways of vision, hearing, balance, taste, and olfaction.
- Correctly identify the histology slides and the structures that can be differentiated on each.
- Determine the structures of the dissected eye.
- Demonstrate the ability to count the taste buds of a lab partner using the experiment provided.
- Demonstrate an adequate understand of the material in this section.

## Background

In anatomy, special senses are the senses that have organs specifically devoted to them such as vision, gustation, olfaction, audition, and equilibrioception. These senses have specialized organs that detect and process stimuli and send signals to the brain which lead to the perception of that stimulus. These specialized organs include the tongue, the nose, the eyes and the ears.

The *tongue* is a crucial organ in mechanical digestion and taste. Taste buds contain taste receptor cells which are the smallest functional unit in gustation. Taste buds can be found throughout the length of the upper digestive tract. On the surface of the tongue are protrusions called papillae. *Circumvallate papillae* are arranged in a v shape pattern on toward the base of the tongue, on the dorsal aspect, and contain more than 100 taste buds each. The *fungiform papillae* are found all over the dorsal aspect of the tongue and contain only about 5 taste buds each. The *foliate papillae* are found on the lateral aspects of the tongue and only contain taste buds during childhood. Finally, there are the *filiform papillae* which, like the fungiform papillae, are found all over the tongue, however, they do not contain taste buds. Instead, their barbed shape provides the friction for moving food around during mastication.

The olfactory epithelium is easily discernable on most models. Unlike any of the following special senses, neurons from the olfactory bulb bypass the thalamus and synapse directly with the olfactory cortex.

The ear is a complex organ which houses special structures that allow us to hear, balance and orientate ourselves. Sound waves are collected by the *auricle* and funneled into the external acoustic meatus. The ear is divided into three sections, the outer, middle, and inner ear. The outer ear consists of the *auricle* which extends through the *external auditory canal* and terminates at the *tympanic membrane*. The main structures of the middle ear are the *auditory ossicles*, Eustachian tube, oval window and round window. The auditory ossicles inward from the tympanic membrane, are the malleus, incus, and stapes. The base of the stapes covers the *oval window* which allows sound waves to pass from the tympanic membrane, into the cochlea of the inner ear. The inner ear is the innermost region of the ear where the *cochlea*, *vestibule*, and *semicircular canals* are.

The cochlea, vestibule, and semicircular canals are responsible for hearing, static and dynamic equilibrium respectively. The vestibulocochlear nerve branches, into the cochlear branch, which innervates the cochlea, and the vestibular branch which innervates the vestibule and semicircular canals.

The eye is the specialized organ of sight which has three principal layers, the *fibrous tunic*, the *vascular tunic* and the *neural tunic*. Furthermore, there are two main chambers, the *anterior chamber*, containing *aqueous humor* and the *posterior chamber*, that contains *vitreous humor*. In the neural tunic of the retina, light propagates from the ganglionic cells through the bipolar cells to the rods and cones, which, somewhat paradoxically hyperpolarize opposite the direction of light.

The lacrimal apparatus frames the eye and coats the sclera and cornea in lacrimal fluid, a bactericide, which lubricates and protects them. The lacrimal apparatus is made of the *lacrimal gland*, *lacrimal canaliculi*, *lacrimal sac* and *nasolacrimal duct*. This network of structures allows tears produced by the *lacrimal gland* to cover the eye, drain through the lacrimal puncta into the lacrimal canaliculi, collect in the lacrimal sac, travel down the nasolacrimal duct and finally empty into the nose. This is why crying leads to a runny nose.

**Vocabulary for Special Senses can be found on page(s) 169-171.**

# 13. Pre-lab 5

(5 points)

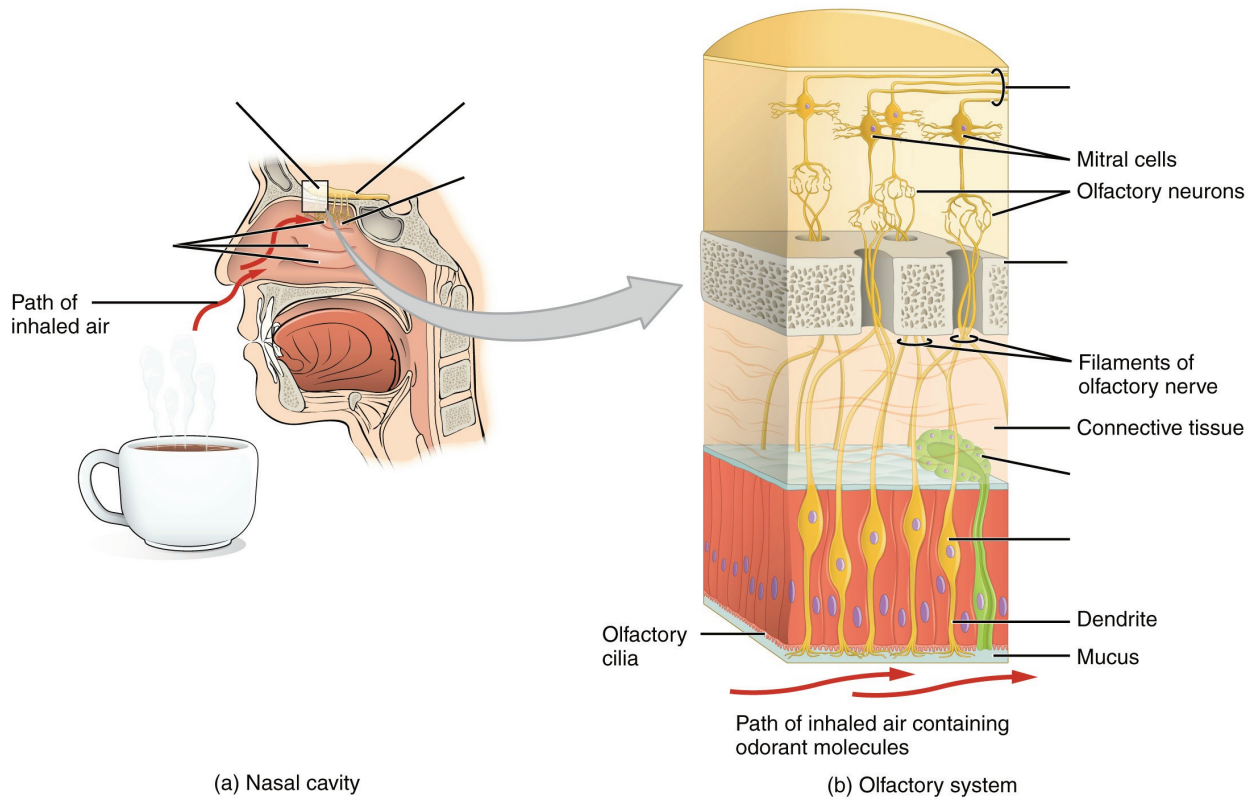
Last Name: \_\_\_\_\_ First Name: \_\_\_\_\_

## Instructions:

Fill in the table below with the appropriate terms. For the remaining exercises, label the structures accordingly.  
(1 point)

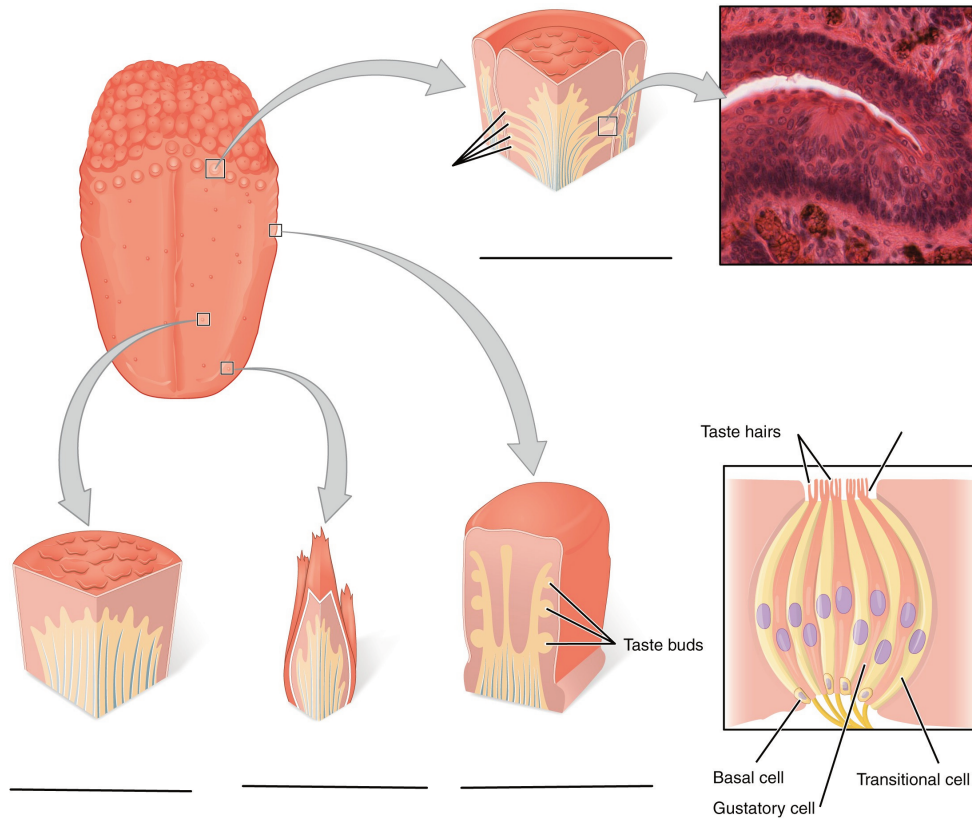
Name of a structure	is	directional term	to	Name of the second structure
retina	is	posterior	to	lens
middle nasal conchae	is	superior	to	
	is	inferior	to	cribriform plate
cornea	is	anterior	to	
	is	distal	to	tympanic membrane
medial rectus	is	medial	to	
	is	lateral	to	tongue

Label the structures of the olfactory epithelium and olfactory pathway. (1 point)

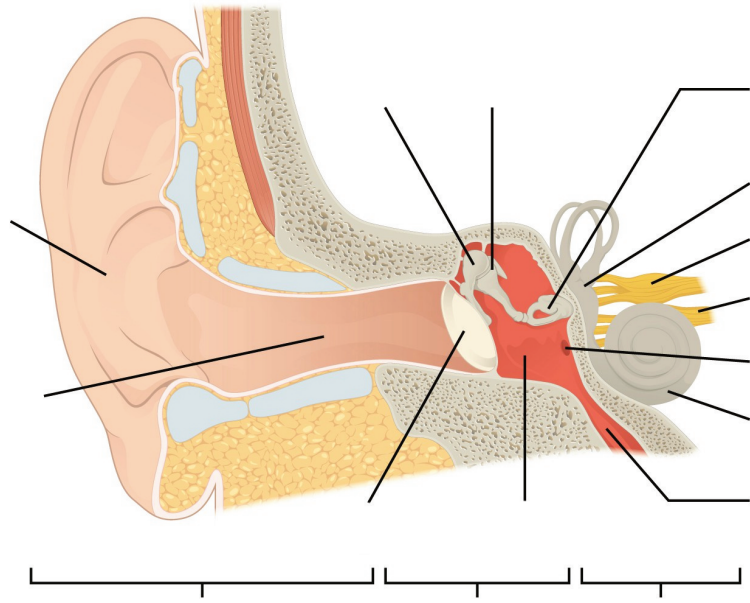




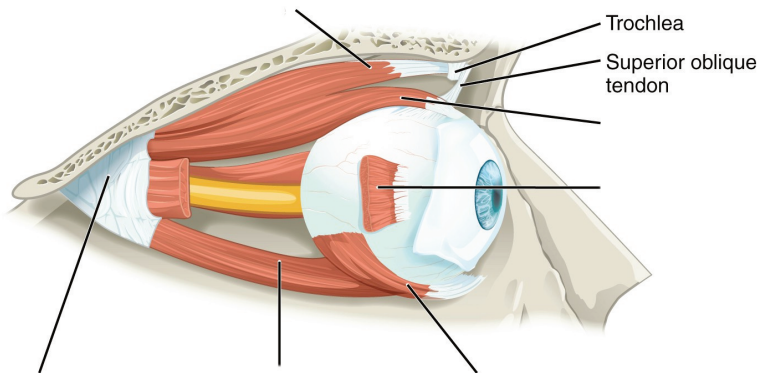
Label the types of papillae and parts of the taste buds. (1 point)



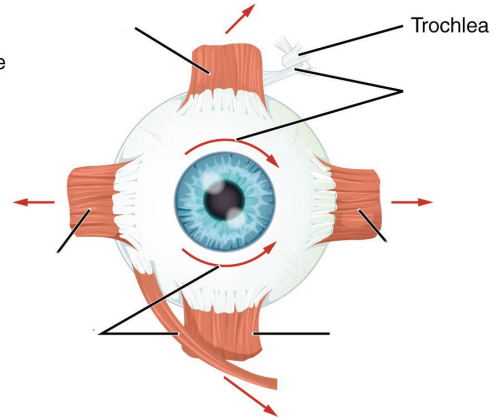
Label the regions and structures of the ear. (1 point)



**Label the muscles of the eye. (0.5 points)**

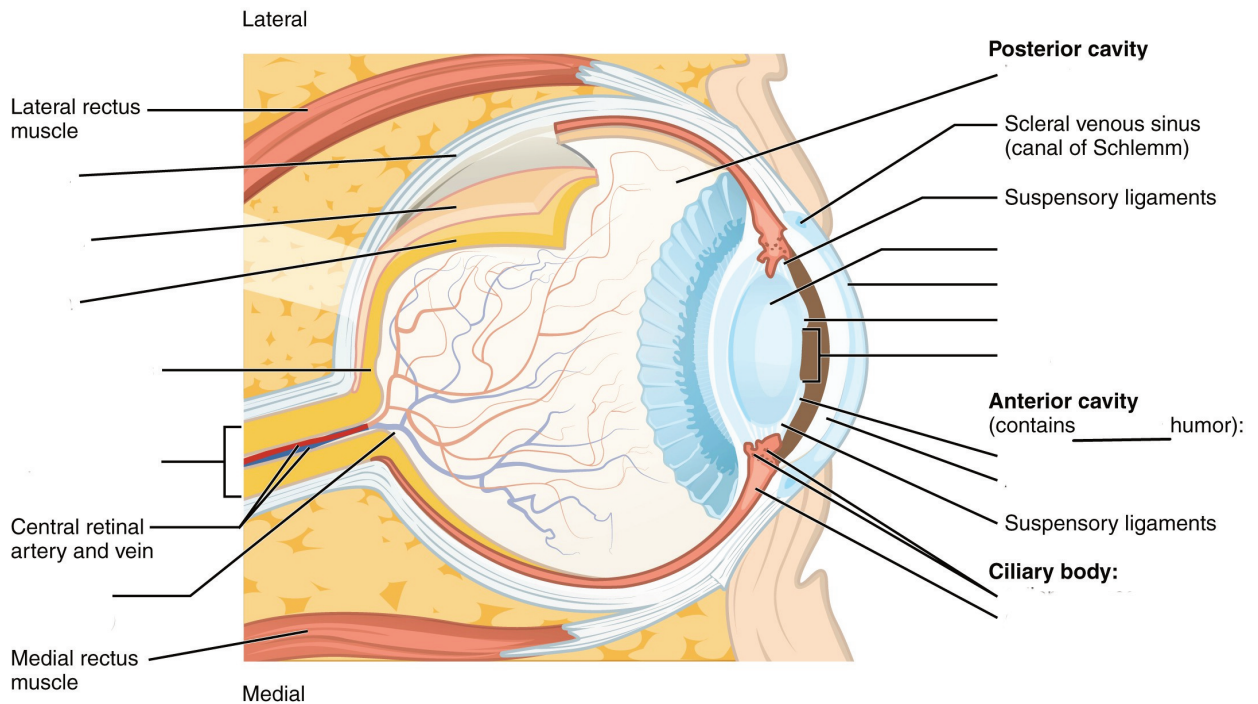


Lateral view of the right eye



Anterior view of the right eye

**Label the structures and regions of the eye. (0.5 points)**



# 14. Lab Activities

A list of words is provided below that you are expected to identify, learn, and label on the models provided. Note that not all models will have some of the organs/structures, so be sure to find them on an alternate model. You must use all the words provided. Using the colored tape provided, write the number that corresponds to the organ/structure and place them on your model. When complete, notify your TA so they may check your work.

For each additional station, directions will be provided for the activity.

## Station One: Are You a Super Taster?

- For this exercise, it is recommended that you use dark food coloring for maximum effect
- Using the spoon, use a small amount of the food coloring or powder on the tongue. Do NOT use a full spoon or pour a mound on the subject's tongue!
- Paper squares will be provided which have a 1cm in diameter hole in them. Have the volunteer place the paper on their tongue and make sure that the hole aligns with the area highlighted by the food coloring.
- Use a camera phone (or other devices), to take a closeup still photo of the circle.
- The papilla will contrast against the color of the food coloring. Count the number of the papilla in the circle and record it below.
- If there are between 0 and 5 papilla, then the subject is a "hypo-taster". A hypo-taster is more tolerant of bitter tastes. If there are between 5 and 15 papillae, then the subject has average tasting capabilities. If there are more than 15 papillae found in this 1cm area, then the subject is a "hyper-taster". A hyper-taster is more sensitive to bitter tastes. Determine whether the subject is a hypo-taster, average taster or hyper-taster and record it below next to "Tasting abilities".
- Repeat with another group member.

Note: if your lab does not permit the use of food items in the lab, leave the room before conducting this experiment.

Subject #1: \_\_\_\_\_

Number of taste buds: \_\_\_\_\_

Tasting abilities: \_\_\_\_\_

Subject #2: \_\_\_\_\_

Number of taste buds: \_\_\_\_\_

Tasting abilities: \_\_\_\_\_

## Station Two: Taste and Smell

Label the models of this station with the number that corresponds to the appropriate structure of the peripheral nervous system using the colored tape. When you are finished, ask your TA to check your labeling. Before leaving the station, remove all the labels you have placed on the model.

Note: For the following structures, be able to differentiate between left and right halves when applicable.

### Tongue and Associated Structures

#1 lingual tonsils	#4 fungiform papillae	#7 circumvallate papillae
#2 palatine tonsils	#5 filiform papillae	#8 taste bud
#3 lingual papillae	#6 foliate papillae	#9 taste pore

### Taste Pathway

#10 facial nerve (CN VII)	#12 vagus nerve (CN X)	#14 primary gustatory area
#11 glossopharyngeal nerve (CN IX)	#13 thalamus	

### Nose

#15 superior nasal conchae	#19 middle nasal meatus	#23 cribriform plate of ethmoid bone
#16 middle nasal conchae	#20 inferior nasal meatus	#24 olfactory foramina
#17 inferior nasal conchae	#21 olfactory epithelium	
#18 superior nasal meatus	#22 olfactory glands	

### Olfactory Pathway

#25 olfactory epithelium	#27 olfactory nerve (CN I)	#29 olfactory tract
#26 olfactory receptors	#28 olfactory bulb	#30 primary olfactory area of the cerebral cortex

## Station Three: Hearing

Label the models of this station with the number that corresponds to the appropriate structure of the peripheral nervous system using the colored tape. When you are finished, ask your TA to check your labeling. Before leaving the station, remove all the labels you have placed on the model.

Note: For the following structures, be able to differentiate between left and right halves when applicable.

### Outer Ear

#1 auricle (pinna)	#3 lobule	#5 external auditory canal	#7 tympanic membrane
#2 helix	#4 external auditory meatus	#6 ceruminous glands	

### Middle Ear

#8 auditory ossicles	#10 incus	#12 Eustachian tube	#14 round window
#9 malleus	#11 stapes	#13 oval window	

### Inner Ear


#15 bony labyrinth	#18 cochlea	#21 utricle
#16 semicircular canals	#19 membranous labyrinth	#22 saccule
#17 vestibule	#20 semicircular canals	#23 organ of corti

### Auditory Pathway


#24 vestibulocochlear nerve (CN VIII)	#25 primary auditory area of the cerebral cortex
---------------------------------------	--

## Station Four: Histology

Sketch the slides available for today's lab and specify the magnitude at which you are observing/ sketching. Be sure to identify and label your sketch with the corresponding structures listed beneath each slide.



**Retina**  
Pigmented layer, Neural layer



**Tongue**  
Fungiform papillae, Filiform papillae

---

## Station Five: Eye Dissection

- First, determine the external surface features and structures of the cow eye. You should be able to identify: the *sclera*, or the white of the eye, the *cornea*, which is the semi-transparent layer covering the front part of the eye, and the *optic nerve* which protrudes from the posterior portion of the eye. There may be periorbital fat or external muscles still attached to the eye.
- Use dissecting scissors to cut away any fat or muscle attached to the eye.
- Using a scalpel, cut through the sclera along the frontal plane. When you remove the top of the eye, the part containing the cornea, what will remain is the lens sitting on top of a jelly-like mass known as the *vitreous humor*, it maintains the shape of the eye.
- Remove the lens and note how its composition is hard and similar to that of a marble. Next, remove the vitreous humor and take note of the shiny, blue layer along the inside of the back half of the eye, this is the retina.
- Moving back to the front half of the eye, depending on your initial halving of the eye, you can remove the iris from the cornea. Now lay out the contents of the cow eye from the most anterior through to the posterior portion of the eye and examine the structures.

\*If you are the last table to use this station, be sure to clean off the dissection kits in the lab sink.

## Station Six: Vision

Label the models of this station with the number that corresponds to the appropriate structure of the peripheral nervous system using the colored tape. When you are finished, ask your TA to check your labeling. Before leaving the station, remove all the labels you have placed on the model.

### Fibrous Tunic

#1 sclera	#2 cornea
-----------	-----------

### Vascular Tunic

#3 iris	#5 lens	#7 ciliary body
#4 pupil	#6 choroid	

### Neural Tunic

#8 retina	#12 pigmented layer	#16 bipolar cells
#9 optic disc	#13 neural layer	#17 horizontal cells
#10 macula lutea	#14 rods	#18 ganglion cells
#11 fovea centralis	#15 cones	

### Visual Pathway

#20 optic nerve	#22 optic tract
#21 optic chiasm	#23 primary visual area of the cerebral cortex

### Eye Interior

#24 anterior chamber	#26 posterior chamber
#25 aqueous humor	#27 vitreous humor (body)



## Muscles of the Eye

#28 levator palpebrae superioris	#30 inferior rectus	#32 medial rectus	#34 inferior oblique
#29 superior rectus	#31 lateral rectus	#33 superior oblique	

## Lacrimal Apparatus

#35 lacrimal gland	#36 superior lacrimal canaliculi	#38 lacrimal sac
#36 lacrimal puncta	#37 inferior lacrimal canaliculi	#39 nasolacrimal duct

## Conjunctiva

#40 palpebral conjunctiva	#41 bulbar conjunctiva
---------------------------	------------------------

# 15. Post-Lab 5 Questions

**(3 point)**

Last Name: \_\_\_\_\_ First Name: \_\_\_\_\_

1. List the structures in each layer of the eye. (0.5 points)
  - Fibrous tunic:
  - Vascular tunic:
  - Neural tunic:
  
2. What is the olfactory pathway, starting from odorant to the primary olfactory area? How does this pathway differ from other sensory pathways? (0.5 points)

3. Match the following structures with their corresponding descriptions. (1 point)

Name of Structure	Descriptions	No. of Structure
1. Optic disc	an area where odorants bind to receptors to produce a sensation that will be perceived as smell	
2. Round window	contains approximately 100 taste buds	
3. Fungiform papillae	location of no visual activity, known as the “blind spot”	
4. Vitreous humor	contains the organs that sense dynamic equilibrium	
5. Olfactory epithelium	contains the organs that sense static equilibrium	
6. Filiform papillae	jelly-like mass that provides stability and structure to the eye	
7. Semicircular canals	provide friction, contains no taste buds	
8. Retina	contains approximately 5 taste buds	
9. Auditory ossicles (malleus, incus, and stapes)	the smallest bones in the body; transmits vibrations that are key to hearing	
10. Circumvallate papillae	possess the following layers to allow for the transmission of stimuli to the optic nerve; pigmented layer, photoreceptor layer, outer synaptic layer, bipolar cell layer, inner synaptic layer, ganglion layer	
11. Vestibule	membrane between the inner and middle ear to allow for pressure changes to equilibrate	

4. Describe the path of sound traveling through the ear to CN (VIII). (list structures)(0.5 points)

5. Describe the function of the following muscles. Do they assist in intorsion, extorsion, abduction, adduction, elevation and/or depression of the eye? (0.5 points)

1. Superior Rectus-
2. Inferior Rectus-
3. Medial Rectus-
4. Lateral Rectus-
5. Superior Oblique-
6. Inferior Oblique-



PART VI

## LAB 6: RESPIRATORY SYSTEM



# 16. Lab 6: Respiratory System

## Measurable Outcomes

- Understand and identify the anatomical structures of the respiratory system on available models.
- Deduce the pathway of air through the respiratory system.
- Determine the pathway of pulmonary circulation.
- Identify the various muscles involved in respiration.
- Recognize the hallmarks of lung histology.
- Demonstrate an adequate understand of the material in this section.

## Background

The respiratory system is responsible for the gas exchange of oxygen and carbon dioxide. The main specialized organs of this process are the lungs which house clusters of sac-like structures known as *alveoli*. There are from 480 to 790 million alveoli which increase the efficiency of gas exchange by increasing surface area to around 118m<sup>2</sup> in men and 91m<sup>2</sup> in women. The respiratory system consists of the *nasal cavity*, *pharynx*, *larynx*, *trachea*, *lungs*, *bronchi*, *bronchioles*, and *alveoli*, along with their accessory structures. These structures are divided into the *upper and lower respiratory systems*, with the lower portion beginning at the larynx. The primary function of this system is to exchange oxygen and carbon dioxide between the body and the environment. Functionally, the respiratory system can be divided into the *conducting zone*, terminating at the terminal bronchioles; then air flows into the *respiratory zone*, where the actual gas exchange occurs.

Though we view each system individually in this lab, it is important to keep in mind that all organ systems overlap and work together in such a way that scientist are constantly discovering new connections. One such example is the nose. Not only is it the primary entrance and exit for respiration, but it also contains the olfactory epithelium, the primary structure of one of the special senses, olfaction. Likewise, the pharynx is a structure shared by both the respiratory and digestion systems.

Although both lungs functionally participate in respiration, they differ physically in various ways. The right lung is shorter and wider than the left lung, and the left lung occupies a smaller volume than the right. Another distinction between the two lungs is that the left lung contains the *cardiac notch*, which makes space for the heart. Furthermore, whereas the right lung has three lobes, the left lung has only two.

Though not visible on every model, each lung is surrounded by the pleura, which consists of two layers called the visceral and parietal pleurae. They are important because they lubricate the lungs and reduce friction during inhalation and exhalation.

**Vocabulary for Respiratory System can be found on page(s) 169.**

# 17. Pre-Lab 6

(5 points)

Last Name: \_\_\_\_\_ First Name: \_\_\_\_\_

## Instructions:

Fill in the table below with the appropriate terms. For the remaining exercises, label the designated structures.  
(1 point)

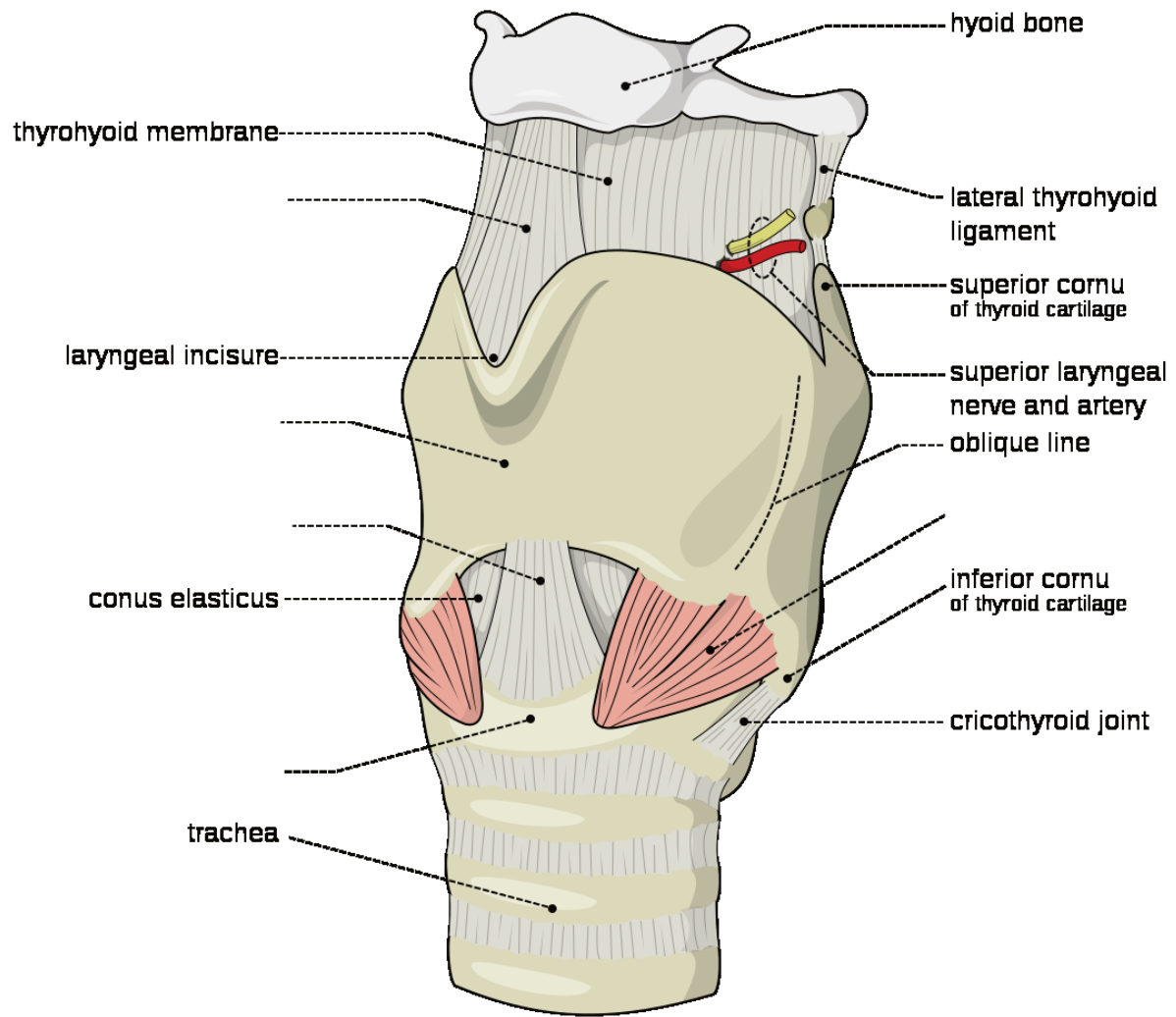
Name of a structure	is	directional term	to	Name of the second structure
Epiglottis	is	Superior	to	Vocal cords
Hyoid bone	is	Anterior	to	
	is	Inferior	to	Cricoid cartilage
Carina	is	Medial	to	
	is	Directly Superficial	to	Conus elasticus

List two structures of the respiratory zone? (0.5 points)

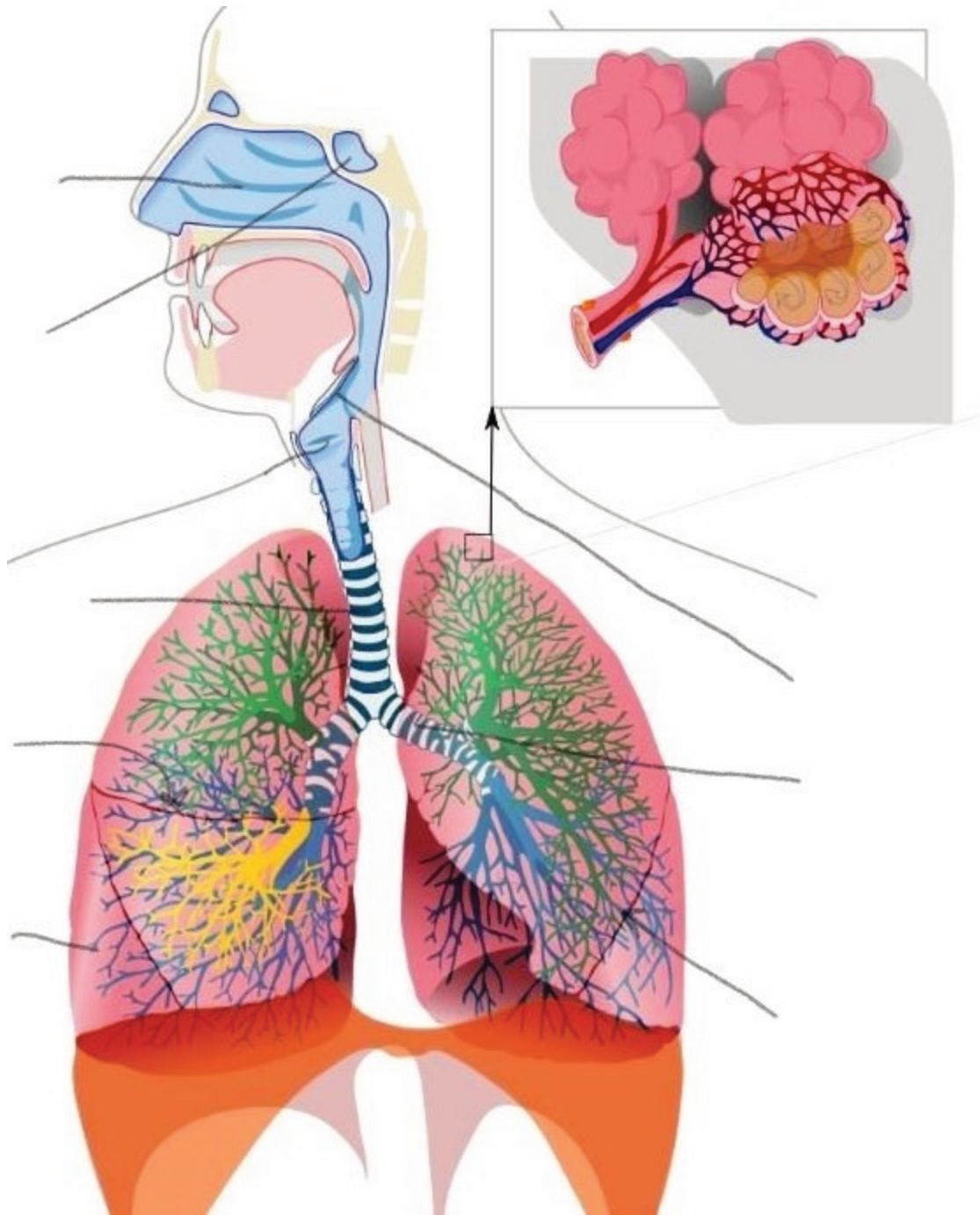
List two structures of the conducting zone? (0.5 points)

Label the following structures of the larynx. (1 point)

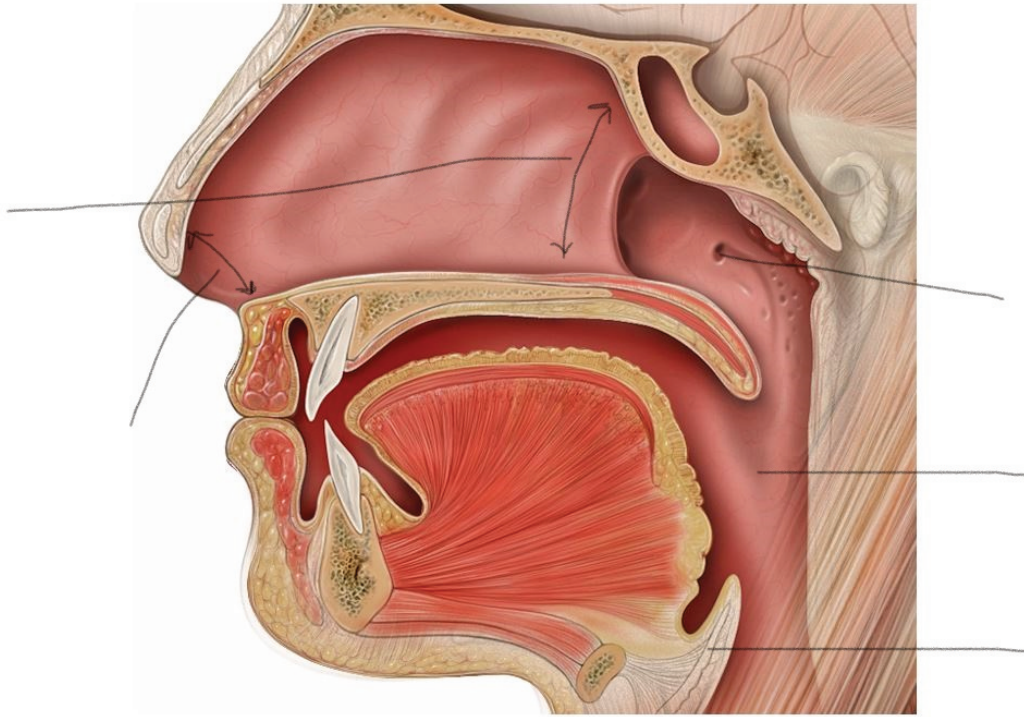




Label the following structures of the respiratory system. (1 point)



Label the following structures in the sagittal view of the upper respiratory system. (1 point)



# 18. Lab Activities

A list of words is provided below that you are expected to learn and label on the models provided. Note that not all models will have some of the organs/structures, so be sure to find them on an alternate model. You must use all the words provided. Using the colored tape provided, write the number that corresponds to the organ/structure and place it on your model. When complete, notify your TA so they may check your work.

For each additional station, directions will be provided for the activity.

## Station One: Upper Respiratory

Label the models of this station with the number that corresponds to the appropriate structure of the peripheral nervous system using the colored tape. When you are finished, ask your TA to check your labeling. Before leaving the station, remove all the labels you have placed on the model.

#1 nose	#6 septal nasal cartilage	#12 nasal conchae*	#16 laryngopharynx	#21 soft palate
#2 root	#7 major alar cartilages	#12 nasal meatuses*	#17 lingual tonsils	#22 uvula
#3 bridge	#8 minor cartilages	#13 pharynx	#18 palatine tonsils	
#4 apex	#9 external naris	#14 nasopharynx	#19 pharyngeal tonsil (adenoid)	
#5 lateral nasal cartilages	#10 nasal cavity	#15 oropharynx	#20 hard palate	

\*There are Superior, Middle, and Inferior parts to these structures.

## Station Two: Lower Respiratory

Label the models of this station with the number that corresponds to the appropriate structure of the peripheral nervous system using the colored tape. When you are finished, ask your TA to check your labeling. Before leaving the station, remove all the labels you have placed on the model.

#1 larynx	#8 corniculate cartilages	#15 esophagus	#22 alveolar sacs	#29 middle lobe
#2 epiglottis	#9 cuneiform cartilage	#16 carina	#23 alveoli	#30 cardiac notch
#3 vestibular folds	#10 cricothyroid ligament	#17 primary (main) bronchi	#24 L/R lungs	#31 horizontal fissure
#4 vocal folds	#11 cricoid cartilage	#18 secondary (lobar) bronchi	#25 apex of lung	#32 oblique fissure
#5 thyrohyoid membrane	#12 cricotracheal ligament	#19 tertiary (segmental) bronchi	#26 base of lung	#33 hilum
#6 thyroid cartilage	#13 tracheal cartilages	#20 respiratory bronchioles	#27 superior lobe	
#7 arytenoid cartilages	#14 trachea	#21 alveolar ducts	#28 inferior lobe	

## Station Three: Muscles of Respiration

Label the models of this station with the number that corresponds to the appropriate structure of the peripheral nervous system using the colored tape. When you are finished, ask your TA to check your labeling. Before leaving the station, remove all the labels you have placed on the model.

### Muscles of Inspiration

#1 diaphragm	#2 external intercostals	#3 scalenes	#4 sternocleidomastoid
--------------	--------------------------	-------------	------------------------

\*Make note of which muscles are the primary muscles of inhalation, and which are the accessory muscles.


### Muscles of Exhalation

#5 internal intercostals	#6 external oblique	#7 internal oblique	#8 transverse abdominis	#9 rectus abdominis
--------------------------	---------------------	---------------------	-------------------------	---------------------



## Station Four: Histology

Sketch the slides available for today's lab and specify the magnitude at which you are observing/ sketching. Be sure to identify and label your sketch with the corresponding structures listed beneath each slide.



### Lung

Terminal bronchioles, Respiratory bronchioles, Alveolar ducts, Alveolar sacs, Alveoli

## Station Five: Lung Dissection

- First, identify the trachea and observe if it is flexible or stiff, does it collapse in on itself? Note the ringed structures along the trachea that support it and allow it to stay open. Identify any other structures along the outside of the lungs and trachea such as the pleural membrane or larynx if still attached.
- Lay the lungs where they both lay flat on the table. Using the dissecting scissors make a cut along the frontal plane beginning at the top of the trachea and working your way down to the branching of the primary bronchi.
- Cut along one of the bronchi, along the corresponding lung until you make a complete frontal plane cut.
- Use the pins provided and label as many structures as you can identify. Your TA will come around and ask you to identify the pins you have placed.
- Before leaving the station, remove all the pins you have placed.

\*If you are the last table to use this station, be sure to clean off the dissection kits in the lab's sink.

## Station Six: Flow of Oxygen and Pulmonary Circulation

As a group, determine the path that oxygen travels starting from the nostrils to the alveoli. Be sure to identify where along that path each of the structures on the vocabulary list is located.

As a group, determine the route of pulmonary circulation. Be mindful of the fact that several structures are directly connected to the heart. Label the models/posters of this station with the # that corresponds to the appropriate vessels involved in pulmonary circulation using the colored tape. When you have finished, have your TA check your labeling. Before leaving the station, remove all of the labels you have placed on the models/posters.

#1 pulmonary trunk	#2 pulmonary arteries	#3 pulmonary capillaries	#4 pulmonary veins
--------------------	-----------------------	--------------------------	--------------------



# 19. Post-Lab 6 Questions

(2 points)

Last Name: \_\_\_\_\_ First Name: \_\_\_\_\_

1) Write a **C** if the listed structure is part of the conducting zone and an **R** if it is part of the respiratory zone. Also, label whether the structure is part of the upper respiratory (**U**) or lower respiratory system (**L**). (0.5 point)

Example: Larynx   C  ,   L  

Alveoli \_\_\_\_\_

Trachea \_\_\_\_\_

Nasal cavity \_\_\_\_\_

Bronchi \_\_\_\_\_

Respiratory bronchioles \_\_\_\_\_

Pharynx \_\_\_\_\_

Alveolar ducts \_\_\_\_\_

Terminal bronchioles \_\_\_\_\_

2) Write the route that oxygen takes from when you inhale to the point of gas exchange with carbon dioxide. (0.5 point)

3) Give two unique characteristics of the pulmonary artery and vein. (0.5 point)

4) Describe the route of pulmonary circulation. (0.5 point)



PART VII

## LAB 7: THE CARDIOVASCULAR SYSTEM



# 20. Lab 7: The Cardiovascular system

## Measurable Outcomes

- Visually identify major components, vessels, and structures of a dissected heart.
- Determine the anatomical structures of the heart on available models.
- Determine the pathway of blood flow through the heart.
- List and accurately classify the distinct types of blood cells from histological slides.
- Recognize the features of cardiac tissue under a microscope.
- Identify the major blood vessels required for this lab.
- Distinguish between arterial and venous flow.

## Background

The cardiovascular system is responsible for the circulation of blood and transport of nutrients. Large multicellular organisms developed such a system as a means of actively transporting nutrients to the cells of the body. The *heart* is the organ of focus in this lab. It is divided into four distinct chambers, which in concert work to circulate blood. When the heart beats, it pumps blood into two different circuits: pulmonary and systemic. Pulmonary circulation carries blood from the right side of the heart to the alveoli of the lungs and back to the left side of the heart, while the systemic circulation carries blood from the left side of the heart to all the organs and tissues of the body, then back to the right side of the heart. If it were possible to stretch out all of the blood vessels in the body, they would measure 60,000 to 100,000 miles, enough to circle the earth roughly four times. The heart is an incredible organ capable, on average, of circulating roughly 2,000 gallons worth of blood each day. Furthermore, the heart is one of the few organs capable of operating entirely apart from the central nervous system which makes it one of the hardest working organs.

Blood is classified as liquid connective tissue and is vital in its roles of transportation, regulation, and protection. It is made of distinct types of cells, mostly derived from bone marrow, and helps maintain homeostasis. Plasma and cellular elements are the two main components of blood, where plasma makes up 55% of blood and cellular elements make up 45%. Plasma is mostly water but contains proteins and other solutes as well. The vast majority of cell elements are *erythrocytes* with less than 1% comprising of *leukocytes* and *platelets*.

In this lab we will focus on the major blood vessels of the cardiovascular system. Arteries are blood vessels that always carry blood away from the heart; the blood they carry is oxygenated (exception: *pulmonary arteries*). They generally have thicker walls than veins, the other major blood vessels in the cardiovascular system. Veins carry blood toward the heart and carry deoxygenated blood (exception: *pulmonary veins*). Both vessel types are formed by the tunica intima, tunica media, and tunica adventitia.

**Vocabulary for the Cardiovascular System can be found on page(s) 163-165.**

## 2I. Pre-lab 7

(5 points)

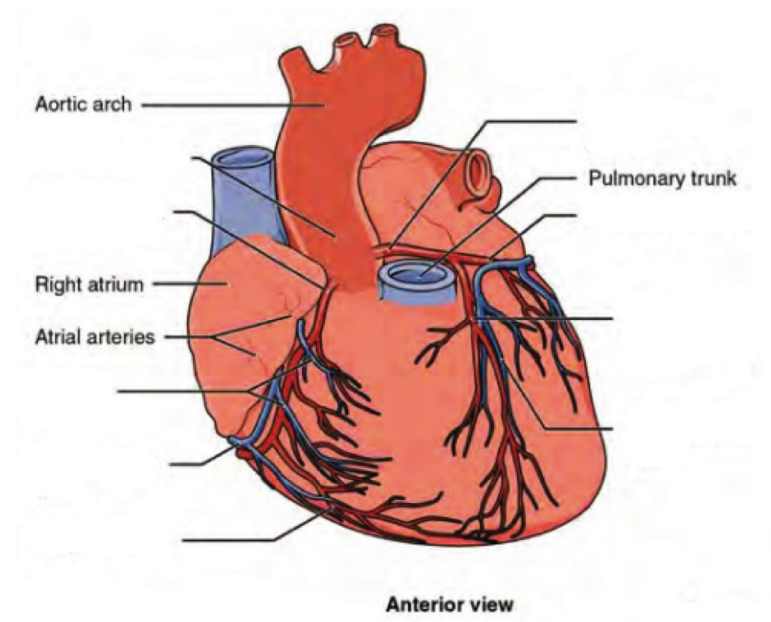
Last Name: \_\_\_\_\_ First Name: \_\_\_\_\_

### Instructions:

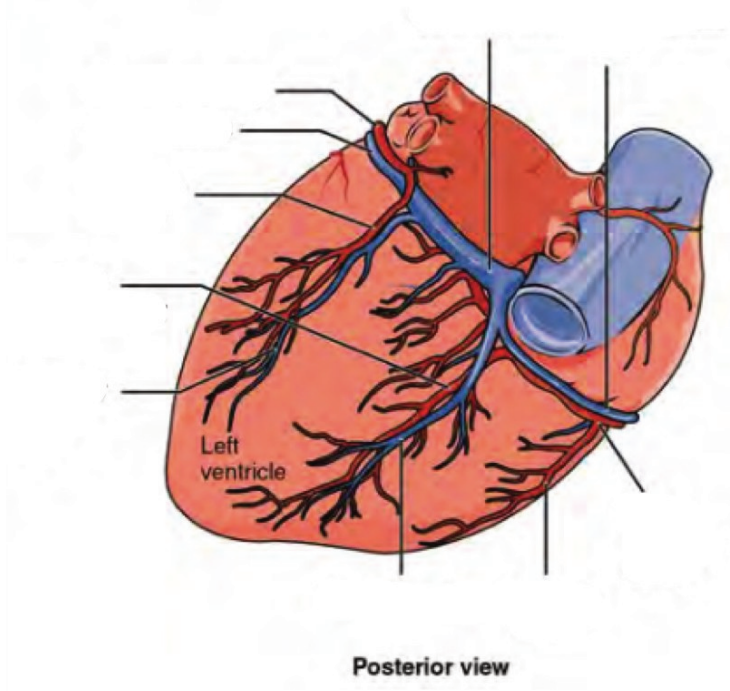
Fill in the table below with the appropriate terms. For the remaining exercises, label the structures accordingly.  
(1 point)

Name of a structure	is	directional term	to	Name of the second structure
pulmonary vein	is	proximal	to	right ventricle
auricle	is	superior	to	heart's base
anterior interventricular sulcus	is	inferior	to	heart's base
heart	is	anterior	to	ascending aorta
	is	distal	to	ascending aorta
	is	medial	to	
	is	lateral	to	left ventricle

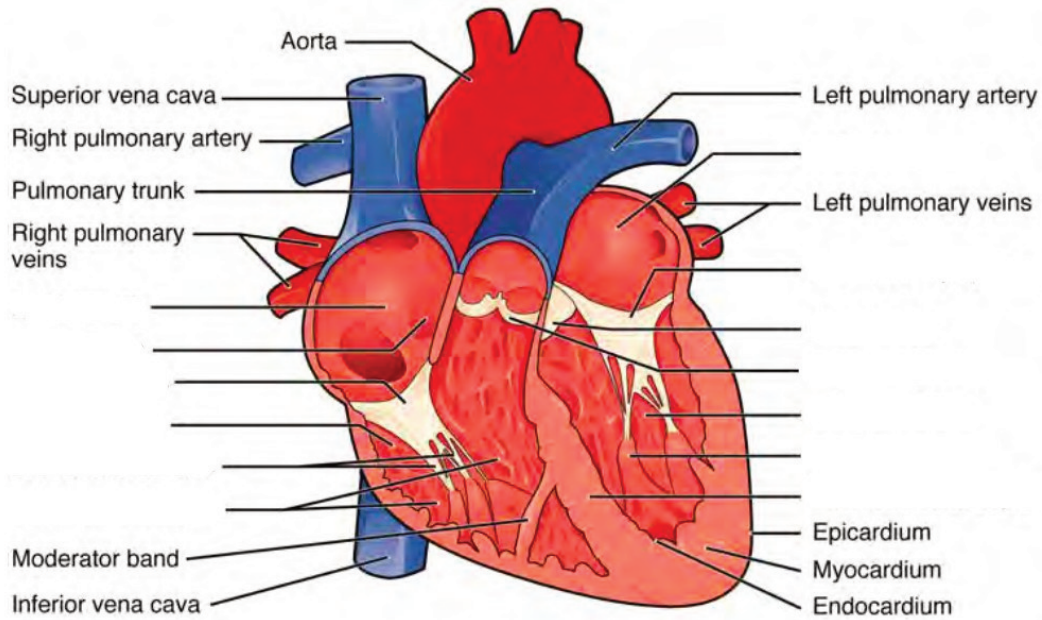
Label the prominent coronary surface vessels. (0.5 points)



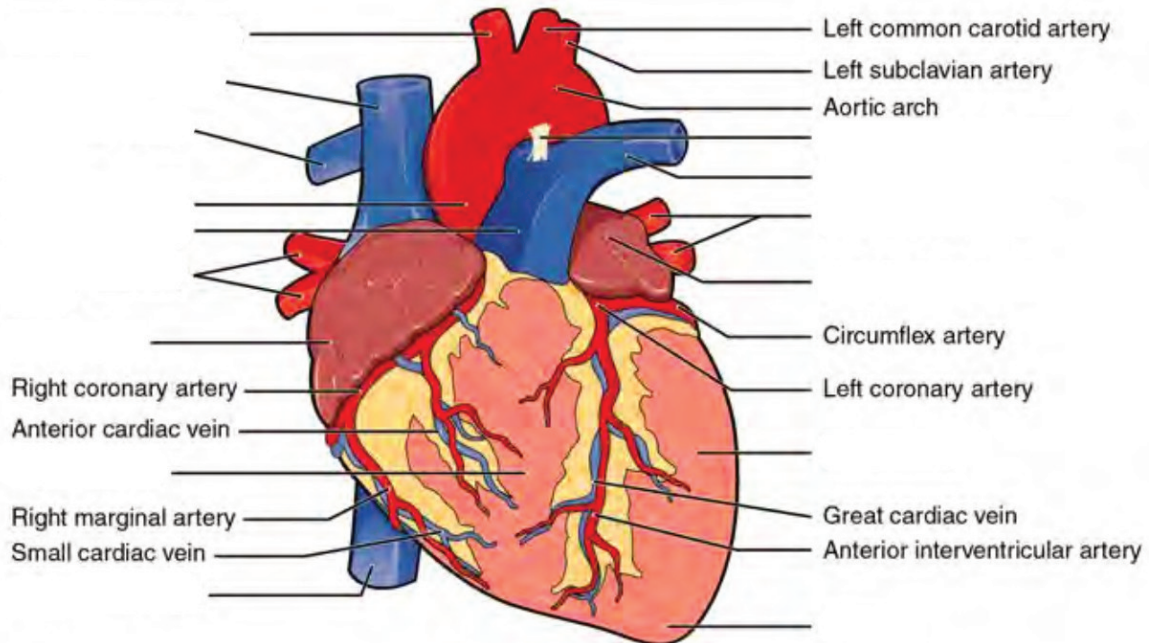
Label the prominent coronary surface vessels. (0.5 points)



Label the internal formations of the heart. (1 point)



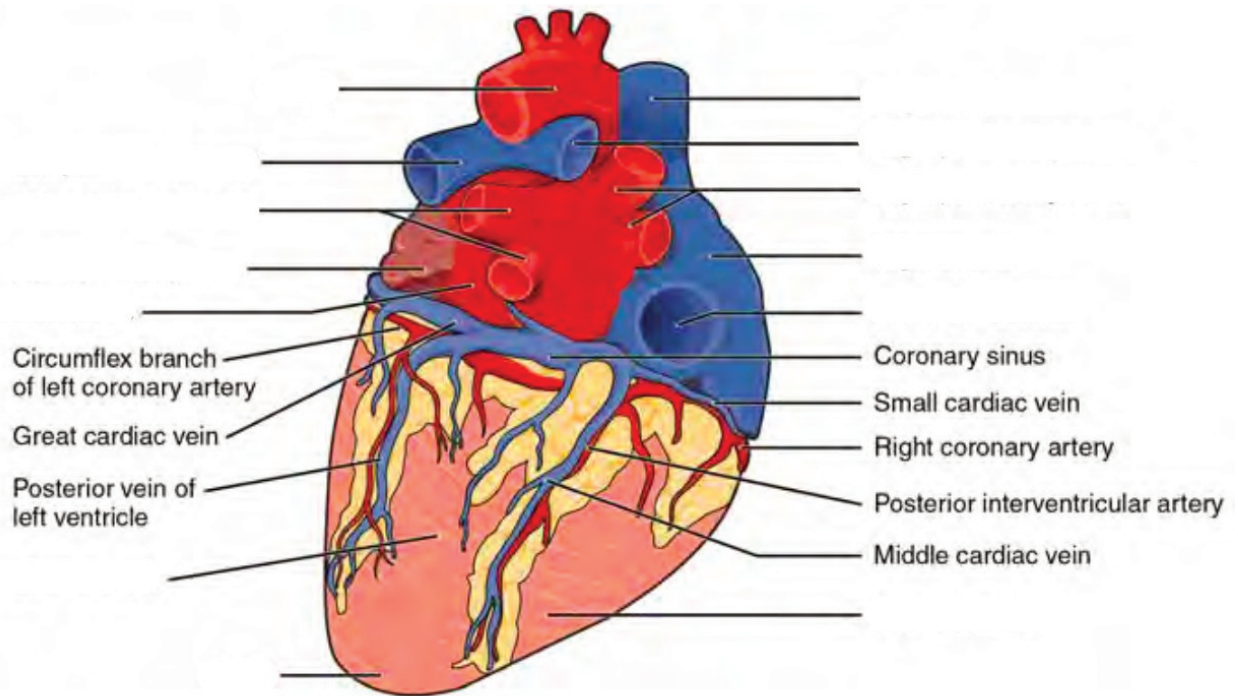
Label the surface features of the anterior aspect of the heart. (0.5 points)



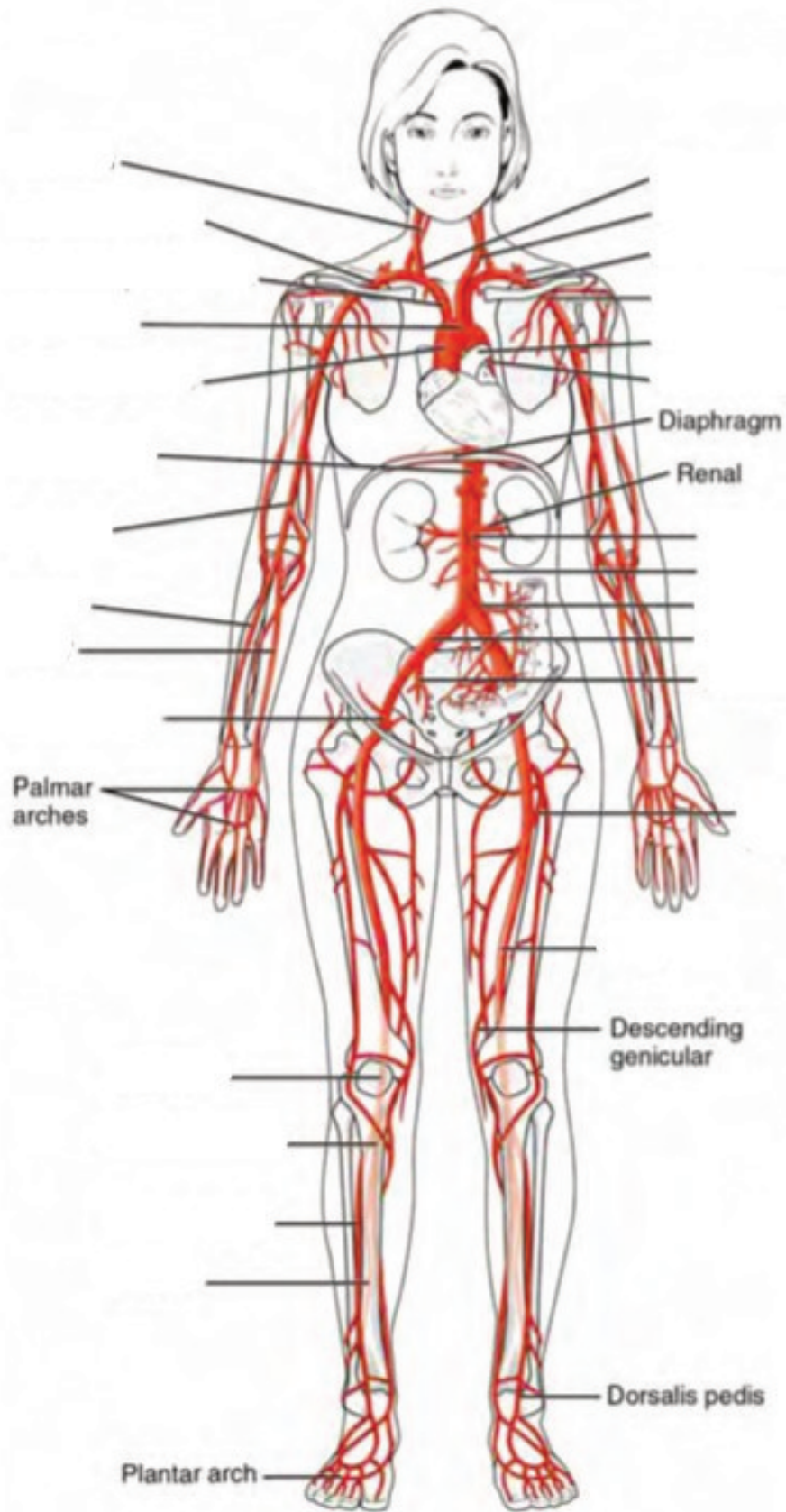




Label the surface features on the posterior aspect of the heart. (0.5 points)

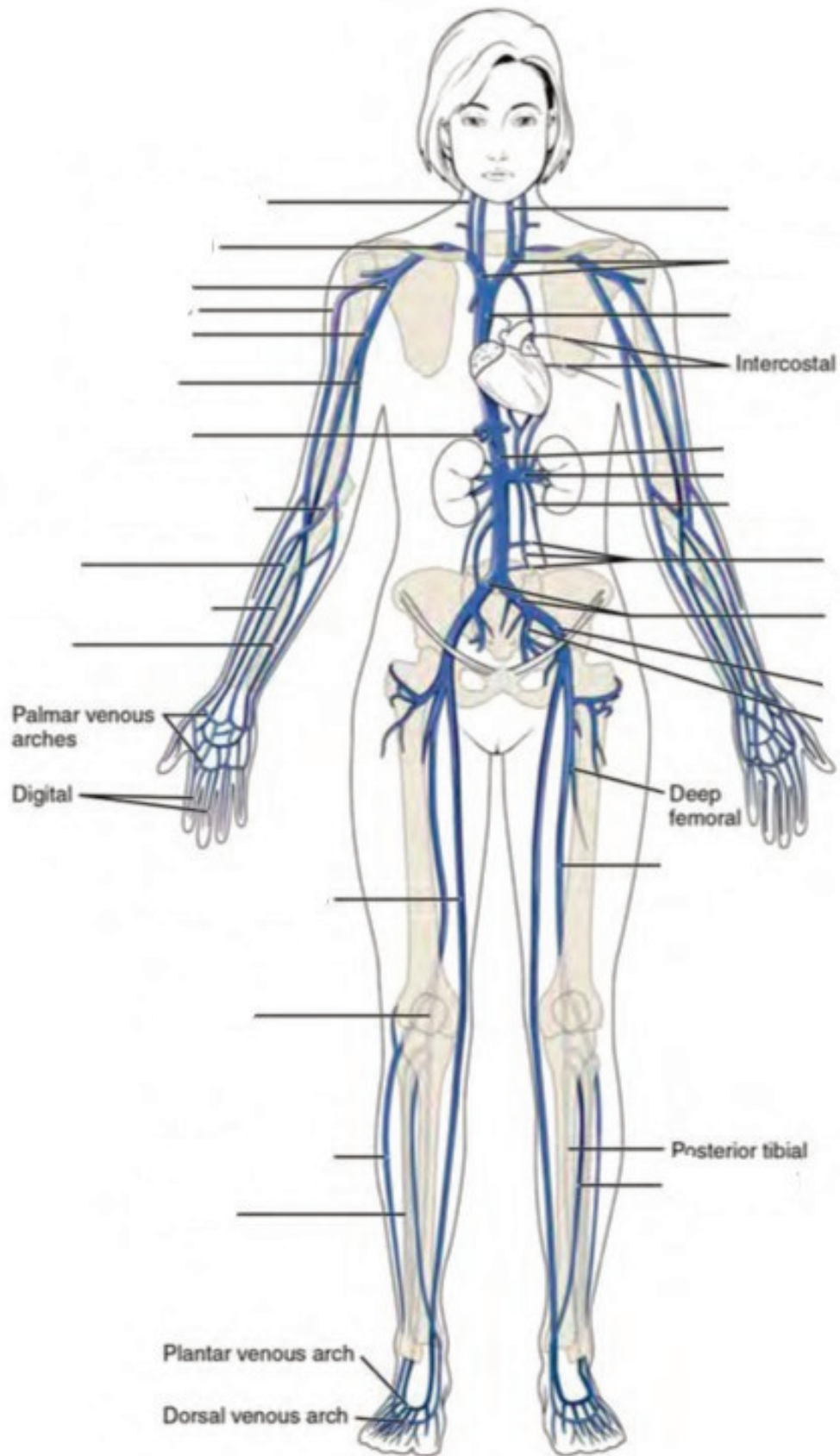


**Label the major systemic arteries of the body. (0.5 points)**





**Label the major systemic veins of the body. (0.5 points)**







## 22. Lab Activities

A list of words is provided below that you are expected to identify, learn, and label on the models provided. Note that not all models will have some of the organs/structures, so be sure to find them on an alternate model. You must use all the words provided. Using the colored tape provided, write the number that corresponds to the organ/structure and place them on your model. When complete, notify your TA so they may check your work.

For each additional station, directions will be provided for the activity.

### Station One: Heart

Label the models of this station with the number that corresponds to the appropriate structure of the peripheral nervous system using the colored tape. When you are finished, ask your TA to check your labeling. Before leaving the station, remove all the labels you have placed on the model.

Note: For the following structures, be able to differentiate between left and right halves when applicable.

#### Orientation

#1 apex	#2 base
---------	---------

#### Layers

#3 pericardium	#4 epicardium	#5 endocardium	#6 myocardium
----------------	---------------	----------------	---------------

#### Surface Features

#7 superior vena cava	#10 left pulmonary artery	#13 ascending aorta	#16 posterior interventricular sulcus
#8 right pulmonary artery	#11 coronary sulcus	#14 descending aorta	#17 epicardial fat
#9 inferior vena cava	#12 arch of aorta	#15 anterior interventricular sulcus	#18 auricles

## Internal Structures

#19 papillary muscles	#23 tricuspid valve	#27 right atrium	#31 left ventricle
#20 pectinate muscles	#24 bicuspid valve	#28 left atrium	#32 interventricular septum
#21 chordae tendineae	#25 pulmonary valve	#29 interatrial septum	#33 right bundle branches
#22 trabeculae carneae	#26 aortic valve	#30 right ventricle	#34 left bundle branches

## Coronary Circulation – Arteries

#35 coronary arteries	#37 posterior interventricular branch	#39 circumflex branch	#41 branch of left coronary artery
#36 marginal branches	#38 right pulmonary artery	#40 anterior interventricular branch	#42 middle cardiac

## Coronary Circulation – Veins

#43 coronary sinus	#45 great cardiac	#47 left pulmonary
#44 anterior cardiac	#46 small cardiac	#48 right pulmonary

## Station Two: Major Upper Body Vessels

Label the models of this station with the number that corresponds to the appropriate structure of the peripheral nervous system using the colored tape. When you are finished, ask your TA to check your labeling. Before leaving the station, remove all the labels you have placed on the model.

Note: For the following structures, be able to differentiate between left and right halves when applicable.

## Arterial Circulation

#1 brachiocephalic trunk	#6 vertebral arteries	#11 anterior cerebral artery	#16 thoracic aorta
#2 common carotid arteries	#7 basilar artery	#12 anterior communicating artery	#17 abdominal aorta
#3 internal carotid arteries	#8 posterior cerebral artery	#13 axillary arteries	
#4 external carotid arteries	#9 posterior communicating artery	#14 radial arteries	
#5 subclavian arteries	#10 middle cerebral artery	#15 ulnar arteries	

## Venous Circulation

#18 brachiocephalic veins	#22 axillary veins	#26 medial cubital veins	#30 azygos vein
#19 internal jugular veins	#23 brachial veins	#27 radial veins	#31 hemiazygos vein
#20 subclavian veins	#24 cephalic veins	#28 ulnar veins	#32 accessory hemiazygos vein
#21 external jugular veins	#25 basilic veins	#29 median antebrachial veins	

## Station Three: Major Lower Body Vessels

Label the models of this station with the number that corresponds to the appropriate structure of the peripheral nervous system using the colored tape. When you are finished, ask your TA to check your labeling. Before leaving the station, remove all the labels you have placed on the model.

Note: For the following structures, be able to differentiate between left and right halves when applicable.

## Arterial Circulation

#1 suprarenal arteries	#6 celiac trunk	#11 external iliac arteries	#16 anterior tibial arteries
#2 renal arteries	#7 common hepatic artery	#12 internal iliac arteries	#17 posterior tibial arteries
#3 gonadal arteries	#8 splenic artery	#13 femoral arteries	#18 fibular arteries
#4 inferior mesenteric artery	#9 lumbar arteries	#14 deep femoral arteries	
#5 superior mesenteric artery	#10 common iliac arteries	#15 popliteal arteries	


## Venous Circulation

#19 ascending lumbar veins	#24 hepatic portal veins	#30 common iliac veins	#35 popliteal veins
#20 gonadal veins	#25 inferior mesenteric vein	#31 internal iliac veins	#36 small saphenous veins
#21 renal veins	#26 splenic vein	#32 external iliac veins	#37 anterior tibial veins
#22 suprarenal veins	#27 superior mesenteric vein	#33 femoral veins	#38 fibular veins
#23 hepatic veins	#28 inferior phrenic vein	#34 great saphenous veins	


## Station Four: Histology & Differential Blood Count

Sketch the slides available for today's lab and specify the magnitude at which you are observing/ sketching. Be sure to identify and label your sketch with the corresponding structures listed beneath each slide.

### Blood Vessels




**Vein**




**Artery**

---

# Blood Components




**Leukocyte**




**Thrombocyte**

---




**Erythrocyte**


**Leukocytes**




**Basophil**




**Eosinophil**



**Neutrophil**




**Lymphocyte**



**Monocyte**

**Cardiac**



**Cardiac muscle**

## **Differential Blood count**

- Place the blood smear slide under the microscope and focus it to 70x magnification.
- Once you have isolated a portion of the smear, count the number of each type of blood cell. Record the

numbers below

Note: Platelets may not be visible at this magnification

- RBC: \_\_\_\_\_ Neutrophils: \_\_\_\_\_
- Basophils: \_\_\_\_\_ Eosinophils: \_\_\_\_\_
- Monocytes: \_\_\_\_\_ Lymphocytes: \_\_\_\_\_

### Station Five: Heart Dissection

- Observe and identify all the surface anatomy of the heart.
- Orientate the heart so that the ventral side is facing you. The base of the heart should be positioned right side up for dissection.
- Using your fingers or a probe, find the following at the base of the heart: pulmonary vein, aorta, vena cava, and pulmonary trunk.
- Using the superior vena cava and pulmonary vein as guides, make a coronal incision using the scapula.
- Observe and place pins on the following structures: R/L ventricles, R/L atriums, interventricular septum, the valves, tissue layers (cardiac muscle, papillary muscles). Your TA will come around and ask your group to identify the pins you have placed.
- Before leaving the station, remove all the pins you have placed.

\*If you are the last table to use this station, be sure to clean off the dissection kits in the lab's sink.

### Station Six: Flow of Blood and Blood Typing

As a group, determine the flow of blood through the various structures and vessels of the heart. Be sure to identify where along that path each of the structures on the vocabulary list is located. Use the rest of this page to draw out the pathway.

As a group, determine the different blood type in this station. Follow the procedure below in order to do so.

- Obtain a blood-sampling tray and place two drops of the synthetic blood into the wells.
- Place two drops of the Anti-a “antibody” into the well labeled a. Using a toothpick, mix well and allow to sit undisturbed for one minute. Note any clotting that may occur.
- Place two drops of the Anti-B “antibody” into the well labeled B. Using a toothpick, mix well and allow to sit undisturbed for one minute. Note any clotting that may occur.
- Place two drops of the Anti-Rh “antibody” into the corresponding well. With a toothpick, mix well and allow to sit undisturbed for one minute. Note any clotting that may occur.
- Using your knowledge of the interaction between blood antigens and their corresponding antibodies, determine the blood type. Remember that if an antibody finds its targeted antigens, it causes blood



coagulation. If no coagulation occurs, this means that the blood does not contain any of the antigens.

## 23. Post-Lab 7 Questions

(3 points)

Last Name: \_\_\_\_\_ First Name: \_\_\_\_\_

1. List the function of each cardiac layer and number the order from most to least superficial. (0.5 point)
  - Pericardium:
  - Myocardium:
  - Endocardium:
  - Epicardium:
  
2. Explain why the left ventricle's walls are thicker than the right ventricle's. (0.5 point)
  
  
  
  
  
  
  
  
  
  
3. A child is stung by a bee and experiences an anaphylactic reaction. Upon observing the pathology, you notice a large increase in the number of very large granulocytic white blood cells whose granules obscure the nucleus. What type of cell did you observe? (0.5 point)
  
  
  
  
  
  
  
  
  
  
4. Correctly match the term with the correct order of blood flow through the heart. (0.5 point)

Venous blood enters the \_\_\_\_\_ from the \_\_\_\_\_ and \_\_\_\_\_ as well as the coronary sinus, which converge into the the \_\_\_\_\_. From there blood passes the \_\_\_\_\_ valves and enters the \_\_\_\_\_. The venous blood passes through the \_\_\_\_\_ and from there branches off into the \_\_\_\_\_ and \_\_\_\_\_ before circulating through the \_\_\_\_\_. After being oxygenated, the blood re-enters the heart through the \_\_\_\_\_ which converge into the \_\_\_\_\_. Then the blood flows through the \_\_\_\_\_ into the \_\_\_\_\_. From here, blood is ejected through the \_\_\_\_\_ into the \_\_\_\_\_ before entering the \_\_\_\_\_ and finally systemic circulation.

  1. Superior vena cava
  2. Inferior vena cava
  3. Right atrium
  4. Left atrium
  5. Lungs
  6. Pulmonary veins

7. Left pulmonary artery
8. Right pulmonary artery
9. Right atrioventricular valve
10. Mitral valves
11. Ascending aorta
12. Arch of aorta
13. Aortic semilunar valve
14. Pulmonary semilunar valve
15. Left ventricle
16. Right ventricle
17. Heart

5. What is the anatomical significance of the pericardium and epicardial fat? The visceral layer of the pericardium is also known as the \_\_\_\_\_? (0.5 point)

6. An individual who cannot coagulate properly is at risk of bleeding out with any significant lesion. A reduction in what type of cell might cause this in such an individual? How does this affect the composition of their blood? (0.5 point)



PART VIII

## LAB 8: DIGESTIVE SYSTEM



# 24. Lab 8: Digestive System

## Measurable Outcomes

- Label the anatomical structures of the digestive system on available models.
- Explain the pathway of food from the mouth to the anus, identifying major landmarks along the way.
- Deduce the pathway of major arteries and veins that supply the organs of the digestive system.
- Identify the histology of the digestive organs on microscope slides.
- Demonstrate an adequate understand of the material in this section.

## Background

The digestive system consists of the gastrointestinal tract (also known as the alimentary canal), a hollow muscular tube extending from the mouth to the anus, and accessory organs, including the *liver* and *pancreas*. Technically, until food is absorbed in the intestines it is considered to be outside of the body. To promote absorption, the intestines have villi which contain hair-like structures called microvilli. Like the alveoli of the lungs, microvilli substantially increase the surface area of the intestines to between 180 to 300 m<sup>2</sup> (the size of the average American home). Major structures of the gastrointestinal tract include the *oral cavity*, *pharynx*, *esophagus*, *stomach*, *small intestine*, *large intestine*, *rectum*, and *anus*. These structures and organs form a hollow space from mouth to anus and function to chemically and mechanically catabolize and absorb nutrients. Along the way organs such as the *salivary glands*, *liver*, *gallbladder* and *pancreas* release enzymes to aid digestion and are known collectively as accessory structures.

The organs of the GI tract are made from four layers, the inner lining or *mucosa*, the *submucosa* containing blood vessels and lymphatics, the *muscularis* or smooth muscle layer, and the outermost layer or *serosa/adventitia*. Each layer plays a vital role in the digestive system ranging in their capacity to form a protective barrier from the highly acidic contents of the stomach to supplying hormones, producing muscle contractions and draining lymph. Furthermore, specialized cells such as the foveolar, chief cells of the stomach are supporting cells which produce a protective layer of mucus and gastric acid for digestion. Other supporting cells, such as the gastric parietal cells of the stomach and the ductal and acinar cells of the pancreas release zymogens, inactive forms of digestive enzymes.

The peritoneum is a large serous membrane which lines the abdominal cavity and covers most of the digestive organs. some organs are only partially covered by the peritoneum while others are entirely uncovered. These organs are referred to as being retroperitoneal. Formed by the double folding of the peritoneum is a continuous set of tissues known as the mesentery. This organ was relatively recently reclassified as an organ after discovering its complex constitution. The mesentery houses lymphatic vessels as well as providing a conduit for the blood vessels for the small and large intestines.

**Vocabulary for Digestive System can be found on page(s) 165-166.**

# 25. Pre-Lab 8

(5 points)

Last Name: \_\_\_\_\_ First Name: \_\_\_\_\_

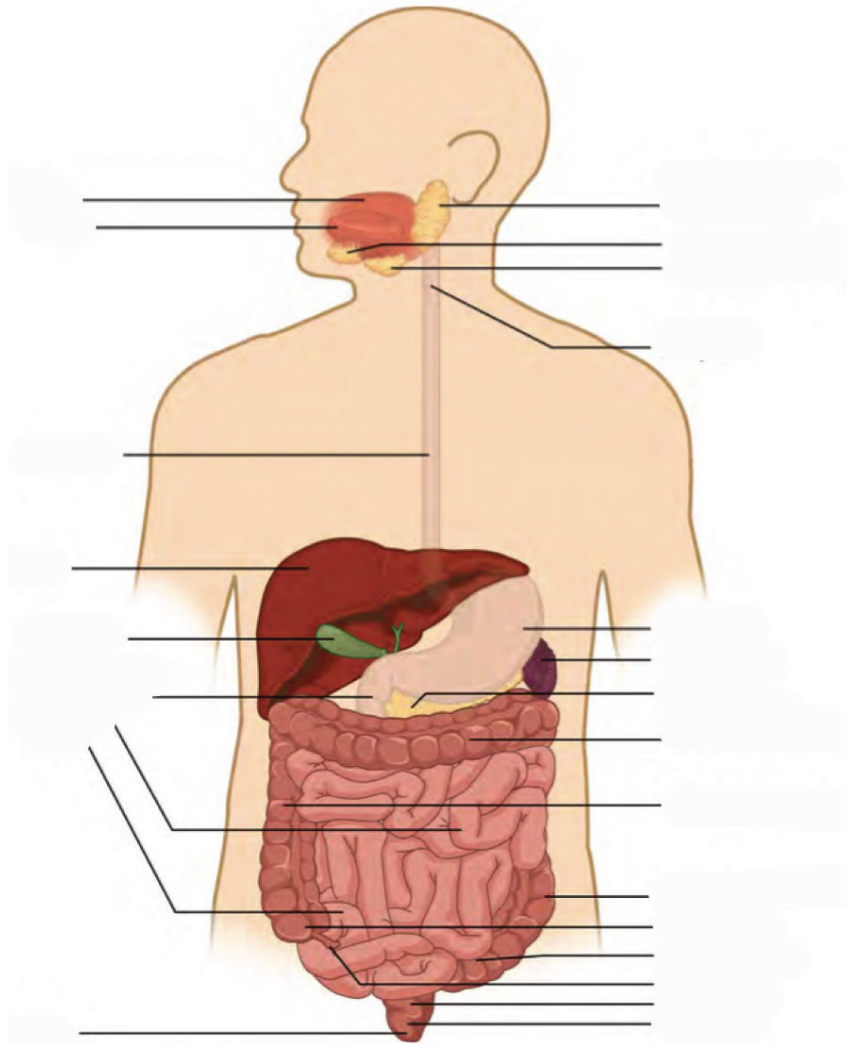
## Instructions:

Fill in the table below with the appropriate terms. For the remaining exercises, label the structures accordingly.  
(1 point)

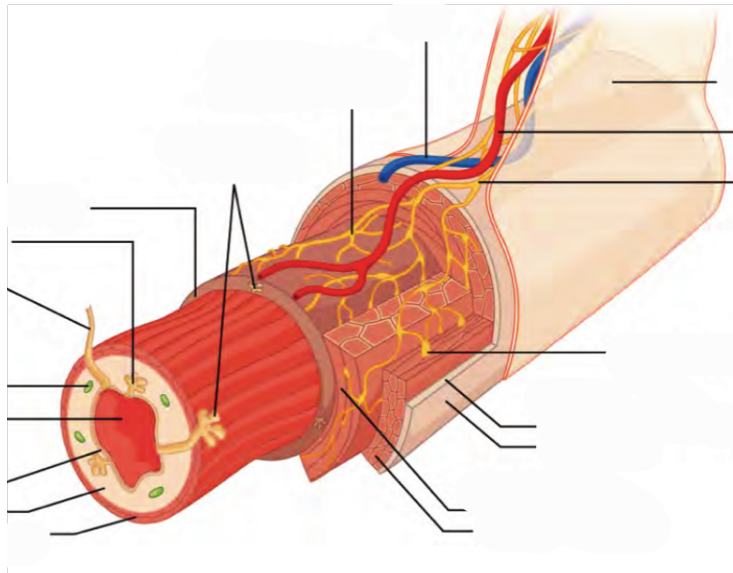
Name of a structure	is	directional term	to	Name of the second structure
gallbladder	is	posterior	to	liver
transverse colon	is	superior	to	
	is	inferior	to	small intestine
liver	is	anterior	to	
	is	distal	to	duodenum
jejunum	is	medial	to	
	is	lateral	to	left lobe of liver



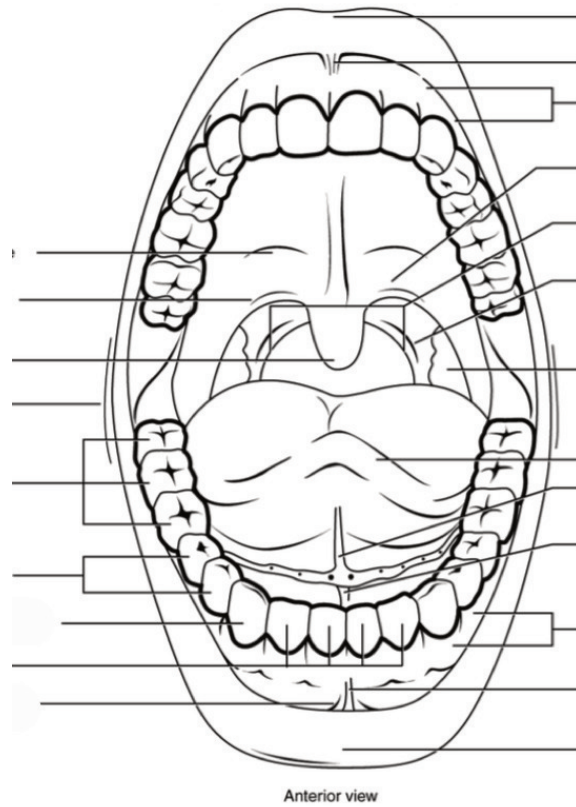
Label all digestive organs of the GI tract. (1 point)



Label the elements of the alimentary canal. (0.5 points)

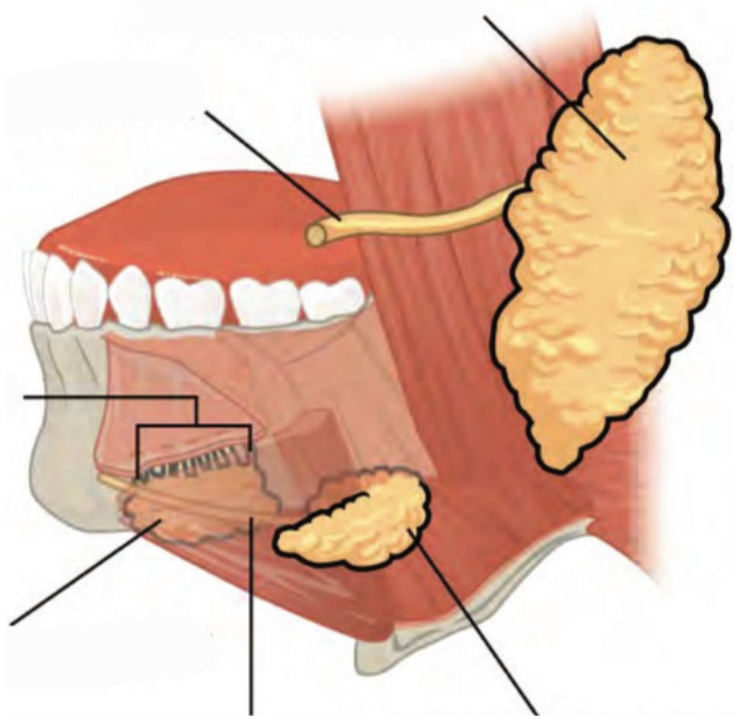


Label the different aspects of the mouth. (0.5 points)

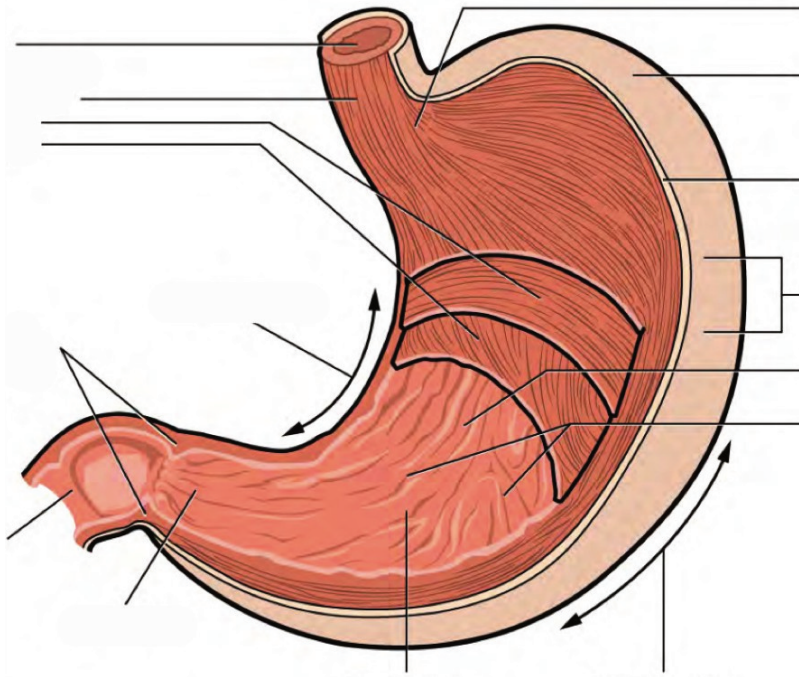




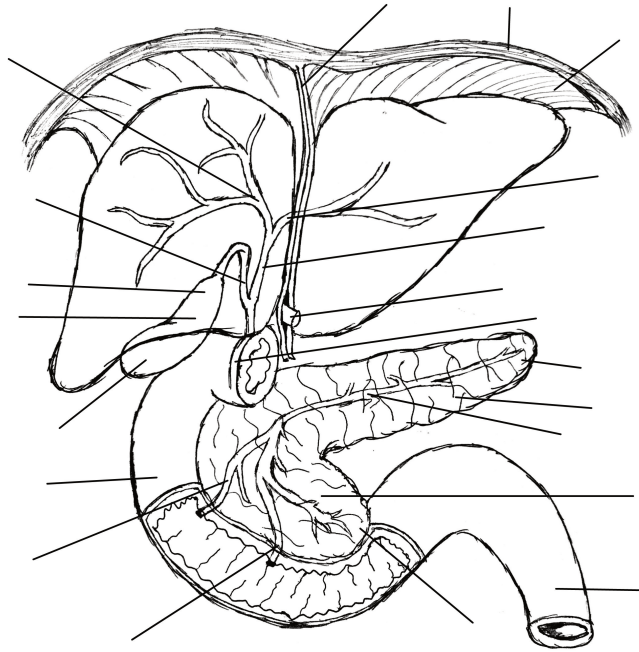
Label the major salivary glands and ducts. (0.5 points)



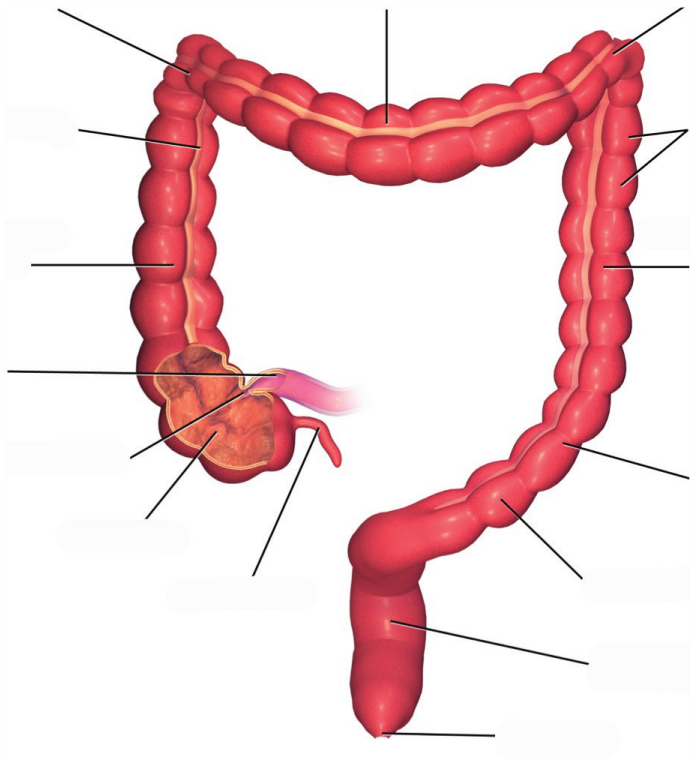
Label the aspects of the stomach accordingly. (0.5 points)



**Label the accessory organs, structures, and ducts of the digestive system. (0.5 points)**



**Label the structures and features of the large intestine. (0.5 points)**



## 26. Lab Activities

A list of words is provided below that you are expected to identify, learn, and label on the models provided. Note that not all models will have some of the organs/structures, so be sure to find them on an alternate model. You must use all the words provided. Using the colored tape provided, write the number that corresponds to the organ/structure and place them on your model. When complete, notify your TA so they may check your work.

For each additional station, directions will be provided for the activity.

### Station One: Mouth

Label the models of this station with the number that corresponds to the appropriate structure of the peripheral nervous system using the colored tape. When you are finished, ask your TA to check your labeling. Before leaving the station, remove all the labels you have placed on the model.

Note: For the following structures, be able to differentiate between left and right halves when applicable.

#### Mouth

#1 labial frenulum	#3 hard palate	#5 uvula
#2 fauces	#4 soft palate	

#### Tongue

#6 tongue	#9 fungiform papillae	#11 circumvallate papillae	#13 taste pore
#7 lingual frenulum	#10 filiform papillae	#12 taste bud	#14 base
#8 apex			



## Teeth

#15 incisor	#18 molar	#21 root	#24 pulp cavity	#27 cementum
#16 canine	#19 crown	#22 enamel	#25 pulp	#28 periodontal ligament
#17 premolar	#20 neck	#23 dentin	#26 apical foramen	#29 gingiva

## Salivary Glands

#30 submandibular	#31 parotid	#32 sublingual
-------------------	-------------	----------------

## Station Two: Esophagus and Stomach

Label the models of this station with the number that corresponds to the appropriate structure of the peripheral nervous system using the colored tape. When you are finished, ask your TA to check your labeling. Before leaving the station, remove all the labels you have placed on the model.

### Esophagus

#1 upper esophageal sphincter	#2 lower esophageal sphincter
-------------------------------	-------------------------------

### Stomach

#3 gastric pits	#6 cardia	#9 pylorus	#12 circular muscle layer
#4 gastric glands	#7 gastric body	#10 pyloric sphincter	#13 oblique muscle layer
#5 fundus	#8 rugae	#11 longitudinal muscle layer	

## Station Three: Liver, Gallbladder and Pancreas

Label the models of this station with the number that corresponds to the appropriate structure of the peripheral nervous system using the colored tape. When you are finished, ask your TA to check your labeling. Before leaving the station, remove all the labels you have placed on the model.

Note: For the following structures, be able to differentiate between left and right halves when applicable.

### Liver

#1 right lobe of liver	#3 right hepatic duct	#5 common hepatic duct	#7 hepatic canaliculi
#2 left lobe of liver	#4 left hepatic duct	#6 hepatic lobule	#8 falciform ligament

### Gallbladder


#9 fundus of gallbladder	#11 neck of gallbladder	#13 common bile duct
#10 body of gallbladder	#12 cystic duct	

### Pancreas


#14 acinar cells	#16 islets of Langerhans	#18 pancreatic head	#20 uncinat process	#22 pancreatic duct
#15 endocrine cells	#17 pancreatic tail	#19 pancreatic body	#21 accessory duct	

## Station Four: Histology


Sketch the slides available for today's lab and specify the magnitude at which you are observing/ sketching. Be sure to identify and label your sketch with the corresponding structures listed beneath each slide.




**Tooth**  
Enamel, Dentin, Pulp




**Parotid Gland**



**Tongue**  
Fungiform papillae, Filiform papillae, Circumvallate papillae, Taste bud, Taste pore




**Esophagus**  
Mucosa, Submucosa, Muscularis externa




**Pancreas**

Acinar cells, Endocrine cells, Islets of Langerhans




**Liver**

Hepatic lobules, Hepatic canaliculi



**Duodenum**


Lumen, Villi, Mucosa, Submucosa, Muscularis, Externa  
Serosa



**Large Intestine**

Lumen, Crypts of Lieberkühn, Mucosa, Submucosa,  
Muscularis externa, Serosa

---



**Vermiform appendix**

### Station Five: Small and Large Intestines

Label the models of this station with the number that corresponds to the appropriate structure of the peripheral nervous system using the colored tape. When you are finished, ask your TA to check your labeling. Before leaving the station, remove all the labels you have placed on the model.

Note: For the following structures, be able to differentiate between left and right halves when applicable.

#### Small Intestine

#1 microvilli	#4 submucosa	#8 enterocytes	#11 ampulla of Vater	#14 ileum
#2 vili	#6 muscularis	#9 plicae circulares	#12 sphincter of Oddi	#15 ileocecal valve
#3 mucosa	#7 serosa	#10 duodenum	#13 jejunum	

## Large Intestine

#16 crypts of Lieberkühn	#20 serosa	#24 right colic flexure	#28 sigmoid colon	#32 rectum
#17 mucosa	#21 cecum	#25 transverse colon	#29 teniae coli	#33 anal canal
#18 submucosa	#22 vermiform appendix	#26 left colic flexure	#30 haustra	#34 anal sphincter
#19 muscularis	#23 ascending colon	#27 descending colon	#31 epiploic appendices	#35 anus

## Miscellaneous

#36 peritoneum	#38 greater omentum	#40 mesoappendix
#37 mesentery of transverse colon	#39 lesser omentum	

## Station Six: Flow of Gastrointestinal Tract

As a group, determine the route boluses take through the various organs of the digestive tract. Be sure to identify the location of each structure on the vocabulary list of this lab section.

## 27. Post-Lab 8 Questions

**(3 points)**

Last Name: \_\_\_\_\_ First Name: \_\_\_\_\_

1. Describe the pathway food takes upon ingesting it, making sure to include all accessory structures. (0.5 point)
2. Explain the differences between the layers of the gastrointestinal tract. (0.5 points)

3. Match the terms with their corresponding descriptions. (0.5 points)

Name of Structure	Description	No. of Structure
1. Ileum	the largest salivary glands that produce approximately 25% of the saliva produced daily	
2. Gallbladder	passageway for liquids, foods, AND air	
3. Fauces	the modified muscularis of the large intestine	
4. Parotid glands	structures on the tongue that provide friction, allowing the tongue to move food in the oral cavity during mastication efficiently	
5. Filiform papillae	the terminal portion of the small intestine	
6. Pulp cavity	where bile made in the liver joins the bile stored in the gallbladder	
7. Pharynx	the opening between the oral cavity and the oropharynx	
8. Rugae	inner part of the tooth containing nerves and blood vessels	
9. Common bile duct	storage area for bile	
10. Teniae coli	folds of the inner wall of the stomach	

4. List each type of tooth. How do they function during mastication? (0.5)

5. List the accessory and primary structures of the GI tract. Why would accessory structures not be classified as primary organs/structures of the digestive system? (0.5 point)

6. A patient with cancerous growths in their salivary glands undergoes surgery to have them removed. How might this affect the digestive processes? (0.5 points)



PART IX

# LAB 9: URINARY AND REPRODUCTIVE SYSTEMS



# 28. Lab 9: Urinary and Reproductive Systems

## Measurable Outcomes

- Analyze reproductive and urinary organ tissues under the microscope.
- Complete the dissection of the kidney and accurately identify (with a pin) all structures of the kidney using the corresponding vocabulary list.
- Learn about the organs of the urinary system: kidney, ureter, urinary bladder and urethra, as well as the structural elements of the nephron and label on any available models.
- Compare and contrast the elements of the male and female reproductive systems and their associated accessory glands.
- Recognize homologous structures of the male and female reproductive systems.
- Demonstrate an adequate understand of the material in this section.

## Background

The urinary system is one of excretion, elimination and reabsorption. It is made from four organs, only one of which produces urine (the *kidney*). *Nephrons*, the smallest functional unit of the kidneys, are found in numbers of one to two million within the kidney and can filter up to 400 gallons of cycled blood, daily. The kidneys receive more blood than the heart, liver, or even the brain and have vital functions such as the regulation of pH, blood pressure, concentration of blood solutes and concentration of red blood cells. The remaining three organs (*ureters*, *urinary bladder*, and *urethra*) facilitate urine storage and secretion. Of these organs, only the urethra is anatomically distinct between males and females.

The reproductive system is designed to propagate a species and therefore has two primary functions: the production of gametes ( $n$ ) and sex hormones. Male gametes are referred to as *sperm* cells, whereas female gametes are called *ova*. Reproduction is very metabolically taxing especially for the female. To illustrate, mature ovum can contain as many as 600,000 mitochondria; to reference, liver cells and cardiac muscles cells contain 2,000 and 5,000 mitochondria respectively. The role of the male reproductive system is to produce sperm and transfer them to the female reproductive tract. Although they originate from similar primordial tissues, the female and male reproductive systems differ in gonad type, ducts, accessory glands, and external genitalia. Male gonads are referred to as *testes* while the female gonads as *ovaries*; both are the sites of their respective gametogenesis. The hormones produced by the gonads are crucial to the reproductive system and sexual development, including primary and secondary sexual development, tissue regeneration, and production of gametes.

Humans are a sexually dimorphic species, which mean that there are distinguishing secondary sex characteristics. The hormones that influence male primary and secondary sexual development are called androgens. The hormones that influence female primary secondary sexual development are called estrogens. In females, this entails the development of breasts which are specialized sweat glands. Males also have mammary tissue but their development is arrested early. Similarly, the thyroid cartilage is enlarged and commonly referred to as an Adam's apple in males but not so in females.

A developing fetus remains anatomically undifferentiated and will either develop characteristically male or female anatomy. At some point of gestation, the fetus will develop both Wolffian and Müllerian ducts, anlagen of the male and female reproductive systems. As a result, there are several elements of the male and female reproductive systems which are *homologous*. Such structures share developmental and evolutionary origins but are not necessarily similar in function. The following are the homologous structures of the male and female reproductive system: *labia majora* – male scrotum; *labia minora* – shaft of penis; clitoris – glans penis; paraurethral gland – prostate gland; greater vestibular gland – bulbourethral gland.

**Vocabulary for the Urinary and Reproductive systems on page(s) 172 and 168.**

# 29. Pre-lab 9

(5 points)

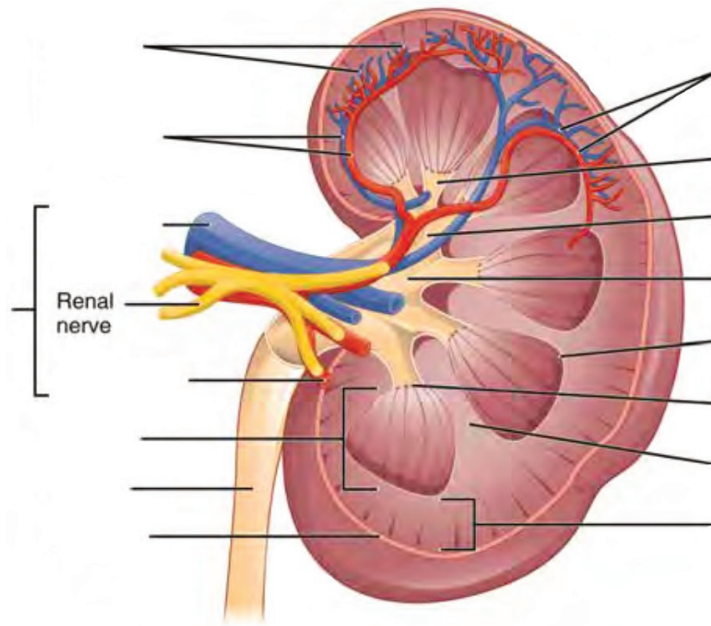
Last Name: \_\_\_\_\_ First Name: \_\_\_\_\_

## Instructions:

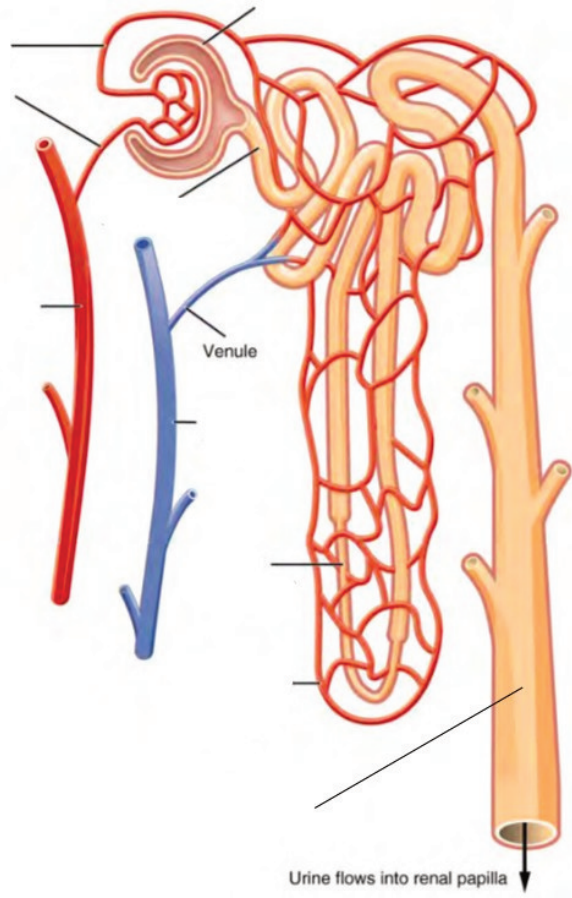
Fill in the table below with the appropriate terms. For the remaining exercises, label the structures accordingly.  
(1 point)

Name of a structure	is	directional term	to	Name of the second structure
scrotum	is	posterior	to	penis
kidneys	is	superior	to	
	is	inferior	to	urinary bladder
pubic symphysis	is	anterior	to	
	is	distal	to	prostate gland
uterus	is	medial	to	
	is	lateral	to	urethra

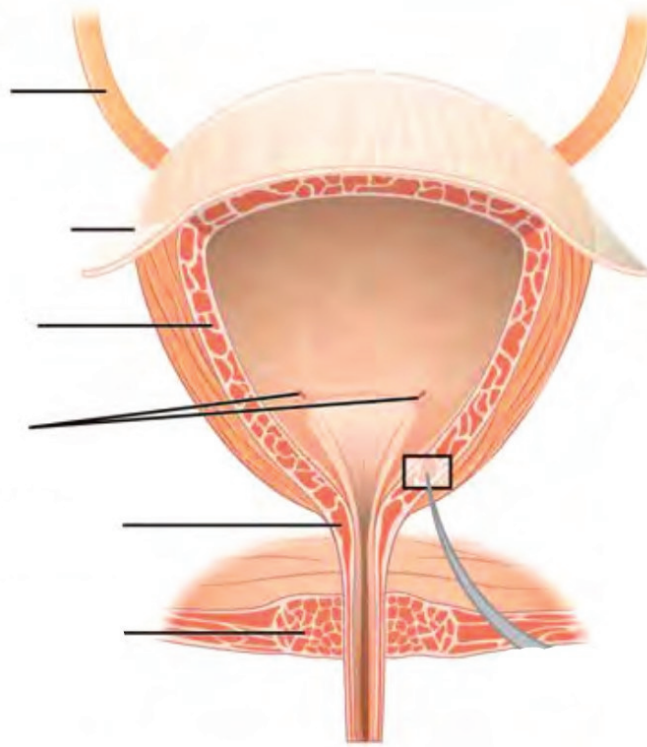
**Label the structures and regions of the left kidney. (1 point)**



**Label the structures of the nephron. (0.5 points)**

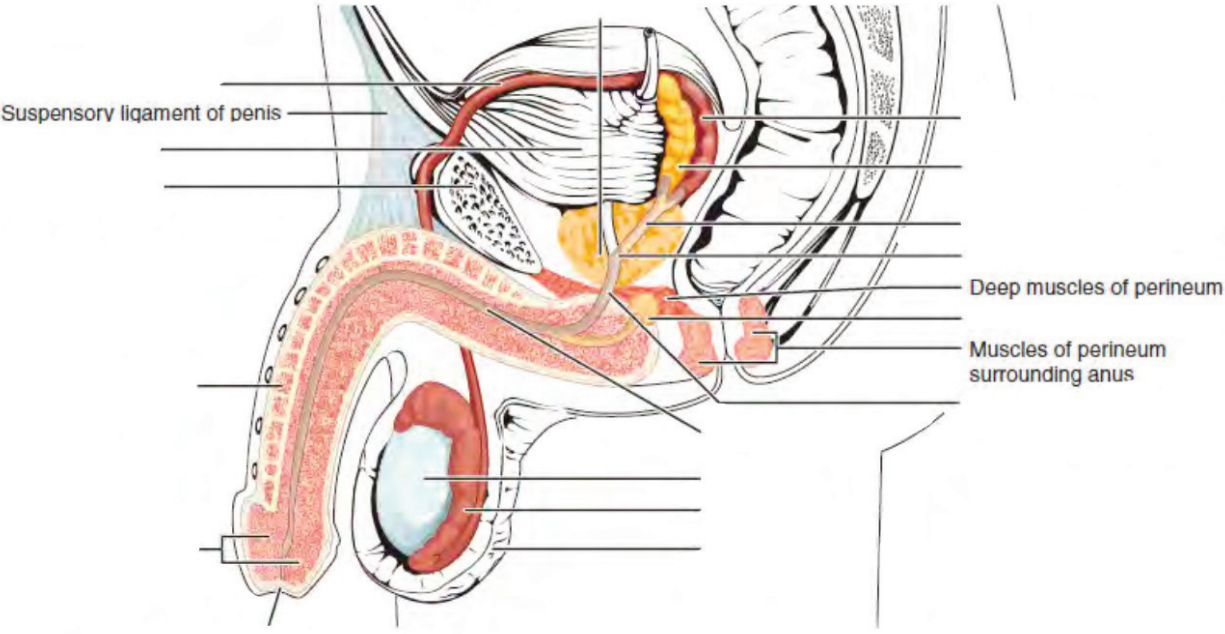


**Label the structures of the bladder. (0.5 points)**

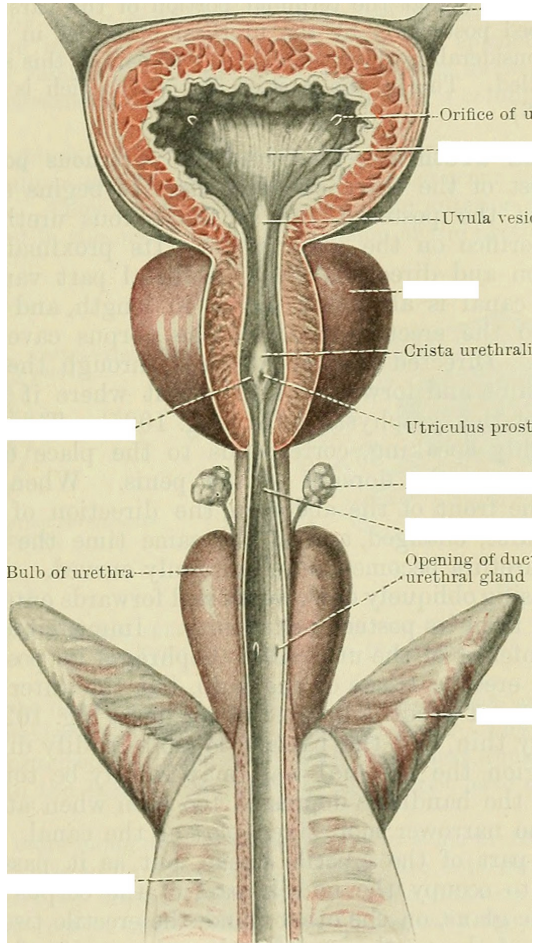


**Label the parts of the male urinary/reproductive systems. (0.5 points)**

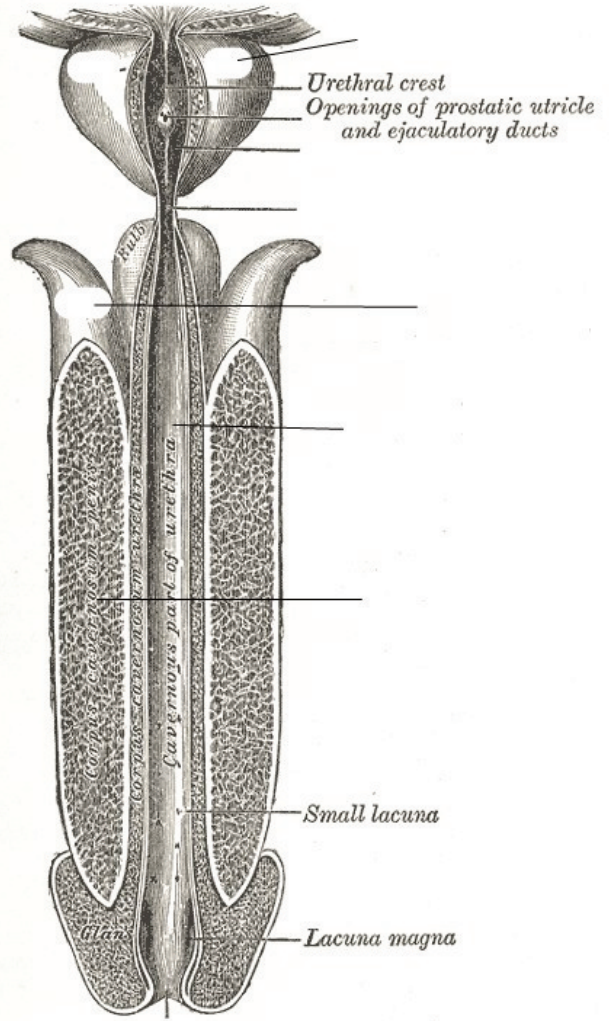




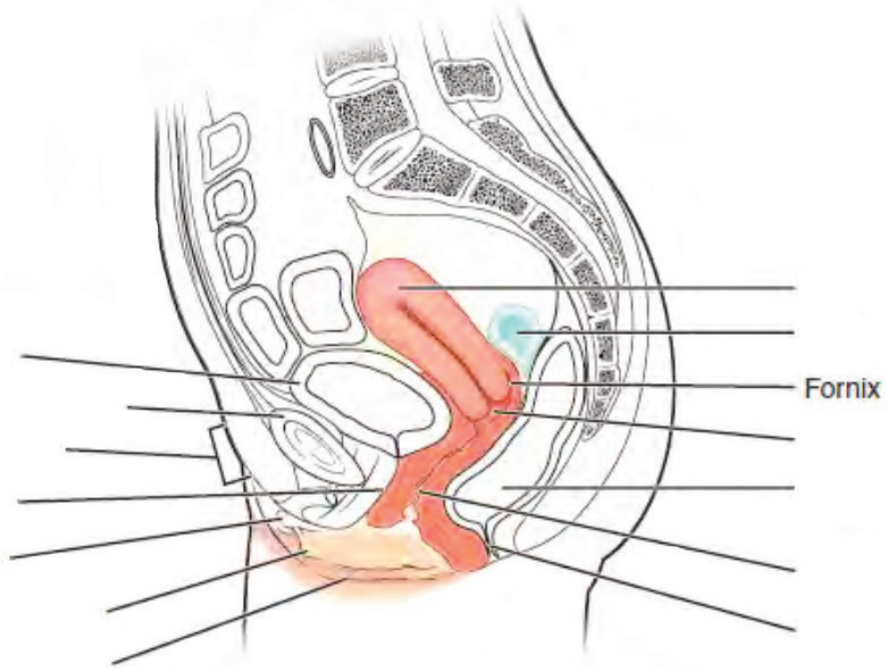
Label the structures of the male reproductive system. (0.25 points)



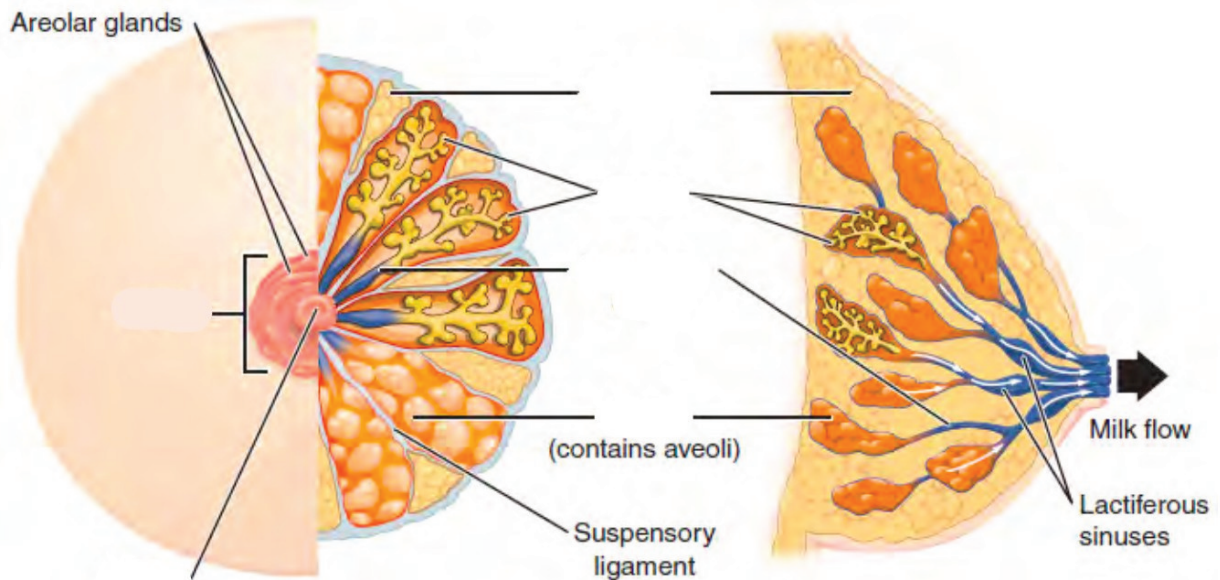
Label the structures of the male reproductive system. (0.25 points)



Label the parts of the female urinary/reproductive system. (0.5 points)

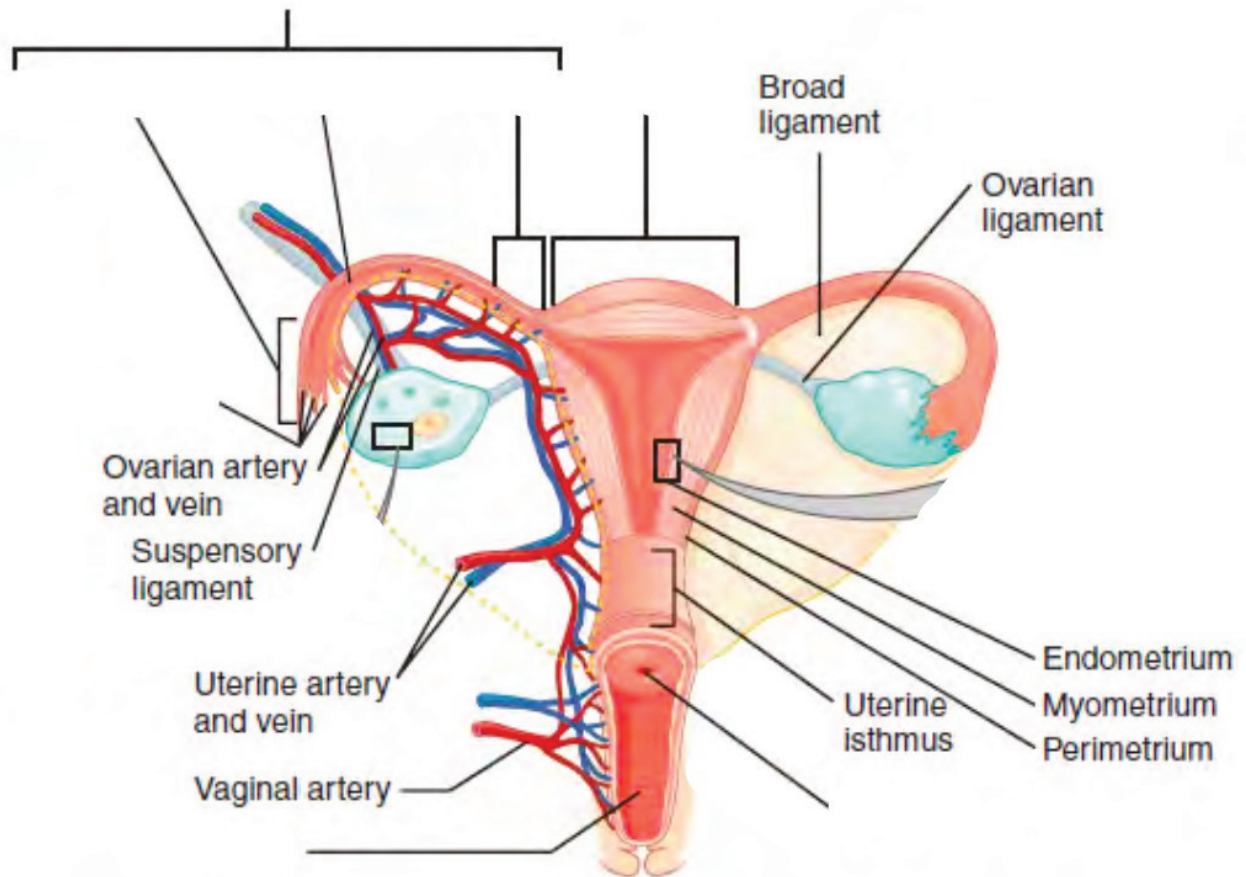


Label the structures of the breasts. (0.25 points)





Label the structures of the uterus. (0.25 points)



## 30. Lab Activities

A list of words is provided below that you are expected to identify, learn, and label on the models provided. Note that not all models will have some of the organs/structures, so be sure to find them on an alternate model. You must use all the words provided. Using the colored tape provided, write the number that corresponds to the organ/structure and place them on your model. When complete, notify your TA so they may check your work.

For each additional station, directions will be provided for the activity.

### Station One: Urinary

Label the models of this station with the number that corresponds to the appropriate structure of the peripheral nervous system using the colored tape. When you are finished, ask your TA to check your labeling. Before leaving the station, remove all the labels you have placed on the model.

#1 renal fascia	#11 renal pelvis	#21 external urethral orifice	#31 proximal convoluted tubule
#2 adipose capsule	#12 renal hilum	#22 cortical nephron	#32 descending loop of Henle
#3 renal capsule	#13 ureter	#23 juxtamedullary nephron	#33 ascending loop of Henle
#4 renal cortex	#14 urinary bladder	#24 juxtaglomerular apparatus	#35 distal convoluted tubule
#5 renal medulla	#15 detrusor muscle	#25 renal corpuscle	#36 collecting duct
#6 renal lobe	#16 rugae	#26 glomerulus	#37 papillary duct
#7 renal pyramid	#17 urinary trigone	#27 podocyte	#38 minor calyx
#8 renal columns	#18 internal urethral sphincter	#28 bowman's capsule	#39 major calyx
#9 renal papilla	#19 external urethral sphincter	#29 capsular space	
#10 renal sinus	#20 urethra	#30 renal tubules	

## Blood Vessels

#40 renal artery	#43 arcuate arteries	#46 glomerular capillaries	#49 cortical radiate veins	#52 renal vein
#41 segmental arteries	#44 cortical radiate arteries	#47 efferent arterioles	#50 arcuate veins	
#42 interlobar arteries	#45 afferent arterioles	#48 peritubular capillaries	#51 interlobar veins	

## Station Two: Reproductive – Male

Label the models of this station with the number that corresponds to the appropriate structure of the peripheral nervous system using the colored tape. When you are finished, ask your TA to check your labeling. Before leaving the station, remove all the labels you have placed on the model.

#1 pubic symphysis	#11 head of sperm	#21 seminal vesicles	#31 prepuce of penis
#2 dartos muscle	#12 midpiece of sperm	#22 bulbourethral (Cowper's) glands	#32 external urethral orifice
#3 cremaster muscle	#13 tail of sperm	#23 ejaculatory ducts	#33 root of penis
#4 scrotum	#14 seminiferous tubules	#24 prostatic urethra	#34 bulb of penis
#5 scrotal septum	#15 straight tubule	#25 intermediate urethra	#35 crus of penis
#6 testis	#16 rete testis	#26 spongy urethra	#36 suspensory ligament of penis
#7 lobules	#17 epididymis	#27 penis	#37 spermatic cord
#8 leydig cells	#18 ductus (vas) deferens	#28 corpus cavernosum	#38 deep muscle of perineum
#9 sertoli cells	#19 ampulla of ductus deferens	#29 corpus spongiosum	
#10 sperm	#20 prostate glands	#30 glans penis	

## Station Three: Reproductive – Female


Label the models of this station with the number that corresponds to the appropriate structure of the peripheral nervous system using the colored tape. When you are finished, ask your TA to check your labeling. Before leaving the station, remove all the labels you have placed on the model.

#1 pubic symphysis	#10 isthmus of uterine tube	#19 fundus of uterus	#28 vaginal orifice	#37 breast
#2 placenta	#11 broad ligament	#20 body of uterus	#29 mons pubis	#36 areola
#3 ovary	#12 round ligament	#21 isthmus	#30 vulva	#39 nipple
#4 ova	#13 uterosacral ligament	#22 cervix	#31 labia majora	#40 mammary glands
#5 ovarian ligament	#14 uterus	#23 external os	#32 labia minora	#41 lobule
#6 uterine (Fallopian) tube	#15 endometrium	#24 internal os	#33 vestibule	#42 lactiferous ducts
#7 fimbriae of uterine tube	#16 myometrium	#25 vagina	#34 clitoris	#43 lactiferous sinus
#8 infundibulum of uterine tube	#17 perimetrium	#26 fornix	#35 external urethral orifice	#44 mammary ducts
#9 ampulla of uterine tube	#18 uterine cavity	#27 rugae	#36 vestibular glands	#45 mammary alveoli

### Station Four: Histology

Sketch the slides available for today's lab and specify the magnitude at which you are observing/ sketching. Be sure to identify and label your sketch with the corresponding structures listed beneath each slide.

#### Urinary




#### Kidney




Bowman's capsule (renal corpuscle), Glomerulus

**Male Reproductive**

---




**Testis**  
Seminiferous tubules, Lobules



**Epididymis**


---




**Human Sperm**  
Head, Midpiece, Tail

**Female Reproductive**


---




**Mammary gland**  
Mammary alveoli, Lobule, Ducts



**Uterus**  
Endometrium, Myometrium, Perimetrium



**Placenta**



**Ovary**  
Mature (Graafian) follicle

---

## Station Five: Kidney Dissection

- Upon receiving your kidney, identify the renal hilum, from which the renal artery, renal vein, and ureter protrude (it is also the indented portion of the kidney).
- Now lay the kidney on its broadest most flat portion, with the renal hilum facing opposite your dominant hand (if you are right-handed, the hilum should be facing left).
- Using the scalpel from your dissection kit, cut the kidney in half lengthwise from the side, meaning, your scalpel should begin at the anterior, medial section of the kidney and work its way down to the posterior medial section. (**DO NOT make sawing motions with the scalpel.**) Continue making these incisions with your scalpel until you have separated the halves of a kidney
- Obtain pins from the table and place them on as many structures as you can identify. Your lab TA will come around and ask you to identify the pins you have placed.
- Before leaving the station, remove all the pins you have placed.

\*If you are the last table to use this station, be sure to clean off the dissection kits in the lab's sink.

## Station Six: Filtrate Path and Blood Flow through Kidney

As a group, determine the route of urine through the various ducts of the kidney, originating at the glomerulus and ending with the urethra. Be sure to identify where along that path each of the structures on the vocabulary list is located.

As a group, determine the course of blood through the vessels of the kidney.

Note: The following three pages are left blank for the purpose of drawing out these two pathways.

# 3I. Post-Lab 9 Questions

(2 points)

Last Name: \_\_\_\_\_ First Name: \_\_\_\_\_

1. Match the structure with the corresponding description. (0.5 point)

Name of Structure	Description	No. of structure
1. ureters	Area where renal vessels and ureters converge	
2. kidney	urination	
3. renal capsule	nephrons located deep in the renal medullas	
4. micturition	smooth muscle of the bladder	
5. rugae of the mucosa	organ of urine production	
6. hilum	includes Bowman's capsule and glomerulus	
7. collecting duct	folds in the bladder when empty	
8. detrusor	a structure where nephrons drain urine into	
9. renal capsule	collagen membrane around the kidney	
10. juxtamedullary nephrons	tubules that conduct urine from the kidney to bladder	

2. Write down the path of urine from the point of origin to secretion. (0.5 point)

3. Match the structure with the corresponding description. (0.5 point)

<b>Name of Structure</b>	<b>Description</b>	<b>No. of structure</b>
1. Ductus- vas-deferens	produce sperm and testosterone	
2. Areola	small convoluted tubules and site of spermatogenesis	
3. Testes	conduct sperm to the urethra during ejaculation	
4. Mammary gland	produces an ovum, estrogen, and progesterone	
5. Fimbriae	a gland in mammals that produces milk	
6. Corpus cavernosum and spongiosum	ducts that carry milk from the mammary glands to the nipple	
7. Labia major	pigmented area around the nipple	
8. Seminiferous tubules	the larger outer folds of the vulva surrounding the inner folds; contain adipose tissue and hair	
9. Ovaries	erectile tissues that form the bulk of the penis	
10. Lactiferous ducts	small fingerlike projections at the end of the fallopian tubes	

4. What is unique about the location/position of the kidneys? (0.5 point)

PART X

LAB 10: THE MUSCULAR AND  
INTEGUMENTARY SYSTEMS





# Lab 10: The Muscular and Integumentary systems

## Measurable Outcomes

- Name the anatomical structures of integumentary and muscular systems on available models.
- Distinguish between the types of muscular tissue from histology slides.
- Determine the layers of the integument from histology slides.
- Demonstrate an adequate understand of the material in this section.

## Background

The body's first line of defense against pathogens and other microbes is the skin. The skin is multi-layered and it functions to maintain homeostasis, retain water, synthesize vitamin D and regulate body temperature (thermoregulation). It is made of two chief layers: the *epidermis*, made of closely packed epithelial cells, and the *dermis*, made of dense, irregular connective tissue which houses blood vessels, *hair follicles*, *sweat glands*, and other structures. Beneath the *dermis* lies the *hypodermis*, which is composed mainly of loose connective and fatty tissues. One of skin's accessory structures, *nails*, are considered to be specialized structures of the epidermis found at the tips of fingers and toes. Other accessory structures, *sudoriferous glands*, produce sweat which cools the body by evaporation. Skin is the largest continuous organ of the body, encompassing approximately 16 percent of our body weight.

The muscular system is an intricate network of contractile tissue which works antagonistically in order to move the body. The action of walking requires roughly 200 different muscles alone. Besides skeletal muscles, there are also cardiac muscle and smooth muscle. Cardiac muscle is found uniquely in the heart and is responsible for pumping blood through the circulatory system. Smooth muscle is the type of muscle involved in involuntary movements such as peristalsis which propel boluses through the GI tract. Skeletal muscle is also known as striated muscle, as is cardiac muscle. As you approach the muscles in this lab, make note of which muscles may be named after their shape and which ones may be named after their location or their attachments to the skeleton. Individually, all cells, with the exception of sperm, are unable to move on their own. Nevertheless, with bones as their scaffold, muscles are able to produce movement through a complex series of metabolic reactions.

**Vocabulary for Muscles and Integumentary systems can be found on page(s) 166-167 and 166.**

# 32. Pre-Lab 10

(5 points)

Last Name: \_\_\_\_\_ First Name: \_\_\_\_\_

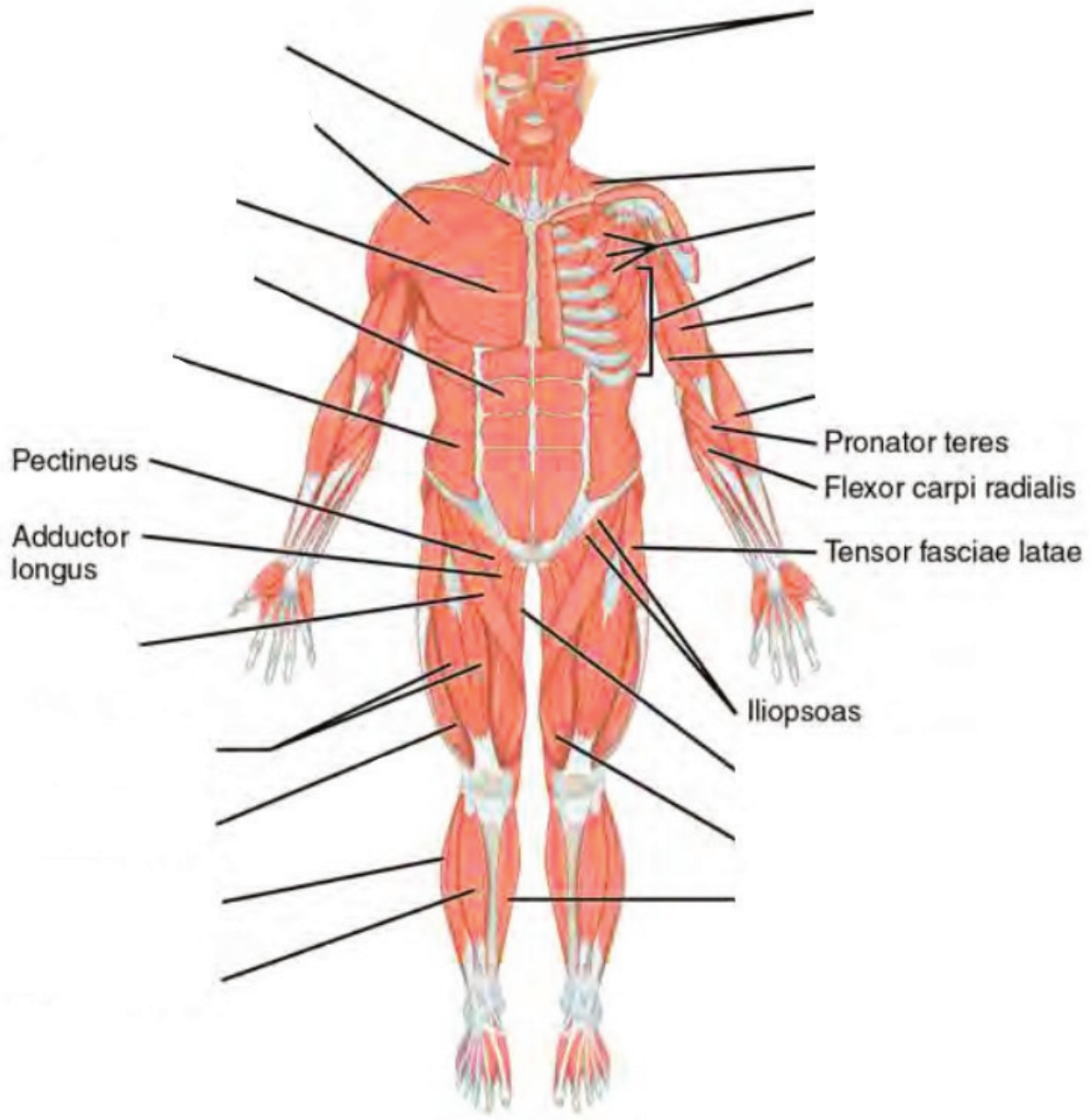
## Instructions:

Fill in the table below with the appropriate terms. For the remaining exercises, label the structures accordingly.  
(1 point)

Name of a structure	is	directional term	to	Name of the second structure
trapezius	is	proximal	to	pectoralis major
diaphragm	is	superior	to	
	is	inferior	to	scalenes
rectus abdominis	is	anterior	to	
	is	distal	to	biceps femoris
pectoralis minor	is	medial	to	
	is	lateral	to	external oblique

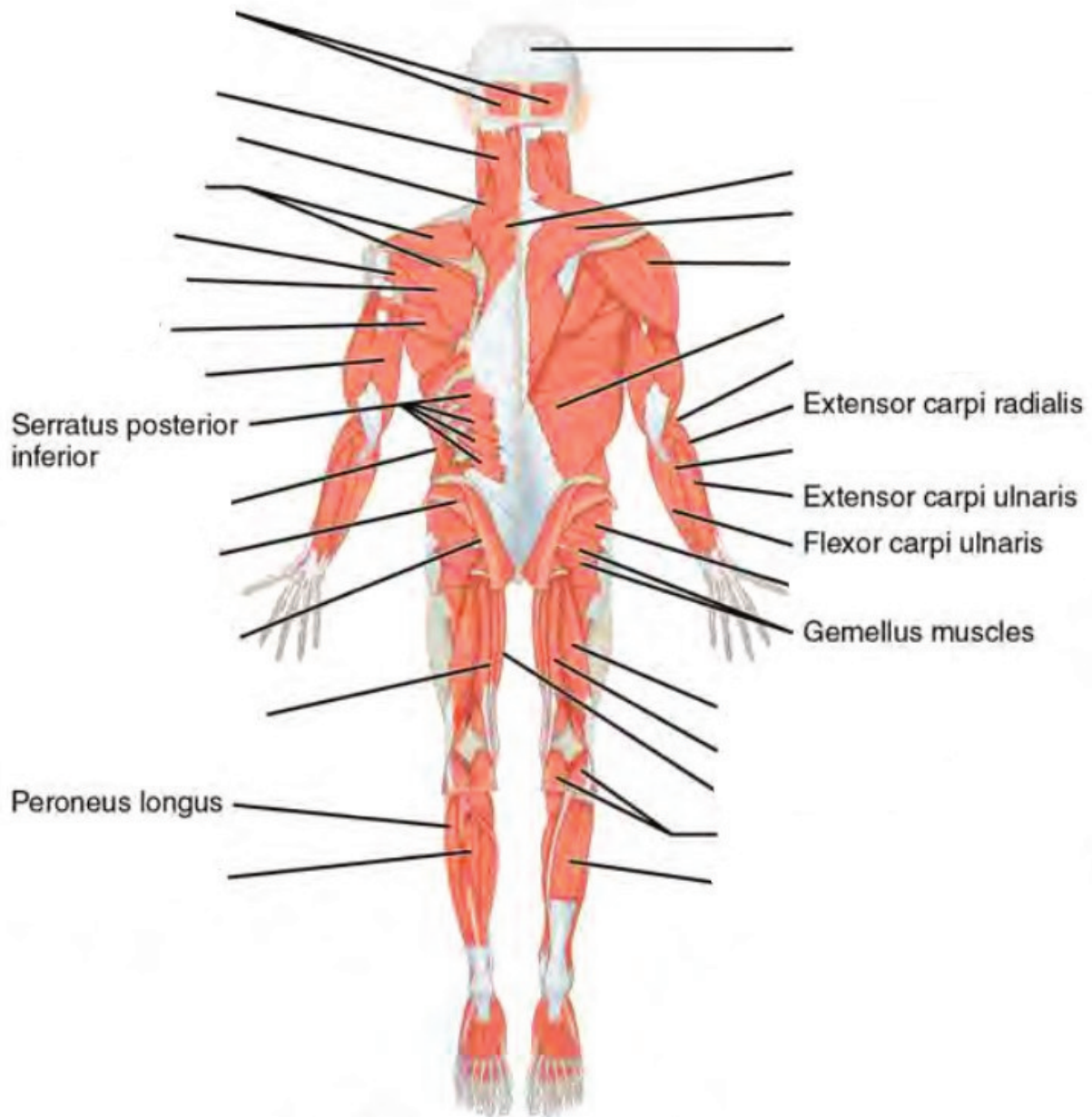
**Label the major muscles. (0.5 points)**

This is the ( ventral /dorsal ) aspect of the body. (circle one)

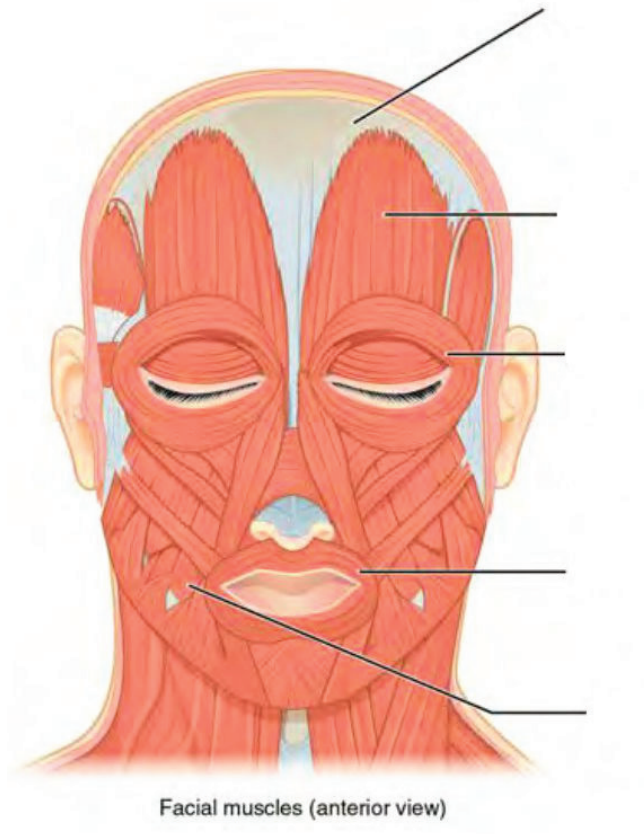


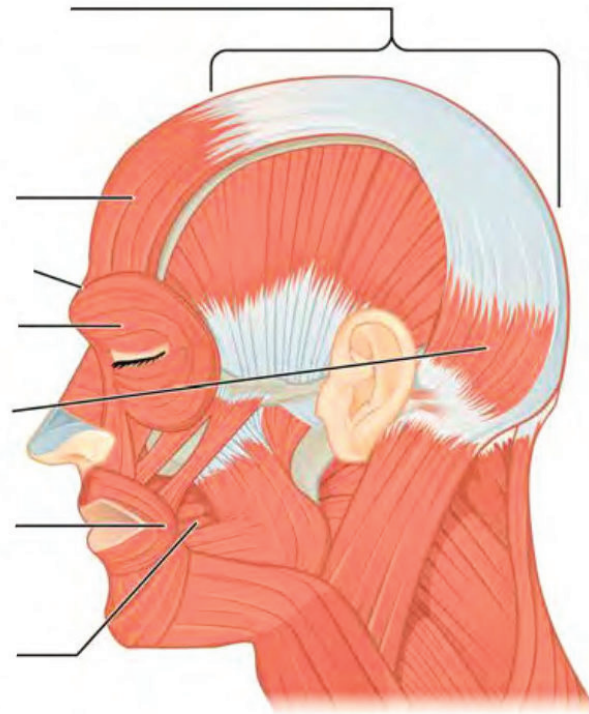
**Label the major muscles of the body. (0.5 points)**

This is the ( ventral /dorsal ) aspect of the body. (circle one)



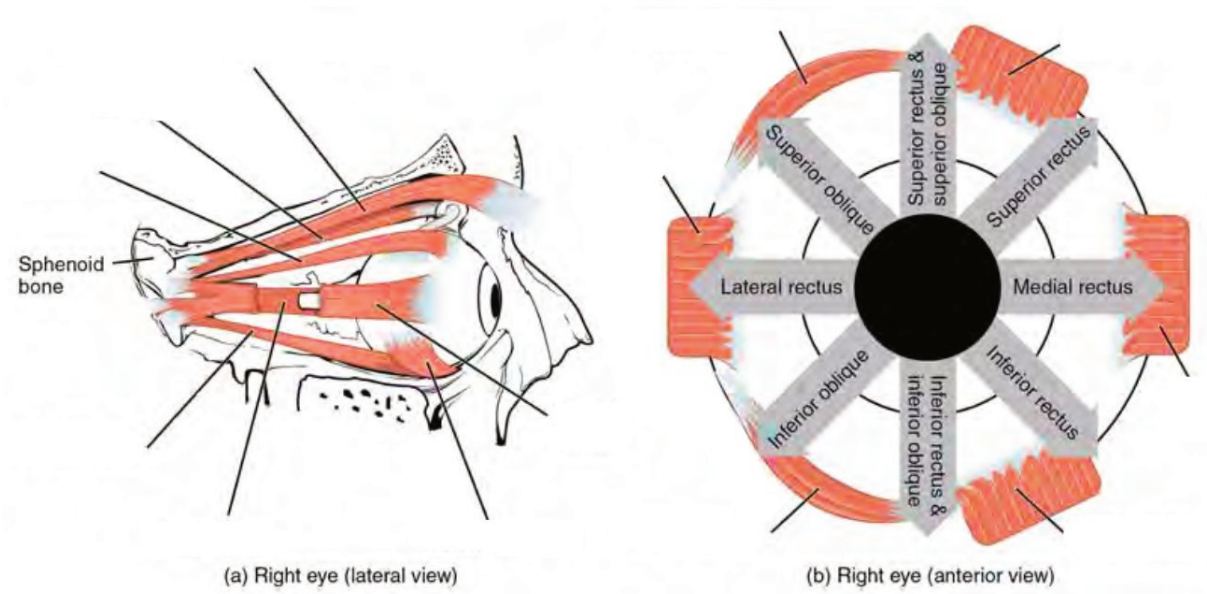
Label the muscles of the head. (0.25 points)



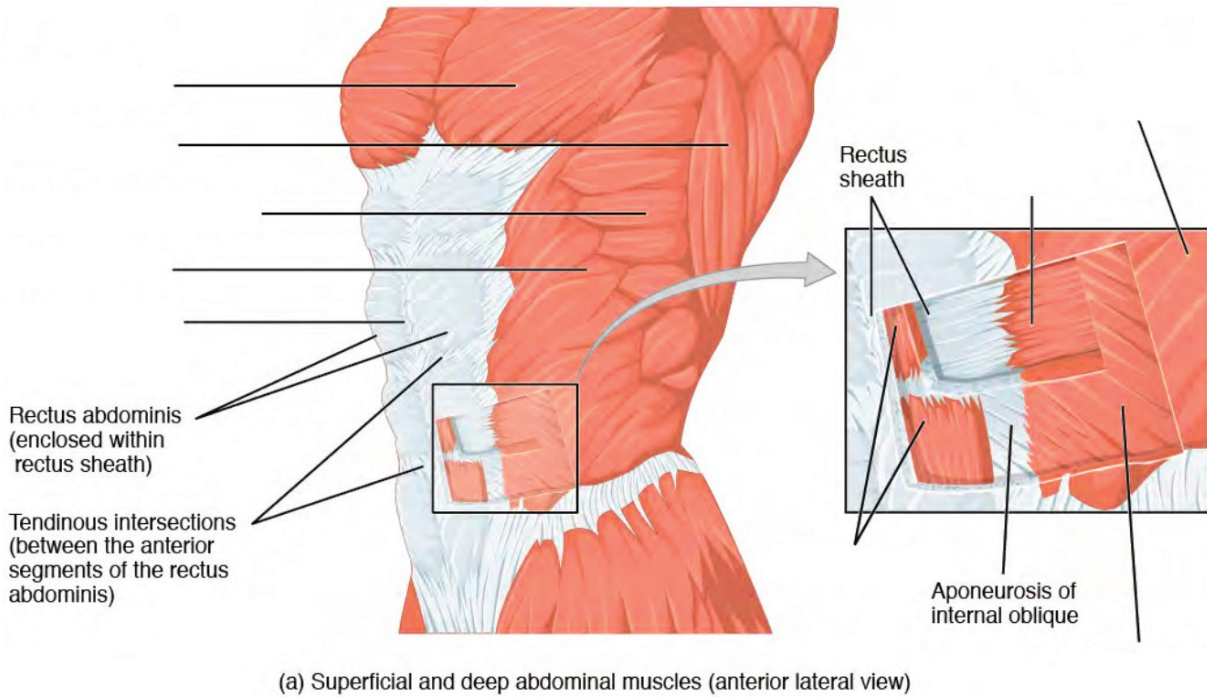


Facial muscles (lateral view)

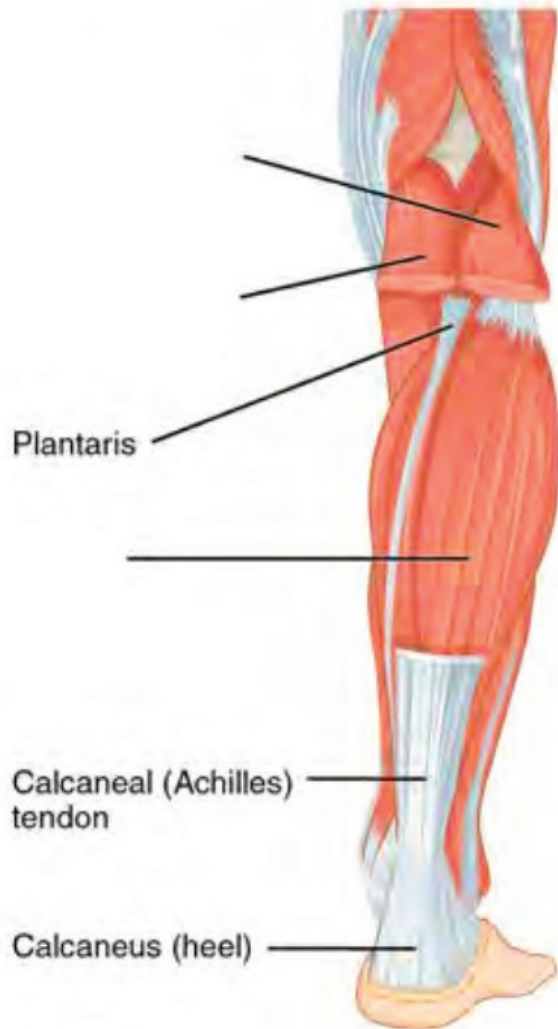Label the muscles of the eye. (0.25 points)



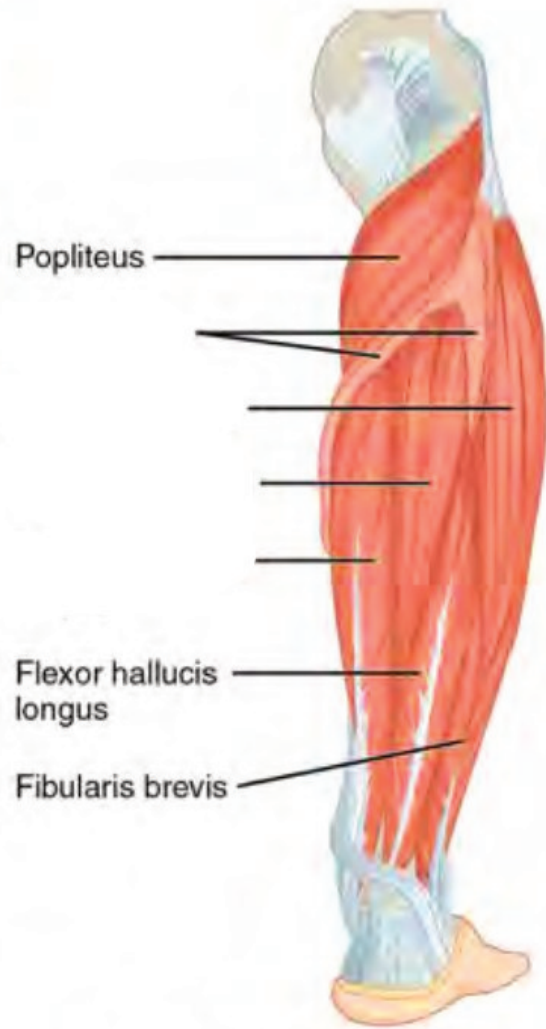
Label the major abdominal muscles. (0.25 points)



Label the major muscles of the lower leg. (0.25 points)



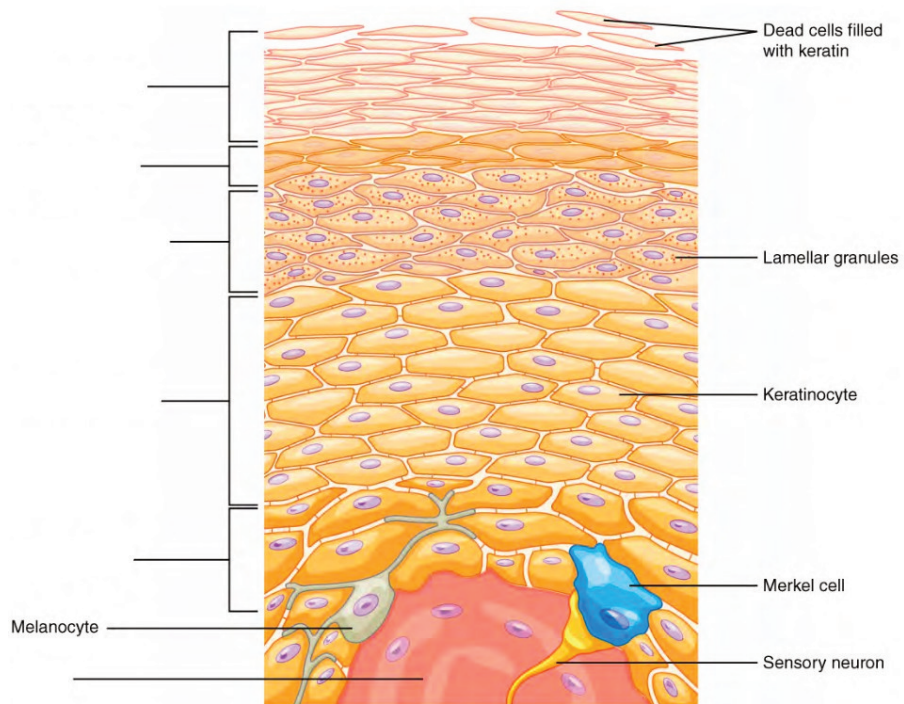
Superficial muscles of the right lower leg (posterior view)



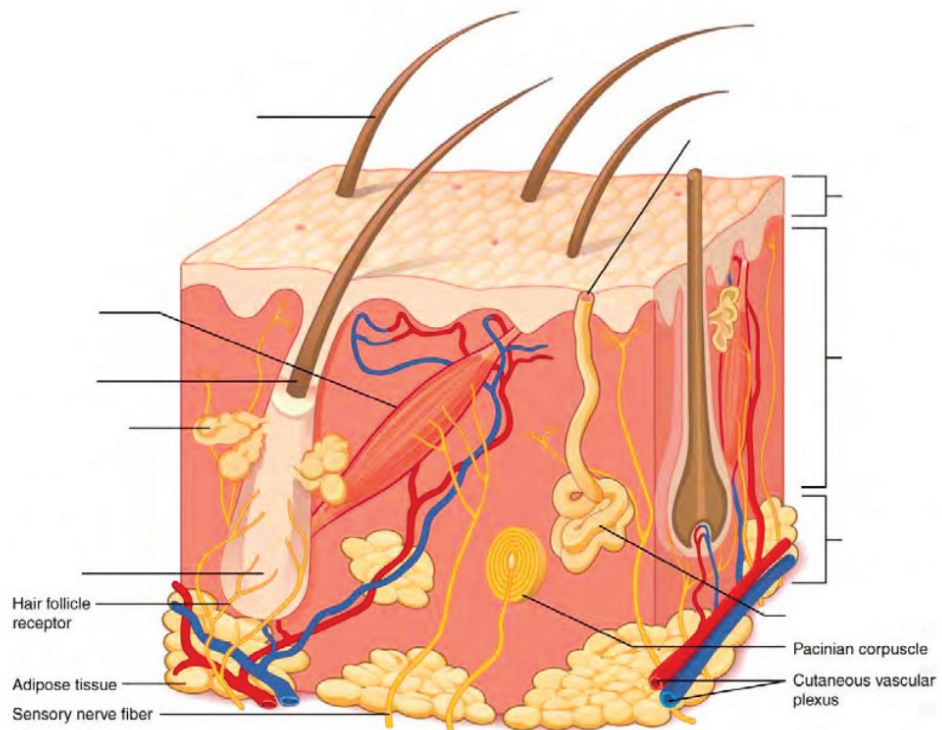
Deep muscles of the right lower leg (posterior view)



Label the layers of the epidermis. (0.5 points)



Label the layers of integument and accessory structures. (0.5 points)





## 33. Lab Activities

A list of words is provided below that you are expected to identify, learn, and label on the models provided. Note that not all models will have some of the organs/structures, so be sure to find them on an alternate model. You must use all the words provided. Using the colored tape provided, write the number that corresponds to the organ/structure and place them on your model. When complete, notify your TA so they may check your work.

For each additional station, directions will be provided for the activity.

### Station One: Muscles of the Upper Body

Label the models of this station with the number that corresponds to the appropriate structure of the peripheral nervous system using the colored tape. When you are finished, ask your TA to check your labeling. Before leaving the station, remove all the labels you have placed on the model.

Note: For the following structures, be able to differentiate between left and right halves when applicable.

### Muscles of the Head and Neck

#1 epicranial aponeurosis	#7 nasalis	#13 zygomaticus minor	#19 sternocleidomastoid
#2 front belly of occipitofrontalis	#8 orbicularis oculi	#14 zygomaticus major	#20 platysma
#3 occipital belly of occipitofrontalis	#9 levator labii superioris	#15 buccinator	#21 sternohyoid
#4 temporalis	#10 levator anguli oris	#16 risorius	#22 scalenes
#5 auricularis superior	#11 depressor anguli oris	#17 orbicularis oris	
#6 procerus	#12 depressor labii inferioris	#18 mentalis	

### Muscles of the Eye

#23 levator palpebrae superioris	#25 medial rectus	#27 inferior recuts	#29 superior oblique
#24 lateral recuts	#26 superior rectus	#28 inferior oblique	#30 trochlea

## Muscles of the Arms

#31 deltoid	#33 clavicular part of deltoid	#35 coracobrachialis	#37 biceps brachii	#39 brachioradialis
#32 acromial part of deltoid	#34 spinal part of deltoid	#36 triceps brachii	#38 brachialis	#40 extensor digitorum

## Station Two: Muscles of the Back and Abdomen

Label the models of this station with the number that corresponds to the appropriate structure of the peripheral nervous system using the colored tape. When you are finished, ask your TA to check your labeling. Before leaving the station, remove all the labels you have placed on the model.

Note: For the following structures, be able to differentiate between left and right halves when applicable.

#1 trapezius	#7 teres major	#13 pectoralis minor	#19 internal intercostals
#2 levator scapulae	#8 teres minor	#14 serratus anterior	#20 external intercostals
#3 splenius capitis	#9 rhomboid major	#15 rectus abdominis	#21 diaphragm
#4 supraspinatus	#10 rhomboid minor	#16 external oblique	
#5 infraspinatus	#11 latissimus dorsi	#17 internal oblique	
#6 subscapularis	#12 pectoralis major	#18 transversus abdominis	

## Station Three: Muscles of the Lower Body


Label the models of this station with the number that corresponds to the appropriate structure of the peripheral nervous system using the colored tape. When you are finished, ask your TA to check your labeling. Before leaving the station, remove all the labels you have placed on the model.

Note: For the following structures, be able to differentiate between left and right halves when applicable.


#1 gluteus maximus	#7 vastus lateralis	#13 gracilis	#19 extensor digitorum longus
#2 gluteus medius	#8 vastus intermedius	#14 adductor longus	#20 fibularis longus
#3 gluteus minimus	#9 hamstrings	#15 pectineus	#21 tibialis anterior
#4 quadriceps	#10 biceps femoris	#16 sartorius	#22 flexor digitorum longus
#5 rectus femoris	#11 semitendinosus	#17 gastrocnemius	#23 tibialis posterior
#6 vastus medialis	#12 semimembranosus	#18 soleus	

## Station Four: Histology – Muscle

Sketch the slides available for today's lab and specify the magnitude at which you are observing/ sketching. Be sure to identify and label your sketch with the corresponding structures listed beneath each slide.



**Striated muscle**




**Cardiac muscle**  
Intercalated discs

---


## Station Five: Histology – Integumentary

Sketch the slides available for today's lab and specify the magnitude at which you are observing/ sketching. Be sure to identify and label your sketch with the corresponding structures listed beneath each slide.

---




**Skin of palm**  
Epidermis, Dermis, Papillary layer, Reticular layer



**Human scalp w/hair follicle**  
Epidermis, Dermis, Arrector pili muscle, Sebaceous gland, Dermal papilla, Hair follicle, Hair bulb

---



**Squamous epithelium**

## Station Six: Integumentary

Label the models of this station with the number that corresponds to the appropriate structure of the peripheral nervous system using the colored tape. When you are finished, ask your TA to check your labeling. Before leaving the station, remove all the labels you have placed on the model.

### Skin

#1 epidermis	#5 stratum spinosum	#9 papillary layer	#13 hypodermis superficial fascia
#2 stratum corneum	#6 stratum basale	#10 reticular layer	#14 lamellated corpuscles
#3 stratum lucidum	#7 epidermal ridges	#11 dermal papillae	#15 thin (hairy) skin
#4 stratum granulosum	#8 dermis	#12 subcutaneous layer (Hypodermis)	#16 thick (hairless) skin

#17 squamous epithelium
-------------------------

### Hair

#18 pili	#20 hair root	#22 bulb
#19 hair shaft	#21 hair follicle	#23 arrector pili muscles

### Glands

#24 sebaceous	#26 eccrine sweat	#28 ceruminous
#25 sudoriferous	#27 apocrine	

### Nail

#29 nail body (nail plate)	#31 lunula	#33 nail bed
#30 free edge	#32 eponychium (cuticle)	



## 34. Post-Lab 10 Questions

**(2 points)**

Last Name: \_\_\_\_\_ First Name: \_\_\_\_\_

1. What muscles, in the dermis are responsible for erecting hair follicles? (0.5 points)
2. While examining a patient's eye, a doctor instructs them to move their right eye upward, to the left. Which muscles of the eye were utilized to perform this task? (0.5 points)
3. What muscle of the cervical region has two origins? (0.5 points)
4. What is the primary muscle used for normal breathing? Which additional muscles are utilized to increase inspiration and expiration during strenuous exercise? (0.5 points)



PART XI  
VOCABULARY



# 35. Vocabulary

## Anatomical Language

1. Frontal (coronal)
2. Transverse
3. Sagittal
4. Anterior (Ventral)
5. Posterior (Dorsal)
6. Proximal
7. Distal
8. Superior
9. Inferior
10. Lateral
11. Medial
12. Deep
13. Superficial
14. Parietal
15. Visceral
16. Cephalic
17. Cranial
18. Ocular (orbital)
19. Auricular (Otic)
20. Buccal
21. Nasal
22. Oral
23. Cervical
24. Acromial
25. Scapular
26. Brachial
27. Cubital
28. Antecubital
29. Olecranal
30. Antebrachial
31. Carpal (carpus)
32. Palmar
33. Digital (phalangeal)
34. Thoracic
35. Mammary
36. Abdominal

37. Hepatic
38. Renal
39. Umbilical
40. Lumbar
41. Pelvic
42. Inguinal
43. Pubic
44. Sacral
45. Gluteal
46. Femoral
47. Patellar
48. Popliteal
49. Crural
50. Sural
51. Tarsal (tarsus)
52. Calcaneal
53. Pedal
54. Plantar
55. Right hypochondriac region
56. Epigastric region
57. Left hypochondriac region
58. Right lumbar region
59. Umbilical region
60. Left lumbar region
61. Right iliac region
62. Hypogastric region
63. Left iliac region
64. Process
65. Tuberosity
66. Condyle
67. Epicondyle
68. Fissure
69. Sulcus
70. Gyrus
71. Foramen
72. Foramina
73. Meatus
74. Facet
75. Fossa
76. Fundus
77. Hilum
78. Isthmus
79. Septum
80. Raphe
81. Ampulla

## Bones and Bone Markings

1. Compact bone
2. Osteon
3. Lamellae
4. Lacunae
5. Volkmann's canal
6. Haversian (Central) canal
7. Spongy bone
8. Ground bone
9. Axial skeleton
10. Skull
11. Frontal bone
12. Parietal bone
13. Temporal bone
14. External auditory meatus
15. Mastoid process
16. Styloid process
17. Occipital bone
18. External occipital protuberance
19. Ethmoid bone
20. Cribriform plate
21. Olfactory foramina
22. Sphenoid bone
23. Zygomatic bone (arch)
24. Zygomatic process of temporal bone
25. Temporal process of zygomatic bone
26. Palatine bone
27. Nasal bone
28. Vomer
29. Lacrimal bone
30. Superior nasal conchae
31. Middle nasal conchae
32. Inferior nasal conchae
33. Mandible
34. Maxilla
35. Hyoid bone
36. Foramen magnum
37. Jugular foramen

38. Foramen Ovale
39. Sella Turcica
40. Coronal suture
41. Sagittal suture
42. Lambdoid suture
43. Vertebrae
44. Body of vertebra
45. Vertebral foramen
46. Lamina
47. Spinous process
48. Transverse process
49. Superior articular process
50. Inferior articular process
51. Facet of the superior articular process
52. Facet of the inferior articular process
53. Cervical region
54. Bifid spinous process
55. Transverse foramen
56. Atlas
57. Axis
58. Dens
59. Thoracic region
60. Lumbar region
61. Sacrum
62. Coccyx
63. Intervertebral foramen
64. Intervertebral disc
65. Sternum
66. Manubrium
67. Sternal body
68. Xiphoid Process
69. Ribs
70. Costal cartilage
71. Appendicular Skeleton
72. Clavicle
73. Acromial end of clavicle
74. Sternal end of clavicle
75. Scapula
76. Glenoid cavity
77. Spine of scapula
78. Acromion
79. Coracoid process
80. Supraspinous fossa
81. Infraspinatus fossa
82. Subscapular fossa
83. Humerus



84. Humeral head
85. Neck of humerus
86. Greater tubercle
87. Lesser tubercle
88. Trochlea
89. Capitulum
90. Coronoid fossa
91. Radial fossa
92. Medial epicondyle
93. Lateral epicondyle
94. Olecranon fossa
95. Ulna
96. Ulnar head
97. Olecranon
98. Trochlear notch
99. Coracoid process
100. Radial notch
101. Styloid process of ulna
102. Radius
103. Radial head
104. Neck of radius
105. Radial tuberosity
106. Styloid process of radius
107. Carpals
108. Metacarpals
109. Phalanges
110. Distal phalanges
111. Middle phalanges
112. Proximal phalanges
113. Ilium
114. Iliac crest
115. Ischium
116. Ischial spine
117. Pubis
118. Pubic symphysis
119. Acetabulum
120. Femur
121. Femoral head
122. Neck of femur
123. Greater trochanter
124. Lesser trochanter
125. Medial epicondyle
126. Lateral epicondyle
127. Lateral condyle
128. Medial condyle
129. Intercondylar fossa

130. Patella
131. Tibia
132. Lateral condyle
133. Medial condyle
134. Medial malleolus
135. Fibula
136. Fibular head
137. Lateral malleolus
138. Tarsals
139. Calcaneus
140. Metatarsals
141. Phalanges

## Brain and Cranial Nerves

1. Brain
2. Grey matter
3. White matter
4. Gyrus (convulsions)
5. Fissure
6. Sulci
7. Precentral gyrus
8. Postcentral gyrus
9. Lateral cerebral sulcus
10. Central sulcus
11. Parieto-occipital sulcus
12. Transverse fissure
13. Longitudinal fissure
14. Dura mater
15. Falx cerebri
16. Falx cerebelli
17. Tentorium cerebelli
18. Arachnoid mater
19. Pia mater
20. Septum pellucidum
21. Lateral ventricles
22. Interventricular foramen
23. Third ventricles
24. Cerebral aqueduct (aqueduct of midbrain)

25. Fourth ventricles
26. Cerebrospinal fluid (CSF)
27. Choroid plexuses
28. Cerebrum
29. Cerebral cortex
30. Frontal lobe
31. Temporal lobe
32. Parietal lobe
33. Occipital lobe
34. Insula
35. Basal Nuclei
36. Corpus Callosum
37. Fornix
38. Cingulate gyrus
39. Cerebellum
40. Cerebellar peduncles
41. Vermis
42. Folia
43. Arbor vitae
44. Brainstem
45. Pons
46. Medulla oblongata
47. Midbrain
48. Cerebral peduncles
49. Tectum (Corpora quadrigemina) (Superior and inferior colliculi)
50. Diencephalon
51. Thalamus
52. Epithalamus
53. Pineal gland
54. Hypothalamus
55. Pituitary gland
56. Infundibulum
57. Optic chiasm
58. Mammillary bodies
59. Olfactory nerve (I)
60. Optic nerve (II)
61. Oculomotor nerve (III)
62. Trochlear nerve (IV)
63. Trigeminal nerve (V)
64. Abducens nerve (VI)
65. Facial nerve (VII)
66. Acoustic/Vestibulocochlear nerve (VIII)
67. Glossopharyngeal nerves (IX)
68. Vagus nerve (X)
69. Accessory/Spinal nerve (XI)
70. Hypoglossal nerve (XII)

# Cardiovascular System

1. Artery
2. Vein
3. Blood
4. Erythrocytes
5. Leukocytes
6. Granular leukocytes
7. Neutrophils
8. Eosinophils
9. Basophils
10. Agranular leukocytes
11. Monocytes
12. Lymphocytes
13. Thrombocytes
14. Cardiac muscle
15. Intercalated discs
16. Striated
17. Apex
18. Base
19. Auricles
20. Anterior interventricular sulcus
21. Posterior interventricular sulcus
22. Coronary sulcus
23. Pericardium
24. Epicardium
25. Myocardium
26. Endocardium
27. L/R atria
28. Pectinate muscles
29. Interatrial septum
30. L/R ventricles
31. Interventricular septum
32. Papillary muscles
33. Chordae tendineae
34. Trabeculae carneae
35. Atrioventricular valves
36. Tricuspid valves
37. Bicuspid valves

38. Semilunar valves
39. Pulmonary valves
40. Aortic Valves
41. Epicardial fat
42. Coronary circulation
43. Coronary arteries
44. Anterior interventricular branch
45. Circumflex branch
46. Right coronary artery
47. Posterior interventricular branch
48. Marginal branch
49. Cardiac vein
50. Great cardiac vein
51. Middle cardiac vein
52. Small cardiac vein
53. Anterior cardiac veins
54. Coronary sinus
55. Pulmonary circulation
56. Pulmonary trunk
57. L/R pulmonary arteries
58. Pulmonary capillaries
59. Pulmonary veins
60. Anastomoses
61. Systemic circulation
62. Ascending aorta
63. Arch of aorta
64. Descending aorta
65. Brachiocephalic trunk
66. L/R common carotid arteries
67. L/R internal carotid arteries
68. L/R external carotid arteries
69. L/R subclavian arteries
70. L/R vertebral arteries
71. Basilar artery
72. Circle of Willis
73. Posterior cerebral artery
74. Posterior communicating artery
75. Middle cerebral
76. Anterior cerebral artery
77. Anterior communicating artery
78. L/R Axillary arteries
79. L/R Radial arteries
80. L/R Ulnar arteries
81. Thoracic aorta
82. Abdominal aorta
83. L/R suprarenal arteries

84. L/R renal arteries
85. L/R gonadal arteries
86. Inferior mesenteric artery
87. Superior mesenteric artery
88. Celiac trunk
89. Common hepatic artery
90. Splenic artery
91. Lumbar arteries (4 pairs, R/L)
92. L/R common iliac arteries
93. L/R external iliac arteries
94. L/R internal iliac arteries
95. L/R femoral arteries
96. L/R deep femoral arteries
97. L/R popliteal arteries
98. L/R anterior tibial arteries
99. L/R posterior tibial arteries
100. L/R fibular artery
101. Superior vena cava
102. Inferior vena cava
103. L/R brachiocephalic veins
104. L/R internal jugular veins
105. L/R subclavian veins
106. L/R external jugular veins
107. L/R axillary veins
108. L/R brachial veins
109. L/R cephalic veins
110. L/R basilic veins
111. L/R median cubital veins
112. L/R radial veins
113. L/R ulnar veins
114. L/R median antebrachial veins
115. Azygos vein
116. Hemiazygos vein
117. Accessory Hemiazygos vein
118. L/R ascending Lumbar veins
119. L/R gonadal veins
120. L/R renal veins
121. L/R suprarenal veins
122. L/R hepatic veins
123. Hepatic portal vein
124. Inferior mesenteric vein
125. Splenic vein
126. Superior mesenteric vein
127. Inferior phrenic vein
128. L/R common iliac veins
129. L/R internal iliac veins

130. L/R external iliac veins
131. L/R femoral veins
132. L/R great Saphenous veins
133. L/R popliteal veins
134. L/R small Saphenous veins
135. L/R anterior tibial veins
136. L/R fibular veins

## Digestive System

1. Mouth
2. Labial frenulum
3. Fauces
4. Hard palate
5. Soft palate
6. Uvula
7. Tongue
8. Lingual frenulum
9. Fungiform papillae
10. Filiform papillae
11. Circumvallate papillae
12. Tastebud
13. Taste pore
14. Teeth
15. Incisor
16. Canine
17. Premolar
18. Molar
19. Crown
20. Neck
21. Root
22. Enamel
23. Dentin
24. Pulp cavity
25. Pulp
26. Apical foramen
27. Cementum
28. Periodontal ligament
29. Gingiva

30. Salivary glands
31. Submandibular gland
32. Parotid gland
33. Sublingual gland
34. Esophagus
35. Upper esophageal sphincter
36. Lower esophageal sphincter
37. Stomach
38. Gastric pits
39. Gastric glands
40. Fundus
41. Cardia
42. Gastric body
43. Rugae
44. Pylorus
45. Pyloric sphincter
46. Longitudinal muscle layer
47. Circular muscle layer
48. Oblique muscle layer
49. Liver
50. Right lobe of liver
51. Left lobe of liver
52. Right hepatic duct
53. Left hepatic duct
54. Common hepatic duct
55. Hepatic lobule
56. Hepatic canaliculi
57. Falciform ligament
58. Gallbladder
59. Fundus of gallbladder
60. Body of gallbladder
61. Neck of gallbladder
62. Cystic duct
63. Common bile duct
64. Pancreas
65. Exocrine cells
66. Acinar cells
67. Endocrine cells
68. Islets of Langerhan
69. Pancreatic tail
70. Pancreatic head
71. Pancreatic body
72. Uncinate process
73. Accessory duct
74. Pancreatic duct
75. Small Intestine



76. Microvilli
77. Vili
78. Mucosa
79. Submucosa
80. Muscularis
81. Serosa
82. Enterocytes
83. Plicae circulares (circular folds)
84. Duodenum
85. Ampulla of Vater
86. Sphincter of Oddi
87. Jejunum
88. Ileum
89. Ileocecal valve
90. Large Intestine
91. Crypts
92. Mucosa
93. Submucosa
94. Muscularis
95. Serosa
96. Cecum
97. Vermiform appendix
98. Ascending colon
99. Right colic flexure
100. Transverse colon
101. Left colic flexure
102. Descending colon
103. Sigmoid colon
104. Teniae coli
105. Haustra
106. Epiploic (omental) appendices
107. Rectum
108. Anal canal
109. Anal sphincter
110. Anus
111. Peritoneum
112. Mesentery of transverse colon
113. Greater omentum
114. Lesser omentum
115. Mesoappendix

# Integumentary System

1. Skin
2. Epidermis
3. Stratum corneum
4. Stratum lucidum
5. Stratum granulosum
6. Stratum spinosum
7. Stratum basale
8. Epidermal ridges
9. Dermis
10. Papillary layer
11. Reticular layer
12. Dermal Papillae
13. Subcutaneous layer (Hypodermis)
14. Hypodermis superficial fascia
15. Lamellated corpuscles
16. Thin (hairy) skin
17. Thick (hairless) skin
18. Hair (pili)
19. Hair shaft
20. Hair root
21. Hair follicle
22. Bulb
23. Arrector pili muscles
24. Sebaceous gland
25. Sudoriferous glands
26. Eccrine sweat gland
27. Apocrine sweat gland
28. Ceruminous gland
29. Nail
30. Nail body (nail plate)
31. Free edge
32. Lunula
33. Eponychium (cuticle)
34. Nail bed
35. Squamous epithelium

# Muscular System

1. Striated muscle
2. Skeletal muscle
3. Cardiac muscle
4. Intercalated discs
5. Smooth muscle
6. Epicranial aponeurosis
7. Front belly of Occipitofrontalis
8. Occipital belly of Occipitofrontalis
9. Temporalis
10. Auricularis Superior
11. Orbicularis Oculi
12. Levator palpebrae superioris
13. Lateral rectus
14. Medial rectus
15. Superior rectus
16. Inferior rectus
17. Inferior oblique
18. Superior oblique
19. Trochlea
20. Procerus
21. Nasalis
22. Levator labii superioris
23. Levator anguli oris
24. Depressor anguli oris
25. Depressor labii inferioris
26. Zygomaticus minor
27. Zygomaticus major
28. Buccinator
29. Risorius
30. Orbicularis oris
31. Mentalis
32. Sternocleidomastoids
33. Scalenes
34. Platysma
35. Sternohyoid muscle
36. Deltoid
37. Acromial part of deltoid
38. Clavicular part of deltoid
39. Spinal part of deltoid
40. Coracobrachialis
41. Triceps brachii

42. Biceps brachii
43. Brachialis
44. Brachioradialis
45. Extensor digitorum
46. Trapezius
47. Levator scapulae
48. Splenius Capitis
49. Splenius cervicis
50. Supraspinatus
51. Infraspinatus
52. Subscapularis
53. Teres minor
54. Teres major
55. Rhomboid major
56. Rhomboid minor
57. Latissimus dorsi
58. Pectoralis minor
59. Pectoralis major
60. Serratus anterior
61. Rectus abdominis
62. External oblique
63. Internal oblique
64. Transversus abdominis
65. Internal intercostals
66. External intercostals
67. Transversus thoracis
68. Serratus posterior
69. Diaphragm
70. Gluteus maximus
71. Gluteus medius
72. Gluteus minimus
73. Quadriceps
74. Rectus femoris
75. Vastus medialis
76. Vastus lateralis
77. Vastus intermedius
78. Hamstrings
79. Biceps femoris
80. Semitendinosus
81. Semimembranosus
82. Gracilis
83. Adductor longus
84. Pectineus
85. Sartorius
86. Gastrocnemius
87. Soleus

88. Extensor digitorum longus
89. Fibularis longus
90. Tibialis anterior
91. Flexor digitorum longus
92. Tibialis posterior
93. Masseter
94. Hyoglossus
95. Styloglossus
96. Palatoglossus
97. Pharyngeal muscles
98. Superior constrictor
99. Middle constrictor
100. Inferior constrictor

## Reproductive System

### MALE

1. Pubic symphysis
2. Dartos muscle
3. Cremaster muscle
4. Scrotum
5. Scrotal septum
6. Testis
7. Lobules
8. Leydig cells
9. Sertoli cells
10. Sperm
11. Head of sperm
12. Midpiece of sperm
13. Tail of sperm
14. Seminiferous tubules
15. Straight tubule
16. Rete testis
17. Epididymis
18. Ductus (Vas) deferens
19. Ampulla of ductus deferens

20. Prostate
21. Seminal Vesicles
22. Bulbourethral (Cowper's) glands
23. Ejaculatory ducts
24. Prostatic urethra
25. Intermediate Urethra
26. Spongy urethra
27. Penis
28. Corpus cavernosum
29. Corpus spongiosum
30. Glans penis
31. Prepuce of penis
32. External urethral orifice
33. Root of Penis
34. Bulb of Penis
35. Crus of Penis
36. Suspensory Ligament of Penis
37. Spermatic cord
38. Deep muscle of perineum

## FEMALE

1. Pubic symphysis
2. Placenta
3. Ovary
4. Ova
5. Mature (Graafian) follicle
6. Ovarian ligament
7. Uterine (Fallopian) tube
8. Fimbriae of uterine tube
9. Infundibulum of uterine tube
10. Ampulla of uterine tube
11. Isthmus of uterine tube
12. Broad ligament
13. Round ligament
14. Uterosacral ligament
15. Uterus
16. Endometrium
17. Myometrium
18. Perimetrium
19. Uterine cavity
20. Fundus of uterus

21. Body of uterus
22. Isthmus
23. Cervix
24. external os
25. internal os
26. Vagina
27. Fornix
28. Rugae
29. Vaginal orifice
30. Mons pubis
31. Vulva
32. Labia majora
33. Labia minora
34. Vestibule
35. Clitoris
36. External urethral orifice
37. Vestibular glands
38. Breast
39. Areola
40. Nipple
41. Mammary glands
42. Lobule
43. Lactiferous ducts
44. Lactiferous sinus
45. Mammary ducts
46. Mammary alveoli

## Respiratory System

1. Nose
2. Root
3. Bridge
4. Apex
5. Lateral nasal cartilages
6. Septal nasal cartilage
7. Major alar cartilages
8. Minor cartilages
9. External naris (nostril)
10. Nasal cavity

11. Nasal Conchae (Superior, Middle, Inferior)
12. Nasal Meatuses (Superior, Middle, Inferior)
13. Pharynx
14. Nasopharynx
15. Oropharynx
16. Laryngopharynx
17. Lingual tonsils
18. Palatine tonsils
19. Pharyngeal tonsil (adenoid)
20. Hard palate
21. Soft palate
22. Uvula
23. Larynx
24. Epiglottis
25. Vestibular folds
26. Vocal folds
27. Thyrohyoid membrane
28. Thyroid cartilage
29. Arytenoid cartilages
30. Corniculate cartilages
31. Cuneiform cartilage
32. Cricothyroid ligament
33. Cricoid cartilage
34. Cricotracheal ligament
35. Tracheal cartilages
36. Trachea
37. Esophagus
38. Carina
39. Primary (main) bronchi
40. Secondary (lobar) bronchi
41. Tertiary (segmental) bronchi
42. Terminal Bronchioles
43. Respiratory Bronchioles
44. Alveolar ducts
45. Alveolar sacs
46. Alveoli
47. L/R lungs
48. Apex of lung
49. Base of lung
50. Superior lobe
51. Inferior lobe
52. Middle lobe
53. Cardiac notch
54. Horizontal fissure
55. Oblique fissure
56. Hilum



57. Primary muscles of inhalation
58. Diaphragm
59. External intercostal muscles
60. Accessory muscle of inhalation
61. Scalenes
62. Sternocleidomastoid
63. Muscles of exhalation
64. Internal intercostal muscles
65. External oblique
66. Internal oblique
67. Transverse abdominis
68. Rectus abdominis
69. Pulmonary circulation
70. Pulmonary trunk
71. Pulmonary arteries
72. Pulmonary capillaries
73. Pulmonary veins

## Special Senses

1. Eye
2. Palpebral conjunctiva
3. Bulbar conjunctiva
4. Fibrous tunic
5. Sclera
6. Cornea
7. Vascular tunic
8. Iris
9. Pupil
10. Lens
11. Choroid
12. Ciliary body
13. Neural tunic
14. Retina
15. Pigmented layer
16. Neural layer
17. Optic disc
18. Macula lutea
19. Fovea centralis

20. Rods
21. Cones
22. Bipolar cells
23. Horizontal cells
24. Ganglion cells
25. Optic nerve (CN II)
26. Optic chiasm
27. Optic tract
28. Primary visual area
29. Anterior chamber
30. Aqueous humor
31. Posterior chamber
32. Vitreous humor (vitreous body)
33. Superior rectus
34. Inferior rectus
35. Lateral rectus
36. Medial Rectus
37. Superior oblique
38. Inferior oblique
39. Levator palpebrae superioris
40. Lacrimal apparatus
41. Lacrimal gland
42. Lacrimal puncta
43. Superior lacrimal canaliculi
44. Inferior lacrimal canaliculi
45. Lacrimal sac
46. Nasolacrimal duct
47. Outer ear
48. Middle ear
49. Inner ear
50. Auricle (pinna)
51. Helix
52. Lobule
53. External auditory meatus
54. External auditory canal
55. Ceruminous glands
56. Tympanic membrane
57. Auditory ossicles
58. Malleus
59. Incus
60. Stapes
61. Eustachian tube
62. Oval window
63. Round window
64. Bony labyrinth
65. Semicircular canals

66. Vestibule
67. Cochlea
68. Vestibulocochlear nerve (CN VIII)
69. Membranous labyrinth
70. Semicircular ducts
71. Utricle
72. Saccule
73. Organ of Corti
74. Primary auditory area
75. Superior nasal conchae
76. Middle nasal conchae
77. Inferior nasal conchae
78. Superior nasal meatus
79. Middle nasal meatus
80. Inferior nasal meatus
81. Olfactory epithelium
82. Olfactory glands
83. Cribriform plate of the ethmoid bone
84. Olfactory foramina
85. Olfactory receptors
86. Olfactory nerve (CN I)
87. Olfactory bulb
88. Olfactory tract
89. Primary olfactory area
90. Tongue
91. Lingual tonsils
92. Palatine tonsils
93. Lingual papillae
94. Fungiform papillae
95. Filiform papillae
96. Foliate papillae
97. Circumvallate papillae
98. Taste bud
99. Taste pore
100. Facial nerve (CN VII)
101. Glossopharyngeal nerve (CN IX)
102. Vagus nerve (CN X)
103. Thalamus
104. Primary gustatory area

# Spinal Cord and Spinal Nerves

1. Spinal cord
2. Sympathetic ganglion
3. Vertebral column
4. Spinal meninges
5. Dura mater
6. Arachnoid mater
7. Pia mater
8. Denticulate ligaments
9. Subarachnoid space
10. Subdural space
11. Epidural space
12. Cervical innervation segment
13. Thoracic innervation segment
14. Lumbar innervation segment
15. Sacral innervation segment
16. Cervical enlargement
17. Lumbar enlargement
18. Conus medullaris
19. Filum terminale
20. Cauda equina
21. Anterior median fissure
22. Posterior median sulcus
23. Lateral white columns
24. Anterior white columns
25. Posterior white columns
26. Posterior gray horns
27. Anterior gray horns
28. Lateral gray horns
29. Posterior gray commissure
30. Anterior white commissure
31. Central canal
32. Cerebrospinal fluid (CSF)
33. Cranial nerves
34. Thoracic nerves
35. Lumbar nerves
36. Sacral nerves
37. Coccygeal nerve
38. Cervical plexus
39. Lesser occipital nerve
40. Great auricular nerve
41. Transverse cervical nerve

42. Supraclavicular
43. Superior root of Ansa cervicalis nerve
44. Inferior root of Ansa cervicalis nerve
45. Phrenic nerve
46. Segmental branches
47. Brachial plexus
48. Dorsal scapular nerve
49. Long thoracic nerve
50. Nerve to subclavius
51. Suprascapular nerve
52. Musculocutaneous nerve
53. Lateral pectoral nerve
54. Upper subscapular nerve
55. Thoracodorsal nerve
56. Lower subscapular nerve
57. Axillary nerve
58. Median nerve
59. Radial nerve
60. Medial pectoral nerve
61. Medial cutaneous nerve of arm
62. Medial cutaneous nerve of forearm
63. Ulnar nerve
64. Lumbar plexus
65. Iliohypogastric nerve
66. Ilioinguinal nerve
67. Genitofemoral nerve
68. Lateral cutaneous nerve of thigh
69. Femoral nerve
70. Obturator nerve
71. Sacral plexus
72. Superior gluteal nerve
73. Inferior gluteal nerve
74. Nerve to piriformis
75. Nerve to quadratus
76. Nerve to obturator internus and superior gemellus
77. Perforating cutaneous nerve
78. Posterior cutaneous nerve of thigh
79. Pudendal nerve
80. Sciatic nerve
81. Tibial, median plantar nerve
82. Tibial, lateral plantar nerve
83. Superficial common fibular nerve
84. Deep common fibular nerve

# Urinary System

1. L/R kidneys
2. Renal fascia
3. Adipose capsule
4. Renal capsule
5. Renal cortex
6. Renal medulla
7. Renal lobe
8. Renal pyramid
9. Renal columns
10. Renal papilla
11. Renal sinus
12. Renal pelvis
13. Renal hilum
14. Renal artery
15. Segmental arteries
16. Interlobar arteries
17. Arcuate arteries
18. Cortical radiate arteries
19. Afferent arterioles
20. Glomerular capillaries
21. Efferent arterioles
22. Peritubular capillaries
23. Cortical radiate veins
24. Arcuate veins
25. Interlobar veins
26. Renal vein
27. Ureter
28. Urinary bladder
29. Detrusor muscle
30. Rugae
31. Urinary trigone
32. Internal urethral sphincter
33. External Urethral sphincter
34. Urethra
35. External urethral orifice
36. Nephron
37. Cortical nephron
38. Juxtamedullary nephron
39. Juxtaglomerular apparatus
40. Renal corpuscle
41. Glomerulus

42. Podocyte
43. Bowman's capsule
44. Capsular space (Bowman's space)
45. Renal tubules
46. Proximal convoluted tubule
47. Descending loop of Henle
48. Ascending loop of Henle
49. Distal convoluted tubules
50. Collecting duct
51. Papillary duct
52. Minor calyx
53. Major calyx





# Image Credits

Images are individually licensed as noted below.

## Lab 1

“Planes of body” by OpenStax College is licensed under CC BY 3.0.

“Abdominal Quadrant Regions” by OpenStax College is licensed under CC BY 3.0.

“Directional Terms” by OpenStax College is licensed under CC BY 3.0.

“Regions of Human Body” by OpenStax College is licensed under CC BY 4.0.

“1916 Leukocyte Key” by OpenStax College is licensed under CC by 3.0.

“Compact bone” by Lord of Konrad is in the public domain. It was accessed via Wikimedia Commons.

“1313 Spinal Cord Cross Section” by OpenStax College is licensed under CC BY 4.0.

“Renal corpuscle” by Ed Uthman is licensed under CC BY-SA 2.0.

## Lab 2

“705 Lateral View of Skull-01” by OpenStax College is licensed under CC BY 3.0.

“707 Superior-Inferior View of Skull Base-01” by OpenStax College is licensed under CC BY 3.1.

“Vertebra Superior View” by BodyParts3D/Anatomography is licensed under CC BY-SA 3.0.

“Right scapula – close-up – anterior view” by Anatomography is licensed under CC BY-SA 2.1 JP.

“Right scapula – close-up – posterior view” by Anatomography is licensed under CC BY-SA 2.1 JP.

“804 Humerus and Elbow” by OpenStax College is licensed under CC BY 3.0.

“805 Ulna and Radius” by OpenStax College is licensed under CC BY 3.0.

“810 Femur and Patella” by OpenStax College is licensed under CC BY 3.0.

“811 Tibia and fibula” by OpenStax College is licensed under CC BY 3.0.

## Lab 3

N/A

## Lab 4

“1306 Lobes of Cerebral CortexN” by OpenStax College is licensed under CC BY 4.0.

“PSM V46 D168 Mesial view of the human brain” is in the public domain. It was accessed via Wikimedia Commons.

“Blausen 0896 Ventricles Brain” by BruceBlaus is licensed under a CC BY 3.0 Unported license.

“1320 The Cranial Nerves” by OpenStax College is licensed under CC BY 4.0.

## Lab 5

“1402 The Tongue” by OpenStax College is licensed under CC BY 4.0.

“1403 Olfaction” by OpenStax College is licensed under CC BY 4.0.

“1404 The Structures of the Ear” by OpenStax College is licensed under CC BY 4.0.

“1412 Extraocular Muscles” by OpenStax College is licensed under CC BY 3.0.

“1413 Structure of the Eye” by OpenStax College is licensed under CC BY 3.0.

## Lab 6

N/A

## Lab 7

“2014ab Coronary Blood Vessels” by OpenStax is licensed under CC BY 3.0.

“2008 Internal Anatomy of the HeartN” by OpenStax is licensed under CC BY 3.0.

“2005 Surface Anatomy of the Heart” by OpenStax is licensed under CC BY 3.0.

“2120 Major Systemic Artery” by OpenStax is licensed under CC BY 3.0.

“2131 Major Systemic Veins” by OpenStax is licensed under CC BY 3.0.

## Lab 8

“2401 Components of the Digestive System” by OpenStax is licensed under CC BY 3.0.

“2402 Layers of the Gastrointestinal Tract” by OpenStax is licensed under CC BY 3.0.

“2406 Structures of the Mouth” by OpenStax is licensed under CC BY 3.0.

“2408 Salivary Glands” by OpenStax is licensed under CC BY 3.0.

“2414 Stomach” by OpenStax is licensed under CC BY 3.0 .

“Liver Gallbladder SI” by Andrea Campo-Velez is licensed under CC BY-SA 4.0.

“Blausen 0604 LargeIntestine2” by OpenStax is licensed under CC BY 3.0.

## Lab 9

“2610 The Kidney” by OpenStax is licensed under CC BY 3.0.

“2611 Blood Flow in the Nephron” by OpenStax is licensed under CC BY 3.0.

“2605 The Bladder” by OpenStax is licensed under CC BY 3.0.

“Figure 28 01 01” by OpenStax is licensed under CC BY 3.0.

“Image from page 1340 of ‘Cunningham’s Text -book of anatomy’ (1914)” is in the public domain. It was accessed via the Internet Archive Book Images Flickr.

“Image from ‘Anatomy of the Human Body’ (1918)” is in the public domain. It was accessed via Wikimedia Commons.

“Figure 28 02 01” by OpenStax is licensed under CC BY 3.0.

“Figure 28 02 09” by OpenStax is licensed under CC BY 3.0.

## Lab 10

“1105 Anterior and Posterior View of Muscles” by OpenStax is licensed under CC BY 4.0.

“1106 Front and Side Views of the Muscles of Facial Expressions” by OpenStax is licensed under CC BY 4.0.

“1107 The Extrinsic Eye Muscles” by OpenStax is licensed under CC BY 4.0.

“1112 Muscles of the Abdomen” by OpenStax is licensed under CC BY 4.0 .

“1123 Muscles of the Leg that Move the Foot and Toes” by OpenStax is licensed under CC BY 4.0.

“502 Layers of epidermis” by OpenStax is licensed under CC BY 3.0.

“501 Structure of the skin” by OpenStax is licensed under CC BY 3.0.

# Links by Chapter

## Front Matter

Mavs Open Press (<https://library.uta.edu/scholcomm/mavs-open-press>)

Creative Commons licenses (<https://creativecommons.org/licenses/>)

OER (<https://library.uta.edu/scholcomm/open-education/oer>)

Pressbooks Accessibility Policy (<https://pressbooks.org/blog/2018/05/01/our-accessibility-policy-and-forthcoming-accessibility-improvements>)

Open Education at UTA (<http://libguides.uta.edu/utacares>)

OER Adoption Form ([https://uta.qualtrics.com/jfe/form/SV\\_8HTkgCym5Q6Mk7j](https://uta.qualtrics.com/jfe/form/SV_8HTkgCym5Q6Mk7j))

BCcampus Open Education (<https://open.bccampus.ca/>)

# Accessibility Rubric

MAVS OPEN PRESS

## **Evaluation in progress**

Web version evaluated on DATE

Accessibility Standards Passed – XX/10

Evaluation Criteria	Pass/ Fail	Additional Information
Accessibility Documentation:		
<ol style="list-style-type: none"> <li>The organization providing materials has a formal accessibility policy.</li> <li>The organization providing materials has an accessibility statement.</li> </ol>	Pass	Accessibility statement is present in the front matter.
Content Organization:		
<ol style="list-style-type: none"> <li>Chapter titles and section headers should be marked as headers and distinct from body text.</li> <li>Table of contents should be present and allow navigation.</li> <li>Page numbers should be present and correspond with print numbers.</li> <li>Content should remain organized after user 'reflows' page.</li> </ol>	Pass	Chapter organization and headers marked clearly.
Images:		
<ol style="list-style-type: none"> <li>Non-decorative images should be marked with alternative text.</li> <li>Images should be compatible with screen reader and magnification software.</li> <li>Decorative images should be marked with null alternative text.</li> </ol>	Pass	All images marked with alternative text.
Tables:		
<ol style="list-style-type: none"> <li>Tables should be simple and compatible with screen readers and magnification software.</li> <li>Tables should be single celled and contain ordered lists.</li> <li>Tables should include markup that identify their rows and columns.</li> </ol>	Pass	
Hyperlinks:		
<ol style="list-style-type: none"> <li>In-book links should function and connect to their correct location in the text.</li> <li>Hyperlinks should connect to a working webpage. Hyperlinks should preferably open pages in the same window.</li> <li>All links should be distinct from body text. They should be descriptively titled and a different color or italicized.</li> </ol>	Pass	All hyperlinks are distinct from body text and link to the correct sites.
Multimedia:		
<ol style="list-style-type: none"> <li>Closed captions should be provided for any video content.</li> <li>Descriptive transcripts should be provided for any video content.</li> <li>Audio or video player used for multimedia content should be compatible with assistive technology.</li> <li>No content should flash more than 3 times per second.</li> </ol>	Pass	
STEM Content		
<ol style="list-style-type: none"> <li>STEM formulas and equation should be created with an editor compatible with screen readers such as LaTeX or MathML.</li> <li>If equations are inserted as images they should be described in an alt tag.</li> </ol>	Pass	

Font

- 1. Font should be adjustable and compatible with screen readers, magnification software, and colored displays. Text must remain accessible when any font size is selected.
  - 2. All font should have zoom capabilities to 200%.
  - 3. Font should meet standard size requirements (12 pt. body, 9 pt. footnote).
  - 4. Alternative color and line spacing adjustments should be available.
- Pass

Color Contrast:

- 1. All information presented in color should also be conveyed in text or other images.
  - 2. Headers should meet WCAG AA contrast standards.
  - 3. Body text should meet WCAG AA contrast standards.
  - 4. Simple images should meet WCAG AA contrast standards.
- Fail
- The example answers to the questions in the pre-lab portion of the manual are marked in red with no other distinction.

Interactive Elements:

- 1. Interactive elements such as menus, examples, practice questions, etc., allow keyboard only operation with and without assistive technology.
  - 2. All instructions, error messages, and prompts are in text and compatible with assistive technology.
  - 3. Text should allow for keyboard only operation.
  - 4. Text should be accessible on mobile devices.
- Pass
-

# Errata and Versioning History

MAVS OPEN PRESS

The peer review process for Mavs Open Press resources varies by publication and author. We strive for transparency and describe the creation process in the front matter of each text so readers may evaluate the work on its own merit. Because we offer web-based services, we can quickly and easily address any errors that arise after publication. This page provides a record of edits and changes made to the web version of this book since its initial publication.

Changes logged here are reflected in the web text only until a new version of the resource is released, at which point the file downloads are also updated. Version updates are noted in the Status field below.

If you have a correction to suggest, submit it to [pressbooks@uta.edu](mailto:pressbooks@uta.edu). We will contact the author then make and log necessary changes here. Below is a list of Correction Types we currently update:

1. Typo
2. Broken link
3. Addition
4. Other factual inaccuracy in content
5. Incorrect calculation or solution
6. General/pedagogical suggestion or question
7. Settings

---

<b>Date Submitted</b>	<b>Format</b>	<b>Correction Type</b>	<b>Location</b>	<b>Description</b>	<b>Status</b>
NA	Web + Exports	NA	NA	Initial Release	8/22/18 – Published V1
8/23/18	Web + Exports	Meta Update	Front Matter	Updated Wilk's title	8/23/18 – complete
8/23/18	Web	Settings	NA	Changed accessibility review date to 8/31	8/24/18
8/24/18	Exports	Settings	NA	Download options not available	8/24/18 – adjusted setting to allow downloads
10/4/18	Web Text	General Update	Accessibility Statement	Added more precise attribution for BCCampus resource	Updated 10/8/18
NA	Web Text	URL	Front & Back Matter	Updated URLs	Updated 11/19/18

---